



A Bizarre Case of Periovarian Hematoma in a Patient Undergoing Controlled Ovarian Stimulation Managed Conservatively

Garima Sachdeva *, Devi Ravikumar, Viqat Ara

- Department of Reproductive Medicine, Milann Indiranagar Centre, Bangalore, India

Abstract

Background: The occurrence of ovarian hematoma during controlled ovarian stimulation (COS) is very rare. Until now, there is no such case reported in the literature. In this study, an attempt was made to discuss the possible mechanisms for the development of hematoma in such patients, the clinical presentation, monitoring, and management of these cases.

Case Presentation: A rare case of periovarian hematoma was reported in a patient with a history of endometriosis undergoing ovarian stimulation for in vitro fertilization. On the seventh day of stimulation, the patient complained of severe pain in the abdomen. Her vitals and blood investigations were within normal limits. On abdominal examination, mild tenderness was noted in the left iliac fossa. On vaginal examination, fullness and tenderness were noted in the left fornix. On ultrasound, probe tenderness was present and a left ovarian hematoma measuring 2.0×1.81×1.55 cm was observed. She was managed conservatively. The hematoma exhibited a gradual reduction following the pick-up procedure and eventually resolved completely within a month.

Conclusion: Underlying endometriosis could be one of the possible causes of this periovarian hematoma. A conservative approach with close monitoring forms the first-line management in hemodynamically stable patients.

Keywords: Hematoma, In vitro fertilization, Oocyte retrieval, Ovarian stimulation, Ultrasonography.

To cite this article: Sachdeva G, Devi R, Viqat Ara. A Bizarre Case of Periovarian Hematoma in a Patient Undergoing Controlled Ovarian Stimulation Managed Conservatively. *J Reprod Infertil.* 2024;25(2):157-162. <https://doi.org/10.18502/jri.v25i2.16010>.

Introduction

In this modern era, assisted reproductive technology (ART) and its associated procedures like in vitro fertilization (IVF) and embryo transfer are becoming extremely popular. However, these ART procedures are associated with certain complications like ovarian hyperstimulation syndrome, ovarian torsion, and transvaginal oocyte retrieval related complications like intraperitoneal haemorrhage, rupture of the endometriosis cysts, pelvic abscess, and perforation (1). Cases of intra-abdominal or intra-peritoneal bleeding following ovum pick-up have been reported, with a prevalence rate estimated to be approximately 0.23% (2). However, intra-peritoneal

hematoma during ovarian stimulation is extremely rare with no case reported till now in the literature.

In this study, a case of spontaneous periovarian hematoma was reported during ovarian stimulation which was managed conservatively with antibiotics and analgesics.

Case Presentation

A 29-year-old woman with a history of primary infertility of 1.5 years visited our infertility center (Bangalore, India) in June 2020. One year ago, she underwent operative hystero-laparoscopy during which bilateral endometriomas measuring 2×1

* Corresponding Author:
Garima Sachdeva,
Department of Reproductive
Medicine, Milann
Indiranagar Centre,
Bangalore, India
E-mail:
gsachdeva25@gmail.com

Received: 19, Jan. 2024

Accepted: 5, Jun. 2024

cm were identified in her ovaries and cystectomy was performed. Endometriotic spots present in the pouch of Douglas were fulgurated. A focal adenomyoma measuring 3×2 *cm* was present and adeno-myomectomy was done. Anterior subserosal fibroid measuring 3×2 *cm* was present and myomectomy was performed to remove it. There was adhesion between the left tube and the left ovary. The right tube was normal. On chromoperturbation, the free bilateral spill was present. Two cycles of ovulation induction and timed intercourse were done post hystero-laparoscopy, when she failed to conceive.

Her BMI was 35.7 *kg/m²*, baseline follicle stimulating hormone (FSH) and luteinizing hormone (LH) levels were 8.03 *IU/ml* and 4.43 *IU/ml*, respectively and anti-Müllerian hormone (AMH) level was 1.86 *ng/ml*. Semen analysis was suggestive of normozoospermia (135 *M/ml*, 94% total motility, 64% progressive motility, and 11% normal forms). Baseline ultrasound on day 2 of the menstrual cycle revealed a retroverted retroflexed adenomyotic uterus. The posterior wall appeared adenomyotic, with the anterior wall measuring 0.8 *cm* and posterior wall measuring 3.2 *cm*. The right ovary had an endometrioma measuring 8 *mm*. Bilateral ovaries were of normal size with a total antral follicle count (AFC) of 8. The left ovary was stuck to the posterior wall of the uterus. There was no other haemorrhagic cyst/fluid collection noted.

The patient was counseled about undergoing IVF. The antagonist protocol was used for controlled ovarian stimulation, starting with recombinant FSH-300 *IU* (Follisurge; Intas, India). On stimulation day 7, the patient complained of severe pain in the abdomen. There was no history of tenesmus, painful urination, or fever. Her vital signs were stable with a blood pressure of 110/60 *mmHg*, pulse rate of 88 bpm, and oxygen saturation (SpO₂) levels ranging between 98% to 99%. On abdominal examination, mild tenderness was noted in the left iliac fossa. On vaginal examination, fullness and tenderness were noted in the left fornix. On ultrasound, probe tenderness was present along with left ovarian hematoma measuring 2.0×1.81×1.55 *cm*. Additionally, haemorrhagic free fluid measuring 2.78×1.81 *cm* was observed around the left ovary. The urine pregnancy test yielded a negative result. Her blood counts, coagulation profile, and serum electrolytes were within normal ranges with the following values: haemo-

globin-12 *gm/dL*; leukocyte count-8090 cells/cumm; platelet-3.66 lac/cumm; erythrocyte sedimentation rate (ESR)-10; packed cell volume (PCV)-39.2; prothrombin time (PT)-12 seconds; activated partial thromboplastin time (APTT)-29.8 seconds; international normalized ratio (INR)-1.04; sodium-135 *mEq/L*; potassium-4.14 *mEq/L*; and chloride-97.3 *mEq/L*.

The couple was counseled about the options of cycle cancellation or continuation of IVF stimulation with inpatient monitoring. In case of hemodynamic instability, worsening of pain, or deterioration of blood counts, the possibility of cycle cancellation and operative laparoscopy with drainage of hematoma, hemostatic measures, and a rare chance of oophorectomy in the event of uncontrolled bleeding was thoroughly explained. Moreover, the patient was counseled about the uncertain effects on the oocyte or embryo quality, and the possibility of not obtaining or not forming any embryos. The patient expressed her desire to continue with the controlled ovarian stimulation (COS). A detailed and comprehensive written consent was obtained from the patient, and the process was thoroughly explained for her.

She was admitted to the center and started on intravenous antibiotics and analgesics. She was closely monitored as an inpatient, with regular assessments of vitals, abdominal girth, urine output, changes in the size of hematoma (via ultrasound), and blood counts. Table 1 and figure 1 show the progressive changes in hematoma size, abdominal girth, and blood counts as the stimulation progressed.

These parameters were almost stable with the progression of the stimulation. A challenge revolved around ensuring the patient received adequate analgesia. During the initial part of the COS, she was managed with intravenous NSAIDs (specifically, intravenous diclofenac sodium) in accordance with the patient's body mass index. She did not get adequate pain relief with acetaminophen or tramadol. In order to avoid the use of NSAIDs towards the end of the stimulation, an alternative approach was taken. Hence, during the last four days of COS, a fentanyl patch (50 *µg/hr*) was used for her pain relief.

The stimulation continued for 12 days, during which a total dose of 3600 *IU* of gonadotropin was administered. This consisted of Inj Follisurge (recombinant FSH) at a dose of 1725 *IU* and Inj Menopur (HMG) at a dose of 1875 *IU*. Ovum

Table 1. Changes in the ultrasound and hematological parameters during the ovarian stimulation cycle

Stimulation day	Abdominal girth (cm)	Ultrasound findings			Counts	
		Left peri-ovarian hematoma (cm)	Hemorrhagic fluid (cm)	Hemoglobin (gr/dl)	Hematocrit (%)	Leucocyte count: Total (cell/ul) and differential (Neutrophil-N/Lymphocytes-L)
Day 7	101	2.0×1.81×1.55	2.78×1.81	12	39.2	8090 N78/L16/M4
Day 8	101	2.2×1.76×1.55	1.7×1.1			
Day 9	101	2.3×2.4×1.9	2.5×1.23	11.5	37.6	7700 N67/L26/M4
Day 10	101	2.7×2.6×2.06	1.8×1.2	12.1	38.3	8010 N65/L26/M4
Day 11	101	2.6×2.0×1.9	1.9×1.3			
Day 12	101	2.7×2.6×2.0	Very minimal	12.1	38.3	8010 N70/L22/MS
OPU Day	101	2.7×2.6×2.0	2.6×1.7			

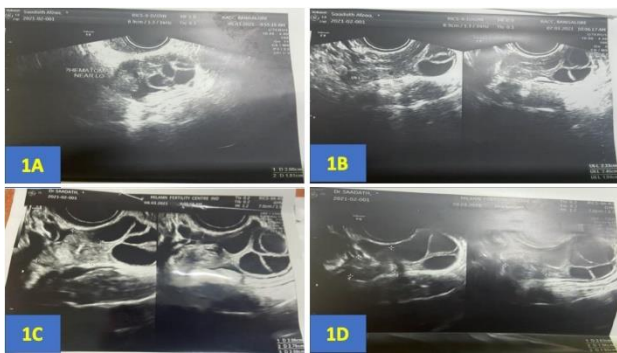


Figure 1. Left peri-ovarian hematoma during controlled ovarian stimulation. 1A) Day 7 of stimulation-Left peri-ovarian hematoma measuring 2.0×1.81×1.55 cm. 1B) Day 9 of stimulation-Left peri-ovarian hematoma measuring 2.3×2.4×1.9 cm. 1C) Day 10 of stimulation- Left peri-ovarian hematoma measuring 2.7×2.6×2.06 cm. 1D) Day 11 of stimulation-Left peri-ovarian hematoma measuring 2.6×2.0×1.9 cm

pick-up was done with proper precautions. Prior to the procedure, the patient underwent pre-operative bowel preparation. Additionally, a standby surgeon and fully equipped operation theatre were prepared in case that laparoscopy or laparotomy was required during the procedure.

The ovum pick-up procedure was done under general anaesthesia. A double lumen needle was used, allowing a maximum of 2 flushes of 2 ccs each for every follicle. Next, a single puncture was made in both ovaries under ultrasound and Doppler guidance. A total of 5 metaphase II oocytes were obtained during the procedure. The oocytes exhibited characteristics such as a dense

cytoplasm, fragmented polar bodies, and an increased perivitelline space with debris. All retrieved oocytes were successfully fertilized and cleaved. A total of 3 embryos at the 8-cell stage and 2 embryos at the 5-cell stage were obtained. Out of these, 1 embryo at the 8-cell stage and 2 embryos at the 5-cell stage were cultured for further development to the blastocyst stage. However, unfortunately, these embryos arrested during their development. As a result, the final remaining embryos were 2 at the 8-cell stage, which were cryopreserved (frozen) for future use. The patient's symptoms improved, leading to a gradual reduction in the use of analgesics. Ultrasound revealed no evidence of active bleeding or an increase in hematoma size and the patient was discharged under the stable condition on the postoperative day 3. There was a progressive decrease in the size of hematoma in the post pick-up period and it finally disappeared on day 30 post pick-up (Table 2).

Frozen day 3 embryo transfer was planned one month after resolution of hematoma but unfortunately the patient failed to conceive.

Discussion

During management of this patient, several potential differential diagnoses were considered, including peri-ovarian hematoma, haemorrhagic cyst, and hematosalpinx. The possibility of a hemorrhagic cyst was ruled out as the observed collection was separate from the ovary. Hematosalpinx was also excluded as it was not present prior to

Table 2. Changes in the ultrasound and hematological parameters Post-PICK-UP

Post OPU day	Ultrasound findings				Counts	
	Left peri-ovarian hematoma (cm)	Hemorrhagic fluid (cm)	Hemoglobin (gr/dl)	Hematocrit (%)	Total (cell/ul)	Leucocyte count: and differential (Nuetrophil-N/ Lymphocytes-L)
Day 1	2.7×2.6×2.0	2.58×1	11.5	36.4		14.200 N785/L10/M4
Day 3	3.4×1.76×1.53	2.3×2.3×0.93				
Day 13	2.8×1.99×1.65	1.5×1.47×1.28	11.5	37.6		9000 N69/L23/M5
Day 30	No hematoma	No fluid				

the stimulation, resolved completely within a month of oocyte retrieval and it did not have typical tubular appearance. The possible diagnosis of periovarian hematoma was thus determined. Spontaneous ovarian hematoma during ovarian stimulation is extremely rare but can sometimes prove to be life-threatening due to complications like haemorrhagic shock, disseminated intravascular coagulation, and sudden death (3). Due to the paucity of available literature, the decision regarding whether to proceed with stimulation or cancel the cycle could not be reached. However, with the patient’s consent, the decision to continue stimulation was made but stringent daily monitoring of the vitals, symptoms, size of the hematoma, haemoglobin, and blood counts was conducted. Symptomatic treatment with antibiotics and analgesics was done, keeping the patient informed about the need for emergency surgery if symptoms deteriorate. There was no need for surgery in this case as the hematoma was relatively stable during the course of follow-up.

The possible mechanisms of the hematoma in this patient could be due to bleeding from the endometriotic implants or spontaneous rupture of the utero-ovarian vessels (4). Adhesions around the ovaries can create tension leading to rupture of these utero-ovarian vessels as the ovaries get enlarged with ovarian stimulation (5). Another possible reason for this hematoma could be stretching of the ovarian capsule with progressive enlargement of the ovaries leading to rupture of small capillaries or endometriosis implants. Moreover, endometriosis can cause chronic inflammation, which may be aggravated by ovarian stimulation causing extravasation from these utero-ovarian vessels (5).

Blood clot acts as an irritant, leading to peritoneal irritation, which subsequently activates somatic

sensory nerves and causes severe pain that is localized and characterized by a sharp sensation (6). Similarly, in this patient, the blood clotted around the ovary was irritating the somatic sensory nerve endings of the peritoneum and she presented with acute pain in the abdomen. Hence, pain is an important symptom in a patient undergoing ovarian stimulation, which should prompt the attending physician to do an urgent scan to assess for any blood accumulation.

Treating pain was very challenging in this patient as the most commonly used analgesics, NSAIDs (non-steroidal anti-inflammatory drugs), should be used very cautiously in these patients undergoing ovarian stimulation. The process of ovulation involves a series of events which are initiated by luteinizing hormone (LH) surge. These events include resumption of meiosis, expansion of the cumulus cells, follicular wall rupture mediated by various proteolytic enzymes, and release of COC (cumulus oophorus complex) from the ovaries (7). Prostaglandins (PGs) have a well-established role in initiating the cascade of events leading to ovulation. LH surge increases the levels of PGE2 within the mature follicle which causes expansion of cumulus cells and increased expression of the proteases that are required for follicular rupture (8). Moreover, PGE2 has a role in the resumption of meiosis in the oocyte via the cAMP (cyclic adenosine monophosphate) pathway (8). NSAIDs are COX-2 (cyclo-oxygenase-2) inhibitors and they inhibit prostaglandin synthesis and thus prevent ovulation, resulting in luteinized unruptured follicle syndrome (9). Hence, in this patient, NSAIDs were discontinued near the end of the stimulation and opioids (fentanyl patch) were used for effective analgesia which should be the choice for pain management in such patients.

Ovum pick-up can sometimes present challenges

in such cases because it can exacerbate bleeding, leading to expansion of hematoma, and worsening of symptoms. In such scenarios, emergency laparoscopy or laparotomy may be necessary for further management. Sometimes, bleeding can be so severe that it may require an oophorectomy, which poses a significant loss for a patient undergoing infertility treatment. Hence, counseling and obtaining proper written informed consent are very important in such patients to avoid the risk of medical litigation. Using ultrasound and Doppler guidance can help decrease bleeding complications (10). Moreover, it is very important to be prepared for major emergency surgery in case any complications arise. In this case, the patient, operation theatre, and surgeon were kept prepared in the event of an emergency requirement for laparoscopy or laparotomy. Subsequent pick-up or pooling method in such patients can become increasingly challenging as with each surgery or pick-up procedure, neo-vascularisation, fibrosis, and adhesion formation occurs, escalating the risk of similar complications in future cycles of pick-up. There is clear evidence available in the literature about the deleterious effect of blood collections in cases of endometriosis affecting the oocyte and embryo quality (11). Nevertheless, additional research is needed to investigate the implications of blood collection outside the ovary in the form of periovarian hematoma. In this case, the proportion of oocytes retrieved was 100% (benchmark value (12): 80-95%), M2 conversion rate was 62.8% (benchmark value (12): 75-90%), cleavage rate was 100% (competency value (12) >95%, benchmark value (12) >99%), and day 3 embryo rate was 60% (competency value (12) >45%, benchmark value (12) >70%). Moreover, the quality of oocytes was also affected which could be a possible reason for low M2 conversion rates.

To the best of our knowledge, to date, no such case has been reported in the literature. It is very important for reproductive medicine specialists to be aware of and to identify this rare complication of ovarian stimulation to ensure optimal clinical management. Reporting of such rare cases is very important to bridge the knowledge gaps within the field.

Conclusion

Periovarian hematoma following ovarian stimulation is extremely rare. Underlying endometriosis

can be one of the possible causes. A conservative approach with close monitoring forms the first-line management in hemodynamically stable patients.

Conflict of Interest

The authors declare that they have no conflict of interest.

References

1. Gautam A. Complications of IVF. *J Obstet Gynecol India*. 2010;60(4):297-8.
2. Levi-Setti PE, Cirillo F, Scolaro V, Morengi E, Heilbron F, Girardello D, et al. Appraisal of clinical complications after 23,827 oocyte retrievals in a large assisted reproductive technology program. *Fertil Steril*. 2018;109(6):1038-1043.e1.
3. Liberty G, Hyman JH, Eldar-Geva T, Latinsky B, Gal M, Margalioth EJ. Ovarian hemorrhage after transvaginal ultrasonographically guided oocyte aspiration: a potentially catastrophic and not so rare complication among lean patients with polycystic ovary syndrome. *Fertil Steril*. 2010;93(3):874-9.
4. Aziz U, Kulkarni A, Lazic D, Cullimore JE. Spontaneous rupture of the uterine vessels in pregnancy. *Obstet Gynecol*. 2004;103(5 Pt 2):1089-91.
5. Katorza E, Soriano D, Stockheim D, Mashiach R, Zolti M, Seidman DS, et al. Severe intraabdominal bleeding caused by endometriotic lesions during the third trimester of pregnancy. *Am J Obstet Gynecol*. 2007;197(5):501.e1-4.
6. Patterson JW, Kashyap S, Dominique E. Acute abdomen [internet]. In: Treasure Island, (FL): StatPearls Publishing; 2021. StatPearls [cited May 20 2021]. Available from: <http://www.ncbi.nlm.nih.gov/books/NBK459328/>.
7. Holesh JE, Bass AN, Lord M. Physiology, ovulation [internet]. In: Treasure Island, (FL): StatPearls Publishing; 2021. StatPearls [cited May 20 2021]. Available from: <http://www.ncbi.nlm.nih.gov/books/NBK441996/>.
8. Niringiyumukiza JD, Cai H, Xiang W. Prostaglandin E2 involvement in mammalian female fertility: ovulation, fertilization, embryo development and early implantation. *Reprod Biol Endocrinol*. 2018;16(1):43.
9. Gaytán M, Morales C, Bellido C, Sánchez-Criado JE, Gaytán F. Non-steroidal anti-inflammatory drugs (NSAIDs) and ovulation: lessons from morphology. *Histol Histopathol*. 2006;21(5):541-56.
10. Sehgal N. Efficacy of color doppler ultrasonography in differentiation of ovarian masses. *J Midlife Health*. 2019;10(1):22-8.

11. Sanchez AM, Vanni VS, Bartiromo L, Papaleo E, Zilberberg E, Candiani M, et al. Is the oocyte quality affected by endometriosis? a review of the literature. *J Ovarian Res.* 2017;10(1):43.
12. ESHRE special interest group of embryology and

alpha scientists in reproductive medicine. The vienna consensus: report of an expert meeting on the development of ART laboratory performance indicators. *Reprod Biomed Online.* 2017;35(5): 494-510.