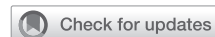

# Functional anatomy and surgical principles of mitral repair for the Barlow valve: Past legacy guides the future



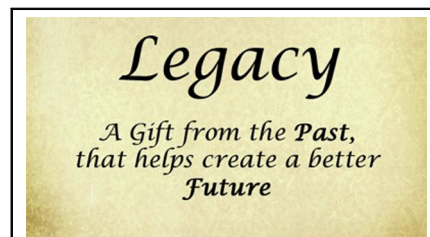
Clifford W. Barlow, DPhil, FRCS (CTh), Hani Ali-Ghosh, MBBS, FRCS (CTh), and Sarvananthan Sajiram, IC-PhD, MRCS

**Associate Editor's Introduction**—Of the degenerative mitral valve diseases, the “Barlow valve” may be the most complex in terms of anatomy, pathophysiology, and repairability. This entity has the pathognomonic bileaflet “billowing” with functional prolapse secondary to abnormal annular motion and is further characterized by the presence of arrhythmias and, on occasion, sudden death. As the namesake first author reminds us, an understanding of this complex anatomy and physiology as well as adherence to a standard set of principles will aid the surgeon in addressing repair of this valve. This Invited Expert Opinion provides the reader with a synopsis of the main issues to consider in the treatment of this disease.

**Abe DeAnda Jr, MD**

## HISTORY OF THE BARLOW VALVE: UNDERSTANDING COMPLEX TERMINOLOGY

More than 5 decades have passed since John Barlow first described the condition that has come to be known by a plethora of names including Barlow syndrome, Barlow disease, and the Barlow valve.<sup>1</sup> Two of Dr Barlow's initial observations have proved particularly noteworthy. The first was that a late systolic murmur had a mitral origin, as previously clinicians believed that the murmur of mitral regurgitation must always be pan-systolic. Remarkably, Barlow described this feature in the era before echocardiography.<sup>2</sup> We now know that mitral regurgitation commencing in mid-systole is a result of “functional prolapse” caused by abnormal annular motion, and understanding this guides our repair strategy more than 50 years later. Dr Barlow's second observation was that malignant arrhythmias could be triggered by a prolapsing mitral valve, especially a



Today's optimal strategy for Barlow valve repair is derived from the legacy of pioneering scientists.

### CENTRAL MESSAGE

Optimal Barlow valve repair requires an understanding of both abnormal mitral valve anatomy and function and then application of one set of principles to deliver an individual solution for each patient.

See Commentaries on pages 64 and 66.

“Barlow valve,” and that sudden cardiac death could occur.<sup>3</sup> Once again, Barlow not only established and reported this finding decades ago, but also noted that mitral valve repair could have a beneficial effect on arrhythmias that were largely unrelated to any degree of preoperative mitral regurgitation.<sup>4</sup>

In the 1960s, before echocardiography was available, using clinical examination, phonocardiography, and cineangiography, Dr Barlow initially described a mitral etiology of the “nonejection systolic click” and late systolic murmur.<sup>1,2</sup> He noted that a “syndrome” of symptoms comprising anxiety, atypical chest pain, and palpitations may be associated with this condition.<sup>5-7</sup> These symptoms were found to be most common in young women and, crucially, were causally related to the mitral valve.

For more than 4 decades, until his death in 2008, Dr Barlow emphasized the importance of understanding the functional anatomy of the abnormal mitral valve.<sup>7</sup> For example, either or both leaflets could “billow” beyond the annulus into the atrium during systole, but the valve could be functionally normal. A billowing but functionally normal valve should not be described as “mitral valve

From the Department of Cardiothoracic Surgery, University Hospital Southampton, Southampton, United Kingdom.

Received for publication July 29, 2021; accepted for publication Aug 27, 2021; available ahead of print Sept 15, 2021.

Address for reprints: Clifford W. Barlow, DPhil, FRCS (CTh), Department of Cardiothoracic Surgery, University Hospital Southampton, Tremona Rd, Southampton SO16 6YD, United Kingdom (E-mail: [clifford.barlow@uhs.nhs.uk](mailto:clifford.barlow@uhs.nhs.uk)).

JTCVS Techniques 2021;10:58-63

2666-2507

Crown Copyright © 2021 Published by Elsevier Inc. on behalf of The American Association for Thoracic Surgery. This is an open access article under the CC BY-NC-ND license (<http://creativecommons.org/licenses/by-nc-nd/4.0/>).

<https://doi.org/10.1016/j.jtc.2021.08.046>

prolapse” even if it causes an audible mid-systolic click. Barlow emphasized that if there is true anatomic prolapse of the free edge of either mitral leaflet, then there is mitral regurgitation, and therefore a “prolapsing” mitral valve is always functionally abnormal. He favored the umbrella term “degenerative mitral valve disease” over the eponym “Barlow’s disease” for the pathologic processes and clinical features of this condition. Indeed, in a personal communication written in 2008 a few months before his death, he stated “if the eponym Barlow’s syndrome is used in the future, it is crucial it reflects the symptoms are causally related to the billowing posterior mitral valve leaflet.” It remains important that complex terminology describes both the anatomy and function of the abnormal mitral valve.

Contemporaneously, in the 1970s, the pioneering French surgeon Alain Carpentier began describing mitral repair techniques including leaflet resection, chordal shortening, chordal transfer, and ring annuloplasty.<sup>8</sup> These techniques of course require accurate anatomic descriptions of the mitral pathology being addressed. When faced with a particularly abnormal valve that might have marked myxomatous degeneration and billowing of both leaflets, fissuring between leaflet scallops, bilateral chordal elongation with or without rupture, annular dilatation, and possible prolapse of both leaflets and commissures, the surgeon is presented with a surgical challenge that is difficult to describe anatomically. Therefore, it was not John Barlow, but Alain Carpentier, who coined the term “Barlow valve” to describe this particular entity.

### BARLOW VALVE REPAIR: UNDERSTANDING FUNCTIONAL PROLAPSE

From a surgical perspective, the Barlow Valve represents the most severe degenerative form of mitral valve disease. Anatomically, the leaflet tissue is diffusely thickened and

excessive and may have varying degrees of calcification, chords may be elongated and thickened, and the annulus may be severely dilated. Importantly, there frequently is also functionally abnormal annular motion, as advances in echocardiography can now demonstrate. The posterior annulus moves outward and downward during systole (Figure 1). Irrespective of the presence of true “anatomic prolapse” of the free edge of one or both leaflets, as Klautz and colleagues describe, the “movement of the annulus causes any opposing segment to appear prolapsing”.<sup>9</sup> Thus, the valve may be competent in early systole, but with pathologic annular outward and downward motion, “functional prolapse” occurs in later systole. This explains the murmur that John Barlow detected occasionally commencing in mid-systole but nevertheless having a mitral origin.

### BARLOW VALVE REPAIR: ONE SET OF PRINCIPLES AND THE IMPORTANCE OF SYMMETRY

All Barlow valves may be different, but if a surgeon understands the functional anatomy of each individual valve, and applies a single set of principles, then excellent and durable repairs can be achieved. As with all mitral repairs, the primary goals are valve competence, freedom from leaflet tension, and a smooth surface of leaflet coaptation.<sup>10</sup>

Initially, clear and precise anatomic and functional characterization of the valve through echocardiography is required, and 3-dimensional echocardiography has now emerged as an essential tool for characterizing the Barlow valve.<sup>11</sup> Preoperative echocardiography in the Barlow valve may confirm that functional prolapse due to abnormal annular motion is the sole abnormality. The resultant functional prolapse of both the anterior and posterior leaflets in later systole appears symmetrical and usually results in a

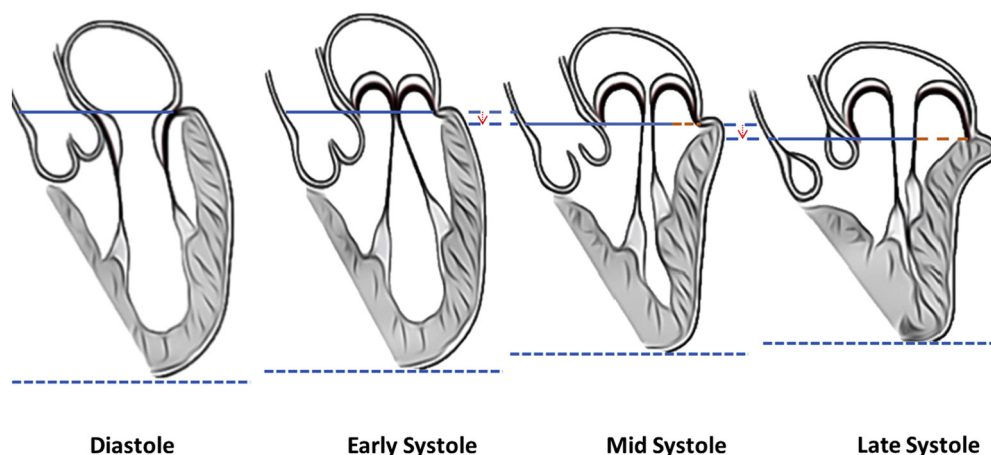


FIGURE 1. Abnormal annular motion causing functional prolapse in the Barlow valve. The posterior annulus moves outwards (orange dotted lines) and downward during systole (arrows).

central jet of mitral regurgitation. However, true anatomic prolapse results in an eccentric jet of regurgitation, regardless of the presence or absence of additional abnormal annular motion.

The intraoperative surgical assessment is for true anatomic prolapse and for the presence of excessive tissue. Any underlying lesion causing anatomic prolapse, either chordal elongation or rupture, should be identified by assessing each leaflet segment against a reference point, frequently the P1 scallop, and not the annulus.

If there is no true chordal elongation or rupture, then a stabilizing annuloplasty ring will eliminate the abnormal annular motion. This is a simple solution for an apparently complex but symmetric pathology. Because there is always excessive leaflet tissue in a Barlow valve, to avoid systolic anterior motion of the mitral valve after repair, the ring is invariably of a large size and may even be 38 mm or 40 mm in a small patient. Outstanding results have been reported using ring annuloplasty alone for symmetrical pathology in the Barlow valve through both median sternotomy and minimally invasive approaches.<sup>12</sup>

Addressing true anatomic prolapse and any excessive tissue of the posterior mitral valve leaflet must be done simultaneously. While there is no consensus among surgeons about the optimal technique for dealing with each specific abnormality, and each Barlow valve is different, the surgeon should apply a single set of principles. First, the distinction between excessive width and excessive height of posterior mitral leaflet tissue needs to be determined. Both Klautz and colleagues<sup>9</sup> and Dreyfus and colleagues<sup>10</sup> have described clear and logical approaches to this determination. Excessive width usually needs to be resected, although this frequently can be done via a limited triangular resection. Excessive height can be addressed through the “resect” technique, either by a sliding valvuloplasty or by resection of the posterior mitral valve leaflet base or free edge. This method has been clearly described by Dreyfus and colleagues,<sup>10</sup> and since normal leaflet height is restored, these authors advocate using secondary chords, which are already the correct height, rather than polytetrafluoroethylene (PTFE) neochords or loops. Alternatively, the “respect” technique for the Barlow valve involves correcting prolapse with PTFE neochords. If excessive posterior mitral leaflet height has not been addressed, the neochords can be shortened to pull the posterior mitral leaflet down into the left ventricle and ensure that the line of coaptation is situated well posteriorly. Neochords can be adjusted with water testing and final adjustments made after ring annuloplasty.<sup>9</sup>

True anatomic prolapse of the commissures is common in the Barlow valve. When the quality of the subvalvular apparatus is satisfactory, this frequently can be addressed by papillary muscle head repositioning.<sup>9</sup> Alternatively, PTFE

neochords or edge-to-edge commissuroplasty or cleft closure techniques can be applied.<sup>13</sup>

Ring annuloplasty is performed to secure the repair and reduce strain on the leaflets and subvalvular apparatus, as well as to correct annular dilatation. Large annuloplasty rings corresponding to the height of the anterior mitral leaflet and not to the intercommissural distance are needed, as with the symmetrical Barlow pathology, to reduce the risk of systolic anterior motion and to ensure smooth lines of coaptation between the leaflets.

Many techniques have their own merits, and they usually should be regarded as complementary to one other. Various surgeons have reported very good long-term results with their individual repair strategies,<sup>13,14</sup> suggesting that different approaches are possible to achieve successful treatment. This was well summarized in the descriptive article by Dreyfus and colleagues<sup>10</sup> that challenged the perception that “resect” and “respect” are somehow in conflict with each other. Excessive resection has undesirable consequences, including annular disruption and the potential for tension, but obsessively respecting the entire posterior mitral leaflet may be an oversimplification aimed at reducing learning curves and possibly allowing for minimal access approaches.<sup>10</sup> As Dreyfus and colleagues concluded, the best option may be to “respect when you can, resect when you should”.<sup>10</sup> In my Commentary on their paper, I recommended that we should therefore “tailor the operation to the patient and not the patient to the operation,” as one repair does not fit all, but one set of principles does.<sup>15</sup>

Freedom from recurrent late moderate or severe mitral regurgitation has been reported to be approximately 90% in the Barlow valve.<sup>16</sup> Some failures may be related to unreliable techniques or poor surgical execution. However, the disease process may be progressive, and so there are bound to be some repair failures in the long-term that cannot be completely prevented.<sup>17</sup>

#### **BARLOW VALVE REPAIR AND ARRHYTHMIAS: ANOTHER “GIFT FROM THE PAST”?**

There is a growing understanding of the arrhythmias associated with degenerative mitral valve disease and the role of surgery in managing them.<sup>18</sup> Just as it is essential to comprehend both the anatomic and functional abnormalities of any individual Barlow valve to be able to repair it optimally for regurgitation, so it is certain that in the future, the best practices for rhythm disturbances in degenerative mitral valve disease will be targeted to each individual patient. To do this, the surgeon must first understand the pathophysiology of arrhythmias in this condition and then be able to plan each individual patient’s investigations and any appropriate surgery.

Once again there are lessons for us from the past. John Barlow described palpitations as one of the most prominent symptoms of the so-called “Barlow syndrome” nearly

40 years ago.<sup>3</sup> Importantly, he was one of the first to describe that syncope and sudden death, although uncommon, could be associated with the condition and were directly associated with the abnormal mitral valve.<sup>3,19,20</sup> Barlow and coworkers postulated that the mechanisms of these arrhythmias included tension on the chords, friction injury to the ventricular endocardium caused by the excessive leaflet tissue during diastole, and, in older patients, established myocardial fibrosis, particularly of the papillary muscles.<sup>3,6</sup> Indeed, in 1957, 6 years before the publication of his seminal paper, Dr Barlow observed a single fibrosed mitral chord at the postmortem of a patient who whose sole clinical sign while alive was an isolated mid-systolic click and no murmur of regurgitation.<sup>6</sup> Barlow and coworkers' subsequent hypotheses regarding the mechanisms for palpitations, as well as the occasional malignant arrhythmias occurring in degenerative mitral valve disease, have proven remarkably accurate. Contemporary research assumes that premature ventricular contractions, especially when pleomorphic and following exercise, serve as the trigger for ventricular fibrillation.<sup>18</sup> Ventricular ectopy is now recognized as being due in part to regional stretch, to direct mechanical forces on the papillary muscles, or to triggered activity owing to damaged tissue with abnormal calcium handling and evoked delayed afterdepolarizations.<sup>20</sup> Ultimately, established myocardial fibrosis can supervene in older patients.

To investigate and manage patients appropriately, those patients at risk need to be identified. Barlow and coworkers' original research identified young women who had experienced syncope and had complex and multifocal premature ventricular contractions after exercise as the most at-risk group.<sup>3,4</sup> Nearly 30 years later, degenerative mitral valve disease, especially with a Barlow valve, has been confirmed as one of the most common causes of sudden cardiac death in young women.<sup>21,22</sup> The interaction of myocardial fibrosis substrate, ventricular ectopy trigger, and transient modulators causing sudden cardiac death, as well as clinical variables and markers associated with higher risk, has been superbly summarized in a review article by Miller and colleagues.<sup>18</sup> This research will further guide when particular investigations, such as magnetic resonance imaging and electrophysiological studies, are appropriate to identify those patients at risk of sudden cardiac death.

The vast majority of patients with arrhythmias associated with degenerative mitral valve disease should be treated medically or with catheter ablation. However, a case report by Barlow's group over 30 years ago, was among the first to describe the effect of mitral repair surgery in this condition.<sup>4</sup> We reported a 22-year-old woman who underwent mitral valve repair surgery after experiencing 3 episodes of syncope. Surgery was done primarily to prevent sudden cardiac death, as the associated mitral regurgitation was no more than mild. Not only did the resting

electrocardiogram normalize by 10 weeks after repair, but also multifocal premature ventricular contractions after exercise were virtually eliminated.<sup>4</sup>

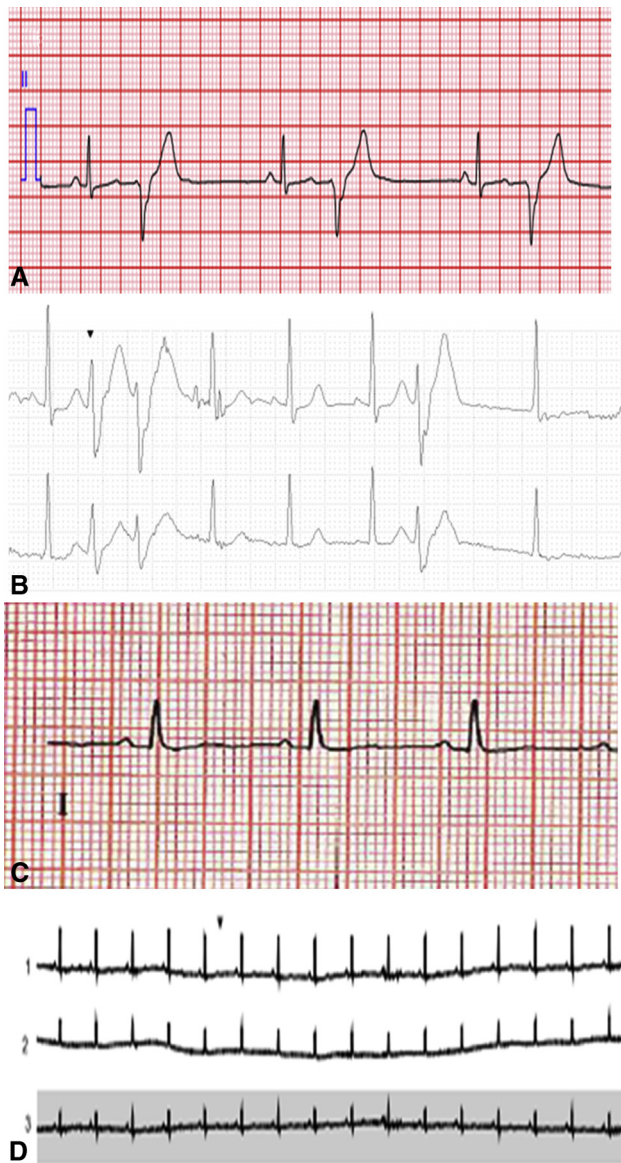
At the 2021 AATS Virtual Learning Experience, the first author of this publication described a very similar patient from his own practice. A 33-year-old woman presented with pre-syncope, frequent palpitations, and multifocal ventricular ectopy after exercise, but no more than moderate mitral regurgitation from a Barlow valve with symmetric pathology. The functional prolapse was eliminated with a stabilizing mitral annuloplasty ring. Preoperative resting and 24-hour Holter electrocardiograms showed multifocal premature ventricular ectopic beats, including bigeminy, couplets and triplets. At 2 months after mitral valve repair, the premature ventricular ectopic burden, which had been up to 14% of the total preoperatively, was virtually eliminated, to 0.01% of the total (Figure 2).

The literature on the benefit of mitral surgery for arrhythmias in mitral valve prolapse remains limited to isolated case studies, such as ours, and small series.<sup>4,23,24</sup> Nonetheless, it is becoming clearer that in older patients, there is a fairly limited benefit from mitral repair surgery alone.<sup>24</sup> This is understandable, given the high likelihood of established myocardial fibrosis in older patients and the fact that the release of tension alone following mitral repair is insufficient to treat their arrhythmias. In these patients, such procedures as additional catheter ablation, either perioperatively or intraoperatively, and possibly even internal defibrillator implantation may be required.

## CONCLUSION: LEARNING FROM THE PAST

Legacy has been described as a gift from the past that helps us create a better future. Pioneering research reported decades ago by John Barlow and others established the need to understand both the anatomic and functional pathology of the regurgitant Barlow valve to perform an optimal and durable repair. The same requirement will apply to future transcatheter interventions. There are already 4 transcatheter techniques for the treatment of degenerative mitral regurgitation,<sup>25</sup> including chordal replacement (NeoChord, Harpoon cords), leaflet edge-to-edge clip repair (MitraClip, PASCAL TMVr system), percutaneous ring annuloplasty inserted indirectly via the coronary sinus or directly from retrograde left ventricular access (Carillon, Cardioband, Millipede, Mitralign, ARTO systems), and transcatheter mitral valve replacement (Sapien-XT, Melody, CardiaAQ, Caisson valve). It is uncertain whether these emerging technologies will complement or replace current repair strategies, and we lack long-term data, particularly in the management of the Barlow valve. Nonetheless, what is certain is that for future percutaneous techniques to be effective and durable, they must reflect an understanding of the interactions between the anatomic and functional pathology of the mitral valve in this condition.





**FIGURE 2.** Resting and Holter electrocardiogram recordings from a 33-year-old patient with symmetrical Barlow valve pathology before and after mitral repair. Preoperative rhythm strips show premature ventricular ectopic bigeminy at rest (A) and multifocal, high-burden premature ventricular ectopics, including couplets, during exercise (B). Postoperative rhythm strips are normal at rest (C) and during exercise (D).

Past pioneers, like John Barlow, also made the initial observations on malignant arrhythmias and sudden cardiac death in degenerative mitral valve disease, as well as the possible benefits of mitral repair surgery. In the future, when we are confronted by a Barlow valve with associated malignant arrhythmias, it is also the legacy of their research that will help direct the investigation, timing, technique, and need for additional procedures of the subsequent mitral repair.

**Conflict of Interest Statement**

The authors reported no conflicts of interest.

The *Journal* policy requires editors and reviewers to disclose conflicts of interest and to decline handling or reviewing manuscripts for which they may have a conflict of interest. The editors and reviewers of this article have no conflicts of interest.

**References**

1. Barlow JB, Pocock WA. The significance of late systolic murmurs and mid-late systolic clicks. *Md State Med J.* 1963;12:76-7.
2. Barlow JB, Bosman CK, Pocock WA, Marchand P. Late systolic murmurs and non-ejection (“mid-late”) systolic clicks. An analysis of 90 patients. *Br Heart J.* 1968;30:203-18.
3. Pocock WA, Bosman CK, Chesler E, Barlow JB, Edwards JE. Sudden death in primary mitral valve prolapse. *Am Heart J.* 1984;107:378-82.
4. Pocock WA, Barlow JB, Marcus RH, Barlow CW. Mitral valvuloplasty for life-threatening ventricular arrhythmias in mitral valve prolapse. *Am Heart J.* 1991; 121(1 Pt 1):199-202.
5. Pocock WA, Barlow JB. Postexercise arrhythmias in the billowing posterior mitral leaflet syndrome. *Am Heart J.* 1970;80:740-5.
6. Barlow JB. Idiopathic (degenerative) and rheumatic mitral valve prolapse: historical aspects and an overview. *J Heart Valve Dis.* 1992;1:163-74.
7. Barlow JB, Pocock WA. Billowing, floppy, prolapsed or flail mitral valves? *Am J Cardiol.* 1985;55:501-2.
8. Carpentier A, Chauvaud S, Fabiani JN, Deloche A, Relland J, Lessana A, et al. Reconstructive surgery of mitral valve incompetence: ten-year appraisal. *J Thorac Cardiovasc Surg.* 1980;79:338-48.
9. Klautz RJ, Tomšič A, Palmen M, van Brakel TJ, Perier P. Optimal surgical mitral valve repair in Barlow’s disease: the concept of functional prolapse. *Multimed Man Cardiothorac Surg.* December 6, 2016. <https://doi.org/10.1510/mmcts.2016.001>, <https://mmcts.org/tutorial/476>
10. Dreyfus GD, Dulguerov F, Marcacci C, Haley SR, Gkouma A, Dommer C, et al. “Respect when you can, resect when you should”: a realistic approach to posterior leaflet mitral valve repair. *J Thorac Cardiovasc Surg.* 2018;156:1856-66.e3.
11. Chandra A, Salgo IS, Sugeng L, Weinert L, Tsang M, Takeuchi KT, et al. Characterization of degenerative mitral valve disease using morphologic analysis of real-time three-dimensional echocardiographic images: objective insight into complexity and planning of mitral valve repair. *Circ Cardiovasc Imaging.* 2011;4:24-32.
12. Faerber G, Tkebuchava S, Diab M, Schulze C, Bauer M, Doenst T. Minimally invasive mitral valve repair of symmetric and asymmetric Barlow’s disease. *Clin Res Cardiol.* April 1, 2021;1-9. <https://doi.org/10.1007/s00392-021-01844-9>, <https://link.springer.com/article/10.1007%2Fs00392-021-01844-9>
13. Borger MA, Kaeding AF, Seeburger J, Melnitchouk S, Hoebartner M, Winkfein M, et al. Minimally invasive mitral valve repair in Barlow’s disease: early and long-term results. *J Thorac Cardiovasc Surg.* 2014;148:1379-85.
14. De Bonis M, Lapenna E, Del Forno B, Di Sanzo S, Giacomini A, Schiavi D, et al. Minimally invasive or conventional edge-to-edge repair for severe mitral regurgitation due to bileaflet prolapse in Barlow’s disease: does the surgical approach have an impact on the long-term results? *Eur J Cardiothorac Surg.* 2017;52:131-6.
15. Sadeque SA, Barlow CW. Posterior leaflet mitral valve prolapse: one repair does not fit all. *J Thorac Cardiovasc Surg.* 2018;156:1867-8.
16. Jouan J, Berrebi A, Chauvaud S, Menasché P, Carpentier A, Fabiani JN. Mitral valve reconstruction in Barlow disease: long-term echographic results and implications for surgical management. *J Thorac Cardiovasc Surg.* 2012;143(4 Suppl):S17-20.
17. Flameng W, Meuris B, Herijgers P, Herregods MC. Durability of mitral valve repair in Barlow disease versus fibroelastic deficiency. *J Thorac Cardiovasc Surg.* 2008;135:274-82.
18. Miller MA, Dukkupati SR, Turagam M, Liao SL, Adams DH, Reddy VY. Arrhythmic mitral valve prolapse: JACC review topic of the week. *J Am Coll Cardiol.* 2018;72(23 Pt A):2904-14.
19. Basso C, Perazzolo Marra M, Rizzo S, De Lazzari M, Giorgi B, Cipriani A, et al. Arrhythmic mitral valve prolapse and sudden cardiac death. *Circulation.* 2015; 132:556-66.
20. Maruyama T, Fukata M. Increased coupling interval variability—mechanistic, diagnostic and prognostic implication of premature ventricular contractions and underlying heart diseases. *Circ J.* 2015;79:2317-9.

21. Oliva A, Brugada R, D'Aloja E, Boschi I, Partem S, Brugada J, et al. State of the art in forensic investigation of sudden cardiac death. *Am J Forensic Med Pathol.* 2011;32:1-16.
22. Chugh SS, Chung K, Zheng ZJ, John B, Titus JL. Cardiac pathologic findings reveal a high rate of sudden cardiac death of undetermined etiology in younger women. *Am Heart J.* 2003;146:635-9.
23. Naksuk N, Syed FF, Krittanawong C, Anderson MJ, Ebrille E, DeSimone CV, et al. The effect of mitral valve surgery on ventricular arrhythmia in patients with bileaflet mitral valve prolapse. *Indian Pacing Electrophysiol J.* 2016;16:187-91.
24. Vaidya VR, DeSimone CV, Damle N, Naksuk N, Syed FF, Ackerman MJ, et al. Reduction in malignant ventricular arrhythmia and appropriate shocks following surgical correction of bileaflet mitral valve prolapse. *J Interv Card Electrophysiol.* 2016;46:137-43.
25. Shah M, Jorde UP. Percutaneous mitral valve interventions (repair): current indications and future perspectives. *Front Cardiovasc Med.* 2019;6:88.

**Key Words:** arrhythmia and Barlow valve, Barlow repair, functional anatomy of Barlow valve, mitral valve repair