



Since January 2020 Elsevier has created a COVID-19 resource centre with free information in English and Mandarin on the novel coronavirus COVID-19. The COVID-19 resource centre is hosted on Elsevier Connect, the company's public news and information website.

Elsevier hereby grants permission to make all its COVID-19-related research that is available on the COVID-19 resource centre - including this research content - immediately available in PubMed Central and other publicly funded repositories, such as the WHO COVID database with rights for unrestricted research re-use and analyses in any form or by any means with acknowledgement of the original source. These permissions are granted for free by Elsevier for as long as the COVID-19 resource centre remains active.



# Patient Counseling Through the Pelvicalyceal-shaped Labyrinth: In Search of an Easy Understanding of the Upcoming Stone Removal: A Pilot Study

A. Talyshinskii, B. Guliev, B. Komyakov, and A. Galfano

<b>OBJECTIVE</b>	To investigate the impact of a mobile application (app) displaying a visualization of the internal anatomy of the pelvicalyceal system PCS and of kidney stones on patient understanding of their affected kidney anatomy and their upcoming percutaneous nephrolithotripsy (PCNL).
<b>MATERIALS AND METHODS</b>	One-hundred patients who required PCNL were included in this study, and all patients were non-randomly distributed into 2 groups: counseled using only 3D-reconstructed computed tomography (CT) images (group 1) or using only the “InsKid” app (group 2). Patient data were obtained from CT scans as Digital Imaging and Communications in Medicine format and converted into stereolithography (STL) format. All patients completed the questionnaire after counseling, and the results were compared between groups.
<b>RESULTS</b>	Patients from group 2 better understood the anatomy of their affected kidney by 53%; awareness regarding their stone location was better by 32%; the steps of planned surgery, as well as possible complications, were more transparent for patients using the app by 24% and 56%, respectively. The number of patients who were dissatisfied with the mobile counseling dropped by 70%. The average duration of consultation with the 3D reconstruction of CT images was $10.9 \pm 0.6$ min, while counseling using our program reliably led to a reduction in this duration ( $7.3 \pm 0.5$ min).
<b>CONCLUSION</b>	The InsKid app is a freely available, easy-to-use educational software that improves patient counseling without considerable financial expense or long waiting periods for use. UROLOGY 143: 75–79, 2020. © 2020 Elsevier Inc.

Three-dimensional (3D) printing technology is a significant advancement in the visualization of pathology in organs.<sup>1</sup> Printed 3D models can improve intraoperative navigation, resident education, and patient counselling.<sup>2</sup> The patient is able to hold a model of the organ in question in his or her hand, which

offers advantages over education exclusively using 3D images.<sup>3</sup> However, when it comes to creating a model ready to apply, there may be limitations that constrain the availability of this technology, including production time and manufacturing costs.

To date, the literature contains several articles that describe methods for visualizing the pelvicalyceal system (PCS) in an effective manner, including the use of virtual reality technology.<sup>4,5</sup> Nevertheless, these alternatives usually require relevant experience and sophisticated and prohibitively expensive devices that are not widely available.<sup>6</sup> Given the above, displaying 3D images with both an exterior and interior view of the PCS using widespread electronic devices, such as smartphones, without cumbersome resources could facilitate the understanding of PCS anatomy for upcoming kidney stone surgery. Herein, we present the “InsKid” application (app) for devices based on the Android operating system, displaying 3D intraluminal reconstruction of the kidney’s PCS from an intraoperative perspective.

Information about authors: Komyakov Boris – MD, Professor of Urology, the head of the Department of Urology of North-Western State Medical University named after I.I. Mechnikov. Senior urologist of Saint Petersburg. Tel +79219125289. Guliev Bakhman – MD, Professor of Urology, the head of the Urology Center with robot-assisted surgery of the Mariinsky Hospital. Tel: +79219453480. Galfano Antonio – MD, PhD, Department of Urology, Niguarda Hospital. Tel.: +39 02 64444617.

Talyshinskii Ali – undergraduate student. Tel. +79045130436.

**Conflict of interest:** None.

From the Department of Urology, North-Western State Medical University, Saint Petersburg, Russia; the Urology Center, Mariinsky Hospital, Saint Petersburg, Russia; and the Department of Urology, ASST Grande Ospedale Metropolitano Niguarda, Milan, Italy

Address correspondence to: Talyshinskii Ali, undergraduate student, North-Western State Medical University, Piskarevskiy pr. 47, Saint Petersburg, 195067, Russia. E-mail: ali-ma@mail.ru

Submitted: January 16, 2020, accepted (with revisions): April 29, 2020

## MATERIALS AND METHODS

Prospectively, from December 2018 to December 2019, after InsKid received institutional ethical committee approval, 100 patients with primary staghorn stones who underwent percutaneous nephrolithotripsy (PCNL) were consecutively recruited. Patients with the recurrent stones were not included since they may already be familiarized to the upcoming procedure. All patients provided informed consent and were equally and alternately distributed into 2 groups, namely, counseled with only 3D-reconstructed computed tomography (CT) images (group 1) or with the InsKid app (group 2). Patient demographics from both groups were compared to clarify probable bias caused by nonrandom allocation.

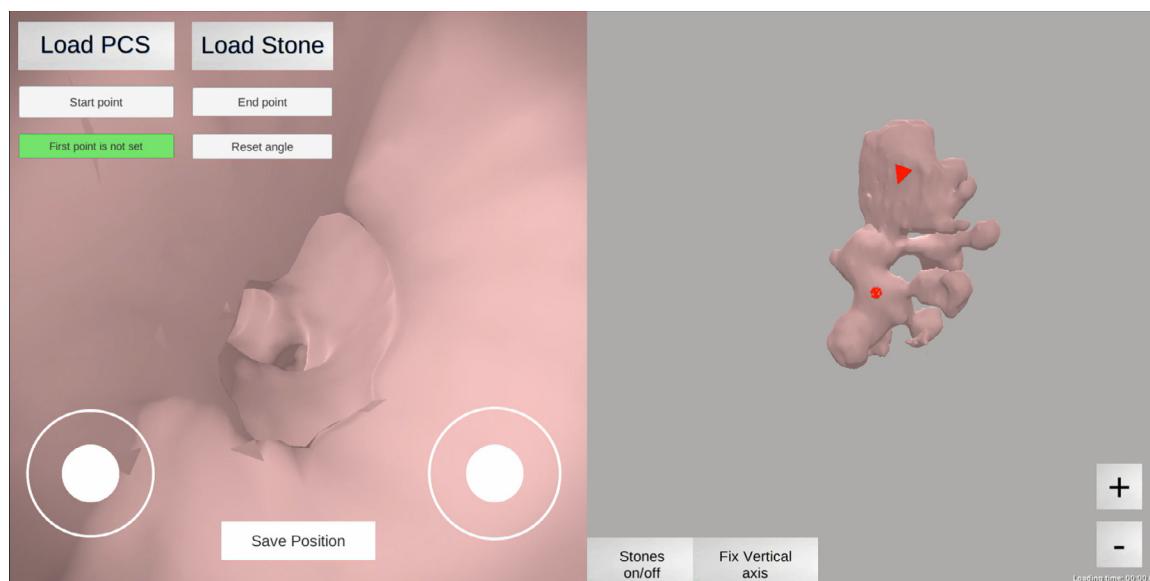
To define the influence of the complexity of the renal collecting system on the results, all of the PCSs were categorized according to the classification proposed by Sampaio, in which the pelvicalyceal patterns were grouped into 2 types, A and B. These were subdivided into AI, AII, BI, and BII. In type AI, there were two major calyces, one from each of the upper and lower poles, with middle zone drainage dependent on either or both of them. In type AII, the drainage was similar to AI, but with crossing calyces in the middle zone. In BI, there was a separate calyx draining the middle zone that was not connected to either the upper or lower pole calyceal groups. In BII, the middle zone was drained by 1-4 minor calyces that drain directly into the renal pelvis. Data acquisition was performed using a 64-row CT unit with the 0.5 mm step intervals SOMATOM Definition AS (Siemens, Germany). The CT data of patients from group 2 were extracted and saved in stereolithography (STL) format. This process was performed using RadiAnt Digital Imaging and Communications in Medicine Viewer software and had a <2 min duration for each PCS unit.

The main desktop of InsKid consisted of two parts—left and right—displaying the inside and outside 3D view of PCS,

respectively (Fig. 1). The user can navigate between anatomical levels of the PCS using a joystick or by touching the specified location on the exterior view. Regardless of the position, it is possible to toggle between showing and hiding the stone. A specific questionnaire was designed to determine the InsKid value for patient counseling (Fig. 2), and the duration of counseling was measured and compared between groups. After the intervention, all patients were asked whether they had any additional questions about the surgery. The null hypothesis was the inability of InsKid to improve a patient's awareness of the crucial considerations of upcoming surgery. Statistical significance was set at  $P = .05$ . The mean values for continuous variables were compared using the Wilcoxon test. A Chi-squared test was used to compare frequencies and proportions. Statistical analyses were performed using SPSS v.22.0 software.

## RESULTS

Patient demographics, stone size, and PCS type according to Sampaio classification are shown in Table 1. Regardless of the non-random allocation approach, no significant differences were found between groups with respect to age, male-to-female ratio, and PCS type. Interestingly, that mean stone size was larger in group 2. The maximum total score for each quantitative question was 250. Patients from group 2 were found to show better understanding of the anatomy of the affected kidney by 53% relative to group 1 ( $P = .003$ ); awareness regarding their stone was better by 32% ( $P = .017$ ); the steps of planned surgery were more transparent by 24% ( $P = .023$ ); and the possible complications were more evident by 60% ( $P = .001$ ). The number of patients who were unsatisfied and desired better counseling was reduced by 70% (38 vs 3,  $P = .006$ ). The average duration for patient consultation with the 3D-reconstructed CT images was  $10.9 \pm 0.6$  min, while counseling using InsKid reliably led to a decrease



**Figure 1.** The main desktop of the InsKid app that consists of left and right parts displaying the internal and external 3D view of the PCS, respectively. In the upper left corner are located 2 buttons that load PCS and the stone location onto the screen. Along the lower border of the left window, which corresponds to the internal view of the PCS, are placed 2 joysticks responsible for navigating around the physician's axis (left) and in all directions (right). There are 2 buttons along the lower border of the right window responsible for the next functions: (1) "stones on/off" to hide or show the kidney stones at any time, (2) "fix vertical axis" to rotate the PCS around it. (Color version available online.)

Questions	Score				
	1	2	3	4	5
Understanding of anatomy					
Understanding of stone's localization					
Understanding of planned surgery					
Understanding of possible complications					
Is better counselling necessary?	YES			NO	

**Figure 2.** Patient questionnaire consisting of 4 quantitative items and 1 qualitative question. (Color version available online.)

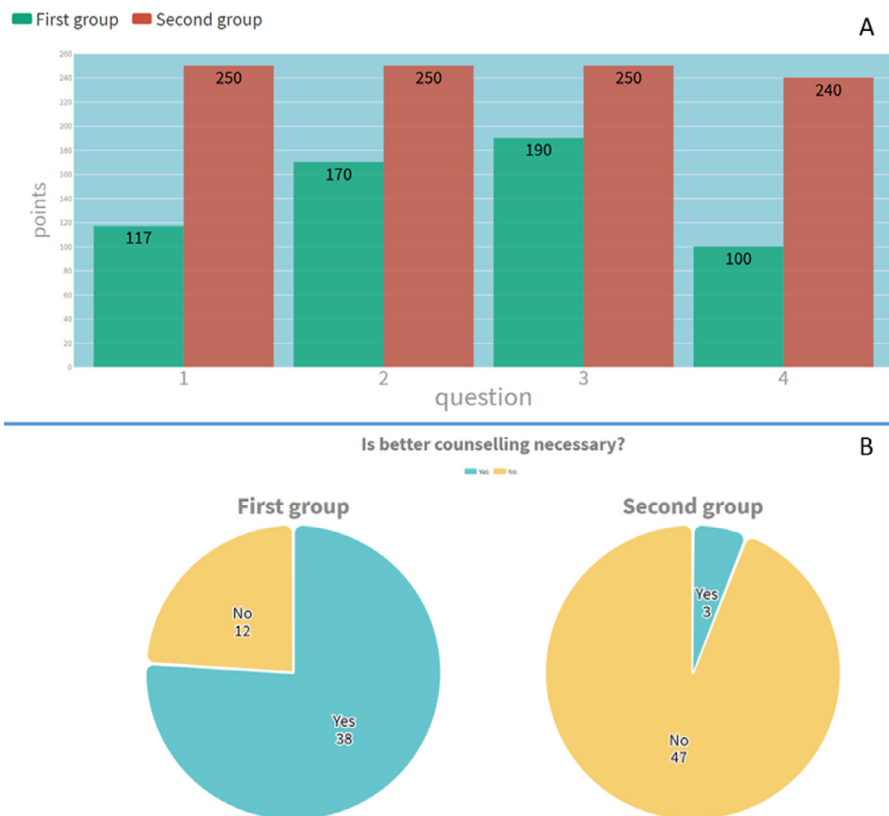
**Table 1.** Patient demographics, stone size and PCS type according to Sampaiu's classification

Feature	1 Group	2 Group	P Value
Age, year (mean ± sd)	48 ± 1.4	49 ± 1.9	.7
Male-to-Female ratio	32/18	27/23	.4
Stone size, mm	44 ± 1.2	48 ± 1.5	.02
PCS type (AI/All/BI/BII)	34/11/4/1	30/14/3/3	.12

in this duration ( $7.3 \pm 0.5$  min;  $P = .001$ ). When asking patients after the intervention, the patient counseled through InsKid was found to show significant decreases in any remaining matters after surgery ( $P = .001$ ; Fig. 3).

## DISCUSSION

Currently, 3D-printing technology is widely used in medicine and reduces the complexity of the PCNL through preoperative planning and intraoperative navigation. It



**Figure 3.** Total scores for patients from groups 1 and 2. (A) The total point for quantitative questions. (B) The distribution of patients according to the qualitative question. (Color version available online.)

allows young specialists to acquire necessary experience, as printed models allow for simulation of the main steps in a given surgery, thereby improving the learning curve. It may also be capable of improving patient-physician consultations, because the patient is better able to visualize and understand the surgical process.<sup>7-11</sup>

Spatial perception is essential during minimally invasive procedures such as PCNL or retrograde intrarenal surgery.<sup>12-14</sup> The methods used to create reference tools for kidney stone surgery are prospective; these were explored in several articles. Gadzhiev et al<sup>15</sup> described an experience of making plasticine replication of the PCS. According to their preliminary results, plasticine biomodeling was very useful in the treatment of complex renal stone by PCNL, which offers clear benefits for planning the surgery. More relevant to our topic, Yoshida et al<sup>6</sup> assessed the navigation system to improve the performance of ureteroscopic manoeuvres and defined its ability to maintain spatial orientation. Their device used a magnetic tracking device to detect the position of the ureteroscope and display it via 3D imaging. The results indicated that using the proposed navigation system improved the accuracy rate of marked calyce identification, time exposed to simulated fluoroscopy, and migration length of the tip of the ureteroscope, among surgeons with a wide range of expertise.

During counseling, the patients should receive a simplified, easy-to-understand description of all aspects of their upcoming procedure.<sup>16</sup> In modern times, many specialists assume that visualization using only external 3D images based on CT data is not suitable to maximize the patient's understanding.<sup>17</sup> 3D-printing technology is one avenue for solving this problem.<sup>18</sup> Porpiglia et al<sup>19</sup> assessed the face and content validity of virtual, 3D-rendered printed models used before robot-assisted prostate cancer surgery and nephron-sparing surgery. Eighteen patients were enrolled, including 8 undergoing robot-assisted radical prostatectomy and 10 undergoing minimally invasive partial nephrectomy. For each patient, a virtual 3D-printed model was created and shared with the patient in question. All patients provided favorable feedback (9-10 on a 10-point Likert scale) about the inclusion of this technology during the case discussion with the surgeon.

Atalay et al<sup>20</sup> described the results of patient counseling using 3D-printed models of the PCS. Five patients with a unilateral staghorn renal stone and clinical indication of percutaneous nephrolithotomy were selected. The process of creating all 5 models required 2 attempts. The consumable costs of the model comprised USD ~\$100, and the printing duration for the 3D model was ~2 hours.

The promising idea of combining 3D-printing technology with intraluminal PCS visualization was proposed by Guliev et al<sup>21</sup>. The 3D-printed segmented collapsible models of the PCS were used as a reference tool to improve the learning curve of the residents. The definition of the precise number of calyces in each calyces group, as well as their orientation, was superior in the group of residents provided with printed models. To

manufacture 1 such collapsible colored model costs \$100 USD and consumes 6 hours.

Despite obvious advantages, the main limitations of this technology cannot be overlooked. In the literature, the shortest duration to manufacture a 3D PCS model was 2 hours; however, this may require more than one attempt, which could increase manufacturing time. The second drawback of printed kidney collecting system models is cost. To the best of our knowledge, only a small number of articles explore the usefulness of printed PCS models as reference tools, where the cost was approximately USD \$100 for 1 model. As mentioned, any unsuccessful attempts will raise the final production costs.

From our perspective, the InsKid app is not subject to the disadvantages of printed models. The cost was USD \$800, and the conversion of the CT images into STL format lasted nearly 2 min, which can be further reduced as experience rises. Soon, this software will be available for free download in the AppStore and GooglePlay, thereby removing any financial barriers to the incorporation of InsKid into clinical practice. The net cost of using InsKid is ultimately lower than that of 3D-printing technology, since no expenses are incurred other than the initial manufacturing cost.

Helpfully, many patients offered suggestions on ways in which InsKid could be applied. For example, 1 patient suggested to incorporate it during the operation itself to help the surgeon navigate within the cavity. Another patient suggested producing personalized booklets for each patient that includes an external and internal view of the PCS.

Our paper has several limitations. The main obstacle when using InsKid is the initial quality of the CT data. However, the same problem contributes to the unavailability of 3D-printed models; therefore, it is not specific to our program. We did not include any patients that had no indications for the surgical treatment or patients who have indications for either retrograde intrarenal surgery or extracorporeal shock wave lithotripsy. Also, it should be mentioned that, despite being overlooked here, the app could prove useful in other scenarios, such as surgeon education and reduction of operating time by use of intraoperative navigation. For instance, as with the current use of fusion MRI in prostate biopsy, it would be logical to generate a fusion of the CT or MRI images intraoperatively with the imaging being used for PCS puncture, such as ultrasound or fluoroscopy, that should allow easier access and improve the surgery's outcomes in terms of, for example, operative time and patient morbidity. Also, visualization of the interior view of the kidney collecting system could be accomplished by the latest technology, such as augmented reality. We are refining our software for use in the operative room; these results will be published in the near future.

## CONCLUSION

Detailed and case-specific understanding of surgical anatomy represents a key point for tailored treatment planning. Many studies have shown that 2D and 3D imaging

may not be optimal to convey information to patients most effectively regarding their disease, surgery, or risk of complications. To improve patient counseling, we created a unique software program that does not have the drawbacks associated with resources needed for 3D printing.

**Acknowledgments.** None.

## SUPPLEMENTARY MATERIALS

Supplementary material associated with this article can be found in the online version at <https://doi.org/10.1016/j.urology.2020.04.114>.

## References

1. Wrazidlo W, Brambs HJ, Lederer W, Schneider S, Geiger B, Fischer C. An alternative method of three-dimensional reconstruction from two-dimensional CT and MR data sets. *Eur J Radiol.* 1991;12:11–6.
2. Costello JP, Olivieri LJ, Su L, et al. Incorporating three-dimensional printing into a simulation-based congenital heart disease and critical care training curriculum for resident physicians. *Congenit Heart Dis.* 2015;10:185–190.
3. Liaw C-Y, Guvendiren M. Current and emerging applications of 3D printing in medicine. *Biofabrication.* 2017;9:024102.
4. Checcucci E, De Cillis S, Porpiglia F. 3D-printed models and virtual reality as new tools for image-guided robot-assisted nephron-sparing surgery. *Curr Opin Urol.* 2019;1:142–146.
5. Parkhomenko E, O'Leary M, Safiullah S, et al. Pilot assessment of immersive virtual reality renal models as an educational and preoperative planning tool for percutaneous nephrolithotomy. *J Endourol.* 2019;33:283–288.
6. Yoshida K, Yokomizo A, Matsuda T, et al. The advantage of a ureteroscopic navigation system with magnetic tracking in comparison with simulated fluoroscopy in a phantom study. *J Endourol.* 2015;29:1059–1064.
7. Petretta M, Desando G, Grigolo B, Roseti L. 3D printing of musculoskeletal tissues: impact on safety and health at work. *J Toxicol Environ Health A.* 2019;82:891–912.
8. Harb SC, Rodriguez LL, Vukicevic M, Kapadia SR, Little SH. Three-dimensional printing applications in percutaneous structural heart interventions. *Circ Cardiovasc Imaging.* 2019;12:e009014.
9. Tack P, Victor J, Gemmel P, Annemans L. 3D-printing techniques in a medical setting: a systematic literature review. *Biomed Eng Online.* 2016;15:115.
10. Porpiglia F, Amparore D, Checcucci E, et al. Current use of three-dimensional model technology in urology: a road map for personalised surgical planning. *Eur Urol Focus.* 2018;4:652–656.
11. Srisubat A, Potisat S, Lojanapiwat B, Setthawong V, Laopaiboon M. Extracorporeal shock wave lithotripsy (ESWL) versus percutaneous nephrolithotomy (PCNL) or retrograde intrarenal surgery (RIRS) for kidney stones. *Cochrane Database Syst Rev.* 2014:CD007044. <https://doi.org/10.1002/14651858.CD007044.pub2>.
12. Kumsar Ş, Aydemir H, Halis F, Köse O, Gökçe A, Adsan O. Value of preoperative stone scoring systems in predicting the results of percutaneous nephrolithotomy. *Cent Eur J Urol.* 2015;68:353–357.
13. Miller NL, Matlaga BR, Lingeman JE. Techniques for fluoroscopic percutaneous renal access. *J Urol.* 2007;178:15–23.
14. Andonian S, Scoffone CM, Louie MK, et al. Does imaging modality used for percutaneous renal access make a difference? A matched case analysis. *J Endourol.* 2013;27:24–28.
15. Gadzhiev N, Brovkin S, Grigoryev V, Tagirov N, Korol V, Petrov S. Sculpturing in urology, or how to make percutaneous nephrolithotomy easier. *J Endourol.* 2015;29:512–517.
16. Audit commission for local authorities and the national health service in England and Wales. *What seems to be the matter : communication between hospitals and patients.* H.M.S.O; 1993.
17. Hess B. Renal stone clinic survey: calcium stone formers' self-declared understanding of and adherence to physician's recommendations. *Urolithiasis.* 2017;45:363–370.
18. Guarino J, Tennyson S, McCain G, Bond L, Shea K, King H. Rapid prototyping technology for surgeries of the pediatric spine and pelvis: benefits analysis. *J Pediatr Orthop.* 2007;27:955–960.
19. Porpiglia F, Bertolo R, Checcucci E, et al. Development and validation of 3D printed virtual models for robot-assisted radical prostatectomy and partial nephrectomy: urologists' and patients' perception. *World J Urol.* 2018;36:201–207.
20. Atalay HA, Canat HL, Ülker V, Alkan İ, Özkuvanci Ü, Altunrende F. Impact of personalized three-dimensional -3D- printed pelvicalyceal system models on patient information in percutaneous nephrolithotripsy surgery: a pilot study. *Int Braz J Urol.* 2019;43:470–5.
21. Guliev B, Komyakov B, Talyshinskii A. The use of the three-dimensional printed segmented collapsible model of the pelvicalyceal system to improve residents' learning curve. *Turk J Urol.* 2019; 18:1–5.