

Pretty peachy

Case

An 83-year-old Caucasian woman with decreasing vision for 5 years was referred for a macular mass in the left eye (OS). She was a known hypertensive with no other significant systemic complaints. Surgical history included two previous breast biopsies, both of which were negative. On ocular examination, best-corrected visual acuity was 20/20 in the right eye (OD) and 20/50 OS. Intraocular pressures were normal. She was pseudophakic with bilateral peripheral iridotomies. There was an elevated orange choroidal lesion in the macula (white arrow) and a small choroidal nevus inferiorly OS (black arrow) (a). There was no overlying drusen, hemorrhage, lipid exudation, or edema.

What is Your Next Step?

- Photodynamic therapy to the choroidal hemangioma.
- Computed tomography scan of the chest and abdomen to look for a primary tumor.
- Plaque brachytherapy.
- Perform fluorescein and indocyanine green angiography (FA, ICGA) for further investigation.

Findings

The lesion was 2.65 mm thick and acoustically solid on ultrasonography. Fundus autofluorescence demonstrated central hypoautofluorescence surrounded by a halo of hyperautofluorescence (b). Fluorescein angiography showed early central hypofluorescence surrounded by stippled hyperfluorescence and late ring-like staining. ICGA revealed early hypocyanescence and late geographic hypercyanescence (c). Optical coherence tomography (OCT) showed a large subfoveal pigment epithelial detachment (PED) and smaller surrounding PEDs without subretinal fluid (d). Heterogenous hyperreflective signals were present along the inner roof of the large PED, and the choroid was flat [Fig. 1]. A fibrovascular PED associated with age-related macular degeneration (ARMD) was diagnosed and intravitreal bevacizumab was advised.

Diagnosis

Large fibrovascular PED secondary to ARMD OS.

Correct Answer: D.

Discussion

A fibrovascular PED represents Type 1 choroidal neovascular membrane (CNVM) separating the retinal pigment epithelium (RPE) from Bruch's membrane, frequently secondary to ARMD.^[1] The dome-shaped mass was yellow-orange in color, clinically mimicking choroidal hemangioma, metastasis, or amelanotic melanoma. PEDs account for 5% of pseudomelanomas.^[2] Melanoma often reveals "double circulation" on FA and hemangioma typically shows early hypercyanescence with late washout on ICGA.^[3] PEDs demonstrate stippled hyperfluorescence and late staining on FA. Variably delineated late hypercyanescence on ICGA suggests regressed CNVM. OCT localizes fibrovascular PEDs to the sub-RPE space. Therefore, multimodal imaging was essential for accurate diagnosis.

Declaration of patient consent

The authors certify that they have obtained all appropriate patient consent forms. In the form the patient(s) has/have given his/her/their consent for his/her/their images and other clinical information to be reported in the journal. The patients understand that their names and initials will not be published and due efforts will be made to conceal their identity, but anonymity cannot be guaranteed.

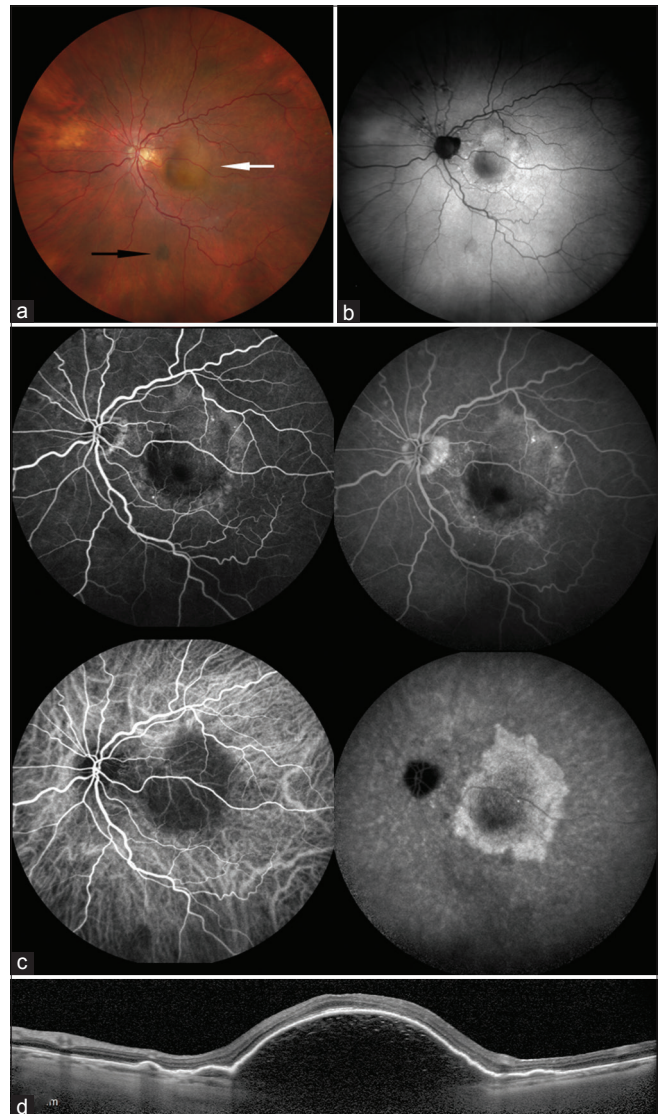
Financial support and sponsorship

Support provided in part by the Eye Tumor Research Foundation, Philadelphia, PA (CLS), an unrestricted grant from Research to Prevent Blindness, Inc. (LAD), and the Heed Ophthalmic Foundation (LAD). The funders had no role in the design and conduct of the study, in the collection, analysis, and interpretation of the data, and in the preparation, review, or approval of the manuscript.

Carol L. Shields, MD has had full access to all the data in the study and takes responsibility for the integrity of the data and accuracy of the data analysis.

Conflicts of interest

There are no conflicts of interest.



References

- Mrejen S, Sarraf D, Mukkamala SK, Freund KB. Multimodal imaging of pigment epithelial detachment, A guide to evaluation. *Retina* 2013;1735-62.
- Shields JA, Mashayekhi A, Ra S, Shields CL. Pseudomelanomas of the posterior uveal tract: The 2006 Taylor R. Smith Lecture. *Retina* 2005;25:767-71.
- Shields JA, Shields CL. Vascular tumours and malformations of the uvea. In Shields JA, Shields CL. *Intraocular Tumors. An Atlas and Textbook*. 3rd ed. Philadelphia, PA: Lippincott Walters Kluwer; 2016. P 247-8.

Li-Anne Lim, Basil K Williams Jr., Carol L Shields

Ocular Oncology Service, Wills Eye Hospital, Thomas Jefferson University, 840 Walnut Street, 14th Floor, Philadelphia, PA, 19107, USA

Correspondence to: Dr. Carol L Shields,
Ocular Oncology Service, 840 Walnut Street, Suite 1440,
Philadelphia, PA 19107, USA.
E-mail: carolshields@gmail.com

This is an open access journal, and articles are distributed under the terms of the Creative Commons Attribution-NonCommercial-ShareAlike 4.0 License, which allows others to remix, tweak, and build upon the work non-commercially, as long as appropriate credit is given and the new creations are licensed under the identical terms.

For reprints contact: reprints@medknow.com

Cite this article as: Lim LA, Williams Jr. BK, Shields CL. Pretty peachy. *Indian J Ophthalmol* 2018;66:1238.

Access this article online

Quick Response Code:



Website:

www.ijo.in

DOI:

10.4103/ijo.IJO_948_18