

Fate of bone grafting for acetabular defects in total hip replacement

Anil Thomas Oommen, Vignesh Prasad Krishnamoorthy, Pradeep Mathew Poonnoose, Ravi Jacob Korula

ABSTRACT

Background: The use of allografts and autografts in the management of acetabular defects have been reported with varying results. Trabecular metal is an expensive option in the management of these defects. This study aims to assess the fate and efficacy of bone grafting for acetabular bone defects in total hip arthroplasty.

Materials and Methods: A total of 30 hips in 28 patients with acetabular deficiencies were treated with bone grafting and total hip replacement (THR). Seventeen hips had American Academy of Orthopedic Surgeons (AAOS) type 2 (Paprosky type 2c) deficiency and 13 had AAOS type 3 (Paprosky type 3a) defects of the acetabulum. Allografts were used in 15 patients and autografts were used in the remaining 13. Cemented total hip arthroplasty was done in 18 hips and uncemented THR in 12. Seven patients underwent the procedure for, acetabular erosion and symptoms following hemiarthroplasty (4 out of 7), or, acetabular revision for failure (3 out of 7) following total hip arthroplasty. Acetabular deficiencies in other patients were due to posttraumatic causes, advanced primary hip arthritis and second stage treatment of postinfective arthritis. A mesh was used in 6 hips and screws were used in 13 hips for graft fixation.

Results: Patients were followed up clinicoradiologically for a period of 10 months to 4 years (mean 23.4 months). One patient required staged revision due to infection. Two patients had early asymptomatic cup migration. One patient had graft lysis and change in cup inclination with persistent pain. He was not keen on further intervention at last followup. Other patients were pain free at the time of followup with radiographs showing maintenance of graft and implant position.

Conclusion: Bone grafting is a suitable option in the management of acetabular defects in total hip arthroplasty, especially in resource challenged countries.

Key words: Acetabulum, bone grafts, defects, protrusio, reconstruction

MeSH terms: Acetabulum, replacement, hip, grafting, bone

INTRODUCTION

Total hip replacement (THR) is the accepted methodology of treatment for patients with advanced hip arthritis limiting their daily activities. According to the National Joint Registry there were approximately 89,000 hip replacements carried out in the United Kingdom during the year 2012 and more than 250,000 hip replacements in the United States during the same period with these numbers

showing a steady increase over the years.¹ There are a significant number of patients who present with advanced arthritis and associated bone deficiencies at our center warranting augmentation procedures. Large defects of the acetabulum are seen in complex primary hips usually due to late presentation in inflammatory arthritis, postinfective or posttraumatic sequelae. Revision procedures are associated with the management of various defects in the acetabulum. The bony defects in the acetabulum can be managed with bone grafts including autografts or allografts.²⁻⁷

Bone grafts can be used in conjunction with cemented all polyethylene cups, cementless implants as well as reinforcement rings and cages. Long term survival of bone grafts for defects in the acetabulum have been reported to vary from 84% at 8 years to 52% at 25 years.^{8,9} 10- and 20-year cup survivorship for bone grafting with cementless and cemented implants varied from 88% to 36% in a recent series.¹⁰ Porous metal cups along with augments made of trabecular metal is another method to reconstruct bone loss within the acetabulum.^{2,11,12} Although, these are widely available, the use of modular cups and augments are limited by costs.¹¹ Majority of patients with acetabular defects are in

Department of Orthopaedics, Unit 2, Christian Medical College and Hospital, Vellore, Tamil Nadu, South India

Address for correspondence: Prof. Anil Thomas Oommen, Department of Orthopaedics, Unit 2, Christian Medical College and Hospital, Vellore - 632 004, Tamil Nadu, South India.
E-mail: lillyanil@cmcvellore.ac.in

Access this article online	
Quick Response Code:	Website: www.ijoonline.com
	DOI: 10.4103/0019-5413.152462

the younger age group and would need restoration of bone stock keeping in mind the likely need for a future revision.

We studied the fate of bone grafts in the management of acetabular defects seen during complex primary and revision hip replacements.

MATERIALS AND METHODS

30 hips in 28 patients with acetabular defects were managed at our unit between January 2006 and November 2010. All the patients had routine anteroposterior radiographs of the pelvis and lateral views of the involved hip to assess the defect

Allografts were prepared from femoral heads stored at -70° . The heads were thawed, decorticated and used as large blocks or 10 mm pieces. The planned procedure as well as the potential risks with the use of allografts had been explained in detail to all the patients. All the autografts were taken from the patient's own femoral head at the time of total hip arthroplasty. An Institutional Review Board approval was obtained for this study.

The defects in the acetabulum were classified using the American Academy of Orthopedic Surgeons (AAOS) classification. Seventeen patients had AAOS type 2 (Paprosky type 2c) deficiency and 13 had AAOS type 3 (Paprosky type 3a) defects of the acetabulum. Allografts were used in 13 patients and autografts in the other 17 hips. Ten out of 30 hips had medial wall defects. The medial wall defects in six of these ten hips with protrusion were augmented with a mesh. Cortical screws were used to stabilize the grafts in 13 patients. Grafts in other hips were stabilized in the contained defect itself with the implant in the acetabulum and did not require additional fixation. The surgical approach was a lateral approach in 28 hips and two hips had a posterior approach. One patient had a fracture dislocation of the hip with an acetabular wall fracture, which was treated by open reduction and internal fixation at another center and subsequently developed infection. He underwent stage 1 debridement, implant removal and spacer and required posterior wall reconstruction for hip replacement. Cemented THR was performed in 18 hips and cementless implantation was used in other 12 hips Polyethylene Ogee cups (Depuy Inc, Warsaw, USA) were implanted for cemented fixation and Duraloc (Depuy Inc, Warsaw, USA) cups were used in 10 cementless hips. Cementless fixation in 2 hips were done with Pinnacle (Depuy Inc, Warsaw, USA) cups.

The acetabular deficiencies were secondary to rheumatoid arthritis in three, ankylosing spondylitis in two, posttraumatic

secondary degenerative arthritis in six [Figure 1] and other disorders in six patients.

RESULTS

There were 16 males and 12 females. The mean age of the patients was 53 years (range 33-75 years).

The procedure was carried out as a primary surgery in 17 patients. Four patients had a revision for symptomatic postoperative hemiarthroplasty and three had revision of aseptic loose acetabular component of a THR [Figure 2]. The procedure was performed as a second stage revision in four hips following a 1st stage revision (debridement) and a cement spacer for infection following internal fixation for trauma. The other two hips were treated for chronic infection of the hip with a stage 1 debridement. Infection was ruled out in these hips prior to the reconstruction. This was done by C-reactive protein and erythrocyte sedimentation rate assessment as well as intraoperative tissue smears for leukocytes.

Followup in all patients ranged from 10 months to 4 years with a mean of 23 months. All patients were advised partial weight bearing for 6-12 weeks and gradually progressed to full weight bearing depending on radiological evidence of graft healing and union. The nonparametric Kolmogorov-Smirnov test to assess the difference between preoperative Harris Hip score (HHS) and the HHS at followup. All patients were satisfied at the last followup with significant improvement in their quality of life. The mean preoperative HHS was 31.04 with a standard deviation of 10.23, on followup the mean HHS improved to 78.00 with a standard deviation of 6.32. The difference between the scores is statistically significant ($P < 0.05$).

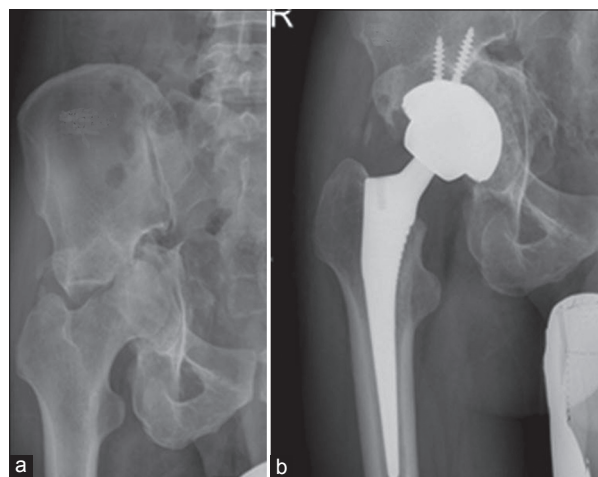


Figure 1: Preoperative X-ray showing (a) posttraumatic arthritis with large Paprosky type 2c defect in a 34-year-old male (b) postoperative X-ray at 1 year 6 months showing graft consolidation

One patient had a dislocation at 3 weeks which was treated successfully by closed reduction [Table 1]. He had a fracture of the greater trochanter which healed with conservative management. The patient had a good outcome at the last followup. One patient required staged revision due to infection. This patient had bone grafting with total hip arthroplasty as a second stage revision. He had sustained a hip fracture dislocation which was treated elsewhere with open reduction and internal fixation. Both clinical and radiological signs of infection were evident at presentation. The first stage of treatment involved removal of the implants, excision arthroplasty and a cement spacer. He was administered 6 weeks of antibiotics and a second stage hip replacement was carried out 10 weeks after the debridement. He had radiological evidence of graft resorption with cup migration at 18 months. He subsequently underwent staged revision using bone grafts augmented with an acetabular cage. At 2 years postoperative he is clinically doing well with radiological evidence of graft integration [Figure 3].

A 37-year-old man had aseptic loosening of the acetabular component of a THR done 8 years prior to presentation. He presented with a malunited childhood fracture shaft femur and the femoral component of the prior THR appeared well fixed radiologically and on intraoperative assessment. Bone grafting with allograft and screw fixation was performed followed by revision of the acetabulum with a cemented cup. At 4 years followup, he is symptom free and the graft was radiologically well incorporated [Figure 4].

The followup radiographs were assessed for signs of graft union, radiolucent zones as well as change in position of the acetabular component on comparison with the immediate postoperative X-rays. Standard anterior-posterior and lateral radiographs were used for assessment of the three zones described by DeLee and Charnley.¹³ Acetabular component loosening was defined as change in component inclination, cup migration >5 mm or bone implant interface demarcation >2 mm in any of the zones.

3 patients had radiological changes in inclination of the cup. One patient with bone grafting and a cemented acetabulum for a defect has lysis with change in cup inclination by 15°, 4 years after the procedure. She has some persistent pain and does not want further intervention. She had been advised to come for regular followup. Two patients with cemented acetabular component had change in cup inclination by 10° at 6 months with no symptoms. Both patients had no subsequent change in position and continue to remain clinically active.

Table 1: Outcome (n=30)

Outcomes	Number of hips (%)
Complications	
Dislocation at 3 weeks with greater trochanter fracture. Treated by closed reduction	1
Graft outcome	
Graft position unchanged	26 (86.7)
Initial change in cup inclination	2 (6.7)
Lysis/resorption of the graft-no further intervention	1 (3.3)
Graft resorption-revision carried out	1 (3.3)

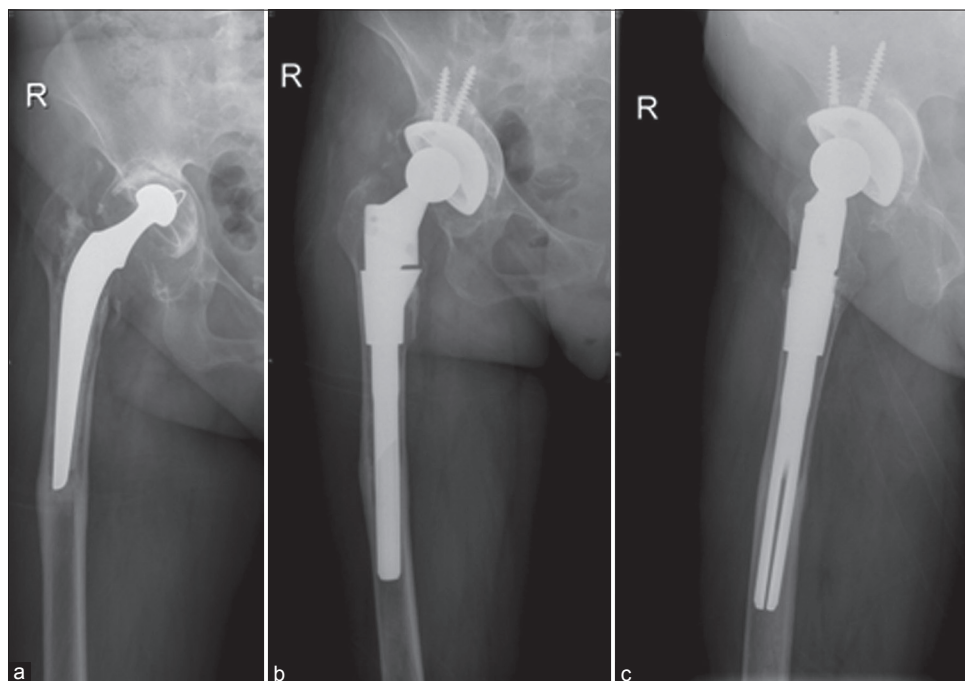


Figure 2: Preoperative radiograph (R) hip with thigh showing (a) loosening and Paprosky type 2c defect 17 years post total hip replacement in a 56-year-old lady (b) Followup at 1 year postoperative lateral (c) showing graft integration

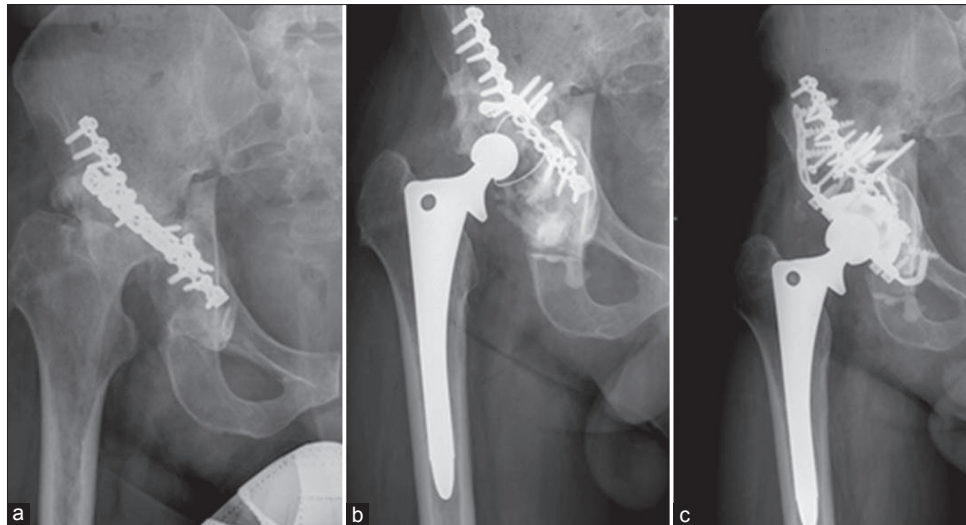


Figure 3: Preoperative X-ray of (R) hip joint showing (a) with infected acetabular implant *in situ* (b) failure of staged cemented acetabular implant with bone graft for defect (c) 2 years postoperative staged acetabular reconstruction with bone graft

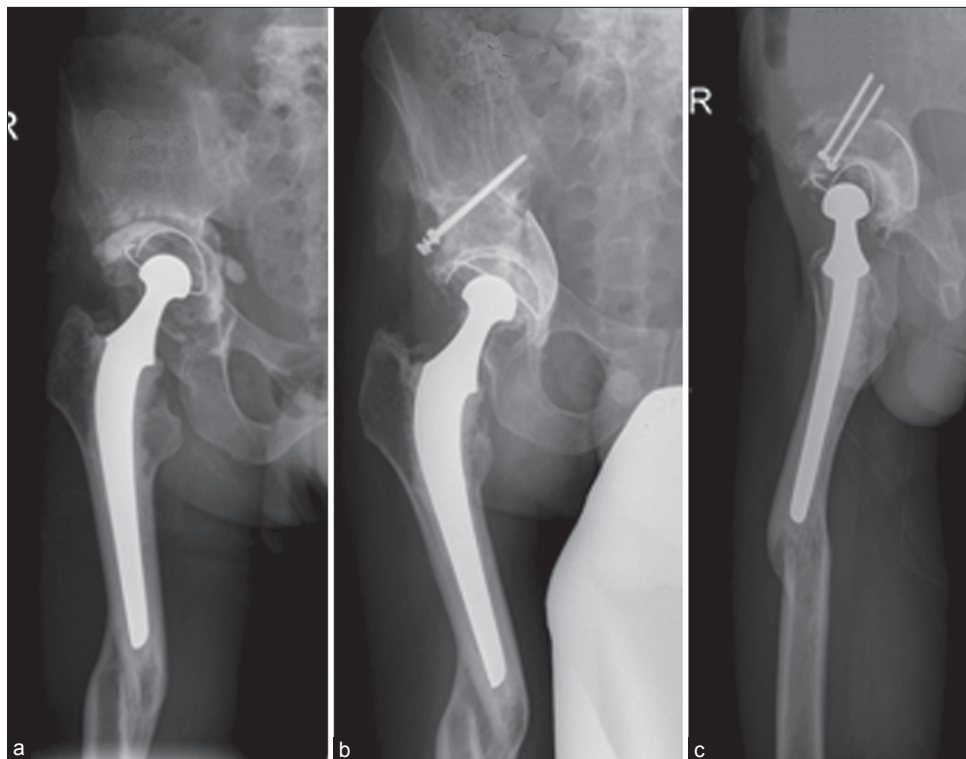


Figure 4: Preoperative X-ray (R) hip joint with thigh showing (a) aseptic loosening and Paprosky type 3a defect 6 years postoperative total hip replacement in a 37 year old male (b) 4 years followup (c) lateral view showing consolidation

In summary, 26 of 30 hips have had a desirable outcome at the last followup. Three patients (10%) had an undesirable outcome (change in cup position, lysis) and 1 hip (3.3%) had graft resorption requiring subsequent revision ($P < 0.001$) [Table 1].

DISCUSSION

Total hip replacement in patients with significant

acetabular defects is challenging and requires bone grafting for acetabular augmentation. The use of bone graft to augment defects in the acetabulum have been described for cemented as well as cementless hips.³⁻⁵ There were 10 hips with protrusio in our series secondary to trauma, rheumatoid arthritis, ankylosing spondylitis and postseptic sequelae. McCollum *et al.* reported a series of 32 patients with medial wall protrusio reviewed for 2-8 years following bone grafting of the acetabulum and

THR. The medial defect was protected with a mesh and this was followed by bone grafting and cement fixation of the acetabular component. There was radiological evidence of union in all cases at 3 months.⁴ Similar results were reported by Slooff *et al.* in a series of 40 hips with medial protrusion treated in the same manner.⁵ An 11-year followup in 35 hips with acetabular defects managed with bone grafting to optimize coverage for THR was documented to have good results.⁶

Recent evidence shows that long term survivorship of impaction bone grafting with meshes have variable outcomes with a failure rate of 12-28%.^{14,15} One of the 30 hips in our series had a poor outcome. The bone grafts used in this cemented hip (with a history of prior infection) had graft resorption with cup migration. Infection was ruled out at the subsequent staged revision. Two other hips had early nonprogressive cup migration and one hip had lysis in zone one with pain in the hip. This may have occurred due to incomplete graft integration. The cemented acetabulum with a 2 mm lytic demarcation in zone one 3 years after the procedure with persistent low grade pain, refused further intervention. These 3 hips need followup to assess the long term outcome.

Cementless hips using trabecular metal cups with or without augments provide good stability with biologic fixation. The use of trabecular metal augments over the past few years has gained fairly widespread acceptance for the management of defects in the acetabulum. Satisfactory results has been reported with a 10 year followup for defects treated with trabecular metal augments and cemented THR.^{12,16} The costs involved in the manufacturing process as well as additional financial burden are significant limiting factors in the use of these highly porous metal cups along with augments.

Cementless implants with bone grafts in the management of acetabular defects were described following variable outcomes associated with cemented fixation (failure rates up to 42%).^{7,10,17,18} 10 and 20 year cup survivorship for bone grafting with cementless and cemented implants varied from 88% to 36% in the same series.¹⁰ However, the use of large cementless cups for defects seen during revisions appear promising.^{18,19}

Defects in the acetabulum which have approximately 50% of host bone contact can be treated with cementless cups with screws for added stability.¹⁹ In our series, there were defects which had 40-50% host bone contact in almost all hips at the final implantation. We hope to have achieved some restoration of the bone stock keeping in mind the need for a future revision especially in the younger individual.

This small series has its own limitations. In our series, we have used cementless as well as cemented implants. This series includes patients with defects of the acetabulum due to different etiological factors. At this point, the numbers in each etiological group are not sufficient for separation. Data analysis with larger numbers may be possible at a later date. Computed tomography scans were not used for preoperative or postoperative assessment in our series. Although radiological healing was established, this requires further followup to assess long term survivorship. We are continuing to followup these patients to study the long term survivorship.

In this series, 26 out of 30 hips have had a good outcome so far. In conclusion, bone grafting can definitely be used as a suitable option in the management of acetabular defects in THRs. The risk of graft resorption, collapse and cup migration have to be taken into consideration while hoping to achieve some restoration of bone stock.^{10,17-19} This would limit the use of hardware for future procedures as well. Although trabecular metal cups used along with augments seem to be a promising alternative, widespread use of these implants are limited by costs especially in countries like ours where the financial burden could be very significant for the patient.

REFERENCES

1. Troelsen A, Malchau E, Sillesen N, Malchau H. A review of current fixation use and registry outcomes in total hip arthroplasty: The uncemented paradox. *Clin Orthop Relat Res* 2013;471:2052-9.
2. Borland WS, Bhattacharya R, Holland JP, Brewster NT. Use of porous trabecular metal augments with impaction bone grafting in management of acetabular bone loss. *Acta Orthop* 2012;83:347-52.
3. Harris WH, Crothers O, Oh I. Total hip replacement and femoral-head bone-grafting for severe acetabular deficiency in adults. *J Bone Joint Surg Am* 1977;59:752-9.
4. McCollum DE, Nunley JA, Harrelson JM. Bone-grafting in total hip replacement for acetabular protrusion. *J Bone Joint Surg Am* 1980;62:1065-73.
5. Slooff TJ, Huiskes R, van Horn J, Lemmens AJ. Bone grafting in total hip replacement for acetabular protrusion. *Acta Orthop Scand* 1984;55:593-6.
6. Rodriguez JA, Huk OL, Pellicci PM, Wilson PD Jr. Autogenous bone grafts from the femoral head for the treatment of acetabular deficiency in primary total hip arthroplasty with cement. Long term results. *J Bone Joint Surg Am* 1995;77:1227-33.
7. Hendrich C, Mehling I, Sauer U, Kirschner S, Martell JM. Cementless acetabular reconstruction and structural bone-grafting in dysplastic hips. *J Bone Joint Surg Am* 2006;88:387-94.
8. Garcia-Cimbrelo E, Cruz-Pardos A, Garcia-Rey E, Ortega-Chamarro J. The survival and fate of acetabular reconstruction with impaction grafting for large defects. *Clin Orthop Relat Res* 2010;468:3304-13.

9. Busch VJ, Gardeniers JW, Verdonschot N, Slooff TJ, Schreurs BW. Acetabular reconstruction with impaction bone-grafting and a cemented cup in patients younger than fifty years old: A concise followup, at twenty to twenty-eight years, of a previous report. *J Bone Joint Surg Am* 2011;93:367-71.
10. Sternheim A, Abolghasemian M, Safir OA, Backstein D, Gross AE, Kuzyk PR. A long term survivorship comparison between cemented and uncemented cups with shelf grafts in revision total hip arthroplasty after dysplasia. *J Arthroplasty* 2013;28:303-8.
11. Levine B, Della Valle CJ, Jacobs JJ. Applications of porous tantalum in total hip arthroplasty. *J Am Acad Orthop Surg* 2006;14:646-55.
12. Van Kleunen JP, Lee GC, Lementowski PW, Nelson CL, Garino JP. Acetabular revisions using trabecular metal cups and augments. *J Arthroplasty* 2009;24:64-8.
13. DeLee JG, Charnley J. Radiological demarcation of cemented sockets in total hip replacement. *Clin Orthop Relat Res* 1976;121:20-32
14. Van Egmond N, De Kam DC, Gardeniers JW, Schreurs BW. Revisions of extensive acetabular defects with impaction grafting and a cement cup. *Clin Orthop Relat Res* 2011;469:562-73.
15. Van Haaren EH, Heyligers IC, Alexander FG, Wuisman PI. High rate of failure of impaction grafting in large acetabular defects. *J Bone Joint Surg Br* 2007;89:296-300.
16. Sporer SM, Paprosky WG. The use of a trabecular metal acetabular component and trabecular metal augment for severe acetabular defects. *J Arthroplasty* 2006;21:83-6.
17. Lee JM, Nam HT. Acetabular revision total hip arthroplasty using an impacted morselized allograft and a cementless cup: Minimum 10-year followup. *J Arthroplasty* 2011;26:1057-60.
18. Mall NA, Nunley RM, Smith KE, Maloney WJ, Clohisy JC, Barrack RL. The fate of grafting acetabular defects during revision total hip arthroplasty. *Clin Orthop Relat Res* 2010;468:3286-94.
19. Pulido L, Rachala SR, Cabanela ME. Cementless acetabular revision: Past, present, and future. *Revision total hip arthroplasty: The acetabular side using cementless implants. Int Orthop* 2011;35:289-98.

How to cite this article: Oommen AT, Krishnamoorthy VP, Poonnoose PM, Korula RJ. Fate of bone grafting for acetabular defects in total hip replacement. *Indian J Orthop* 2015;49:181-6.

Source of Support: Nil, **Conflict of Interest:** None.