

## Original Article

# Effects of five levels of noise reduction applied to indirect digital radiography on diagnostic accuracy of external apical root resorption

Sanaz Sharifi Shoshtari<sup>1</sup>, Seyed Arman Mohagheghi<sup>1</sup>, Nastaran Farhadi<sup>1</sup>, Negin Kheradmand<sup>2</sup>, Lida Naderi<sup>3</sup>

<sup>1</sup>Department of Oral and Maxillofacial Radiology, School of Dental Medicine, Ahvaz Jundishapur University of Medical Sciences, <sup>2</sup>Dentist in Private Practice, Ahvaz Jundishapur University of Medical Sciences, Ahvaz, <sup>3</sup>Department of Oral and Maxillofacial Radiology, School of Dental Medicine, Kermanshah University of Medical Sciences, Kermanshah, Iran

## ABSTRACT

**Background:** Radiologic diagnosis of external apical root resorption (EARR) is clinically important. Noise might disrupt this diagnosis. Therefore, we assessed the efficacy of noise reduction on periapical indirect digital radiography.

**Materials and Methods:** This *in vitro* study as performed on 792 radiographs. A total of 66 single-rooted premolars were inserted in dried hemimandibles of sheep and fixed with modeling wax. Digital images were obtained using the parallel technique. The storage phosphor plates were processed in the DIGORA Optime scanner. The resulting images were sent to a computer using the Scanora software for radiographic analysis. The teeth were removed from the mandible, and artificial EARR defects were simulated. Afterward, the indirect digital radiographs were obtained at the same condition of the baseline. Five levels of noise reduction were applied. All images were saved in Digital Imaging and Communications in Medicine format and monitored by two observers twice over 2 weeks. Data were analyzed statistically using Cochran and McNemar tests ( $\alpha = 0.05$ ).

**Results:** The highest sensitivity rate was found in the baseline group (0.99), and the lowest sensitivity was related to the “four-time noise reduction” method (0.91). The highest specificity rate was in the “five-times noise reduction” method (0.88) and the lowest specificity was associated with “one-time noise reduction” method (0.71). There was no statistical difference between images with/without noise reduction enhancement with varied gradation levels in terms of diagnostic accuracies of EARR ( $P > 0.05$ ).

**Conclusion:** Application of noise reduction procedure in Scanora software might have no effect on the accuracy of EARR diagnosis.

**Key Words:** Computer-assisted image processing, digital imaging, root resorption

Received: November 2018  
Accepted: June 2019

### Address for correspondence:

Dr. Lida Naderi,  
Department of Oral and  
Maxillofacial Radiology,  
School of Dental Medicine,  
Kermanshah University  
of Medical Sciences,  
Kermanshah, Iran.  
E-mail: lida\_naderie@yahoo.  
com

## INTRODUCTION

External resorption of mineralized tissue (cementum and dentin) is either a physiological or pathological condition associated with loss of tooth structure through the continued action of osteoclastic cells.<sup>[1,2]</sup> Root resorption of permanent teeth is usually a result

of various conditions such as dental trauma, common illnesses (such as viral meningitis, pulpal infection, or periodontal infection), orthodontic pressure, ankylosis, and tumoral or impacted tooth pressures.<sup>[3,4]</sup> Idiopathic

This is an open access journal, and articles are distributed under the terms of the Creative Commons Attribution-NonCommercial-ShareAlike 4.0 License, which allows others to remix, tweak, and build upon the work non-commercially, as long as appropriate credit is given and the new creations are licensed under the identical terms.

**For reprints contact:** reprints@medknow.com

**How to cite this article:** Shoshtari SS, Mohagheghi SA, Farhadi N, Kheradmand N, Naderi L. Effects of five levels of noise reduction applied to indirect digital radiography on diagnostic accuracy of external apical root resorption. Dent Res J 2020;17:126-33.

### Access this article online



Website: [www.drj.ir](http://www.drj.ir)  
[www.drjjournal.net](http://www.drjjournal.net)  
[www.ncbi.nlm.nih.gov/pmc/journals/1480](http://www.ncbi.nlm.nih.gov/pmc/journals/1480)

external root resorption (ERR) is defined as cases of ERR without a distinct etiologic factor. Although the exact etiology of the idiopathic root resorption is still unknown, there might be a relationship between extensive pulpal inflammation and the idiopathic resorption.<sup>[5]</sup> ERR occurs more frequently in apical and cervical sites.<sup>[6]</sup> Irreversible loss of external tooth structures is evident in ERR resulting in loss of dentin, cementum, pulp tissue, and premature loss of the tooth.<sup>[7]</sup>

Conventional radiography comprises an X-ray machine producing X-rays and an image receptor such as an X-ray film. It has various drawbacks including long-term preparation and high X-ray dosage, especially when images need to be repeated, and incapability to archive and manipulate the images.<sup>[8]</sup> Digital imaging offers some advantages over conventional radiography for detecting dental and maxillofacial lesions, including high contrast resolution images, low-dose X-ray radiation, as well as using image processing and enhancement software and sharpening and smoothing filters.<sup>[9,10]</sup>

Any fluctuations in a radiograph that do not correspond to X-ray attenuation levels caused by the imaged object may be considered noise.<sup>[11]</sup> Noise represents intensity variation and is often categorized as high-frequency or low-frequency noises. Speckling is a special type of high-frequency noise that is characterized by isolated small regions surrounded by lighter or darker regions. Filters that smooth an image is sometimes called noise or despeckling filters because they are designed to remove high-frequency noises.<sup>[6]</sup> In this study, all images were analyzed using the Scanora 5.1 software (Soredex Corporation, Helsinki, Finland). It is allowed to reduce noise in five levels using the noise reduction algorithm of Scanora software. Few studies have examined the diagnostic accuracy of digital image algorithms for detection of ERR.<sup>[12-15]</sup> In addition, few studies have examined the influence of noise reduction on digital radiography.<sup>[16-22]</sup> These studies have reported contradictory results. Some of these studies have shown that this type of noise reduction does not change image quality and diagnostic accuracy.<sup>[17,19,21]</sup> Some other studies have reported that this type of noise reduction reduces diagnostic confidence and accuracy.<sup>[16,18,20]</sup> Since no study has yet evaluated the impression of noise reduction filter on the diagnostic accuracy of external apical root resorption (EARR), the aim of the present study was to evaluate the effect

of noise reduction option of a radiograph viewer software on the accuracy of EARR diagnosis on digital radiographs.

## MATERIALS AND METHODS

The present study was an *in vitro* study. The study was approved by Research Ethics Committee. The inclusion criteria were intact single-rooted premolar teeth extracted due to orthodontic or periodontal treatment. Multi-rooted premolars and infected roots were excluded from the study.

A total of 66 single-rooted premolar teeth were selected for the study. They were inserted in four dried hemimandibles of sheep and fixed with pink modeling wax (Cavex Set Up Wax, Cavex, Haarlem, The Netherlands). These four hemimandibles were used to improve the diversity of bone structures. Four thick layers of wax were used as a soft-tissue simulator adjacent to the hemimandible. Before creating artificial external apical root resorptive defects, radiographic image of each tooth was obtained at the baseline using the parallel periapical image acquisition method. Images of intact roots served as the control group to assess false-positive cases. The purpose of the baseline group was to provide a control group to estimate the odds of a false-positive error (incorrect diagnosis of root resorption) or a true negative finding (correct diagnosis of the intact root) while observing an intact root. The indirect digital X-ray images were obtained through DIGORA® storage phosphor plates (PSPs) and its scanner, the DIGORA Optime (Soredex Corp, Helsinki, Finland), and a periapical imaging device (XGenus, De Götzen SRL, Varese, Italy) which was operated at exposure settings of 70 kVp and 8 mA, for 0.32 s. The teeth were then removed from the mandible bone, and artificial external apical root resorptive defects were simulated on the mesial aspect of apical thirds of the roots equivalent to the diameter of a bur (0.50 mm) using a sharp 1/4-round bur (Teeskavan Co, Tehran, Iran) attached to a high-speed handpiece. Subsequently, to replicate the bone density, the samples were located in sockets of a dry hemi-mandible using pink modeling wax (Cavex). Afterward, the indirect digital X-ray images (PSP) were obtained at the same condition of the baseline.

Following the exposures, the storage PSPs were scanned immediately in the DIGORA Optime scanner (Soredex Corp, Helsinki, Finland) and the resulting images were sent to a personal computer

for radiographic analysis using the Scanora 5.1 software (Soredex Corporation, Helsinki, Finland). Five levels of noise reduction were applied to enhance each image by clicking on the “Noise reduction” option on the “Diagnostic tools” menu bar on the top of Scanora’s user interface. The algorithm used for this purpose was not disclosed by the developer, and we could not reach them regarding this matter. All images were saved in Digital Imaging and Communications in Medicine format. The purpose of the six groups of radiographs (a control and five levels of noise reduction) was to provide information about the diagnostic accuracies when evaluating images with different intensities of noise reduction.

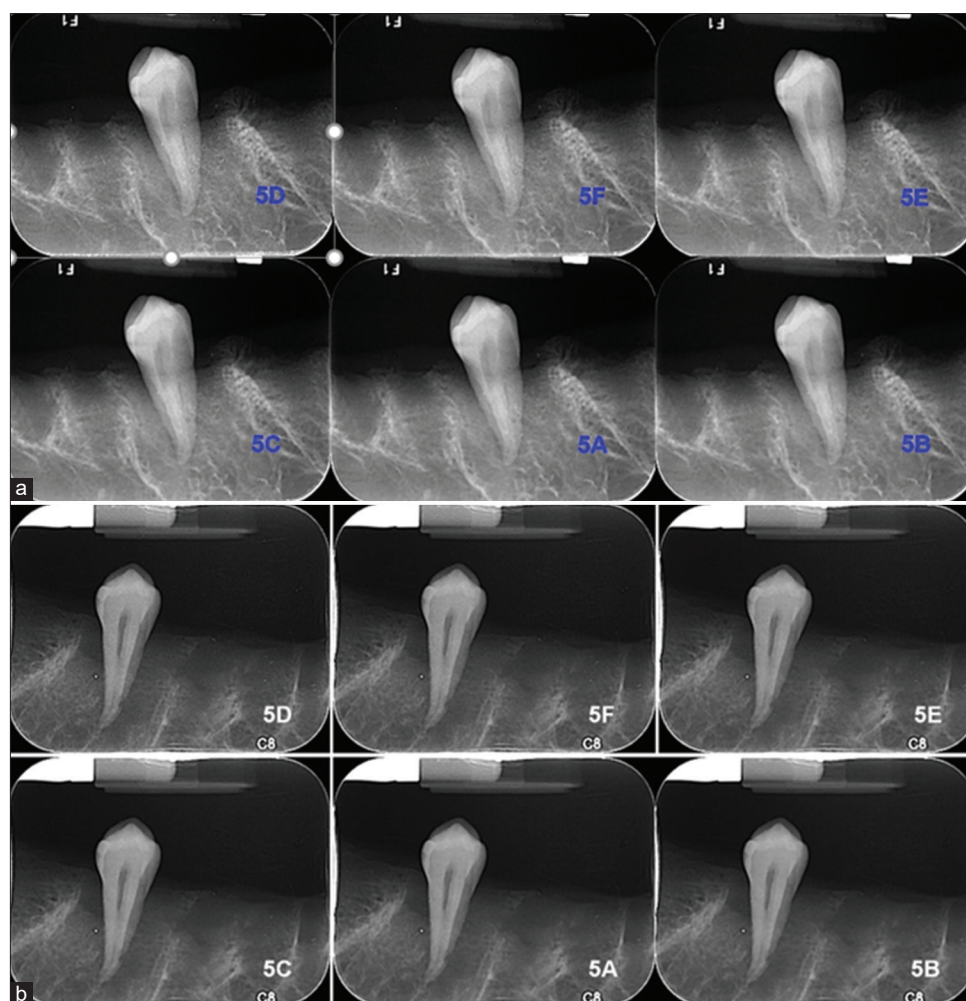
The order of images with EARR and without EARR were randomly selected for evaluation [Figure 1]. All the radiographs were observed by two blind observers two times at 2-week intervals. The images were

observed on an LED monitor (20”, Model 2040S, LG Electronics, Inc. Korea) under dim light conditions.

In total, 792 radiographic images were examined (noise-reduced images before root resorption = 330, original images before root resorption = 66, images after creation of root resorption = 396). Root apices were classified into two levels of root resorption: 0 = no root resorption and 1 = apical root resorption. Agreements were assessed using the Kappa test. Receiver-Operator curves were drawn for each stage of noise reduction. Sensitivity and specificity at all stages of noise reduction were compared using Cochran and McNemar tests of SPSS ver. 20 (IBM, Armonk, NY, USA). The level of significance was predetermined as 0.05.

## RESULTS

According to Table 1, the accuracy of the first



**Figure 1:** (a) Five levels of noise reduction in images without external apical root resorption, (b) Five levels of noise reduction in images with external apical root resorption. 5D: Without noise reduction; 5F: Single-time noise reduction; 5E: Two-time noise reduction; 5C: Three-time noise reduction; 5A: Four-time noise reduction; 5B: Five-time noise reduction.

observer in the first reading was 86%, with a significant  $\kappa = -0.73$  ( $P = 0.001$ ). The second observer showed an accuracy of 89%, and a Kappa of  $-0.78$  [ $P = 0.001$ , Table 1]. The sensitivity, specificity, accuracy, and coefficient of observer 2 (first and second stages) were greater than the observer 1, but the difference was not statistically significant [ $P > 0.05$ , Table 1].

According to Table 2, the degree of accuracy of the first observer in the second reading was 82%. The Kappa statistic was  $-0.644$  ( $P = 0.001$ ). The second observer had an accuracy of 85%. Kappa was  $-0.71$  ( $P = 0.001$ ). The sensitivity, specificity, accuracy, and coefficient of observer 2 (first and second stages) were greater than the observer 1, but the difference was not statistically significant [ $P > 0.05$ , Table 2].

The sensitivity, specificity, and accuracy of the observer 1 in the second phase were similar to the first phase, and no significant difference was found between the diagnosis of the first and second stages ( $P = 0.968$ ). The sensitivity, specificity, and accuracy of the observer 2 in the second phase were similar to the first phase, and no significant difference was found between the diagnosis of the first and second stages ( $P = 0.569$ ).

**Table 1: Results of the first observation**

Observer	Resorption		Total	Sensitivity	Specificity	Accuracy
	Before	After				
Observer 1						
Negative	25	312	337	0.95	0.79	0.86
Positive	371	84	455			
Total	396	396	792			
Observer 2						
Negative	16	324	340	0.96	0.82	0.89
Positive	380	72	452			
Total	396	396	792			

**Table 2: Results of the second observation (two weeks after the first observation)**

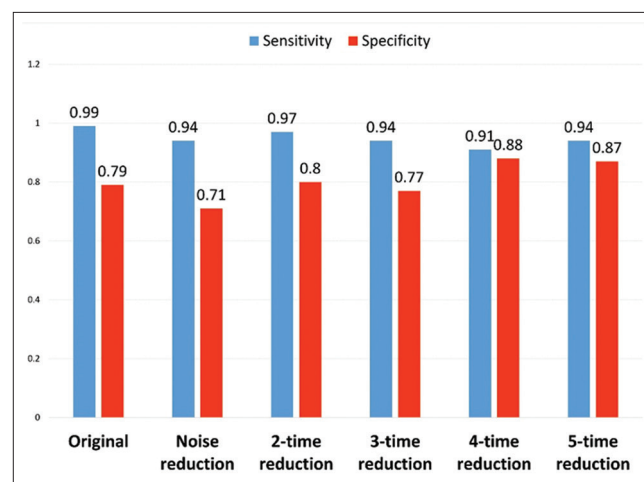
Observer	Resorption		Total	Sensitivity	Specificity	Accuracy
	Before	After				
Observer 1						
Negative	39	294	333	0.90	0.74	0.82
Positive	357	102	459			
Total	396	396	792			
Observer 2						
Negative	30	310	340	0.92	0.78	0.85
Positive	366	86	452			
Total	396	396	792			

The Kappa test showed that the agreement between two assessments of the observer 1 before root resorption and the two assessments of the observer 1 after root resorption were 0.75 and 0.87, respectively which were statistically significant ( $P = 0.001$ ). As well, the agreements between the two values of the observer 2 taken before and also the two values taken after root resorption were 0.68 and 0.89, respectively, which were statistically significant ( $P = 0.001$ ). Both observers had a high and acceptable coefficient of agreement in the first and second stages of observation. Therefore, it was concluded that the first assessment of both observers was accurate, and hence, the first assessments were only used for further analyses.

The values of sensitivity and specificity for the original images (without noise reduction) and images with different levels of noise reduction are presented in Table 3 and Figure 2.

The overall difference between sensitivity or specificity of different groups at all stages was not significant ( $P > 0.05$ ). According to the results of Table 4, there was no significant difference between the sensitivities of different modes of noise reduction ( $P > 0.05$ ). According to the results of Table 5, there was no significant difference between the specificities of different modes of noise reduction ( $P > 0.05$ ).

The areas under the curves pertaining to original images, noise-reduced images, 2-time, 3-time, 4-time, and 5-time noise reductions were 0.826, 0.826, 0.886, 0.856, 0.894, and 0.902, respectively.



**Figure 2:** Sensitivity and specificity of diagnostic accuracy of apical root resorption through indirect digital radiography in five stages of noise reduction (processed images) and without noise reduction (unprocessed image).

**Table 3: Sensitivity and specificity of the indirect digital radiography (PSP) without and with noise reduction**

Mode	Resorption		Total	Sensitivity	Specificity
	Before	After			
Without noise reduction					
Negative	131	28	159	0.99	0.79
Positive	1	104	105		
Total	132	132	264		
Stage one of noise reduction					
Negative	124	38	162	0.94	0.71
Positive	8	94	102		
Total	132	132	264		
Stage two of noise reduction					
Negative	128	26	254	0.97	0.80
Positive	4	106	110		
Total	132	132	264		
Stage three of noise reduction					
Negative	124	30	226	0.94	0.77
Positive	8	102	38		
Total	132	132	264		
Stage four of noise reduction					
Negative	120	16	136	0.91	0.88
Positive	12	116	128		
Total	132	132	264		
Stage five of noise reduction					
Negative	124	18	142	0.94	0.87
Positive	8	114	122		
Total	132	132	264		

**Table 4: The sensitivity of apical root resorption in different modes of noise reduction**

Index	Degree of noise reduction	P
Sensitivity	Without noise reduction=0.99	
	Stage 1=0.94	0.799
	Stage 2=0.97	0.859
	Stage 3=0.94	0.799
	Stage 4=0.91	0.751
	Stage 5=0.94	0.799
	Noise reduction Stage 1=94	
	Stage 2=0.97	0.125
	Stage 3=0.94	1.000
	Stage 4=0.91	0.125
	Stage 5=0.94	0.100
	Noise reduction Stage 2=91	
	Stage 3=0.94	0.125
	Stage 4=0.91	0.086
	Stage 5=0.94	0.125
	Noise reduction Stage 3=94	
	Stage 4=0.91	0.388
	Stage 5=0.94	1.000
	Noise reduction Stage 4=91	
	Stage 5=0.94	0.125

## DISCUSSION

In the present study, the difference was not significant,

but the sensitivity was higher in images without noise removal filters, which might be due to limited use of filtering and the user's familiarity with unprocessed images. The image processing methods included in digital systems might enhance filtering, contrast, and diagnostic accuracy.<sup>[23]</sup> In digital imaging, image quality, contrast, blur, and noise, can be altered digitally.<sup>[24]</sup> Our results indicated no significant improvements of diagnostic accuracy after five rounds of noise reduction. This was consistent with results of some other studies. Ghoncheh *et al.*<sup>[13]</sup> 2017 in a study examined the accuracy of processed digital images (reverse-contrast and colorization) compared to unprocessed indirect digital images in detection of ERR. The results of their study showed that the difference between the sensitivity and specificity of unprocessed, reverse-contrast, and colorized images was not statistically significant and concluded that the three techniques were of similar and desirable accuracy in detection of ERR.<sup>[13]</sup> The results of the study were consistent with the results of the present study.

Mehdizadeh *et al.*<sup>[15]</sup> in 2015, evaluated the accuracy of direct digital radiographs processed with a filter

**Table 5: The specificity of apical root resorption in different modes of noise reduction**

Index	Degree of noise reduction	P
Specificity	Without noise reduction=0.79	
	Stage 1=0.71	0.520
	Stage 2=0.80	0.791
	Stage 3=0.77	0.845
	Stage 4=0.88	0.084
	Stage 5=0.87	0.100
	Noise reduction Stage 1=0.71	
	Stage 2=0.80	0.068
	Stage 3=0.77	0.152
	Stage 4=0.88	0.062
	Stage 5=0.87	0.059
	Noise reduction Stage 2=0.80	
	Stage 3=0.77	0.454
	Stage 4=0.88	0.093
	Stage 5=0.87	0.186
	Noise reduction Stage 3=0.77	
	Stage 4=0.88	0.071
	Stage 5=0.87	0.088
	Noise reduction Stage 4=0.88	
	Stage 5=0.87	0.832

referred to as ‘compensation of X-ray attenuation and visual response’ in the assessment of apical root resorption. The measurement of resorptions was carried out with the use of a periodontal probe (Williams, Hu Friedy, USA) and considered as the gold standard. The results showed no significant difference between the results of the processed digital image measurements and the gold standard; however, there were significant differences between measurements made on processed digital images and nonprocessed digital images. They concluded that X-ray attenuation compensation and visual response algorithms are effective in diagnosing the severity of apical root resorption.<sup>[15]</sup> Therefore, the application of this type of algorithm in digital images was recommended. Although they evaluated different filter and approached different results, they had the same goal as our study evaluated the way to better detection of apical root resorption. In contrast with our study, they introduced an effective filter referred to as “compensation of X-ray attenuation and visual response” in the assessment of apical root resorption.

In another study Mehdizadeh *et al.*<sup>[17]</sup> 2013, examined the measurement accuracy of endodontic file length on periapical indirect digital radiography using noise reduction digital filter and concluded that noise reduction digital filter did not influence the measurement accuracy of the length of the thin endodontic files on the digital periapical

radiographs.<sup>[17]</sup> The results of the study were in line with the results of the present study.

Koob *et al.*<sup>[21]</sup> 2004 studied the different image processing modes (filters) on the reproducibility and accuracy of the assessment of proximal carious lesions viewed in direct digital radiography. Variables studied were exposure time, and tissue scatter radiation. The central depth (CD) of each carious lesion was measured at 21-fold magnification both on the unchanged image and after use of two different filters (median, median plus inversion). The results of the study showed that basic digital filtering of radiographic images failed to result in statistically significant improvement of the accuracy of CD measurements.<sup>[21]</sup> The results of the study were in agreement with the results of the present study.

Brüllmann *et al.*<sup>[19]</sup> in 2011, in a study, evaluated the length of endodontic files measured in direct digital radiographs with and without noise-suppression filters and showed that the filters tested do not affect file sizes bigger than ISO 10. The results of the study were inconsistent with the results of the present study. This contradiction can be due to differences in the methodology, the type of receiver (CCD vs. PSP), and different software (Sidexis XG 2.4, Sirona, Bensheim, Germany) with a specific filter program (Borland C-Builder 6.0, Borland GmbH, Langen, Germany).<sup>[19]</sup>

Brüllmann *et al.*,<sup>[20]</sup> 2008, in another study examined the effect of digital noise filters on diagnostic radiographs for the diagnosis of experimental vertical root fractures. The results of the study suggested that this filter can effectively reduce noise from the input image, but does not increase the diagnostic accuracy of root fractures compared to unprocessed images.<sup>[20]</sup> Although they evaluated different problem (root fractures vs. ERR), their results were in line with the results of the present study and strengthened them.

Näslund *et al.*<sup>[18]</sup> 2003, investigated the cephalometric analysis with digital storage phosphor images. They studied the benefit of postprocessing noise reduction on the localization of anatomic landmarks in extreme low-exposure images, and the quality of the images. The results of the study showed that the landmarks were better identified on the low-exposure images with standard postprocessing than on the images with postprocessing noise reduction, which were inconsistent with the results of the present study. This difference can be due

to different study methods (extraoral radiography vs. intraoral radiography) and different evaluating objectives (landmarks vs. ERR).<sup>[18]</sup>

Filters that sharpen an image either remove low-frequency noise or augment boundaries between regions with different intensities (edge enhancement).<sup>[6]</sup> Farhadi *et al.*<sup>[25]</sup> 2016, studied the effect of different levels of sharpness processing filter on the accuracy of endodontic file length determination using indirect digital periapical radiography. The results of the study showed that the application of mild and moderate levels of sharpness processing filter did not influence the accuracy of endodontic file length determination. This result was in consistent with results of the present study. They also shown high-level sharpness processing filter was not recommended due to its unfavorable effects on measurement accuracy.<sup>[25]</sup> This result was not consistent with the results of the present study, which could be due to differences in the study methods (the measurement of endodontic file length vs. diagnosis of ERR).

In the other study by Farhadi *et al.*,<sup>[26]</sup> 2015, they evaluated the accuracy of endodontic file length measurement on digital periapical radiographs after application of contrast inversion digital enhancement. There were significant differences between the measurement accuracy of the original and enhanced images ( $P < 0.05$ ). The enhanced images exhibited longer measurements compared to the original images. It is suggested that contrast inversion should not be used in determining the lengths of small endodontic files.<sup>[26]</sup> This study has shown an adverse effect of using contrast inversion digital enhancement filter in postprocessing of digital radiography. This result is in contrast whit present study, which could be due to differences in the study methods (the measurement of endodontic file length vs. diagnosis of ERR) and differenr35tt filter (contrast inversion digital enhancement vs. noise reduction).

Yalcinkaya *et al.*,<sup>[23]</sup> 2006, in a study used a specific enhancement algorithm (Vistascan system) that aimed to decrease high-frequency noise of panoramic images. They concluded that this method had no advantage over X-rays that interact with the X-ray film in the diagnosis of anatomical landmarks.<sup>[23]</sup> Although they investigated panoramic imaging and instead of external apical resorption the normal landmarks were analyzed, their results were in line with the result of the present study.

Since the tested noise reduction filter showed no statistically significant influence on EARR diagnosis in this study, it might not be recommended for this purpose. Still, digital radiography along with the software tools that come with it might be still preferable over analog radiography, as they might facilitate diagnostic procedures.<sup>[27,28]</sup> In clinical situations, the presence of soft-tissue results in a greater amount of scattered radiation, increasing the amount of noise. Therefore, clinical studies are suggested for further evaluation of the influence of noise reduction filters on diagnostic accuracy of EARR.

The *in vitro* design of this study with sheep hemimandibles and simulated soft tissues disallows the generalizability of our results to clinical conditions. Moreover, a larger sample determined based on power calculations was needed to increase the reliability of findings. The algorithm used for the noise reduction was not known. It was better to use multiple computer programs and known algorithms to comparatively evaluate whether the lack of significant diagnostic improvements would be observed by other filters as well, and if not, which filters would output better-processed images.

## CONCLUSION

Within the limitations of this *in vitro* study, it was found that the application of noise reduction option of Scanora software might have no considerable effect on the diagnostic accuracy of EARR and might be only time consuming to the clinician. Therefore, it is not recommended for EARR detection.

## Acknowledgment

This study was supported by a financial grant from Jundishapur University of Medical Science.

## Financial support and sponsorship

This study was supported by a financial grant from Jundishapur University of Medical Science.

## Conflicts of interest

The authors of this manuscript declare that they have no conflicts of interest, real or perceived, financial or nonfinancial in this article.

## REFERENCES

1. Durack C, Patel S, Davies J, Wilson R, Mannocci F. Diagnostic accuracy of small volume cone beam computed tomography and intraoral periapical radiography for the detection of

- simulated external inflammatory root resorption. *Int Endod J* 2011;44:136-47.
2. Shokri A, Mortazavi H, Salemi F, Javadian A, Bakhtiari H, Matlabi H. Diagnosis of simulated external root resorption using conventional intraoral film radiography, CCD, PSP, and CBCT: A comparison study. *Biomed J* 2013;36:18-22.
  3. Fuss Z, Tsesis I, Lin S. Root resorption – Diagnosis, classification and treatment choices based on stimulation factors. *Dent Traumatol* 2003;19:175-82.
  4. Kjaer I. External root resorption: Different etiologies explained from the composition of the human root-close periodontal membrane. *Dent Hypotheses* 2013;4:75.
  5. Bolhari B, Meraji N, Nosrat A. Extensive idiopathic external root resorption in first maxillary molar: A case report. *Iran Endod J* 2013;8:72-4.
  6. White SC, Pharoah MJ. *Oral Radiography: Principles and Interpretation*. 7<sup>th</sup> ed. St. Louis: Mosby; 2014. p. 50, 604.
  7. Aziz K, Hoover T, Sidhu G. Understanding root resorption with diagnostic imaging. *J Calif Dent Assoc* 2014;42:158-64.
  8. Nair MK, Nair UP. Digital and advanced imaging in endodontics: A review. *J Endod* 2007;33:1-6.
  9. Tabrizzadeh M, Abrisham SM, Yazdani E. The accuracy comparison of direct digital radiography (DDR) and conventional radiography in detecting chemically created lesions. *J Dent Sch* 2011;29:55-61.
  10. Haiter-Neto F, Casanova MS, Frydenberg M, Wenzel A. Task-specific enhancement filters in storage phosphor images from the vistascan system for detection of proximal caries lesions of known size. *Oral Surg Oral Med Oral Pathol Oral Radiol Endod* 2009;107:116-21.
  11. Williams MB, Krupinski EA, Strauss KJ, Breeden WK 3<sup>rd</sup>, Rzeszotarski MS, Applegate K, *et al.* Digital radiography image quality: Image acquisition. *J Am Coll Radiol* 2007;4:371-88.
  12. Hintze H, Wenzel A, Andreasen FM, Swerin I. Digital subtraction radiography for assessment of simulated root resorption cavities. Performance of conventional and reverse contrast modes. *Endod Dent Traumatol* 1992;8:149-54.
  13. Ghoncheh Z, Afkhami F, Fard MJ, Sorkhabi RE, Aydin U. Accuracy of digitally enhanced images compared with unprocessed digital images in the detection of external root resorption. *Oral Radiol* 2017;33:133-9.
  14. de Azevedo Vaz SL, Vasconcelos TV, Neves FS, de Freitas DQ, Haiter-Neto F. Influence of cone-beam computed tomography enhancement filters on diagnosis of simulated external root resorption. *J Endod* 2012;38:305-8.
  15. Mehdizadeh M, Jahromy MZ, Jahromy AK, Roshanzamir N. Effect of application of a filter in digital radiography to detect root resorption. *Isfahan Dent Coll J* 2015;11:397-404.
  16. Xu Y, Lai EK. Restoration of images contaminated by mixed Gaussian and impulse noise using a recursive minimum-maximum method. *IEE Proc Vis Image Signal Process* 1998;145:264-70.
  17. Mehdizadeh M, Khademi AA, Shokraneh A, Farhadi N. Effect of digital noise reduction on the accuracy of endodontic file length determination. *Imaging Sci Dent* 2013;43:185-90.
  18. Näslund EB, Møystad A, Larheim TA, Øgaard B, Kruger M. Cephalometric analysis with digital storage phosphor images: Extreme low-exposure images with and without postprocessing noise reduction. *Am J Orthod Dentofacial Orthop* 2003;124:190-7.
  19. Brüllmann D, Witzel V, Willershausen B, d'Hoedt B. Effect of digital noise filters on diagnostic radiographs for the diagnosis of experimental root fractures. *Int J Comput Dent* 2008;11:107-14.
  20. Brüllmann DD, Röhrig B, Sulayman SL, Schulze R. Length of endodontic files measured in digital radiographs with and without noise-suppression filters: An ex-vivo study. *Dentomaxillofac Radiol* 2011;40:170-6.
  21. Koob A, Sanden E, Hassfeld S, Staehle HJ, Eickholz P. Effect of digital filtering on the measurement of the depth of proximal caries under different exposure conditions. *Am J Dent* 2004;17:388-93.
  22. Janhom A, van der Stelt PF, van Ginkel FC, Geraets WG. Effect of noise on the compressibility and diagnostic accuracy for caries detection of digital bitewing radiographs. *Dentomaxillofac Radiol* 1999;28:6-12.
  23. Yalcinkaya S, Künzel A, Willers R, Thoms M, Becker J. Subjective image quality of digitally filtered radiographs acquired by the dürr vistascan system compared with conventional radiographs. *Oral Surg Oral Med Oral Pathol Oral Radiol Endod* 2006;101:643-51.
  24. Jayachandran S. Digital imaging in dentistry: A review. *Contemp Clin Dent* 2017;8:193-4.
  25. Farhadi N, Shokraneh A, Saatchi M. Effect of different levels of sharpness processing filter on the measurement accuracy of endodontic file length. *Dent Hypotheses* 2016;7:15.
  26. Farhadi N, Shokraneh A, Mehdizadeh M. Effect of contrast inversion enhancement on the accuracy of endodontic file length determination in digital radiography. *J Clin Diagn Res* 2015;9:ZC102-5.
  27. Rakhshan V, Nateghian N, Ordoubazari M. Risk factors associated with external apical root resorption of the maxillary incisors: A 15-year retrospective study. *Aust Orthod J* 2012;28:51-6.
  28. Rakhshan V, Rakhshan H, Shebaninia A. Developing an automatic lateral cephalometric landmark identification program and evaluating its performance. *Int J Comput Dent* 2009;12:327-43.