



Xerophthalmia: Findings from the Eye Lead to Diagnosis of a Fatal Intestinal Disease

Beril Tulu Aygun,¹ Burcin Kepez Yildiz,¹ Deniz Ogutmen Koc,² Yusuf Yildirim¹

¹Department of Ophthalmology, University of Health Sciences Beyoglu Eye Training and Research Hospital, Istanbul, Turkey

²Department of Gastroenterology, University of Health Sciences Gaziosmanpasa Taksim Training and Research Hospital, Istanbul, Turkey

Abstract

Vitamin A has an essential role in the maintenance of corneal and conjunctival epithelization, as well as photoreceptor transduction in the retina. A deficiency of vitamin A causes keratinization of the surface epithelium, and night blindness is often the first symptom. This report describes a case of chronic intestinal pseudo-obstruction (CIPO), a rare and potentially fatal disease, diagnosed following detection of a vitamin A deficiency in an ophthalmological examination. A 25-year-old female patient presented with a 3-month history of dryness, a burning sensation, and decreased vision, especially at night, in both eyes. She appeared cachectic and ill, and reported having lost 10 kg in the previous year. An ophthalmological examination revealed conjunctival and corneal keratinization in addition to punctate keratopathy with xerosis in both eyes, which raised the suspicion of a vitamin A deficiency. Her serum vitamin A level confirmed the diagnosis, and she was referred to the gastroenterology clinic, where she was diagnosed with CIPO and treated with parenteral multivitamin supplementation. A vitamin A deficiency should be suspected in patients with malnourishment and xerosis. Rapid diagnosis and treatment can be life-saving in cases with a severe underlying pathology.

Keywords: Bitot's spot, chronic intestinal pseudo-obstruction, vitamin A deficiency, xerophthalmia.

Introduction

Vitamin A is a lipid-soluble vitamin absorbed from the intestinal lumen and stored in the liver, and it is crucial for a healthy immune system, skin, ocular surface, and retina. It has an essential role in maintenance of corneal and conjunctival epithelization, as well as photoreceptor transduction in the retina (1). A deficiency of vitamin A causes keratinization of the surface epithelium, and night blindness in particular, which is a first symptom (2).

Detection of even mild ocular signs indicating xerophthalmia (Bitot's spots, xerosis) should alert ophthalmologists to consider a vitamin A deficiency and to seek a gastroenterology consultation in order to reveal the underlying cause,

which could be a life-threatening disorder.

This is a report of a case diagnosed with a rare and potentially fatal disease, chronic intestinal pseudo-obstruction (CIPO), following detection of a vitamin A deficiency in an ophthalmological examination and referral to a gastroenterology clinic.

Case Report

A 25-year-old female patient presented at our outpatient clinic with a 3-month history of dryness, a burning sensation, and decreased vision, especially at night, in both eyes. The patient had been referred to us after visiting 2 other university clinics. Topical artificial tear drops and topical cyclosporin treatments had not been beneficial. Her medical

Address for correspondence: Beril Tulu Aygun, MD. Beyoglu Goz Egitim ve Arastirma Hastanesi, Saglik Bilimleri Universitesi, Goz Hastaliklari Anabilim Dalı, Istanbul, Turkey
Phone: +90 536 811 88 00 **E-mail:** beriltulu@gmail.com

Submitted Date: November 04, 2019 **Accepted Date:** February 08, 2020 **Available Online Date:** July 29, 2020

©Copyright 2020 by Beyoglu Eye Training and Research Hospital - Available online at www.beyoglu-eye.com

OPEN ACCESS This work is licensed under a Creative Commons Attribution-NonCommercial 4.0 International License.



history included episodes of vomiting, diarrhea, and considerable weight loss in the previous 3 months. She appeared cachectic and malnourished, and reported feeling exhausted. The ophthalmological examination revealed a best corrected visual acuity of 20/320, conjunctival and corneal keratinization, and punctate keratopathy with xerosis in both eyes, which raised the suspicion of a vitamin A deficiency (Fig. 1). An analysis of the patient's serum vitamin A level was ordered, and the result was 0.04 $\mu\text{g}/\text{dL}$ (normal range: 30-80 $\mu\text{g}/\text{dL}$). In order to verify the ocular diagnosis, a conjunctival biopsy was performed the next day, and the pathology report revealed diffuse keratinization of the conjunctival epithelium, which is consistent with the clinical diagnosis of xerophthalmia.

Following the initial examination, without waiting for the biopsy results, topical retinol palmitate ointment to be applied 3 times a day was added to the existing treatment of topical, preservative-free, artificial tear drops and topical cyclosporine. An urgent referral to the gastroenterology clinic was also arranged for a systemic evaluation and parenteral vitamin A administration.

Upon further investigation at the gastroenterology clinic, the patient disclosed a history of 10 years of intermittent stomachache and constipation relieved after attacks of vomiting and diarrhea for 2 days. She had lost 10 kg in the prior year, and had experienced amenorrhea for the previous 5 months. Her workup revealed a dilated duodenum, air-fluid levels at the intestines, no peristalsis in the esophagus or stomach, and no intestinal obstruction. A rheumatological evaluation yielded no results related to connective tissue diseases. An explorative laparotomy was performed after the patient had an attack of vomiting, hypotension, fever, and distention in the abdomen on the third day of admittance to the gastroenterology service. No mechanical obstruction was found, which concluded in a diagnosis of CIPO. The patient's ocular pathology of xerophthalmia was attributed to the intestinal malabsorption of vitamin A due to CIPO.

The patient was admitted to the gastroenterology clinic

on the day of presentation, and an intravascular multivitamin complex treatment, which includes 3500 IU vitamin A along with vitamins B through E was initiated, since a systemic (oral or parenteral) form of vitamin A alone is not commercially available in Turkey. Additionally, parenteral nutrition and prokinetic drugs were administered. The patient received an intravascular multivitamin treatment daily for 12 days, and was discharged with recommendations for an oral liquid diet and oral multivitamin complex supplementation.

At the 1-month follow-up examination, the patient had no symptoms of dryness or stinging. Additionally, she reported feeling stronger and looked in better general health. Although still not within the normal limits, the serum vitamin A level of the patient had increased significantly to 11.8 $\mu\text{g}/\text{dL}$. An ophthalmological examination indicated improved visual acuity to 20/32, and the corneal and conjunctival keratinization had substantially decreased in both eyes (Fig. 2). A fundus examination, which was suboptimal in the initial presentation due to corneal distortion, did not show any pathologies. An electroretinogram (ERG) was ordered in order to evaluate photoreceptor function at the 1-month visit and revealed normal results. At her 3-month visit, the patient continued to report no ocular symptoms, and a biomicroscopic examination showed no signs of Bitot's spot or corneal keratinization (Fig. 3).

Discussion

Vitamin A deficiency is uncommon in developed countries; however, there are reports in the literature describing cases that occurred related to eating disorders (3), bariatric surgery (4), and intestinal or liver disorders (4, 5) where either severe malnourishment or malabsorption is evident. CIPO is a rare and severe pathological condition, frequently misdiagnosed due to its rarity and limited awareness, and is often associated with a poor outcome (6). Often, there is a long history of severe, non-specific digestive symptoms followed by an acute, exacerbating sub-occlusive attack (7). In this case, the diagnosis of a rare ocular disease led to the diagnosis of

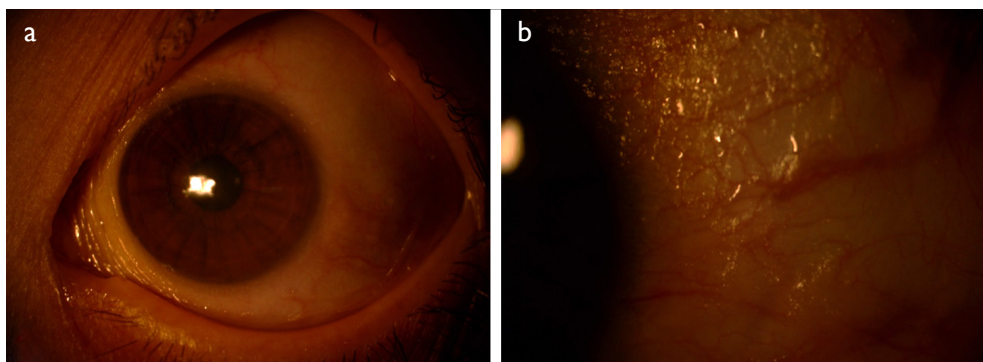


Figure 1. Biomicroscopic view at presentation. (a) Paralimbal corneal and conjunctival keratinization; (b) Bitot's spot at the temporal conjunctiva.

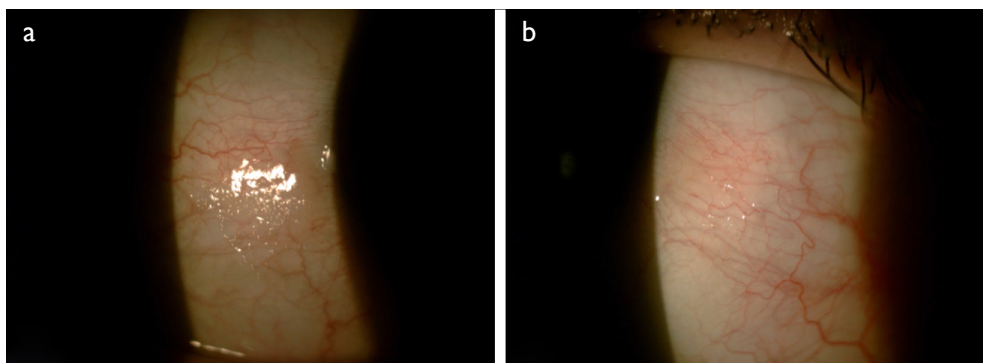


Figure 2. The 1-month follow-up examination results. Note the decrease in the size of the Bitot's spot findings. (a) Right eye; (b) Left eye.

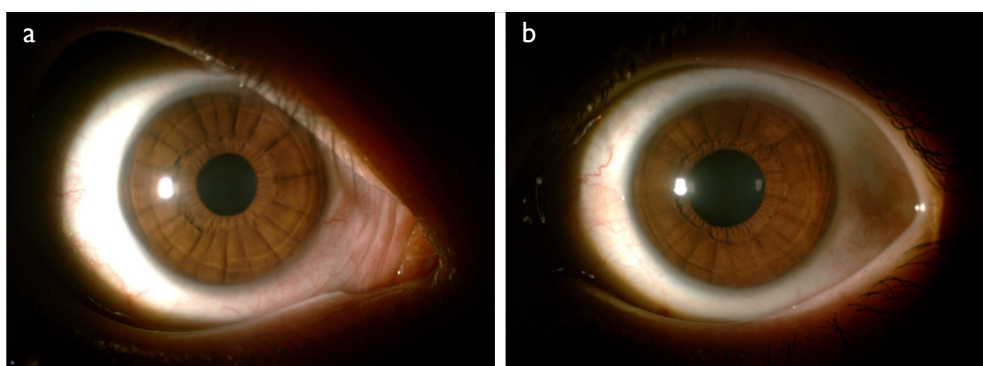


Figure 3. The 3-month follow-up examination results. There were no signs of corneal or conjunctival keratinization. (a) Right eye; (b) Left eye.

a rare and potentially fatal chronic intestinal disease, which had been symptomatic for almost half of the lifetime of the patient. This case is an example of how it is crucial to consider patient's full medical history and systemic complaints, and to investigate any underlying pathology.

In addition to topical treatment of xerophthalmia, systemic supplementation is also necessary in cases of a vitamin A deficiency. The World Health Organization recommends 100,000 IU vitamin A intramuscularly for severe corneal disease or malabsorption (8). In our country, no isolated systemic vitamin A supplementation is commercially available; only multivitamin complexes including vitamins A through E are offered, which was therefore the choice of treatment for our patient. Since our patient required substantial supplementation other than vitamin A, the gastroenterology physicians made the choice to administer the multivitamin complex intravenously, rather than intramuscularly. Since parenteral nutrition had been initiated during the admittance for CIPO treatment, the multivitamin complex was continued intravenously, and then replaced with oral supplementation at discharge, together with an oral feeding recommendation limited to liquid or homogenized food.

Following the initiation of vitamin A therapy, both night blindness and ocular surface symptoms are expected to

resolve in days to weeks (1), as occurred in our patient's case. At the end of the first month, she reported no ocular symptoms, and felt much more energetic, even though she needed further treatment and nutritional support for CIPO. An ophthalmological examination supported this improvement of ocular surface symptoms. In order to evaluate photoreceptor function, an ERG was ordered at this visit, which resulted in normal findings, as could be anticipated, given reports in the literature that after 10 days of vitamin supplementation, all ERG parameters are expected to return to normal (9). The improvement of her symptoms with multivitamin supplementation might suggest that it is an alternative option in places where an isolated form of vitamin A is not available, such as Turkey.

Without sufficient awareness, CIPO or vitamin A deficiency leading to xerophthalmia may not be easily recognizable in a metropolitan area. The purpose of this report is to remind physicians in different specialties that rare diseases do exist, and it is essential to meticulously and comprehensively evaluate patients in order to make the right diagnosis and eventually to suggest the correct treatment, which could affect the prognosis of the patient. The rapid diagnosis of vitamin A deficiency and proper referral of patients to determine and treat the underlying pathology can prevent

morbidity and mortality, though this might be an additional challenge in cases with a rarely encountered intestinal disease such as CIPO.

Disclosures

Informed consent: Written informed consent was obtained from the patient for the publication of the case report and the accompanying images.

Peer-review: Externally peer-reviewed.

Conflict of Interest: None declared.

Authorship Contributions: Involved in design and conduct of the study (BTA, BKY, YY, DOK); preparation and review of the study (BTA, BKY, YY, DOK); data collection (BTA, YY).

References

1. Sommer A. Xerophthalmia and vitamin A status. *Prog Retin Eye Res* 1998;17:9–31.
2. Lange AP, Moloney G, Sheldon CA. Bilateral corneal ulceration caused by vitamin a deficiency in eosinophilic gastroenteropathy. *Case Rep Ophthalmol* 2011;2:302–6.
3. Gospe SM, Todorich B, Foster YG. Keratomalacia in a Patient With Psychogenic Vitamin A Deficiency. *Cornea* 2016;35:405–7.
4. Donaldson KE, Fishler J. Corneal ulceration in a LASIK patient due to vitamin a deficiency after bariatric surgery. *Cornea* 2012;31:1497–9.
5. Renner AB, Dietrich-Ntoukas T, Jäggle H. Recurrent episodes of night blindness in a patient with short bowel syndrome. *Doc Ophthalmol* 2015;131:221–30.
6. Lauro A, De Giorgio R, Pinna AD. Advancement in the clinical management of intestinal pseudo-obstruction. *Expert Rev Gastroenterol Hepatol* 2015;9:197–208.
7. Antonucci A, Fronzoni L, Cogliandro L. Chronic intestinal pseudo-obstruction. *World J Gastroenterol* 2008;14:2953–61.
8. Sommer A, Muhilal I, Tarwotjo I. Protein Deficiency and Treatment of Xerophthalmia. *Arch Ophthalmol* 1982;100:785–7.
9. Spits Y, De Laey J-J, Leroy BP. Rapid recovery of night blindness due to obesity surgery after vitamin A repletion therapy. *Br J Ophthalmol* 2004;88:583–5.