

# Episcleral Venous Pressure and the Ocular Hypotensive Effects of Topical and Intracameral Prostaglandin Analogs

Susan S. Lee, PhD,\* Michael R. Robinson, MD,\*  
and Robert N. Weinreb, MD†

**Abstract:** There is a limit beyond which increasing either the concentration of a prostaglandin analog (PGA) or its dosing frequency fails to produce increases in ocular hypotensive efficacy with topical dosing. Intracameral PGA dosing with a bimatoprost implant, however, does not exhibit the same intraocular pressure (IOP)-lowering plateau at studied concentrations, and the maximum-achievable ocular hypotensive effects are not yet known. This suggests that the bimatoprost intracameral implant may activate another mechanism of action in addition to the mechanism(s) activated by topical application. Episcleral venous pressure (EVP) is a key determinant of IOP, and experimental manipulation of the episcleral vasculature can change both EVP and IOP. The recent observation that topical and intracameral PGA drug delivery routes produce different patterns of conjunctival hyperemia suggested that the differences in the IOP-lowering profiles may be caused by differing effects on the episcleral vasculature. Recent experiments in animals have shown that topical PGAs increase EVP, while the bimatoprost intracameral implant causes a smaller, transient increase in EVP, followed by a sustained decrease. The increase in EVP could be limiting the IOP-lowering efficacy of topical PGAs. In contrast, the decrease in EVP associated with the bimatoprost implant could explain its enhanced IOP-lowering effects. Further research on EVP as a target for IOP lowering is indicated to improve our understanding of this potentially important pathway for treating patients with glaucoma.

**Key Words:** bimatoprost, sustained release, intracameral, episcleral venous pressure, intraocular pressure

(*J Glaucoma* 2019;28:846–857)

Prostaglandin analogs (PGAs) are the most widely used first-line agents for lowering intraocular pressure (IOP) in the treatment of glaucoma.<sup>1</sup> It is well known, however, that

increasing the concentration of a topical PGA or the frequency of topical PGA dosing beyond a certain point does not provide additional IOP-lowering efficacy, and may even decrease efficacy.<sup>2–4</sup> It has recently been reported that the IOP lowering produced by a bimatoprost intracameral implant (Bimatoprost SR, Allergan plc), currently under development for the treatment of glaucoma, has not shown a plateau at tested concentrations with increasing bimatoprost concentration.<sup>5</sup> Moreover, it exceeds the maximum IOP lowering achievable with topical bimatoprost dosing. This suggests that the intracameral delivery of bimatoprost may activate another mechanism of action in addition to what is activated by topical application. The observation that topical and intracameral PGAs also produce different patterns of conjunctival hyperemia led to the hypothesis that the difference in IOP response to these 2 routes of PGA delivery may be caused by their having different effects on the episcleral vasculature and, therefore, episcleral venous pressure (EVP).<sup>6</sup> EVP is a key determinant of IOP,<sup>7</sup> but its role in the response to existing ocular hypotensive therapies is unknown and, to date, it has been an elusive target for therapeutic intervention.

This manuscript reviews the anatomy and physiology of the episcleral vasculature, the relationship between EVP and IOP, and the potential role of EVP in the ocular hypotensive response to topical and intracameral PGAs.

## THE EPISCLERAL VASCULATURE

The episcleral veins are the distal portion of the conventional aqueous outflow pathway that begins at the trabecular meshwork (Fig. 1).<sup>8</sup> Consequently, the pressure gradient between the anterior chamber and the episcleral veins has a significant effect on the rate of aqueous flow through this pathway.<sup>7</sup> Several distinctive characteristics of the episcleral vasculature suggest that it is a highly regulated vascular bed.<sup>8,9</sup> These characteristics are conserved across species (including rats, rabbits, dogs, owls, monkeys, and humans), and this suggests that the episcleral vasculature may have an important role in the control of normal IOP.<sup>9–13</sup>

The episcleral vasculature is notable for a lack of capillaries, a muscle-rich venous network, and numerous arteriovenous anastomoses (AVAs) that control the flow of blood between arterioles and venules (Fig. 2).<sup>9</sup> At the macroscopic level, the episcleral vasculature can be distinguished from conjunctival vessels by applying gentle lateral traction to the conjunctiva; the conjunctival vessels will move with the conjunctiva, while the episcleral vessels will not move.<sup>14</sup> The episcleral veins can be further identified by intracameral injection of a fluorescent dye (eg, indocyanine green). When this is done in beagle dogs, the episcleral veins can be distinguished from both conjunctival vessels and episcleral

Received for publication March 19, 2019; accepted June 7, 2019.  
From the \*Allergan plc, Irvine; and †Viterbi Family Department of Ophthalmology, Hamilton Glaucoma Center, Shiley Eye Institute, University of California, San Diego, La Jolla, CA.

Supported by Allergan plc, Dublin, Ireland.

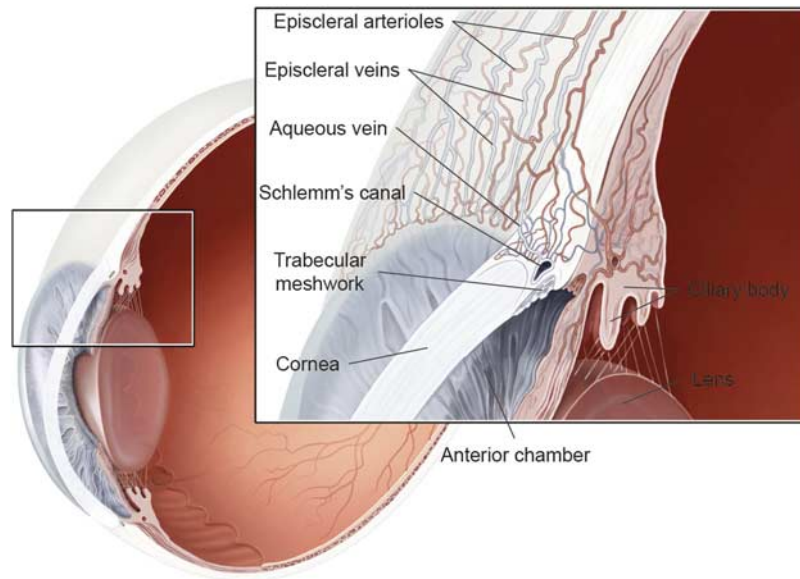
All authors met the ICMJE authorship criteria.

Disclosure: R.N.W. is a consultant to Aerie Pharmaceuticals, Alcon, Allergan, Bausch & Lomb, Eyenovia, Novartis, Sensimed, Unity, and Valeant, and has received research support from Carl Zeiss Meditec, Centervue, Genentech, Heidelberg Engineering, Konan, National Eye Institute, Optos, Optovue, and Tomey. S.S.L. and M.R.R. are employees of Allergan plc

Reprints: Michael R. Robinson, MD, Allergan plc, 2525 Dupont Drive, Irvine, CA 92612-1531 (e-mail: Robinson\_Michael@Allergan.com).

Copyright © 2019 The Author(s). Published by Wolters Kluwer Health, Inc. This is an open-access article distributed under the terms of the Creative Commons Attribution-Non Commercial-No Derivatives License 4.0 (CCBY-NC-ND), where it is permissible to download and share the work provided it is properly cited. The work cannot be changed in any way or used commercially without permission from the journal.

DOI: 10.1097/IJG.0000000000001307



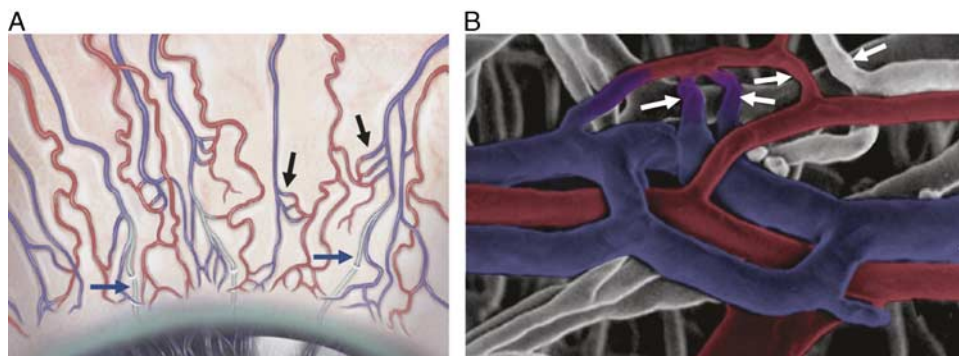
**FIGURE 1.** The episcleral vasculature in relation to the other structures of the conventional outflow pathway. In this pathway, aqueous flows through the trabecular meshwork, into Schlemm’s canal, and then through collector channels and aqueous veins that drain into the episcleral veins.

arterioles by their tendency to be longer and straighter than other vessels (Fig. 3).<sup>6</sup>

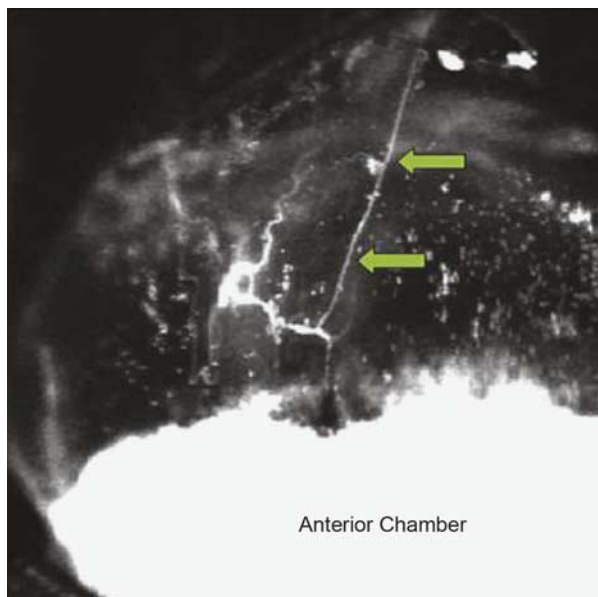
The AVAs connecting the episcleral arterioles and venules are characterized by a narrow (5 to 6 μm in diameter) arteriolar segment and a wider (10 to 14 μm in diameter) funnel-shaped venous segment (Fig. 2). There appear to be between 4 and 10 AVAs per mm<sup>2</sup> of the episcleral venous plexus in the rat eye and between 20 and 30 AVAs per mm<sup>2</sup> in the rabbit eye.<sup>10</sup> Although the role of the AVAs in the eye is still being investigated, AVAs are known to have an important role in other vascular beds. For example, AVAs in the skin contribute to the regulation of body temperature.<sup>15</sup> They are nearly all closed when the temperature is cool but open with increasing temperature or exercise to direct blood to the surface where it can be cooled.<sup>15</sup> In the lungs, AVAs seem to be generally constricted at rest

and to dilate during exercise, which may facilitate gas exchange.<sup>16</sup>

Both episcleral arteries and veins are intensely innervated by parasympathetic, sympathetic, and trigeminal nerve fibers.<sup>8</sup> The vasoactive transmitters that have been found in nerve terminals surrounding the episcleral vessels in monkeys and humans include (but are not limited to) tyrosine hydroxylase, neuropeptide Y, substance P, calcitonin gene-related peptide, and vasoactive intestinal polypeptide.<sup>9</sup> There is also evidence of nitrergic innervation.<sup>9</sup> In rabbits, application of the local anesthetic proparacaine produces a rapid and marked decrease in EVP, suggesting that the episcleral vasculature is under tonic neural control in this species.<sup>17</sup> In rats, electrical stimulation of the superior salivatory nucleus (200 9-μA pulses, 1-ms duration, 20 Hz) produced a significant increase in both EVP and IOP.<sup>18</sup> In addition, several vasoactive substances have been shown to



**FIGURE 2.** Episcleral vasculature. A, Macroscopic view. B, Plastic cast, adapted from Funk and Rohen,<sup>12</sup> published by Informa UK Limited. Adaptations are themselves works protected by copyright. So in order to republish this adaptation, authorization must be obtained both from the owner of the copyright in the original work and from the owner of copyright in the adaptation. Reprinted with permission of the publisher Informa UK Limited trading as Taylor & Francis Ltd, www.tandfonline.com. Copyright Oxford University Press, Oxford, UK. All permission requests for this image should be made to the copyright holders. Blue vessels are the episcleral venules; red vessels are the episcleral arterioles; black and white arrows indicate arteriovenous anastomoses; blue arrows in (A) indicate collector channels (containing a mix of aqueous and venous blood).



**FIGURE 3.** Real-time fluorescent imaging was performed after injection of indocyanine green (ICG) into the anterior chamber of beagle dogs. Vessels running perpendicular to the limbus immediately fluoresce following the ICG injection (arrows) suggesting that these are the aqueous outflow vessels. Reprinted from Lee et al<sup>6</sup> with permission. Copyright the authors. All permission requests for this image should be made to the copyright holder.

have an effect on the episcleral vasculature and EVP. For example, in rabbits, the nitric oxide donor nitroprusside causes an increase in EVP and epinephrine produces a decrease in EVP.<sup>11,19</sup> In humans, the  $\alpha_2$ -adrenoceptor agonist clonidine causes a decrease in EVP.<sup>20</sup> The topical application of pilocarpine in humans causes an initial general vasodilation of conjunctival and episcleral vessels, during which the episcleral veins fill with blood and there is a transient increase in the EVP.<sup>21</sup>

All of these characteristics suggest that the tone of the episcleral vasculature (and therefore EVP) is both highly regulated in normal eyes and potentially influenced by exogenous substances in treated eyes.

### RELATIONSHIP BETWEEN EPISCLERAL VESSEL DIAMETER, EVP, AND IOP

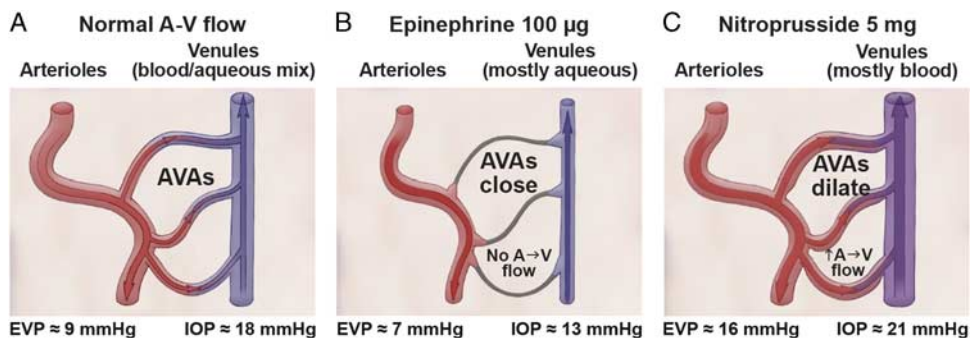
The relationship between EVP and IOP is defined by the modified Goldman equation as follows:

$$IOP = EVP + (Q - U) \div C.$$

In this equation, *Q* represents the aqueous inflow (in  $\mu\text{L}/\text{min}$ ), *U* represents the uveoscleral outflow (in  $\mu\text{L}/\text{min}$ ), and *C* represents conventional outflow facility through the trabecular meshwork ( $\mu\text{L}/\text{min}/\text{mm Hg}$ ).<sup>7,22</sup> Noninvasive measurements of EVP in humans have varied widely among investigators and laboratories, in large part because of the subjective endpoints of vessel changes used for the measurements.<sup>23</sup> Many studies have reported mean EVP values between 7 and 11 mm Hg in normal subjects.<sup>23,24</sup> Assuming a resting IOP of 15 to 17 mm Hg and an EVP of 8 to 9 mm Hg, the modified Goldman equation suggests that EVP accounts for ~47% to 60% of the IOP in humans.

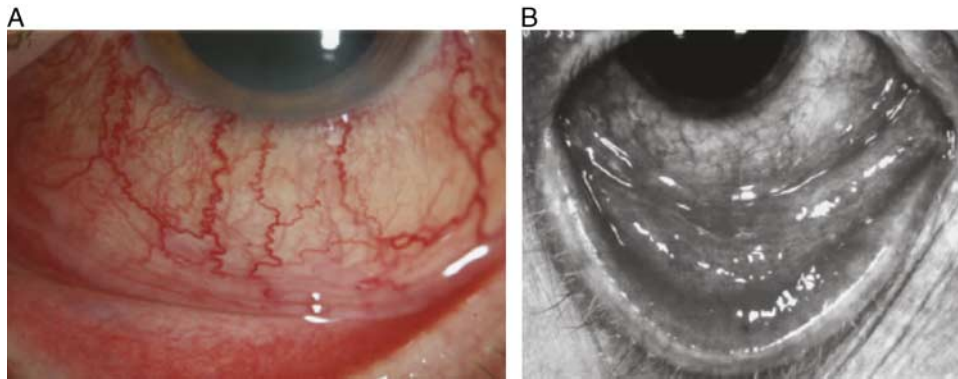
Funk et al<sup>11</sup> hypothesized that changes in EVP caused by pharmacological manipulation of the episcleral vasculature, particularly the diameter of the AVAs, could have a significant impact on IOP. In a series of experiments in rabbits, they demonstrated that changes in the diameter of the episcleral outflow vessels (secondary to AVA opening and closing) can affect the EVP and IOP. For example, AVA opening and a shift of blood from the arteriole to the venule side, causing vasodilation of the outflow vessels, increased the EVP and IOP. Conversely, AVA closing, reducing blood flow from the arteriole to the venule side, caused vasoconstriction of the outflow vessels and decreased the EVP and IOP (Fig. 4).

In these experiments, intraocular microendoscopy was used for simultaneous *in vivo* observation of the episcleral vascular bed and measurement of the episcleral vascular pressure.<sup>11</sup> This involved the use of a pressure chamber attached to the tip of an endoscope. The pressure chamber was filled with salt solution and connected to a hydrostatic reservoir and a pressure transducer. Intravascular pressure was defined as the pressure required to produce a 50% reduction in vessel diameter. IOP was measured using an anterior chamber needle connected to a pressure transducer. The mean resting pressure (*N*=6 animals) was found to be  $21.3 \pm 3.4$  mm Hg in the arterioles,  $15.0 \pm 2.9$  mm Hg in the AVAs,  $12.6 \pm 2.7$  mm Hg in the venules, and  $8.9 \pm 1.4$  mm Hg in the veins of the episcleral vasculature. The resting IOP was ~18 mm Hg. At rest, the episcleral venules could be seen to contain a mix of blood and



**FIGURE 4.** The effect of vasoactive agents on the episcleral vasculature, aqueous flow, EVP, and IOP in the rabbit.<sup>11</sup> A, Normally, the majority of AVAs are closed and the episcleral outflow vessels (venules) contain a mix of venous blood and aqueous humor. B, The vasoconstrictor epinephrine causes the AVAs to collapse, and a reduction of blood flow from the arteriole (A) to the venule (V) side occurs, leading to vasoconstriction and a decrease in both EVP and IOP. C, The vasodilator nitroprusside causes the AVAs to dilate. An increase of blood flow from the arteriole to the venule side occurs, causing vasodilation and an increase in both EVP and IOP. AVA indicates arteriovenous anastomosis; EVP, episcleral venous pressure; IOP, intraocular pressure.





**FIGURE 5.** Examples of conditions associated with elevated episcleral venous pressure. A, Carotid-cavernous dural fistula.<sup>26</sup> From Marx and Nandakumar. Reproduced with permission from SLACK Incorporated. Copyright SLACK Incorporated, Thorofare, New Jersey. All permission requests for this image should be made to the copyright holder. B, Delayed hypersensitivity to topical brimonidine.<sup>27</sup> Reprinted with permission from Macmillan Publishers Ltd: Watts and Hawksworth. Copyright 2002 Nature Publishing Group, London, UK. All permission requests for this image should be made to the copyright holder.

aqueous humor (indicating that the AVAs were at least partially open) (Fig. 4A).

The application of a topical vasoconstrictor (epinephrine) caused all of the episcleral vessels to constrict, the AVAs to close completely, and both EVP and IOP to decrease<sup>11</sup> (Fig. 4B). Some of the veins and venules were observed to be completely filled with aqueous humor because the collapse of the AVAs prevented any blood from flowing in from the arterioles. The pressure decreased to  $9.3 \pm 2.9$  mm Hg in the AVAs (62% of initial value) and to  $7.4 \pm 1.6$  mm Hg in the episcleral veins (83% of initial value). The IOP decreased from 18 to 13 mm Hg. In summary in these animals, topical administration of epinephrine caused complete constriction of the AVAs and closed off all blood flow to the aqueous veins. Although some vasoconstriction of the episcleral venules also occurred, a decrease in EVP, believed to be because of the reduction in fluid volume in the episcleral venules after closure of the AVAs, was observed and resulted in a reduction in IOP.

In contrast, the application of a topical vasodilator (nitroprusside) caused a dose-dependent dilation of the episcleral vasculature, and an increase in both EVP and IOP<sup>11</sup> (Fig. 4C). There was marked hyperemia as veins and venules, formerly perfused exclusively by aqueous humor, filled with arterial blood flowing through the AVAs. The blood impeded the outflow of aqueous humor and caused IOP to increase from 18 to 21 mm Hg. It also caused the pressure in the episcleral AVAs, veins, and venules to approach the pressure seen in the arterioles. The pressure was  $20.7 \pm 1.4$  mm Hg in the AVAs (138% of initial value),  $17.5 \pm 3.4$  mm Hg in the venules (138% of initial value), and  $15.5 \pm 2.5$  mm Hg in the veins (123% of initial value).

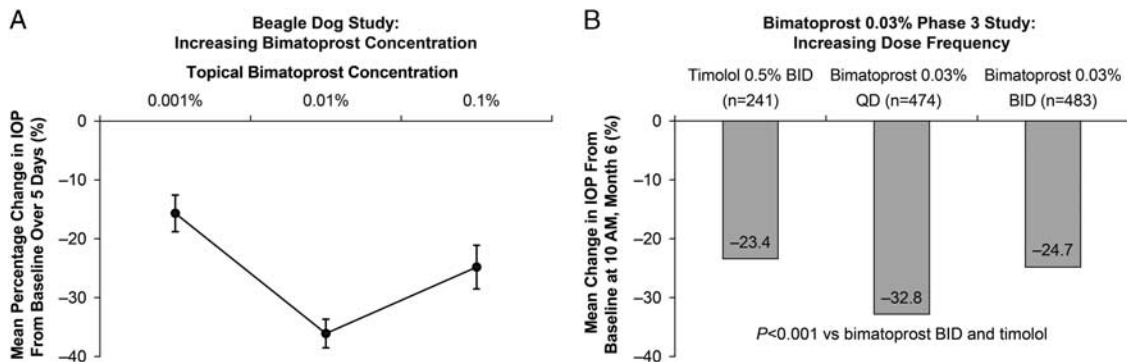
A relationship between changes in EVP and IOP has also been observed in humans. In a study of 11 healthy volunteers, Friberg et al<sup>14</sup> evaluated IOP and EVP in both supine and inverted positions. In the supine position, mean IOP was  $19.0 \pm 1.1$  mm Hg and mean EVP was  $7.9 \pm 0.63$  mm Hg (42% of IOP). Following inversion, mean IOP was  $36.9 \pm 1.2$  mm Hg and mean EVP was  $25.7 \pm 1.13$  mm Hg (70% of IOP). Regression analysis found that each 1 mm Hg increase in IOP was associated with a  $0.83 \pm 0.21$  mm Hg increase in EVP.<sup>14</sup> A similarly close relationship between changes in EVP and IOP in healthy eyes was also observed by Blondeau et al.<sup>25</sup> These

investigators measured EVP and IOP throughout a 24-hour observation period in 12 healthy volunteers and found that both pressures rose and fell in near parallel when the subjects changed position. In the sitting position (4 PM), mean IOP (measured with a Tonopen) was  $15.6 \pm 3.56$  mm Hg and mean EVP was  $8.1 \pm 1.26$  mm Hg (52% of IOP). In the supine position (6 AM), mean IOP was  $17.3 \pm 2.24$  mm Hg and mean EVP was  $10.5 \pm 1.33$  mm Hg (61% of IOP).<sup>25</sup>

In the clinical setting, elevated EVP can be caused by a variety of conditions such as arteriovenous shunts or fistulas (Fig. 5A), Sturge-Weber syndrome, orbital tumors, scleritis, thyroid-related orbitopathy, or large vessel venous obstruction.<sup>26,28,29</sup> Elevated EVP can also occur in the absence of any apparent cause (idiopathic elevated EVP).<sup>30,31</sup> Patients with elevated EVP associated with these conditions usually present with severe conjunctival hyperemia, high IOP, and open-angle glaucoma that is difficult to treat.<sup>29-31</sup> Several cases of severe conjunctival hyperemia and elevated IOP associated with delayed hypersensitivity to brimonidine (Fig. 5B) have also been described, and the authors speculated that the increase in IOP in these patients was caused by increased EVP.<sup>27</sup>

## THE ROLE OF THE EPISCLERAL VASCULATURE IN THE RESPONSE TO OCULAR HYPOTENSIVE PGAs

Topical ocular hypotensive PGAs have well-documented vasoactive properties.<sup>32,33</sup> They commonly produce ocular surface vasodilation that manifests as mild and transient conjunctival hyperemia—the most common adverse event associated with topical PGA use in the treatment of glaucoma.<sup>2,4</sup> In the case of topical bimatoprost, this hyperemia has been found to be caused by endothelial-derived nitric oxide-mediated vasodilation and is not associated with ocular surface inflammation.<sup>33</sup> Consequently, the hyperemia associated with topical PGAs has generally been considered an esthetically undesirable but clinically unimportant adverse event, unrelated to clinical efficacy. The observation that topical and intracameral PGAs have different IOP-lowering dose-response profiles and produce different patterns of conjunctival hyperemia led to the hypothesis that the differing dose-response profiles may be caused by differing effects on the episcleral vasculature.



**FIGURE 6.** Dose-response relationship for topical bimatoprost. A, Increasing concentration in beagle dogs. Error bars represent the standard error of the mean. Reprinted from Lee et al<sup>5</sup> under the terms of the CC BY license (<https://creativecommons.org/licenses/by/4.0/>). B, Increasing dose frequency in a clinical study. Data reported by Sherwood and Brandt.<sup>2</sup> IOP indicates intraocular pressure.

**Dose-Response: Topical PGAs**

It has long been known that maximal IOP lowering with topical PGAs is limited by an unknown mechanism and that increasing either the drug concentration or dosing frequency beyond a certain point does not increase IOP-lowering efficacy. Early in the preclinical development of bimatoprost, for example, it was noted that topical bimatoprost exhibited a U-shaped dose-response curve in beagle dogs<sup>5</sup> (Fig. 6A). The IOP lowering increased from 16% to 36% with an increase in bimatoprost concentration from 0.001% to 0.01%, but a further increase in concentration to 0.1% resulted in a decrease in IOP-lowering efficacy (Fig. 6A). In addition, in the phase 3 clinical evaluation of bimatoprost 0.03% (300 µg/mL) in eyes with glaucoma or ocular hypertension, the mean IOP reduction from baseline (at 10 AM at month 6) was actually significantly lower with twice-daily dosing (24.7%) than with once-daily dosing (32.8%) (Fig. 6B).<sup>2</sup> This has also been seen with latanoprost. Twice-daily dosing with latanoprost produces either no additional benefit or a loss of IOP-lowering efficacy in normal eyes<sup>4</sup> as well as those with glaucoma<sup>34</sup> or ocular hypertension.<sup>35</sup> Increasing the concentration of topical latanoprost above 50 µg/mL is similarly ineffective. A 4-week, dose-ranging study in eyes with primary open-angle glaucoma or ocular hypertension found that IOP lowering was similar with latanoprost concentrations ranging from 50 to 125 µg/mL.<sup>3</sup>

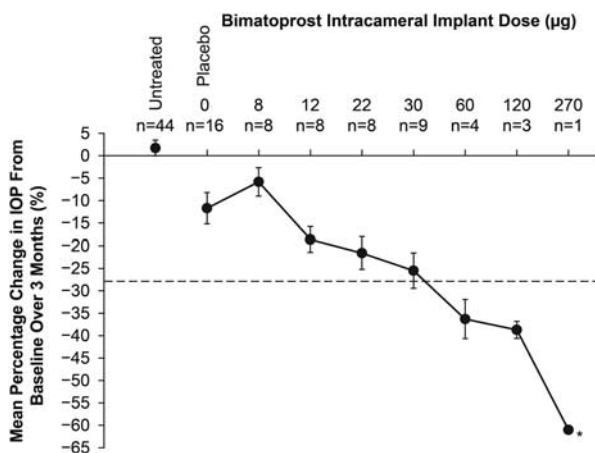
**Dose-Response: Bimatoprost Intracameral Implant**

The bimatoprost intracameral implant is a biodegradable, sustained-release implant that is currently under development for the treatment of glaucoma and ocular hypertension in patients who are unsuitable for treatment with topical drops.<sup>36</sup> Each implant contains preservative-free bimatoprost embedded in a solid biodegradable polymer matrix. In preclinical studies, the bimatoprost intracameral implant provided sustained release of bimatoprost into the intracameral space for ~3 to 4 months, while the polymer matrix slowly biodegraded to carbon dioxide and water. The implants that are continuing in development contain 10 or 15 µg of bimatoprost, similar to the amount of bimatoprost in 1 drop of topical bimatoprost 0.03% solution (Lumigan, Allergan plc).<sup>36</sup>

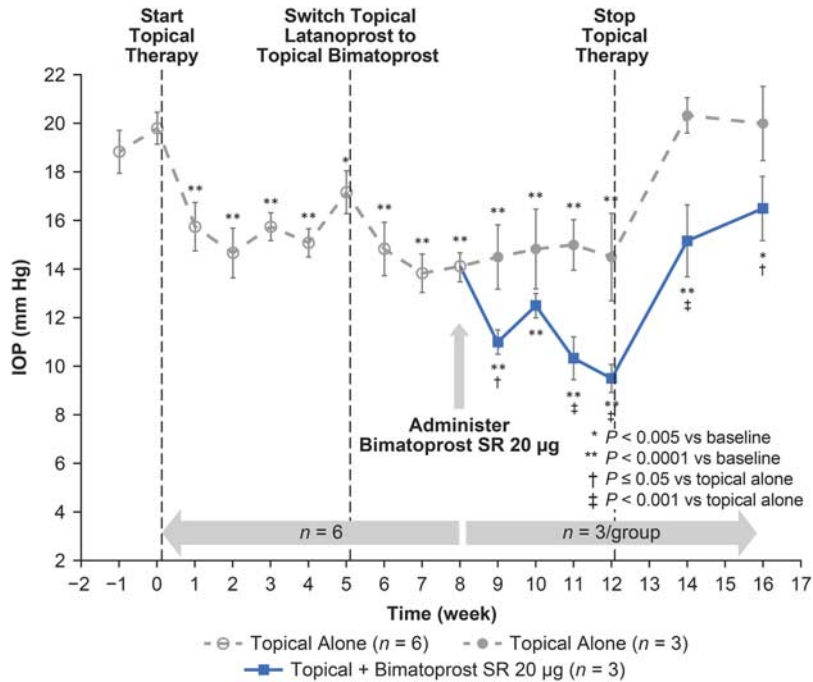
In a preclinical dose-ranging study, the IOP-lowering efficacy of dose strengths of bimatoprost intracameral implant ranging from 8 to 120 µg was compared with that of topical bimatoprost 0.03% in ocular normotensive beagle dogs (n=3 to 8 per dose group).<sup>5</sup> The decrease from

baseline IOP increased with increasing bimatoprost intracameral implant dose throughout the range tested (Fig. 7). Eye examinations were performed at each visit by the veterinary ophthalmologist, and uveitis was not present, suggesting that ocular inflammation did not contribute to the decrease in IOP. Moreover, the IOP lowering with bimatoprost intracameral implant doses of 60 µg and above exceeded that produced by topical bimatoprost 0.03%. In an attempt to determine whether IOP lowering would plateau at doses above 120 µg, a single animal was treated with a bimatoprost implant providing a dose of 270 µg bimatoprost. Surprisingly, IOP decreased even further with this dose and, at this time, the maximum achievable IOP lowering with the bimatoprost intracameral implant in dogs is not known.

A separate preclinical study was designed to see whether the bimatoprost intracameral implant could decrease IOP when added to a multidrug topical medication regimen that included a PGA.<sup>37</sup> In this study, 6 normotensive, chair-trained monkeys



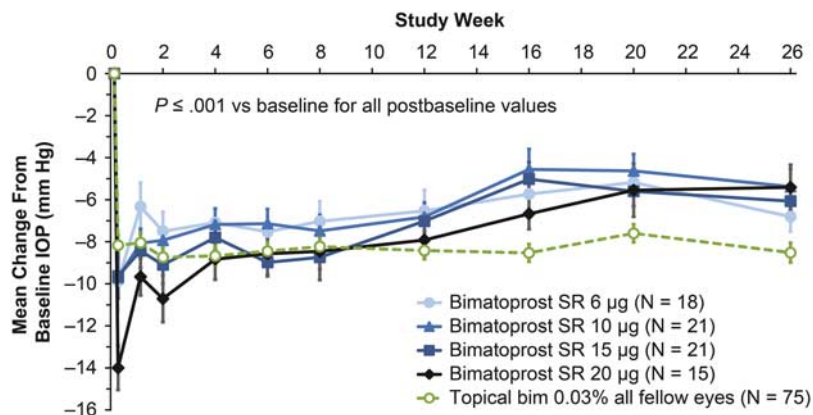
**FIGURE 7.** Mean percentage change in intraocular pressure (IOP) from baseline in beagle dogs in the treated eye over 3 months after administration of intracameral bimatoprost implant or a placebo implant. Error bars indicate standard error of the mean. Dotted line indicates the peak IOP reduction produced by 3 days of topical bimatoprost 0.03% treatment (n=42). Asterisk indicates sentinel dog data. Reprinted from Lee et al<sup>5</sup> under the terms of the CC BY license (<https://creativecommons.org/licenses/by/4.0/>).



**FIGURE 8.** Effect of bimatoprost intracameral implant and topical ocular hypotensive therapy on mean IOP at peak effect in normotensive monkeys. Topical therapy consisted of dorzolamide 2%/timolol 0.5% bid plus either latanoprost qd in the evening (weeks 0 to 5) or bimatoprost qd in the evening (weeks 5 to 12). Peak effect was 2 hours after the morning topical dosing. Bimatoprost SR indicates bimatoprost intracameral implant; IOP, intraocular pressure. Reprinted from Lee et al<sup>37</sup> under the terms of the CC BY license (<https://creativecommons.org/licenses/by/4.0/>).

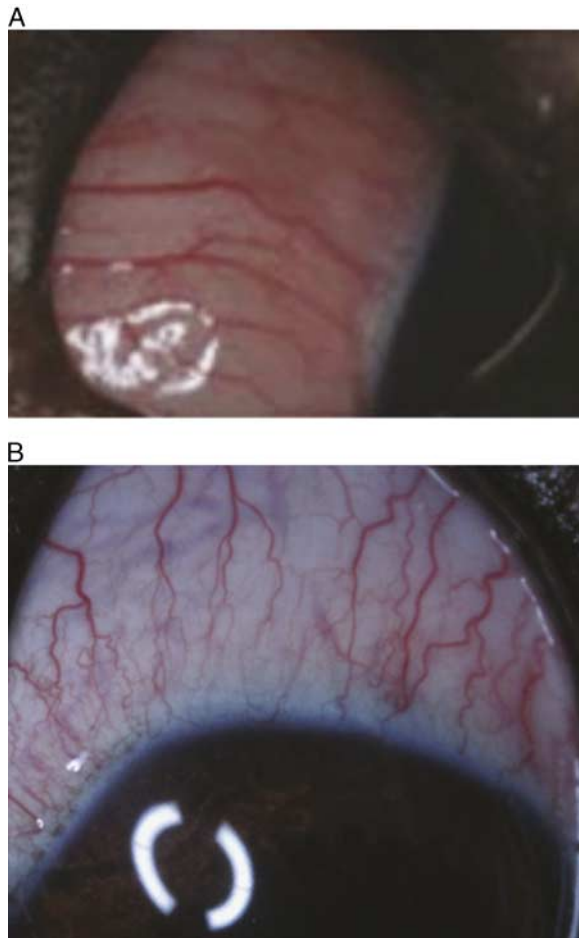
were treated with the topical fixed combination dorzolamide 2%/timolol 0.5% (Cosopt, Merck) bid plus topical latanoprost 0.005% qd for 5 weeks. At 5 weeks, the PGA was switched from latanoprost 0.005% to bimatoprost 0.03%. At 8 weeks, 3 eyes in 3 animals were treated with bimatoprost intracameral implant 20 µg. As can be seen in Figure 8, the addition of a bimatoprost intracameral implant produced an additional 2 to 4 mm Hg of IOP lowering beyond what was achievable with topical therapy alone.

A dose-response was also observed in the 6-month, phase 1/2 clinical trial of the bimatoprost intracameral implant in patients with open-angle glaucoma.<sup>36</sup> This study enrolled a total of 75 patients who, in the investigator’s opinion, could be treated adequately with topical bimatoprost 0.03% monotherapy. Each patient received a single treatment with a 6, 10, 15, or 20-µg bimatoprost intracameral implant in the study eye (n=15 to 21 per group), and was instructed to apply topical bimatoprost 0.03% once daily in the fellow eye. Decreases in



**FIGURE 9.** Mean change from baseline IOP (8 AM time point) in study eyes of glaucoma patients after bimatoprost intracameral implant administration and in fellow eyes treated with once-daily topical bimatoprost 0.03% (bim). Error bars represent standard error of the mean. Bimatoprost SR indicates bimatoprost sustained-release implant; IOP, intraocular pressure. Adapted from Lewis et al<sup>36</sup> with permission. Adaptations are themselves works protected by copyright. So in order to publish this adaptation, authorization must be obtained both from the owner of the copyright in the original work and from the owner of copyright in the adaptation.



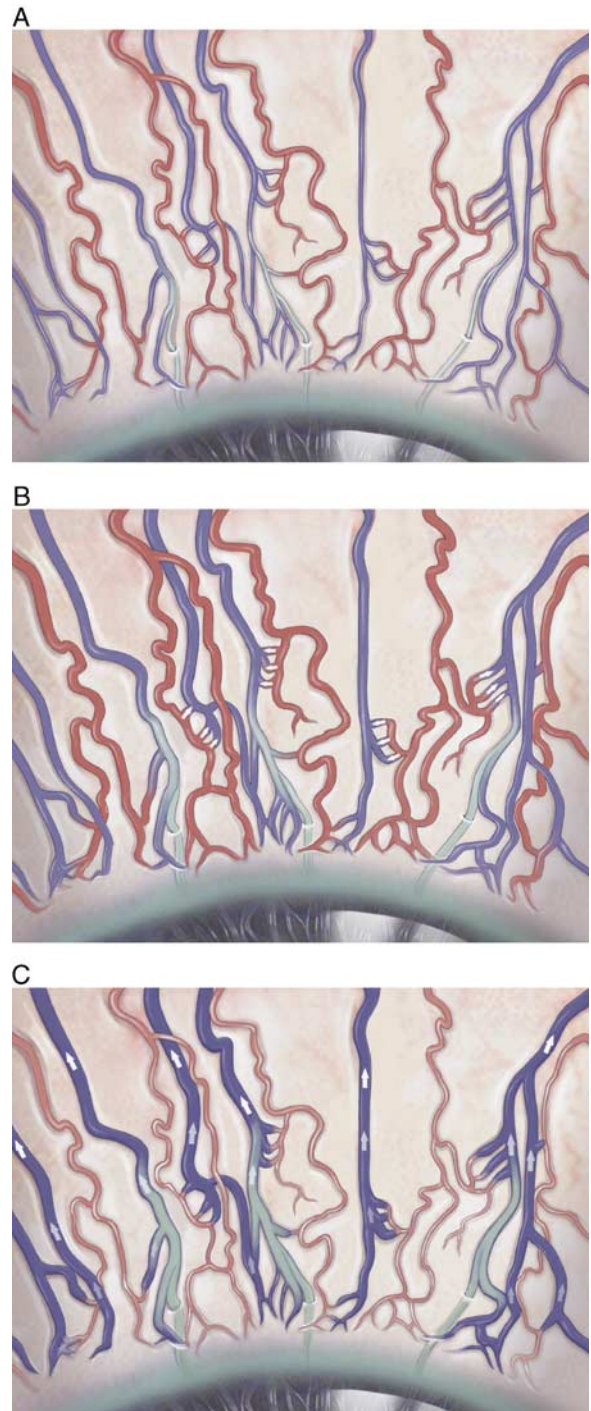


**FIGURE 10.** Hyperemia in dog eyes after administration of (A) topical bimatoprost and (B) bimatoprost intracameral implant.

IOP in the study eye were observed as early as the day after implant treatment and persisted through month 6. A dose-response to the bimatoprost intracameral implant was generally apparent during the first 12 weeks of the study (Fig. 9), and the overall mean IOP reductions through week 16 in the study eye were 7.2, 7.4, 8.1, and 9.5 mm Hg with the 6, 10, 15, and 20- $\mu$ g dose implants, respectively. This was similar to the mean overall decrease of 8.4 mm Hg seen in the fellow eyes treated with topical bimatoprost.<sup>36</sup>

### Ocular PGAs and Hyperemia


The most common ocular adverse event associated with topical PGAs is conjunctival hyperemia that is mostly mild and transient.<sup>2-4,34,35</sup> This hyperemia seems to be due exclusively to vasodilation, as no evidence of inflammation has been documented. In the case of bimatoprost, multiple-dose, long-term (up to 1 y) safety studies were conducted in rabbits, dogs, and nonhuman primates to specifically look for signs of ocular surface inflammation, and none were found.<sup>33</sup> What was found, however, was that the hyperemia produced by topically applied latanoprost or bimatoprost in dogs could be inhibited by L-NAME (a nitric oxide synthase inhibitor), suggesting that it is caused by vasodilation mediated by endothelial cell-derived nitric oxide.<sup>33</sup> There does not appear to be an increase in the incidence of hyperemia with an increase from once-daily to twice-daily



**FIGURE 11.** Hypothetical effect of ocular hypotensive prostaglandin analogs on episcleral vasculature. A, Untreated. B, Generalized vasodilation after topical dosing. C, Selective vasodilation of episcleral veins after intracameral dosing with the bimatoprost intracameral implant (arrows indicate the route of bimatoprost after intracameral dosing).

dosing,<sup>2,4</sup> but there may be an increase in hyperemia with an increase in PGA concentration.<sup>3,38</sup>

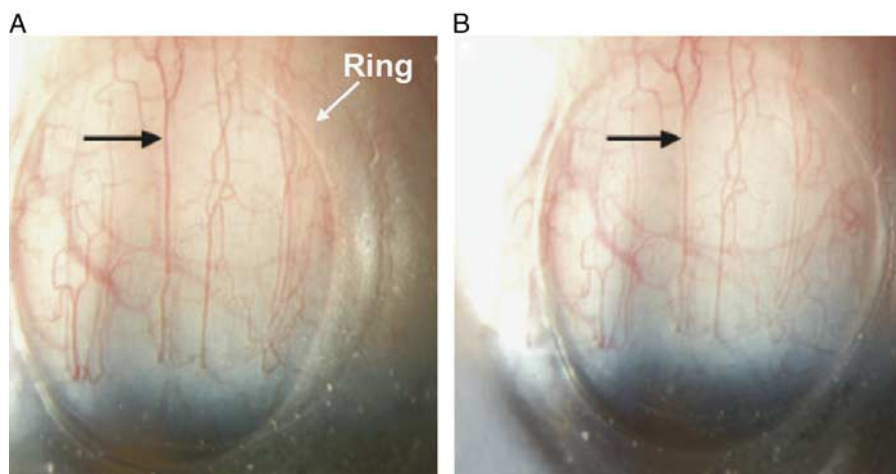
Studies then were conducted to determine whether intracameral delivery of a PGA would reduce the risk of



**FIGURE 12.** A, Eye Tech episcleral venomanometer used to evaluate episcleral venous pressure in beagle dogs. It is similar in design to a Goldmann tonometer and mounts on a slit-lamp biomicroscope. B, The flexible transparent membrane on the tip of the venomanometer. It is dome shaped (arrow) and made of silicone rubber. Reprinted from Tsai et al,<sup>13</sup> publisher John Wiley and Sons, Inc., with permission. Copyright 2012 American College of Veterinary Ophthalmologists, Meridian, Idaho. All permission requests for this image should be made to the copyright holder.

conjunctival hyperemia, and this turned out to be the case in humans. After a transient increase in erythema because of the injection procedure itself, the incidence of hyperemia in eyes treated with the bimatoprost intracameral implant falls to less than half that seen in fellow eyes treated with topical bimatoprost.<sup>36</sup> What was also noted, however, in animal studies where photographic assessment of the hyperemia

was performed, is that the pattern of hyperemia associated with the 2 drug delivery methods was distinctly different (Fig. 10). The hyperemia seen in eyes treated with topical bimatoprost is characterized by general vasodilation of all types of conjunctival and episcleral blood vessels (Fig. 10A). The hyperemia associated with the bimatoprost intracameral implant, however, seems to be largely caused by



**FIGURE 13.** View through the episcleral venomanometer. A, The episcleral vein (black arrow) is identified and located within the aiming ring on the silicone venomanometer tip. B, The pressure is increased until the vessel (black arrow) is 50% blanched. Reprinted from Tsai et al,<sup>13</sup> publisher John Wiley and Sons Inc., with permission. Copyright 2012 American College of Veterinary Ophthalmologists, Meridian, Idaho. All permission requests for this image should be made to the copyright holder.

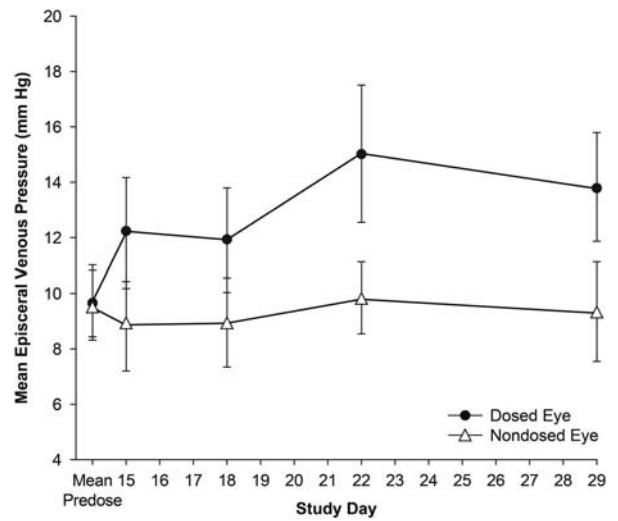


vasodilation of long, straight episcleral vessels (Fig. 10B). The episcleral vessels are deeper than the conjunctival vessels and are nonmobile when the overlying conjunctiva is manipulated with a cotton-tipped applicator.<sup>6</sup> In a representative dog injected intracamerally with indocyanine green, fluorescence imaging of dye that moved from the aqueous humor to outflow vessels verified that the long, straight episcleral vessels running perpendicular to the limbus and at least 4 mm posteriorly, and separated by ~1 clock hour, were the aqueous outflow vessels.<sup>6</sup> Thus, the vessels dilated by the intracameral implant have characteristics of episcleral aqueous outflow vessels (Fig. 10B). This suggests that topical and intracameral bimatoprost have different effects on the episcleral vasculature and, perhaps, on EVP.

**Hypothesis: The Different Dose-Response Profiles of Topical and Intracameral PGAs are Caused By Differing Effects on the Episcleral Vasculature**

If topical and intracameral PGAs have different effects on the episcleral vasculature and EVP, then this could have an effect on IOP-lowering efficacy that may manifest as differing dose-response profiles. It was therefore hypothesized that high doses or bid application of topical PGAs lead to dilation of all conjunctival and episcleral vessels and their associated AVAs.<sup>6</sup> This allows shunting of blood from the arterial (~14 to 16 mm Hg) to the venous vessels (~8 to 10 mm Hg), causing an increase in EVP, and creating a barrier to further IOP lowering. It was also hypothesized that intracameral dosing with increasing doses of the bimatoprost implant leads to progressive dilation of the episcleral veins only, because the episcleral arterioles and AVAs are not exposed to drug when it is delivered intracamerally.<sup>6</sup> This is illustrated in Figure 11. The dilation of the episcleral veins leads to a decrease in EVP, potentially helping to reduce IOP and to reduce the ability of EVP to act as a barrier to further IOP lowering. If this hypothesis is correct, then EVP measured during topical and intracameral PGA dosing should be significantly different.

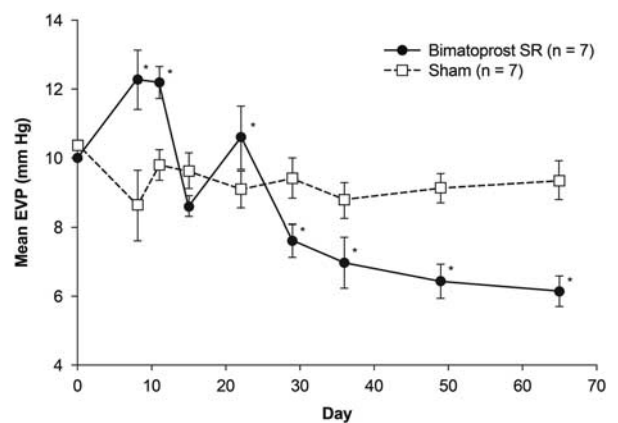
Evidence in support of this hypothesis was observed in a series of experiments in normotensive beagle dogs.<sup>6,13</sup> The effect of topical latanoprost 0.005% qd on EVP was evaluated in 14 normotensive beagle dogs.<sup>13</sup> In this study, EVP was measured noninvasively using an episcleral venomanometer (Eyeteck Ltd, Boca Raton, FL) (Fig. 12) with the animals under general anesthesia. This episcleral venomanometer is similar to a Goldmann tonometer and mounts on a slit-lamp biomicroscope. This device was chosen because it is noninvasive and allows for serial measurements from the same eye. The clinical appearance of episcleral aqueous outflow vessels had been identified as those vessels running perpendicular to the limbus (Fig. 3). To measure EVP, the tip of the silicone membrane of the venomanometer was placed over an episcleral vein (~3 mm from the limbus) and the pressure was slowly increased by turning the venomanometer knob until the vessel was 50% blanched (Fig. 13). Each reading was repeated in triplicate and the median value recorded. Because it can take up to 5 days of daily dosing with latanoprost to achieve maximal IOP lowering, animals were dosed for 6 days before the first on-treatment EVP measurement. Each animal was treated with latanoprost 0.005% qd in 1 eye only, and the fellow, nondosed eye served as the control. Mean EVP in nondosed eyes remained between 8.76 and 9.85 mm Hg throughout the study. In treated eyes, mean EVP was found to be significantly higher than in nondosed fellow eyes at every measurement during the dosing period ( $P < 0.0001$ ; Fig. 14).



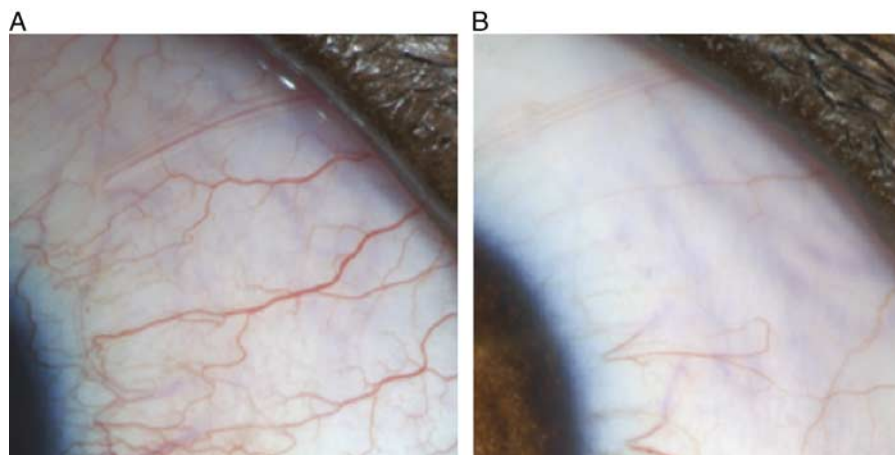
**FIGURE 14.** Mean episcleral venous pressure ( $\pm$ SD) for beagle dogs treated with topical 0.005% latanoprost on study days 9 to 29. Reprinted from Tsai et al,<sup>13</sup> publisher John Wiley and Sons, Inc., with permission. Copyright 2012 American College of Veterinary Ophthalmologists, Meridian, Idaho. All permission requests for this image should be made to the copyright holder.

The greatest increase in EVP occurred after 13 days of dosing: mean EVP was 15.01 mm Hg in treated eyes and 9.85 mm Hg in untreated fellow eyes.<sup>13</sup>

The effect of the bimatoprost intracameral implant on EVP was evaluated in a separate study.<sup>6</sup> In this study, EVP was measured in normotensive beagle dogs that were randomized to receive either bimatoprost intracameral implant 30  $\mu$ g (n = 7) or a sham injection (n = 7) in 1 eye. In addition, IOP was measured in a separate group of animals that had been trained for conscious IOP measurements and were treated with bimatoprost intracameral implant 30  $\mu$ g (n = 8). The method of EVP measurement was the same as used in the series of experiments with topical latanoprost.<sup>13</sup>



**FIGURE 15.** Mean EVP in eyes treated with bimatoprost intracameral implant or sham injection. Error bars represent the standard error of the mean. Bimatoprost SR indicates bimatoprost intracameral implant. EVP indicates episcleral venous pressure. \* $P < 0.05$  versus sham. Reprinted from Lee et al<sup>6</sup> with permission. Copyright the authors. All permission requests for this image should be made to the copyright holder.



**FIGURE 16.** Surface blood vessels in beagle dogs 72 days after (A) bimatoprost intracameral implant insertion or (B) sham injection. Reprinted from Lee et al<sup>6</sup> with permission. Copyright the authors. All permission requests for this image should be made to the copyright holder.

In contrast to the response to topical latanoprost, eyes treated with the bimatoprost intracameral implant exhibited a transient increase in EVP that peaked at day 8 (+2.3 mm Hg), followed by a gradual decrease to below baseline (−2.4 to −3.9 mm Hg) that was sustained through day 65 (Fig. 15). There was no significant change in EVP in the sham-treated eyes. In addition, eyes treated with the bimatoprost intracameral implant exhibited a sustained dilation of aqueous outflow vessels that was not seen in sham-treated eyes (Fig. 16).<sup>6</sup>

The results of these experiments might not be generalizable to all species, where significant differences in anatomy and baseline EVP measurements could potentially influence the results. In addition, use of the “50% blanched” endpoint in these dog studies may possibly have overestimated the true EVP. Nonetheless, the results suggest that EVP may play an important but different role in the ocular hypotensive effects of both topical and intracameral PGAs.

## DISCUSSION

The observation that the IOP-lowering dose-response for topical and intracameral bimatoprost is distinctly different suggests that intracameral delivery unlocks an additional mechanism of IOP lowering that is not accessible with topical delivery. Subtle differences in the nature of the hyperemia seen with the 2 routes of drug delivery<sup>6</sup> indicated that the episcleral vasculature was responding differently to topical and intracameral bimatoprost and suggested that the changes in EVP might also be different. Because EVP is so important in the determination of IOP,<sup>7,22</sup> it was hypothesized that different effects on EVP could be the cause of the different IOP-lowering profiles.

A tight linkage between EVP and IOP has been demonstrated in several experiments in animals and humans<sup>11,14,25</sup> and is a natural consequence of the fact that the episcleral veins comprise the distal portion of aqueous outflow through the conventional pathway.<sup>8</sup> It is not known what contribution, if any, is made by EVP to the normal control of IOP, but several characteristics of the episcleral vasculature suggest that it is a highly regulated vascular bed that serves an important physiological function. For

example, anatomic studies have revealed a muscle-rich venous network that is intensely innervated by vasodilative and vasoconstrictive nerves, and is connected to the episcleral arterioles by numerous AVAs.<sup>8–10</sup> It is also known that the episcleral vasculature and EVP are sensitive to several exogenously applied vasoactive substances.<sup>11,19–21</sup> In a series of elegant experiments in rabbits, Funk et al<sup>11</sup> demonstrated that pharmacologically induced vasodilation and vasoconstriction of the episcleral vasculature affect the flow of blood through the AVAs, which, in turn, affects EVP, the flow of aqueous into the episcleral veins, and IOP. Overall vasodilation (produced by nitroprusside) caused the AVAs to dilate, arterial blood to fill the venules, EVP to increase, the outflow of aqueous to decrease, and IOP to rise. Conversely, overall vasoconstriction (produced by epinephrine) caused the AVAs to collapse, the flow of arterial blood into the venules to cease, EVP to decrease, the outflow of aqueous to increase, and IOP to fall.<sup>11</sup>

Topical ocular hypotensive PGAs are known to produce vasodilation of the ocular surface vasculature,<sup>32,33</sup> so it is reasonable to expect that they may increase EVP. What is not immediately obvious, however, is how topical and intracameral delivery of the same class of drugs could have differing effects on EVP. The experiments of Funk et al<sup>11</sup> suggest that general vasodilation of the episcleral vasculature should cause an increase in both EVP and IOP. For an intracamerally delivered PGA such as bimatoprost to cause a decrease in EVP, it would have to produce selective vasodilation of the episcleral veins only, without opening the AVAs. Observations of the nature of the hyperemia associated with the bimatoprost intracameral implant in dogs suggested that this may indeed be the case; this hyperemia seems to be primarily caused by a selective vasodilation of the episcleral veins. This insight inspired a recent series of experiments to evaluate the effects of topical and intracameral PGAs on EVP in beagle dogs.<sup>6,13</sup>

These experiments in beagle dogs showed that topical and intracameral PGAs do have opposite effects on EVP that could explain their differing IOP-lowering profiles. Specifically, daily use of topical latanoprost caused a steady increase in EVP,<sup>13</sup> whereas the bimatoprost intracameral implant caused a smaller, transient increase in EVP,

followed by a sustained decrease.<sup>6</sup> The increase in EVP associated with topical application could be limiting the IOP-lowering efficacy of topical PGAs, whereas the decrease in EVP associated with the bimatoprost intracameral implant could explain its expanded range of IOP lowering. There may be other mechanisms involved as well. Differing drug levels achieved with the different routes of administration could potentially contribute to the differing IOP-lowering profiles of the intracameral implant and topical administration. In a study in dogs, maximal aqueous humor drug levels were ~7-fold higher after administration of the intracameral bimatoprost implant compared with topical bimatoprost administration.<sup>39</sup> Nonetheless, the EVP experiments suggest that at least part of the difference in the dose-response curves for topical and intracameral PGAs may be because of opposing effects on EVP.

In conclusion, although EVP is an important determinant of IOP, it has been an elusive target for therapeutic intervention in glaucoma and ocular hypertension, perhaps because of the complexity of the anatomy and physiology of the episcleral vasculature. By lowering EVP, the bimatoprost intracameral implant appears to unlock a new mechanism of PGA-mediated IOP lowering that is not accessible with topical application. Further research on EVP as a target for IOP lowering is indicated to improve our understanding of this potentially important pathway for treating patients with glaucoma.

#### ACKNOWLEDGMENTS

The authors thank Amy Lindsay, PhD, Lindsay Biomedical Communications Inc, Orange County, CA for providing writing assistance.

#### REFERENCES

- Prum BE Jr, Rosenberg LF, Gedde SJ, et al. Primary open-angle glaucoma Preferred Practice Pattern<sup>®</sup> guidelines. *Ophthalmology*. 2016;123:P41–P111.
- Sherwood M, Brandt J. Bimatoprost Study Groups 1 and 2. Six-month comparison of bimatoprost once-daily and twice-daily with timolol twice-daily in patients with elevated intraocular pressure. *Surv Ophthalmol*. 2001;45(suppl 4):S361–S368.
- Eveleth D, Starita C, Tressler C. A 4-week, dose-ranging study comparing the efficacy, safety, and tolerability of latanoprost 75, 100 and 125 µg/mL to latanoprost 50 µg/mL (Xalatan) in the treatment of primary open-angle glaucoma and ocular hypertension. *BMC Ophthalmol*. 2012;12:9.
- Lindén C, Alm A. Latanoprost twice daily is less effective than once daily: indication of receptor subsensitivity? *Curr Eye Res*. 1998;17:567–572.
- Lee S, Dibas M, Almazan A, et al. Dose-response of intracameral bimatoprost sustained-release implant and topical bimatoprost in lowering intraocular pressure. *J Ocul Pharmacol Ther*. 2019;35:138–144.
- Lee SS, Burke J, Shen J, et al. Bimatoprost sustained-release intracameral implant reduces episcleral venous pressure in dogs. *Vet Ophthalmol*. 2018;21:376–381.
- Sit A. Glaucoma opinion: episcleral venous pressure. *Int Glaucoma Rev*. 2015;16:12–15.
- McDougal DH, Gamlin PD. Autonomic control of the eye. *Compr Physiol*. 2015;5:439–473.
- Selbach JM, Rohen JW, Steuhl KP, et al. Angioarchitecture and innervation of the primate anterior episclera. *Curr Eye Res*. 2005;30:337–344.
- Selbach JM, Schönfelder U, Funk RH. Arteriovenous anastomoses of the episcleral vasculature in the rabbit and rat eye. *J Glaucoma*. 1998;7:50–57.
- Funk RH, Gehr J, Rohen JW. Short-term hemodynamic changes in episcleral arteriovenous anastomoses correlate with venous pressure and IOP changes in the albino rabbit. *Curr Eye Res*. 1996;15:87–93.
- Funk RH, Rohen JW. Scanning electron microscopic study of episcleral arteriovenous anastomoses in the owl and cynomolgus monkey. *Curr Eye Res*. 1996;15:321–327.
- Tsai S, Miller PE, Struble C, et al. Topical application of 0.005% latanoprost increases episcleral venous pressure in normal dogs. *Vet Ophthalmol*. 2012;15(suppl 1):71–78.
- Friberg TR, Sanborn G, Weinreb RN. Intraocular and episcleral venous pressure increase during inverted posture. *Am J Ophthalmol*. 1987;103:523–526.
- Walløe L. Arterio-venous anastomoses in the human skin and their role in temperature control. *Temperature*. 2015;3:92–103.
- Lovering AT, Riemer RK, Thébaud B. Intrapulmonary arteriovenous anastomoses. Physiological, pathophysiological, or both? *Ann Am Thorac Soc*. 2013;10:504–508.
- Zamora DO, Kiel JW. Topical proparacaine and episcleral venous pressure in the rabbit. *Invest Ophthalmol Vis Sci*. 2009;50:2949–2952.
- Strohmaier CA, Reitsamer HA, Kiel JW. Episcleral venous pressure and IOP responses to central electrical stimulation in the rat. *Invest Ophthalmol Vis Sci*. 2013;54:6860–6866.
- Zamora DO, Kiel JW. Episcleral venous pressure responses to topical nitroprusside and *N*-nitro-L-arginine methyl ester. *Invest Ophthalmol Vis Sci*. 2010;51:1614–1620.
- Kriegelstein GK, Langham ME, Leydhecker W. The peripheral and central neural actions of clonidine in normal and glaucomatous eyes. *Invest Ophthalmol Vis Sci*. 1978;17:149–158.
- Wilke K. Early effects of epinephrine and pilocarpine on the intraocular pressure and the episcleral venous pressure in the normal human eye. *Acta Ophthalmol*. 1974;52:231–241.
- Brubaker RF. Goldmann's equation and clinical measures of aqueous dynamics. *Exp Eye Res*. 2004;78:633–637.
- Sit AJ, McLaren JW. Measurement of episcleral venous pressure. *Exp Eye Res*. 2011;93:291–298.
- Phelps CD, Armaly MF. Measurement of episcleral venous pressure. *Am J Ophthalmol*. 1978;85:35–42.
- Blondeau P, Tétrault JP, Papamarkakis C. Diurnal variation of episcleral venous pressure in healthy patients: a pilot study. *J Glaucoma*. 2001;10:18–24.
- Marx J, Nandakumar N. Man referred for chronic red eye. Grand rounds at the New England Eye Center. Ocular Surgery News US Edition, May 10, 2010. Available at: [www.healio.com/ophthalmology/neurosciences/news/print/ocular-surgery-news/7Bd0dcae15-ed9-4d79-92d6-a1da6df08952%7D/man-referred-for-chronic-red-eye](http://www.healio.com/ophthalmology/neurosciences/news/print/ocular-surgery-news/7Bd0dcae15-ed9-4d79-92d6-a1da6df08952%7D/man-referred-for-chronic-red-eye). Accessed January 2, 2019.
- Watts P, Hawksworth N. Delayed hypersensitivity to brimonidine tartrate 0.2% associated with high intraocular pressure. *Eye*. 2002;16:132–135.
- Weinreb RN. Glaucoma secondary to elevated episcleral venous pressure. In: Ritch R, Shields MB, Krupin T, eds. *The Glaucomas*. St Louis: Mosby; 1989:1127–1140.
- Celebi S, Alagöz G, Aykan U. Ocular findings in Sturge-Weber syndrome. *Eur J Ophthalmol*. 2000;10:239–243.
- Foroozan R, Buono LM, Savino PJ, et al. Idiopathic dilated episcleral veins and increased intraocular pressure. *Br J Ophthalmol*. 2003;87:652–654.
- Cymbor M, Knapp E, Carlin F. Idiopathic elevated episcleral venous pressure with secondary glaucoma. *Optom Vis Sci*. 2013;90:e213–e217.
- Ogundele AB, Earnest D, McLaughlin MA. *In vivo* comparative study of ocular vasodilation, a relative indicator of hyperemia, in guinea pigs following treatment with bimatoprost ophthalmic solutions 0.01% and 0.03%. *Clin Ophthalmol*. 2010;4:649–652.
- Chen J, Dinh T, Woodward DF, et al. Bimatoprost: mechanism of ocular surface hyperemia associated with topical therapy. *Cardiovasc Drug Rev*. 2005;23:231–246.



34. Alm A, Villumsen J, Törnquist P, et al. Intraocular pressure-reducing effect of PhXA41 in patients with increased eye pressure: a one-month study. *Ophthalmology*. 1993;100:1312–1316.
35. Nagasubramanian S, Sheth GP, Hitchings RA, et al. Intraocular pressure-reducing effect of PhXA41 in ocular hypertension: comparison of dose regimens. *Ophthalmology*. 1993;100:1305–1311.
36. Lewis RA, Christie WC, Day DG, et al. Bimatoprost SR Study Group. Bimatoprost sustained-release implants for glaucoma therapy: 6-month results from a phase I/II clinical trial. *Am J Ophthalmol*. 2017;175:137–147.
37. Lee SS, Almazan A, Decker S, et al. Intraocular pressure effects and mechanism of action of topical versus sustained-release bimatoprost. *Transl Vis Sci Technol*. 2019;8:15.
38. Katz LJ, Cohen JS, Batoosingh AL, et al. Twelve-month, randomized, controlled trial of bimatoprost 0.01%, 0.0125%, and 0.03% in patients with glaucoma or ocular hypertension. *Am J Ophthalmol*. 2010;149:661–671.
39. Seal JR, Robinson MR, Burke J, et al. Intracameral sustained-release bimatoprost implant delivers bimatoprost to target tissues with reduced drug exposure to off-target tissues. *J Ocul Pharmacol Ther*. 2019;35:50–57.