

# An unusual presentation of traumatic pseudoaneurysm of axillary artery mimicking soft tissue tumor

**Authors:** B Dympep, S Khangarot & N Hadke

**Location:** Maulana Azad Medical College, New Delhi, India

**Citation:** Dympep B, Khangarot S, Hadke N. An unusual presentation of traumatic pseudoaneurysm of axillary artery mimicking soft tissue tumor. JSCR 2012 10:17

## ABSTRACT

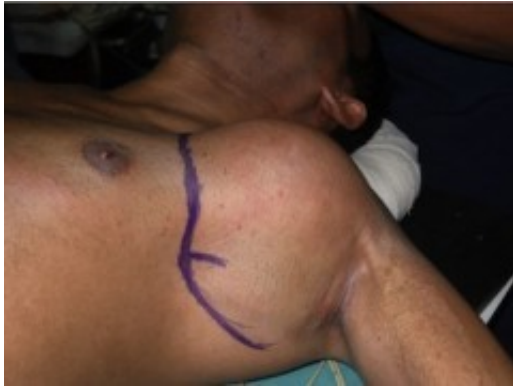Traumatic pseudoaneurysm of the axillary artery is a rare sequela of injury to shoulder region. We report here a unique case of delayed presentation of axillary artery pseudoaneurysm after a blunt injury, clinically mimicking soft tissue tumor without evidence of gross bony injury. The gentleman presented after six months of injury with a progressively growing mass in left axillary region and neurological deficit. Ultimate management of the lesion was surgical resection and Saphenous vein graft interpositioning. Unfortunately the lack of subsequent neurological recovery parallels some of the findings in the literature, from cases where decompression of the brachial plexus was not undertaken soon enough.

## INTRODUCTION

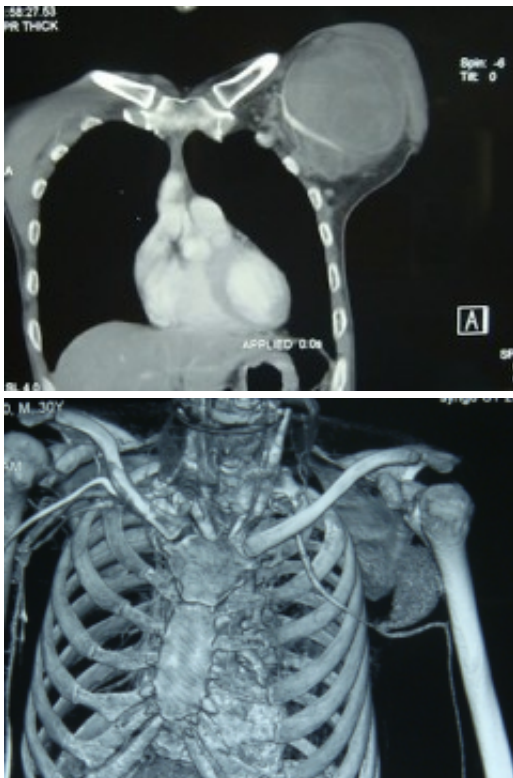
Pseudoaneurysms of the axillary artery are uncommon and usually encountered after penetrating or blunt trauma to the axilla (1). In the case of blunt trauma there tends to be an associated bony injury to the shoulder and most often an anterior dislocation (2), in which axillary artery damage has been reported at around 0.3% prevalence (3). Other injuries that have been described are fractures of the neck of the humerus and proximal humerus (4). The usual presenting complaint is a mass near the site of the trauma that is pulsating, painful, and warm. This pathology can lead to disastrous consequences if not suspected early (5). Indeed clinical suspicion can be lessened by the absence of hard initial signs of arterial injury (6) and the patient may present much later with potentially irreversible sequelae, particularly brachial plexus injuries (5). Here we describe a unique case, where the patient presented without typical features of pseudoaneurysm and no dislocation or fracture and indeed the full consequences of the injury only became apparent when significant secondary neurological deficit had occurred.

## CASE REPORT

A 30 year old patient presented to our institute after six months of an injury sustained to his left shoulder during a fall from a tree with complaints of progressively growing mass in left axillary region and gradual progression of neurological deficit to the point at which the arm became useless and insensate. On examination the mass was firm, non tender, fixed and non pulsatile (Fig. 1).



The left radial, ulnar and brachial pulses were palpable but decreased as compared to the right side. A clinical diagnosis of soft tissue tumor with neurovascular compression was made. Subsequent Doppler study to look for vascular compression revealed pseudoaneurysm of axillary artery, which was confirmed by CT angiography (Fig. 2,3).



The patient was taken up for surgical management. Exploration was done and the proximal and the distal part of the axillary artery were controlled with umbilical tape and brachial plexus cords were identified and preserved. After administering 1 cc heparin (5,000 IU) intravenously, we clamped the proximal and distal vascular structures and opened the capsule of the pseudoaneurysm with a direct incision. An organized thrombus in the aneurysm was removed. The capsule was dissected and evaluated histopathologically and microbiologically. In order to avoid increasing the risk of major hemorrhage or nerve injury, we did not resect the aneurysmal pouch completely. We limited the resection by preserving the adjacent tissues. A 5 cm arterial segment that included the pseudoaneurysmal region was resected. Saphenous vein graft interpositioning was then performed because vascular structure was not conducive to end-to-end anastomosis. A closed drainage system was placed in the aneurysmal pouch.

After hemostasis was achieved, the incision was closed. Post-operative period was uneventful and patient was sent for physical rehabilitation. There had been no recovery of neurological function in the arm at two months follow up.

## DISCUSSION

Aneurysms can develop in all arteries of the human body. Aneurysms at less common locations are generally due to major trauma, syphilis, Marfan syndrome, or infection. Atherosclerotic aneurysms are often seen in large arteries and in patients of advanced age, but pseudoaneurysms due to penetrating or blunt trauma are seen in patients of every age and at any location (7). Frequency of pseudoaneurysms in the upper extremities is much lower than that in the lower extremities. However, as lifespans increase and diagnostic and evaluation processes improve, the detection of such pseudoaneurysms is becoming more common. Infection, polyarteritis nodosa, congenital arterial defects, and especially trauma play a role in the pathogenesis of upper extremity pseudoaneurysms. If the only causal factor is trauma, the aneurysm takes the form of a pseudoaneurysm. Sometimes, as in our report, patients are admitted to hospitals with pseudoaneurysms months or years after the trauma (7,8). Pseudoaneurysms typically present as a mass near the site of the trauma that is pulsating, painful, and warm. Since this patient presented late and without any typical features of pseudoaneurysm or evident bony injury, it was misdiagnosed as soft tissue tumor.

Pseudoaneurysms after blunt trauma to the shoulder tend to occur in the third part of the axillary artery. One theory for this is the lesser mobility of this region of artery because of the relatively fixed nature of the circumflex humeral and subscapular arteries, leading to tearing of the axillary artery with attempts at mobilisation (3,4). Pseudoaneurysms of axillary artery are very rare in absence of bony injury in blunt trauma (9). In our case patient presented late with total paralysis of the arm secondary to a brachial plexus lesion. This has been described by several authors and can occur as a primary injury or delayed, as the aneurysm grows in size and compresses the plexus (10). Delay in decompression is of paramount importance for recovery (1). In this case decompression is delayed, with low likelihood of significant recovery. Two months post surgery, assessment by the rehabilitation team had not shown any sign of recovery. The poor outlook is supported by several authors, including Robbs *et al* (5), who reported 12 cases of delayed (after one to six weeks) compression of the brachial plexus by an axillary pseudoaneurysm in a variety of injuries. The outcome of the six patients presenting initially with total brachial plexus lesions were that none recovered fully and one showed no recovery whatsoever at 18 months. The lesion was repaired by open surgical approach so as to remove organised thrombus, which was causing compression of the neurovascular bundle of arm. An endovascular approach with insertion of a covered stent is a less invasive option for early cases of pseudoaneurysms.

## REFERENCES

1. [Gallen J, Wiss DA, Cantelmo N, Menzoin JO. Traumatic pseudoaneurysm of the axillary artery: report of three cases and literature review. J Trauma. 1984; 24:350](#)
2. [Fitzgerald KF, Keates J. False aneurysm as a late complication of anterior dislocation of](#)

- [the shoulder. Ann Trauma. 1975; 181:785](#)
3. [Bertrand JC, Maestro M, Pequignot JP, Mouiel Vascular complications of simple anterior dislocations of the shoulder. Three cases. J Ann Chir. 1982; 36:329](#)
  4. [Syed AA, Williams HR. Shoulder disarticulation: a sequel of vascular injury secondary to a proximal humeral fracture. Injury. 2002; 33:771](#)
  5. [Robbs JV, Naidoo KS. Nerve compression injuries due to traumatic false aneurysm. Ann Surg. 1984; 200:80](#)
  6. [Oberwader M, Thoni H, Brugger M, Pointer R. Traumatic aneurysm of the axillary artery, a rare and severe complication of anterior shoulder dislocation. Chirurg. 1994; 65:1056](#)
  7. [Johnston KW, Rutherford RB, Tilson MD, Shah DM, Hollier L, Stanley JC. Suggested standards for reporting on arterial aneurysms. Subcommittee on Reporting Standards for Arterial Aneurysms, Ad Hoc Committee on Reporting Standards, Society for Vascular Surgery and North American Chapter, International Society for Cardiovascular Surgery. J Vasc Surg. 1991; 13:452](#)
  8. [Tetik O, Yetkin U, Yilik L, Ozsoyler I, Gurbuz A. Right axillary pseudoaneurysm causing permanent neurological damage at right upper limb: A case report. Turk J Vasc Surg. 2002; 2:102](#)
  9. [Moss AJ, Valenti D, Fraser S, Murie J. An unusual shoulder injury. JSCR. 2011; 10:9](#)
  10. [Helm AT, Watson JS. Compression of the brachial plexus in a patient with a false aneurysm of the axillary artery as a result of anterior shoulder dislocation. J Shoulder & Elbow Surgery. 2002; 11:278](#)