

Rising Trend of “Veil Entanglement Injuries” in Northern Ghana: A Case Series

Alexis D. B. Buunaaim^{1,2}, Anwar Sadat Seidu^{1,2}, Mohammed Issah Suglo Bukari^{1,2}, John Abanga Alatiga¹, Kouakou Emile Tano³, Tolgou Yempabe¹

Learning Point of the Article:

“Veil entanglement injuries” is a silent cause of trauma and on a rising trend but is preventable through public awareness and modification of traffic regulations.

Abstract

Introduction: Veils are thin garments that are worn over the head, wrapped round the neck, and left hanging loosely over the torso up to the thighs. They are also known as scarf or “dupatta.” Veils can get entangled in spokes of motorbikes or in belt-driven machinery resulting in a variety of life-threatening injuries.

Case Reports: We report nine major cases of veil entanglement injuries (VEI) that presented to the Orthopedic Unit of Tamale Teaching Hospital from July 10, 2017 to June 12, 2020. All the patients were females with ages ranging from 5-months to 44-year. All the accidents involved either a motorbike or auto rickshaw. Head, neck, and extremity injuries were the most common. Eight out of nine patients had circumferential neck bruise referred to as “veil sign” in this report. One patient died.

Conclusion: The rising trend of VEI is alarming among women in Northern Ghana. We recommend widespread public education and awareness creation. We also recommend modification of traffic regulations by policy makers to avert this avoidable injury.

Keywords: “Dupatta,” long scarf injuries, “Isadora Duncan syndrome,” veil injuries.

Introduction

Veils, also referred to as scarf or “dupatta,” are thin garments that are worn over the head, wrapped around the neck, and left hanging loosely over the shoulders up to the thighs. These apparels are worn by women in South Asian countries as part of their culture. In other parts of the world, it is worn by Muslim women to disclose their identity and guard their modesty in fulfillment of their religious values [1].

Motorbike and belt-driven machinery are the major causes (75%) of veil entanglement injuries (VEI) [2, 3]. The affected age group is women between 18 and 45-years with a mean age of 32.4-years [3, 4]. Conventionally, women often ride pillion on motorbikes with their legs on one side or astride and their veils/scarfs over their heads, wrapped around their necks and

hanging loosely over the posterior aspect of their torso as shown in (Fig. 1). This increases the chances of their veils getting entangled with the spokes of the rear wheel of a moving motorbike or auto rickshaw shown in (Fig. 2). This avoidable practice is a cause of multiple injuries to various body regions [4]. There is paucity of scientific data on veil associated injuries in sub-Saharan Africa. We report nine major cases admitted to Orthopedic Unit of Tamale Teaching Hospital from July 10, 2017 to June 12, 2020. The minor cases are not included in this study as they were treated and discharged by the emergency department without admission. We seek to provide baseline information, create awareness on “VEI” and to provide recommendations to curb this avoidable practice.

Author's Photo Gallery



Dr. Alexis D. B. Buunaaim



Dr. Anwar Sadat Seidu



Dr. Mohammed Issah Suglo Bukari



Dr. John Abanga Alatiga



Dr. Kouakou Emile Tano



Dr. Tolgou Yempabe

Access this article online

Website:
www.jocr.co.in

DOI:
10.13107/jocr.2021.v11.i05.2194

¹Trauma/ Orthopedic unit, Tamale Teaching Hospital, Box TL 16, Tamale, Ghana.

²Department of Surgery, School of Medicine and Health Sciences, University for Development Studies, Box TL 1350, Tamale, Ghana.

³Department of Surgery, Komfo Anokye Teaching Hospital, Box KS 1934, Kumasi, Ghana.

Address of Correspondence:

Dr. Alexis D. B. Buunaaim,
Trauma/Orthopaedic unit , Tamale Teaching Hospital, Box TL 16, Tamale, Ghana.
E-mail: abuunaaim@yahoo.co.uk



Figure 1: A pillion motorbike rider wearing a long veil hanging loosely, rear spokes have no saree guards.



Figure 2: An auto rickshaw.

Case Series

Case 1

A 43-year-old female not helmeted motorbike rider whose veil got trapped in the spokes of the rear wheel of her motorbike. She felt a sudden forceful pull on her neck, falling to the ground and sustained multiple facial abrasions, bruises on the neck and inability to move all her limbs. On examination, she was fully conscious with multiple facial abrasions with a circumferential bruise on her neck. The power was 0/5 in all limbs with sensory level at C1. Rectal sphincter tone was lax. Cervical computed tomography (CT) scan showed fracture of the odontoid with cord compression as shown in Fig. 3. Head CT scan was grossly normal. She was admitted with diagnoses of (1) odontoid fracture with cord compression and (2) multiple facial and neck

abrasions.

A cervical traction was applied and power in both upper limbs (4/5) and lower limbs (4/5) progressively improved weeks later. Physiotherapy was commenced and patient was subsequently discharged home.

Case 2

A 22-year-old female was riding a motorbike without a helmet when her veil got entangled in the wheel of the bike. She fell on the ground and landed on the neck. On examination, she was hemodynamically stable. Her Glasgow coma score (GCS) = 14/15, and power of 2/5 in upper limbs and 0/5 in lower limbs with sensory level at T4. Rectal sphincter tone was lax. She had a

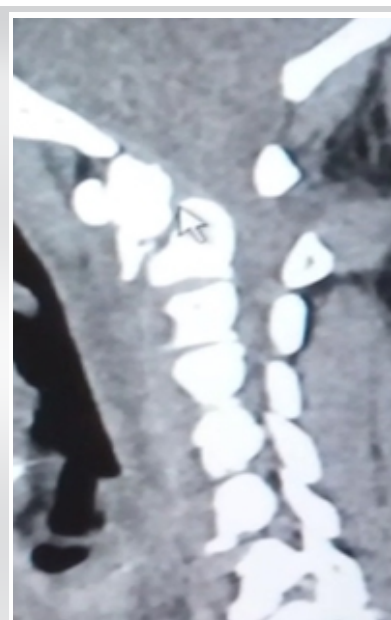

Figure 3: Odontoid fracture with cord compression.

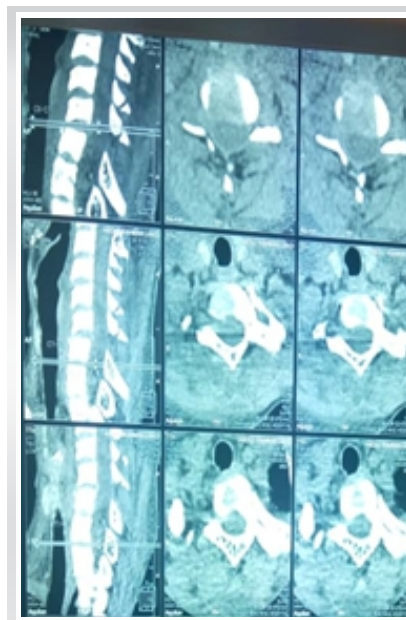


Figure 4: Listhesis of C5/C6 with cord compression.

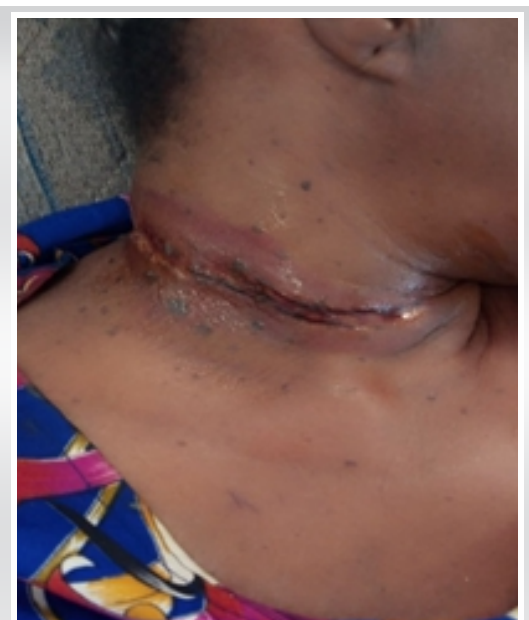

Figure 5: Circumferential neck bruise "veil sign."

circumferential bruise on the neck. Pupils were equal and reactive to light. Head CT scan showed mild cerebral edema. Cervical CT scan showed a non-displaced fracture of C6 vertebral body, traumatic listhesis of C5/C6 (Grade II) as shown in Fig. 4. Diagnoses of (1) traumatic listhesis of C5/C6 with cord compression, (2) non-displaced fracture of C6 vertebral body, and (3) cerebral edema were made.

The cerebral edema was managed medically. She subsequently developed aspiration pneumonitis and died.

Case 3

A 35-year-old nursing mother was riding a motorbike with her 5-month old baby strapped to her back. Her veil got entangled with the spokes of the rear wheel of her bike. She was thrown off the bike and landed on her left side with the baby at her back. On examination, she had a 5 cm laceration below the left eyebrow and circumferential neck bruise. She had mild tenderness over the posterior aspect of her cervical region with no step deformity. The power was normal in all limbs. Her left shoulder was swollen, tender at shoulder tip, but no step deformity. Cervical and left shoulder X-ray was normal. Diagnosis of (1) Whiplash associated disorder (grade II), (2) Left Acromioclavicular injury (Grade I), and (3) facial laceration were made. Patient was managed with analgesia, soft neck collar, and arm sling. Laceration was sutured under local anesthesia.

Case 4

A 5-month-old baby was a victim of veil entanglement of case 3. She had a swollen and tender distal third of the left thigh. Left femur X-ray showed a metaphyseal injury. A diagnosis of metaphyseal injury of distal left femur was made. She was managed with full cast Plaster of Paris full cast for 4 weeks.

Case 5

A 28-year-old female, not helmeted pillion rider veil got stuck in the rear wheel pulling her to the ground. She fell on her left hip and immediately felt a sharp pain in her hip. On examination, she had a neck bruise and deformed left thigh. X-ray showed intertrochanteric fracture of left femur. Open reduction and internal fixation with dynamic hip screw were performed.

Case 6

A 21-year-old female pillion rider presented to the emergency department with a painfully deformed left hip following a road traffic accident. Her veil got entangled with the spokes of her rear wheel and she fell off the motorbike and landed on her left hip. On examination, she had a circumferential neck bruise

referred to as the “veil sign” in this report as shown in Fig. 5. She also had a tender swollen left hip with knee in extension. Left lower limb was shortened and internally rotated. Distal neurovascular status was normal. A pelvic X-ray showed posterior hip dislocation with no associated acetabular fracture. The dislocation was reduced under sedation and a repeat X-ray confirmed congruent reduction.

Case 7

A 19-year-old female presented with a complaint of neck pain following an accident involving an auto rickshaw (also known as tuk-tuk/mototaxi). She was a pillion rider on an auto rickshaw when her veil got stuck in the wheel and threw her onto the ground. On examination, she had a circumferential neck bruise, tender on posterior aspect of the neck. Neurological examination was normal. Cervical X-ray was grossly normal. She was admitted as a case of Whiplash associated disorder (Grade II). She was managed with analgesia and soft cervical collar and discharged home.

Case 8

A 31-year-old female, gravida 6 para 5 all at 30 week's gestation was a pillion rider without a helmet. Her veil got trapped in the rear wheel of the moving motorbike. She fell off the bike and a painful swollen right shoulder. She presented with loss of consciousness and a painful swollen right shoulder. On examination, her GCS was 11/15 and there was a circumferential neck bruise and tender swollen right shoulder with step deformity. Her pupils were equal and reactive to light. Head CT scan showed moderate cerebral edema, with no midline shift or hemorrhage. Right shoulder X-ray showed a lateral third clavicular fracture. Diagnoses of (1) moderate cerebral edema and (2) right clavicular fracture were made. The cerebral edema was managed medically while the clavicular fracture was managed with open reduction and internal fixation with plates and screws.

Case 9

A 44-year-old female, not helmeted pillion motorbike rider whose scarf got trapped in the spokes of the rear wheel of the moving bike. She was thrown off the bike falling on her left thigh and dragged along until the bike stopped. She sustained multiple facial and neck abrasions and swollen painfully deformed left thigh with a step deformity. X-ray showed a left midshaft femur fracture. She was counseled for Locked Intramedullary Nailing but opted to be managed by a traditional bone setter.

Discussion

Isadora Duncan, a world-famous dancer died tragically from strangulation on September 14, 1929, when her long scarf got entangled in the wheels of her Bugatti. She died at the scene following a fractured spinal cord and larynx and torn carotid arteries [5, 6]. This case report was the first in scientific literature to create public awareness on this pattern of injury, now known as the “Isadora Duncan syndrome.” Kohli et al. (1996) and Gupta et al. (2004) reported scarf related accidental strangulations that resulted in mortality [7, 8]. They indicated the dangers of wearing loose clothing while riding pillion [7, 8]. Chiu et al. (2010) reported a middle aged woman who sustained a type 1 Hangman’s fracture from such a mechanism [9].

In most developing countries, motorbikes and auto rickshaws are the most common means of transport in both rural and urban areas. Motorcycles are the most common cause (46.1%) of VEI [3]. In this case series, all the cases involved were riding either a motorbike or an auto rickshaw. The Northern region of Ghana is predominantly Muslim, and it is common practice for women to complete their dressing with long veils. With the increasing use of motorbikes, this practice will cause a rise in VEI. The age range in this report was from 5-month to 44-year. To the best of our knowledge, this 5-month old baby is the youngest victim of VEI in the literature per our review. Case 2 succumbed to aspiration pneumonitis shortly after admission. This illustrates that VEI may be very fatal and can result in death in some instances. Beigh and Ali (2016) demonstrated that anterior neck bruise was a common injury among cases of VEI [10]. In this study, 8 out of 9 of the cases had a circumferential neck bruise casually referred to as the “veil sign” in this report.

Veil entanglement causes a variety of injuries, mostly minor (89.11%). It is also a cause of significant number of major injuries (10.89%) [4]. Injuries involving the head and neck, extremities, and the external account for the majority of the cases [4, 11]. In this report, head and neck and extremity injuries were the most common, accounting for 55.6% and 66.7%, respectively. The most common factor in all these injuries is the long veil. It is, therefore, not surprising that all the cases were females who are the most vulnerable in this regard. Khan et al. (2012) reported females (73.9%) and pillion riders

(80.6%) as the major victims of clothing related accidents [11]. Women are the backbone of every home in our society. They nurse the children as well as manage the daily activities of every household. When a woman is incapacitated by an avoidable injury such as this, it indirectly affects the whole household and the nation at large. There are probably more VEI than presented in this report, partly because most cases are minor and will seek treatment from other health facilities. The lack of a common electronic health record system makes multicenter retrospective studies almost impossible. To determine the gravity of this practice, a prospective multicenter study may be required.

Conclusion

The increasing trend of VEI or otherwise “Isadora Duncan syndrome” is alarming with all the victims being the women of our society. The victims of these injuries are both children and adults, it does not discriminate. The injuries resulting from this phenomenon are varied, commonly involving the head, neck, and extremities in this series. It can also result in death in some instances.

We recommend widespread public education and awareness creation on the gravity of VEI. People should be responsible for their personal protection. Females who wear long veils should be educated to wear short veils anytime they ride a motorbike or auto rickshaw. Failing at that, they should be entreated to tuck their long veils into their clothing to prevent it from hanging loosely. The Motor Transport and Traffic Unit (MTTU) of the Police Service should consider modifying the dress code in the traffic regulations to reduce these avoidable injuries. They should also consider enforcing the use of saree guards to reduce the chances of veils getting entangled.

Clinical Message

VEI is on the rise with the increasing use of motorbikes and auto rickshaw for transport. This avoidable practice is a major cause of injuries to the head, neck, and extremities. Women are the major victims, but children are not spared.

References

1. An-Nur S. [24: 31]-Al-Qur’an Al-Kareem; 2020. Available from: <https://www.quran.com>. [Last accessed on 2020 Aug 27].
2. Jain V, Agrawal M, Dabas V, Kashyap A, Sural S, Dhal A. Dupatta (scarf): A unique cause of cervical spine injury in females. *Injury* 2008;39:334-8.
3. Singh P, Kumar A, Shekhawat V. Scarf-related injuries at a major trauma center in northern India. *Chin J Traumatol* 2017;20:90-3.
4. Minhas MS, Sangani MM, Mehmood K, Bhatti A, Mughal A,



- Kumar R. Dupatta (long scarf) related injuries in female pillion riders in Karachi Pakistan. *J Pak Med Assoc* 2016;66:1458-61.
5. Benecke M. *Ungewollte Strangulation Durch Ein Fahrzeug: Der Tod Von Isadora Duncan*. Germany: Springer; 2020. Available from: <https://www.link.springer.com/article>. [Last accessed on 2020 Oct 15].
 6. Siddiqui A, Mushtaq SM, Jooma R, Enam SA. Long scarf injuries. *J Coll Physicians Surg Pak* 2006;16:152-3.
 7. Aggarwal NK, Agarwal BB. Accidental strangulation in a cycle rickshaw. *Med Sci Law* 1998;38:263-5.
 8. Gupta BD, Jani CB, Datta RG. Case reports. 2. Accidental strangulation: A case report. *Med Sci Law* 2004;44:359-62.
 9. Chiu CK, Chan CY, Saw LB, Kwan MK. Scarf-related hangman's fracture: A case report. *Eur J Trauma Emerg Surg* 2010;36:180-2.
 10. Beigh Z, Ali I. Long scarf syndrome; accidental strangulation due to long scarf. *J Health Educ Res Dev* 2016;4:1. Available from: <http://www.esciencecentral.org/journals/long-scarf-syndrome-accidental-strangulation-due-to-long-scarf-2380-5439-1000162.php?aid=69128>. [Last accessed on 2020 Aug 13].
 11. Khan UR, Bhatti JA, Shamim MS, Zia N, Razzak JA, Jooma R. Clothing-related motorcycle injuries in Pakistan: Findings from a surveillance study. *Int J Inj Contr Saf Promot* 2015;22:308-13.

Conflict of Interest: Nil

Source of Support: Nil

Consent: The authors confirm that informed consent was obtained from the patient for publication of this case report

How to Cite this Article

Buunaaim ADB, Seidu AS, Bukari MI, Alatiga JA, Tano KE, Yempabe T. Rising Trend of "Veil Entanglement Injuries" in Northern Ghana: A Case Series. *Journal of Orthopaedic Case Reports* 2021 May;11(5): 33-37.