



## Purtscher-like retinopathy following total knee arthroplasty: A report of 2 cases

Siyang Chaili<sup>a</sup>, Audrey Mok<sup>b</sup>, Sean D. Adrean<sup>c,\*</sup>

<sup>a</sup> Vanderbilt Eye Institute, Vanderbilt University Medical Center, 2311 Pierce Ave. Nashville, TN, 37232, USA

<sup>b</sup> Eye Treatment Center, 3900 Long Beach Blvd, Long Beach, CA, 90807, USA

<sup>c</sup> Retinal Consultants of Orange County, 301 W Bastanchury Rd #285, Fullerton, CA, 92835, USA

### ARTICLE INFO

#### Keywords:

Immunology  
Ocular trauma  
Purtscher-like retinopathy  
Retinal vascular disease

### ABSTRACT

**Purpose:** To describe two cases of Purtscher-like retinopathy after total knee arthroplasty.

**Observations:** Two patients were referred for blurred vision after knee surgery. They received a complete vision examination including slit lamp exam, dilated fundus exam, fluorescein angiogram and optical coherence tomography. Two patients developed Purtscher-like retinopathy after knee surgery. The first was a 58-year-old male who underwent bilateral total knee arthroplasty. The second patient developed an infected joint and subsequently received a total knee arthroplasty revision surgery. Both patients experienced decreased vision and were found to have characteristic findings of Purtscher-like retinopathy including vessel attenuation, cotton wool spots and nerve fiber layer infarcts following their respective operations in the absence of other injury.

**Conclusions and Importance:** Purtscher-like retinopathy can occur immediately following total knee arthroplasty. Factors including fatty acid liberation, endothelial damage, aberrant coagulation cascade activation, leukocyte aggregation, embolic vascular occlusion and microinfarction likely contributed to these findings. When patients undergo knee arthroplasty and complain of visual scotomas, the diagnosis of Purtscher-like retinopathy should be considered with careful ophthalmic examination and work-up.

Meeting Presentation: None.

### 1. Introduction

Purtscher's retinopathy was originally described in 1910 by Otmar Purtscher after observing characteristic retinal findings in a patient that suffered severe, non-ocular trauma.<sup>1</sup> Purtscher-like retinopathy occurs when characteristic findings of Purtscher's retinopathy (PuR) occur in the absence of trauma, including cotton wool spots and retinal hemorrhages.<sup>2</sup> Various clinical conditions have been associated with Purtscher-like retinopathy, the most common being acute pancreatitis.<sup>2,3</sup> Evidence for the pathogenesis involving boney structures have pointed to vascular occlusion by liberated fatty emboli and inflammatory damage.<sup>4-6</sup> However, in the operative setting, other factors such as direct endothelial damage, venous stasis and aberrant activation of the clotting cascade may lead to thromboembolic events which precipitate typical findings of Purtscher-like retinopathy.<sup>7,8</sup> This report describes two patients who experienced decreased vision and had signs of Purtscher-like retinopathy after orthopedic surgery. The first patient

underwent a total knee arthroplasty (TKA) revision and the second patient received bilateral TKA.

### 2. Findings

#### 2.1. Case one

A 68-year-old male with past medical history of renal disease and benign prostatic hyperplasia had a revision of his TKA. Immediately after surgery, he complained of seeing a large dark area in the right eye, and centrally he felt like he was looking through a thin fog. His past ocular history included LASIK. Best corrected vision was 20/40 + 1 OD and 20/30-1 OS. His slit lamp exam (SLE) was unremarkable. Dilated fundus exam (DFE) of the right eye showed three nearly contiguous large cotton wool spots (CWS) with hemorrhage inferonasal to the fovea and several other scattered CWS (Fig. 1A and B). The fluorescein angiogram (FA) showed retinal nonperfusion in the areas of the CWS (Fig. 1C). Over the next 3 months the CWS resolved and the patient reported better vision (Fig. 1D and E).

\* Corresponding author. 301 W. Bastanchury Ave #285, Fullerton, CA, 92835, USA.

E-mail address: [seadrean@yahoo.com](mailto:seadrean@yahoo.com) (S.D. Adrean).

<https://doi.org/10.1016/j.ajoc.2020.100945>

Received 25 April 2020; Received in revised form 22 August 2020; Accepted 20 September 2020

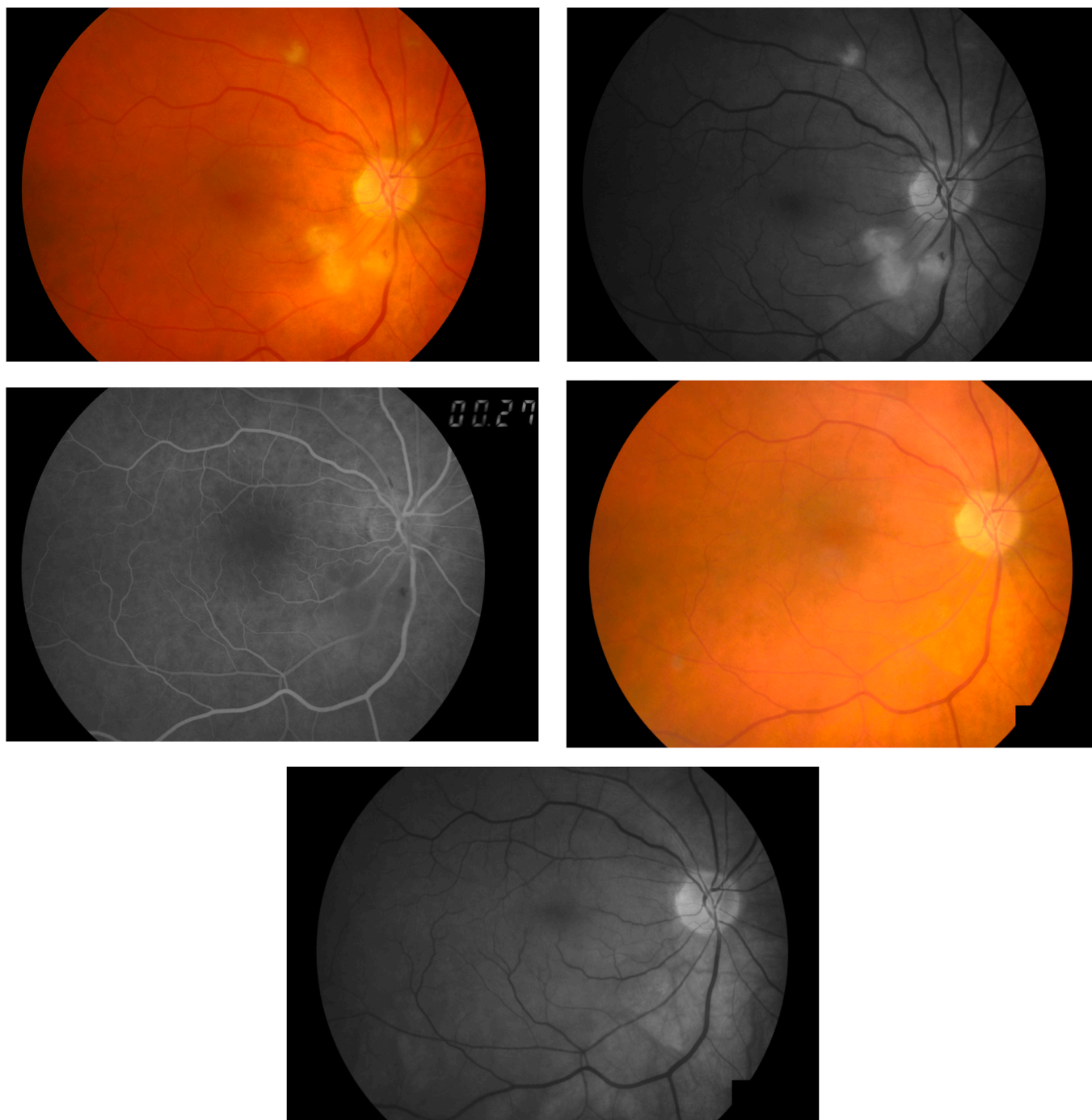
Available online 2 October 2020

2451-9936/© 2020 Published by Elsevier Inc. This is an open access article under the CC BY-NC-ND license (<http://creativecommons.org/licenses/by-nc-nd/4.0/>).

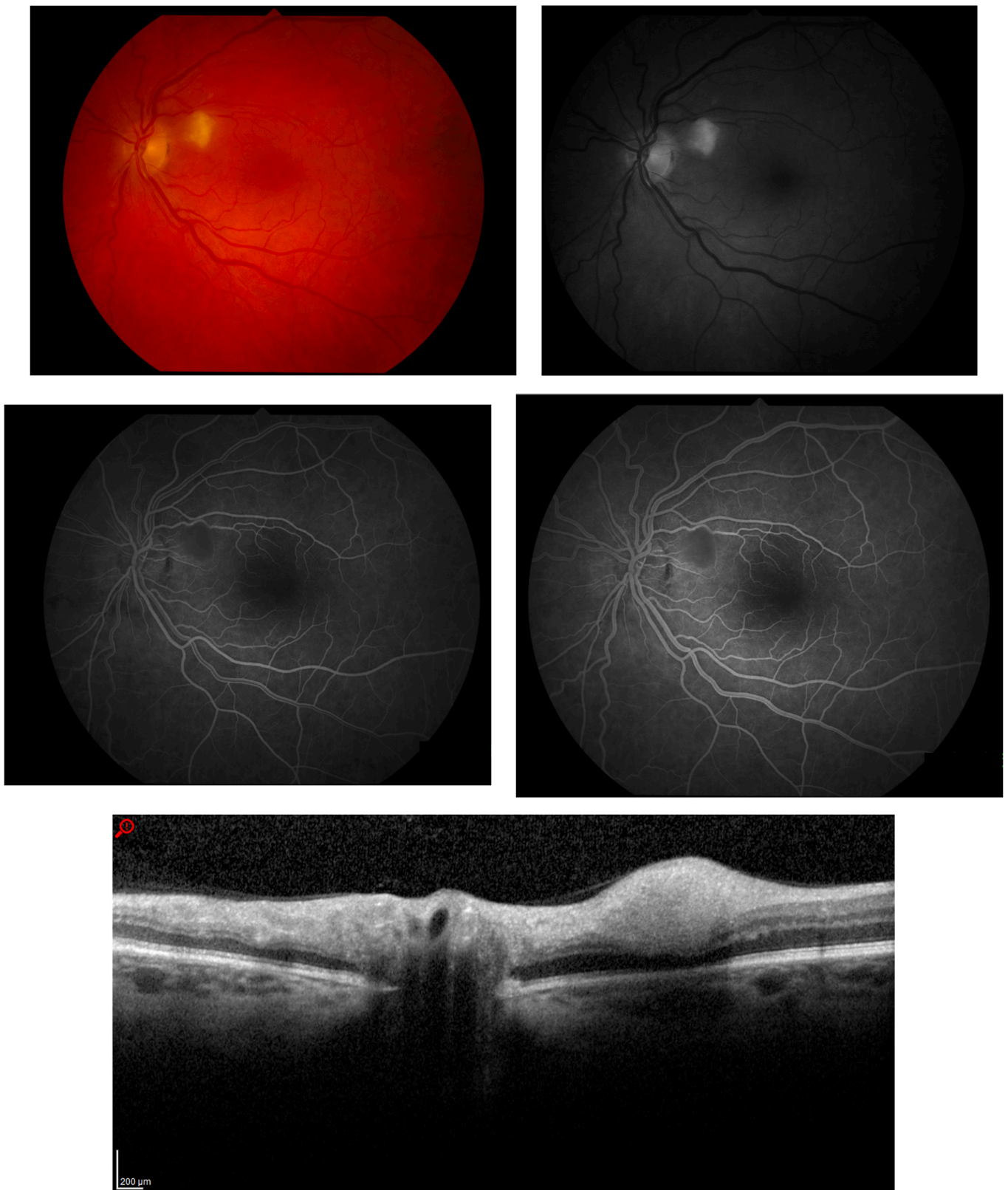## 2.2. Case two

A 58-year-old gentleman with a past medical history of hypertension underwent bilateral total knee arthroplasty (TKA). Immediately after the operation he saw a “puzzle-piece missing” in his left eye with no changes to the vision in the right eye. His past ocular history included bilateral photorefractive keratectomy and blepharoplasty. Two weeks later he presented with best corrected visual acuity of 20/20 in both eyes and normal pressures. His DFE showed normal optic nerves with

multiple CWS nasal to the fovea in the right eye. The vessels were attenuated. The left eye also had a large CWS superonasal to the fovea (Fig. 2A and B) with vessel attenuation. The retinal periphery was normal. FA showed several defects including areas of retinal non-perfusion corresponding to the CWS (Fig. 2C and D). Spectral-domain optical coherence tomography (SD-OCT) showed nerve fiber layer infarcts and accumulation of axoplasmic material at the CWS (Fig. 2E), but no fluid or exudation. He was observed, and two months later stated that the missing “puzzle piece” was resolving. His vision remained stable at



**Fig. 1.** Purtscher-like Retinopathy after Total Knee Arthroplasty Revision. Patient who saw a large dark area in the right eye for four days after surgery found with three nearly contiguous large cotton wool spots inferonasal to the fovea with hemorrhage and several other scattered CWS in the posterior pole. A) color photograph at presentation, B) red free photograph at presentation, C) FA with retinal nonperfusion in the areas of the CWS, D) color photograph at resolution of CWS and improvement in vision, E) red free photograph at resolution. (For interpretation of the references to color in this figure legend, the reader is referred to the Web version of this article.)



**Fig. 2.** Purtscher-like Retinopathy after Bilateral Total Knee Arthroplasty. 58-year-old gentleman who saw a “puzzle piece missing” in his left eye found with large cotton wool spot superonasal to the fovea with retinal vessel attenuation. A) Color fundus photograph at presentation, B) red free photograph at presentation, C) pre-laminar phase FA with retinal nonperfusion in areas of the CWS, D) laminar phase FA, E) OCT through CWS showing accumulation of axoplasmic material in the retinal nerve fiber layer, F) color photograph at resolution with visual improvement, G) red free photograph at resolution, H) OCT at resolution. (For interpretation of the references to color in this figure legend, the reader is referred to the Web version of this article.)

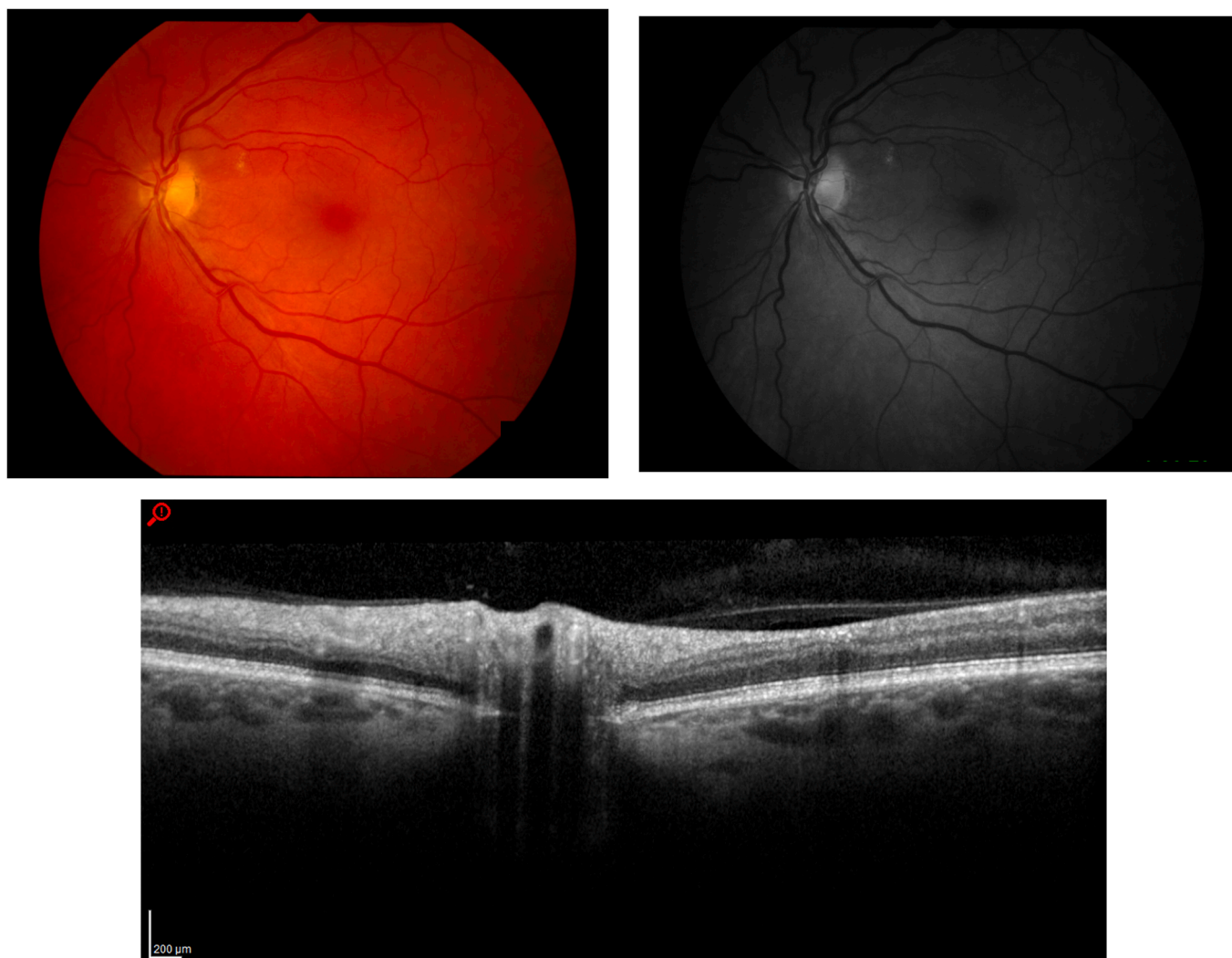


Fig. 2. (continued).

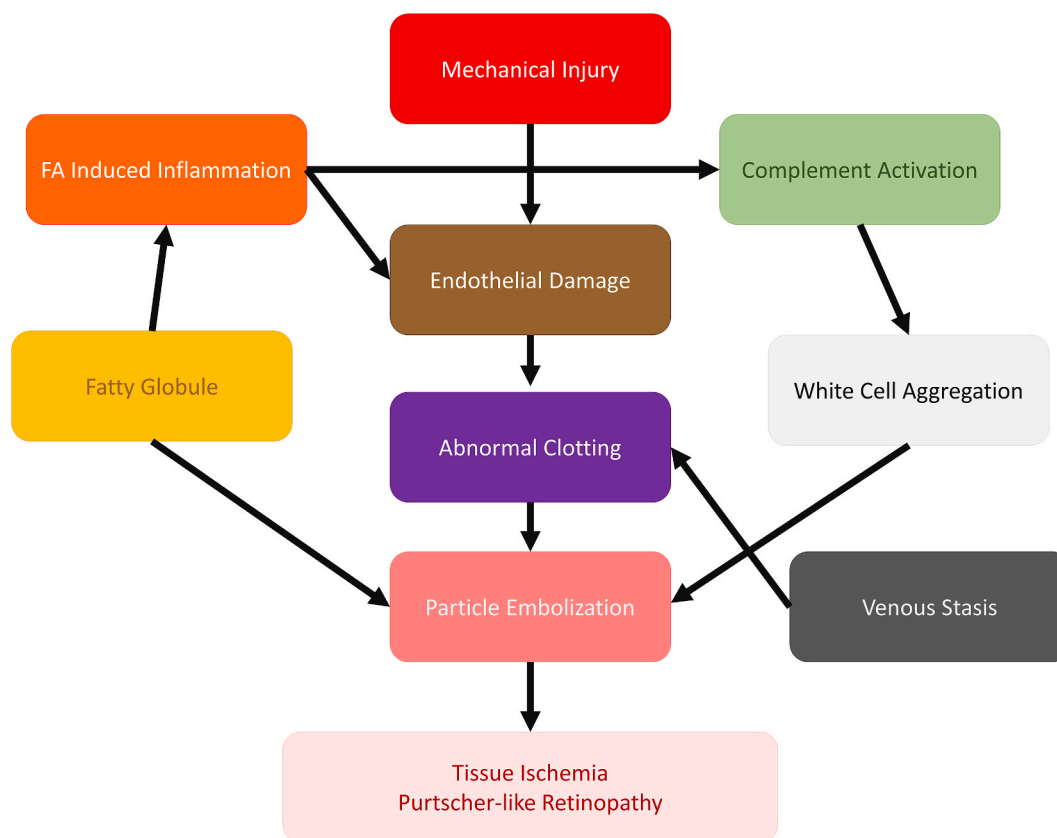
20/20. Fundus exam showed resolution of the cotton wool spots (Fig. 2F and G) and SD-OCT demonstrated resolution of nerve fiber layer infarcts and axoplasmic accumulation at the areas of CWS (Fig. 2H).

### 3. Discussion

Several factors may have contributed to the patients' development of Purtscher-like retinopathy (Fig. 3). First, surgical trauma of the femur and tibia during TKA, like in long bone fractures, may release fatty globules producing several parallel mechanisms leading to the characteristic anatomic findings of PuR and visual sequelae.<sup>2-6</sup> Partial or complete retinal vessel occlusion due to coalescence of fatty globules may limit perfusion to several structures including the retina, choroid or distal retinal vessels, manifesting as retinal vessel attenuation and CWS on DFE.<sup>4,5</sup> Tissue hypoxia in these areas may result in decreased vision at the corresponding visual fields. Moreover, toxic fatty acid inflammation may also precipitate endothelial damage, pathologically activating coagulation cascades and further impeding capillary flow and worsening retinal hypoxia.<sup>5</sup> Properdin and C-reactive protein recognition of Damage-Associated Molecular Proteins (DAMPs) activates the core alternative complement pathways, promoting granulocyte aggregation and leukocytoclastic emboli.<sup>9</sup> With progressive endothelial destruction and loss of vessel integrity, hemorrhage ensues. These factors may have contributed to the visual scotomas and associated retinal findings. Liberation of fatty globules may be common during orthopedic

operations and difficult to prevent. It is also likely that the greater number of bones or joints operated on during a given surgery would increase the chances that fatty emboli or fatty acid inflammation and its sequelae would occur. Given that the eye possesses many small caliber structures, changes in vision following orthopedic procedures should be referred for evaluation, even in the absence of systemic symptoms.

Surgery itself is a form of controlled trauma and increases the risk of thromboembolism with its complications, including Purtscher-like retinopathy.<sup>7,8</sup> It is standard practice to administer post-operative anticoagulation, particularly for orthopedic operations.<sup>7</sup> Venous stasis secondary to leg positioning and increased endothelial injury from surgical manipulation may lead to aberrant activation of the clotting cascade, precipitating thromboemboli in the orthopedic intraoperative and postoperative period.<sup>7</sup> These additional factors may have served as the inciting event or further aggravated retinal damage in the setting of fatty embolization and inflammation. Interestingly, a recent review found that only 45.9% of patients undergoing lower limb orthopedic operations and given pharmacology anticoagulation were within the therapeutic range for anticoagulation following surgery.<sup>7</sup> Patients with a hypercoagulable disorder were also more likely to develop venous thromboembolism.<sup>6</sup> It is possible that patients who are relatively under-anticoagulated due to an underlying known or unknown hypercoagulable disorder may experience Purtscher-like retinopathy due to thrombotic microemboli that occlude ocular vessels. Moreover, cases with longer operating times or greater operative sites will likely have



**Fig. 3.** Mechanisms Contributing to Purtscher-like Retinopathy in Orthopedic Surgery. Mechanical injury and release of fatty acids (FA) contribute to endothelial damage leading to abnormal clotting and thrombus formation. Venous stasis further promotes abnormal clotting. Inflammation induced complement activation leads to white cell activation and aggregation. Fatty globules are directly released from bones. All etiologies lead to a common pathway of particle embolization and tissue ischemia resulting in the anatomical findings observed in Purtscher-like Retinopathy.

greater endothelial damage and venous stasis, aberrant coagulation and chances of thromboembolism. Thus, patients who experience decreased vision or scotomas after surgery should be evaluated for Purtscher-like retinopathy. The development of Purtscher-like retinopathy following surgery may indicate that a patient has received inadequate post-operative anticoagulation or has an undiagnosed hypercoagulable disorder.

Both patients were closely observed and the visual scotomas improved. Clinical findings such as optic disk swelling with disc leakage on FA or decreased vascular perfusion with involvement of the outer retina may signal poor visual prognosis, and were not observed in these patients.<sup>3</sup> There is currently no definitive treatment for PuR or Purtscher-like retinopathy. Reports have described the use of corticosteroids as therapy, however little evidence has demonstrated its superiority over observation alone.<sup>9,10</sup> Given that bystander immune cell damage is a contributing factor in certain precipitants of PuR, corticosteroids may have some impact when damage is predominantly inflammatory. However, in cases of hypercoagulability, as with surgery, optimizing anti-coagulation may be more appropriate for the prevention of PuR. Many cases are likely multifactorial, and a detailed history and close monitoring for decreased vision may lower the risk of poor visual outcomes. Fortunately, in both of these cases, the damage was not centrally located and the symptoms resolved without any permanent sequelae. When patients have TKA and complain of visual loss or scotomas, the diagnosis of Purtscher-like retinopathy should be considered and they should be referred for careful ophthalmic examination and work up.

#### 4. Conclusions

Purtscher-like retinopathy can occur immediately following total knee arthroplasty. Factors including fatty acid liberation, endothelial damage, aberrant coagulation cascade activation, leukocyte aggregation, embolic vascular occlusion and microinfarction are likely contributing factors. When patients undergo knee arthroplasty and complain of visual scotomas, the diagnosis of Purtscher-like retinopathy should be considered with referral for careful ophthalmic examination and work-up.

#### Patient consent

The patients consented to publication of the case orally; and, this report does not contain any personal information that could lead to the identification of the patient.

#### Funding sources

None.

Authorship: All authors attest that they meet the current ICMJE criteria for Authorship.

#### Declaration of competing interest

None.

#### Acknowledgements

None.

## References

1. O P.. Noch unbekannte befunde nach schadeltrauma. *Ber Dtsch Ophthalmol Ges.* 1910;36:294–301.
2. Miguel AI, Henriques F, Azevedo LF, et al. Systematic review of Purtscher's and Purtscher-like retinopathies. *Eye.* 2013 Jan;27(1):1–13. <https://doi.org/10.1038/eye.2012.222>.
3. Agrawal A, McKibbin MA. Purtscher's and Purtscher-like retinopathies: a review. *Surv Ophthalmol.* 2006 Mar-Apr;51(2):129–136.
4. Chuang EL, Miller 3rd FS, Kalina RE. Retinal lesions following long bone fractures. *Ophthalmology.* 1985 Mar;92(3):370–374.
5. Roden D, Fitzpatrick G, O'Donoghue H, et al. Purtscher's retinopathy and fat embolism. *Br J Ophthalmol.* 1989 Aug;73(8):677–679.
6. Scotton WJ, Kohler K, Babar J, et al. Fat embolism syndrome with Purtscher's retinopathy. *Am J Respir Crit Care Med.* 2013 Jan 1;187(1):106. <https://doi.org/10.1164/rccm.201205-0881IM>.
7. Bawa H, Weick JW, Dirschl DR, et al. Trends in deep vein thrombosis prophylaxis and deep vein thrombosis rates after total hip and knee arthroplasty. *J Am Acad Orthop Surg.* 2018 Oct 1;26(19):698–705. <https://doi.org/10.5435/JAAOS-D-17-00235>.
8. Takakura A, Stewart PJ, Johnson RN, et al. Purtscher-like retinopathy after prostate surgery. *Retin Cases Brief Rep.* 2014 Fall;8(4):245–246. <https://doi.org/10.1097/ICB.0000000000000111>.
9. Sellami D, Ben-Zina B, Jelliti B, et al. Purtscher-like retinopathy in systemic lupus erythematosus. Two cases. *J Fr Ophthalmol.* 2002;25(1):52–55.
10. Atabay C, Kansu T, Nurlu G. Late visual recovery after intravenous methylprednisolone treatment of Purtscher's retinopathy. *Ann Ophthalmol.* 1993;25(9):330–333.