

Case Report

Nonconvulsive status epilepticus cases arising in connection with cephalosporins



Ibrahim Bora¹, Aylin Bican Demir^{*}, Pinar Uzun²

Uludag University Medical School, Neurology Department, 16059 Görükle, Bursa, Turkey

ARTICLE INFO

Article history:

Received 28 March 2016

Received in revised form 11 April 2016

Accepted 30 April 2016

Available online 20 May 2016

Keywords:

Nonconvulsive status epilepticus

Cephalosporin

Prognosis

Treatment

ABSTRACT

Cephalosporins, particularly cefepime, exert neurotoxic side effects that can lead to status epilepticus. These neurotoxic side effects include myoclonus, dystonic movements, tremor, asterixis, seizure, status epilepticus, encephalopathy, and sometimes coma. Status epilepticus, particularly nonconvulsive status epilepticus (NCSE), is a well-known but unusual complication in patients with altered renal function who were receiving treatment with intravenous cephalosporins, especially cefepime. We reviewed the clinical and electroencephalographic (EEG) characteristics of 7 patients with renal failure who developed consciousness alterations with changes in EEG activity while being treated with cephalosporins. All patients developed renal failure: six patients had chronic renal failure, one patient had acute renal failure, and two patients were administered hemodialysis. Nonconvulsive status epilepticus was observed between 2 and 8 days (average of 5.6 days) after initiation of cephalosporins. Cephalosporins are epileptogenic drugs, especially when used in excessive doses or when renal function is impaired. Critically ill patients with chronic kidney disease are particularly susceptible to cefepime neurotoxicity. Clinical and electrophysiological results of patients guide the diagnosis of NCSE by healthcare providers.

© 2016 Published by Elsevier Inc. This is an open access article under the CC BY-NC-ND license (<http://creativecommons.org/licenses/by-nc-nd/4.0/>).

1. Introduction

Cephalosporins are characterized by a broad antimicrobial spectrum and excellent tissue penetration in clinical practice [1]. They are currently among the most widely used lactam antibiotics for the treatment of serious gram-negative infections. Cephalosporins are grouped into “generations” according to their antimicrobial properties: the first-generation cephalosporins include cefazolin, the second-generation cephalosporins include cefuroxime, the third-generation cephalosporins include ceftazidime, and the fourth-generation cephalosporins include cefepime. Cefepime is often used as the first choice for the treatment of severe infections. Cephalosporins, particularly cefepime, have neurotoxic side effects that can lead to status epilepticus [2,3]. Neurotoxic side effects due to cephalosporins include myoclonus, dystonic movements, tremor, asterixis, seizure, status epilepticus, encephalopathy, and sometimes coma [4]. Status epilepticus, particularly nonconvulsive status epilepticus (NCSE), is a well-known but unusual complication in patients with altered renal function who are receiving treatment with intravenous cephalosporins, especially cefepime [4]. Nonconvulsive status epilepticus

(NCSE) is a condition that may be associated with different levels of altered consciousness without any apparent motor signs. Patients with NCSE exhibit continuous or intermittent electrographic discharges detected by electroencephalography (EEG) [5]. Electroencephalographic recording is crucial for recognizing NCSE. A delay in diagnosis and treatment may be associated with increased mortality or neuronal loss, as well as impaired cognitive and behavioral abilities [6]. Discontinuation of the drug often leads to restoration of neurological function. Nonconvulsive status epilepticus is a rare complication of cephalosporin therapy, with only a few isolated cases reported in the literature.

We reviewed the clinical and electroencephalographic characteristics of 7 patients with renal failure who developed consciousness alterations and changes in EEG activity while being treated with cephalosporins, particularly cefepime.

1.1. Case 1

The first case is ES, a 52-year-old man undergoing hemodialysis for the past 4 years because of stage-III chronic renal insufficiency secondary to focal segmental glomerulosclerosis. He was seen in the nephrology clinic because of a progressive decline in mental status, delirium, agitation, disorientation, and difficulty with cooperation sometimes accompanied by myoclonic jerks. His medical history included hypertension and diabetes mellitus for the past 20 years. He presented with high fever and positive blood cultures for *Staphylococcus aureus* and was

^{*} Corresponding author. Tel.: +90 224 2951723; fax: +90 224 4429177.

E-mail addresses: aylinbican@myinet.com (A.B. Demir), bora@uludag.edu.tr (I. Bora), drpuzun@gmail.com (P. Uzun).

¹ Tel.: +90 224 2951712; fax: +90 224 4429177.

² Tel.: +90 224 2951740; fax: +90 224 4429177.

diagnosed with a urinary tract infection. The patient was initially administered cefazolin at 4 g/day; cefazolin was eventually discontinued, and cefepime treatment was started at 2 g every 12 h. A progressive deterioration in mental status, including delirium, agitation, disorientation, and difficulty in cooperating, developed on the second day of cefepime treatment. Neurologic examination revealed no focal neurological deficits. Magnetic resonance imaging of the brain showed atrophy in the right temporo-occipital junction reflecting the sequelae of an old infarction of 1.5×2 cm. Electroencephalography revealed continuous 2- to 3-Hz generalized bi/triphasic sharp waves, which led to a diagnosis of NCSE. Cefepime treatment was discontinued, and 10 mg of diazepam was administered via intravenous injection. Clinical symptoms and EEG findings improved approximately 7 days after discontinuation of cefepime (Fig. 1).

1.2. Case 2

The second case is GK, a 39-year-old woman with ankylosing spondylitis, amyloidosis, and chronic renal failure. She was admitted to the orthopedic clinic because of septic arthritis. Drainage was performed, and treatment with cefepime at 3 g/day was initiated. On the sixth day of cefepime treatment, the patient suddenly stopped speaking and exhibited loss of orientation, increased agitation, occasional laughing, meaningless speech, and progressive impairment of consciousness. Myoclonic jerks were also observed. On the neurological exam, we observed that the patient was confused. Her speech was not meaningful, and she was moving all of her extremities in response to painful stimuli. No focal neurological signs or meningismus was present. Laboratory tests revealed a creatinine level of 6.51 mg/dl with a BUN concentration of 56 mg/dl. The Hgb level was 8.2. The platelet count was 185,000, and the Ca^{++} level was 7.9. Cranial MR imaging and LP analysis were normal. An assessment of EEG activity demonstrated continuous, rhythmic, generalized triphasic 2- to 3-Hz sharp-wave activity. Cefepime was discontinued, and Targocid treatment (400 mg) was initiated twice a

day. Diazepam was administered intravenously. Clinical symptoms and EEG findings improved approximately 5 days after discontinuation of cefepime and administration of diazepam. Electroencephalography demonstrated generalized theta- and delta-wave activity (Fig. 2).

1.3. Case 3

The third case is KI, a 24-year-old woman who was being followed in clinic for chronic renal failure due to lupus nephritis and a 3-year history of hemodialysis. Renal transplantation was performed in September of 2014. Tacrolimus and mycophenolate treatments were initiated after transplantation. Ceftriaxone at 2 g/day was initiated to treat recurrent urinary tract infections. The patient deteriorated on the third day of treatment and presented with three generalized tonic-clonic seizures on the same day. Her consciousness did not improve after the seizures. On neurological examination, the patient was confused and could move her limbs only in response to painful stimuli. The blood level of tacrolimus was measured and was within normal limits. The results of a cranial MRI were normal, and there was no indication of an acute infarct. Electroencephalographic activity was characterized by continuous, rhythmic, generalized 2- to 3-Hz sharp-wave activity. Extensive epileptiform activity was also observed in her EEG results. Ceftriaxone was discontinued. Signs and symptoms of NCSE decreased after diazepam treatment and an infusion of phenytoin; symptoms continued to decline as this treatment paradigm was maintained. Clinical symptoms and EEG abnormalities improved approximately 3 days after discontinuation of ceftriaxone.

1.4. Case 4

The fourth case is VK, a 58-year-old woman who was hospitalized because of chronic renal failure accompanied by mesothelioma, diabetes mellitus, coronary artery disease, and bronchopneumonia. Cefepime was initiated at 4 g/day to treat the bronchopneumonia. On the eighth

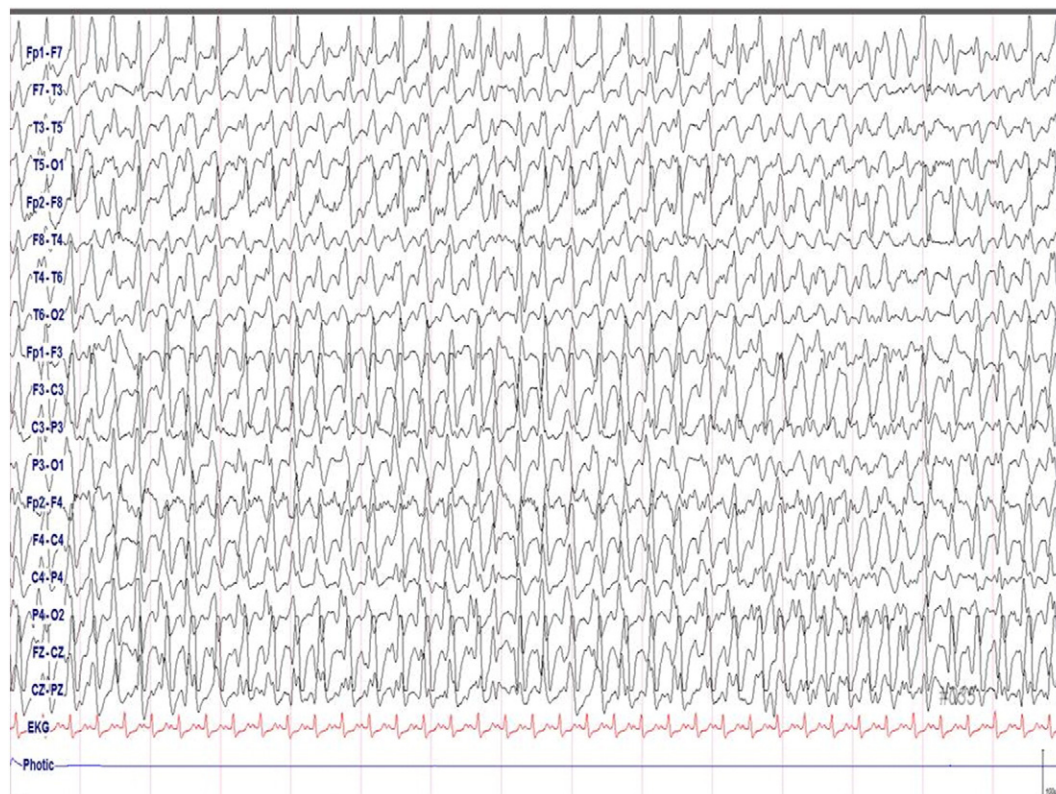

Fig. 1. First electroencephalogram showing continuous, generalized, rhythmic sharp- and slow-wave discharges.

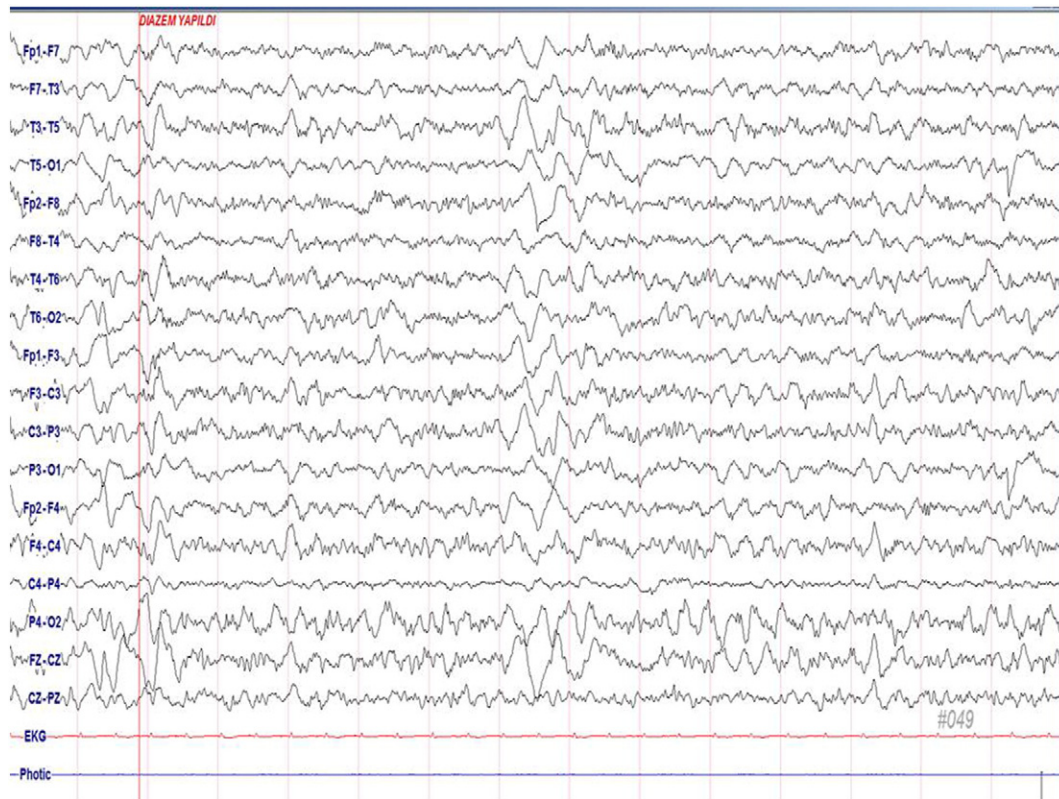


Fig. 2. EEG showing generalized theta- and delta-wave activity after treatment with diazepam.

day of treatment, the patient became less responsive and was unable to speak. No other neurological signs were observed. Laboratory analyses revealed a creatinine level of 4.67 mg/dl with a BUN concentration of 161 mg/dl. A cranial MRI was normal. Electroencephalography detected continuous, rhythmic, generalized 2- to 3-Hz sharp-wave activity that was compatible with a diagnosis of NCSE. Cefepime therapy was discontinued, and the status treatment protocol was applied. Five days after discontinuing cefepime treatment, clinical and neurophysiological findings began to normalize.

1.5. Case 5

The fifth case is IC, a 68-year-old male patient with prostate cancer and a femoral fracture associated with bone metastases and chronic renal failure. He was hospitalized and he developed pneumonia and osteomyelitis after an operation. Cefepime at 4 g/day and amoxicillin at 1000 mg/day were initiated. The patient became disoriented and exhibited difficulty with cooperation, agitation, meaningless speech, and insomnia on the fourth day of cefepime and amoxicillin treatment. His neurological exam revealed no other neurological signs apart from confusion and disorientation. The patient's right leg was stable because of the recent operation. Laboratory tests demonstrated a creatinine level of 4.0 mg/dl and a BUN level of 167 mg/dl. The results of cranial MR imaging were normal. Electroencephalographic activity was indicative of NCSE. Cefepime therapy was discontinued, the status treatment protocol was applied, and diazepam was administered intravenously. Remission of his neuropsychological and clinical findings was observed on the fifth day after discontinuation of cefepime. Electroencephalographic recordings revealed diffuse slow-wave activity and triphasic sharp-wave activity.

1.6. Case 6

The sixth case is ZA, a 74-year-old female patient who was admitted because of rheumatoid arthritis and ankylosing spondylitis. The

patient's pulmonologist initiated treatment for pneumonia with cefepime at 4 g/day. The patient exhibited an altered mental state; she became unresponsive, and myoclonus was observed in both arms on the fourth day of cefepime treatment. The results of her neurological exam were normal except for difficulty with cooperation and disorientation. Magnetic resonance imaging of the brain was normal. Electroencephalography showed continuous, rhythmic, generalized 2- to 3-Hz sharp-wave activity. Cefepime was discontinued after the first EEG, and diazepam and levetiracetam were administered intravenously. Five days after discontinuing cefepime therapy, her mental state returned to normal, and she became alert and oriented. Her neurophysiological findings declined, and her EEG results gradually fully improved. On the 7th day of treatment, these results had completely normalized.

1.7. Case 7

The seventh case is BA, a 71-year-old man with hepatic carcinoma who developed high fever and elevated urea and creatinine levels after an operation. Ceftriaxone was initiated at 2 g/day to treat a possible wound infection. On the 5th day of antibiotic treatment, NCSE was identified in the patient because of meaningless speech, an inability to walk, sleepiness, and abnormal EEG findings. Ceftriaxone treatment was terminated, and diazepam treatment was initiated. After 5 days, apparent neurophysiological and clinical impairments were recorded. Electroencephalography revealed diffuse slow-wave activity after ceftriaxone withdrawal.

2. Results

We describe 7 patients (4 females and 3 males) who developed NCSE while receiving intravenous cephalosporins. The mean age of the patients was 55.1 years (ranging from 24 to 74). Five patients were administered cefepime, and 2 patients received ceftriaxone during NCSE. All patients had developed renal failure: six patients had chronic

renal failure, one had acute renal failure, and two underwent hemodialysis. The doses of cephalosporins, particularly cefepime, were adjusted for renal failure. The doses of cephalosporins (cefepime, ceftriaxone, ceftazidime, ceftazidime, ceftazidime) ranged from 2 to 4 g/day. Nonconvulsive status epilepticus latency, the period between the start of cefepime treatment and detection of neurological deterioration, was between 2 and 8 days, and the average latency was 5.6 days.

Patients exhibited symptoms such as a progressive decline in mental status, disorientation, and agitation, sometimes associated with mild facial or limb myoclonus. Electroencephalography showed continuous or intermittent bursts of generalized, high-voltage, 2- to 3-Hz sharp- and slow-wave activity. Intravenous diazepam completely suppressed epileptiform activity in all patients when cephalosporins were withdrawn and intravenous antiepileptic therapy was started in all patients. Patient outcomes were good after discontinuation of cephalosporins and initiation of anticonvulsant treatments. Neurologic symptoms disappeared following withdrawal of cephalosporin therapy. The first signs of clinical and neurophysiological improvement were observed after 3 to 7 days. Summaries of the 7 cases are presented in Table 1.

3. Discussion

Some antimicrobial agents (penicillins, cephalosporins, carbapenems, quinolones, and antimalarials) may precipitate seizures even in patients who do not have epilepsy. Patients with renal failure or a previous diagnosis of epilepsy are most susceptible to the toxic effects of cephalosporins [7]. Cephalosporins are epileptogenic drugs, especially when used at excessive doses or when renal function is impaired [8]. Critically ill patients with chronic kidney disease are particularly susceptible to cefepime neurotoxicity. Neurotoxicity from cephalosporins may vary from encephalopathy to NCSE [4]. Risk factors for cephalosporin-induced neurotoxicity include renal insufficiency, excessive dose usage (particularly cefepime), and preexisting CNS abnormalities [9,10]. Latency in the development of neurotoxicity varied from one to ten days. All reported neurological symptoms typically resolved within two to seven days after discontinuation of the cephalosporin [4,11–13]. In our patients, the number of days between the start of cefepime treatment and the emergence of neurological deterioration was between 2 and 8 days, with an average time period of 5.6 days. We observed improvement in neurological symptoms after 3–7 days of antibiotic withdrawal. Electroencephalographic results are critical for a correct diagnosis of cephalosporin neurotoxicity, particularly NCSE. Neurotoxicity is seen more often in elderly patients, who may have age-related declines in creatinine clearance. Neurotoxic effects in patients with renal insufficiency are due to altered pharmacokinetics resulting in increased circulating cephalosporin concentrations [14]. All of our patients exhibited chronic or acute renal failure, but three of them were younger adults, not elderly adults. Nonconvulsive status epilepticus can be seen as a complication of cephalosporin therapy even at therapeutic doses and in the presence of normal renal function and normal creatinine clearance. This may be particularly true in the elderly. However, it can also occur in young people. Nonconvulsive status epilepticus can be difficult to recognize in elderly patients, particularly in patients with no history of seizures. None of our patients reported a previous history of seizures. If the blood–brain barrier is disrupted, as in cases of uremia, drugs can more easily cross the BBB, inducing CNS toxicity that is believed to cause NCSE [7].

The mechanism of neurotoxicity in cephalosporin therapy involves inhibiting GABA-A release, increasing glutamate levels, and inducing release of endotoxins and TNF-alpha, which is involved in septic encephalopathy [15–17].

Diagnosis of drug-induced NCSE has increased in recent years and diagnosis should be considered in all patients with unexpected changes in mental status during treatment with intravenous cephalosporins, particularly in patients with some degree of renal dysfunction. Urgent EEG should be considered. Electroencephalography is essential to guide prompt and accurate diagnosis. In all patients in the current

Table 1
Characteristics of seven patients with cephalosporin-induced NCSE.

Case	Age, sex	Symptoms	Renal function	Creatinine (mg/dl) BUN Dialysis	Associated pathology	Indication	Cephalosporin, dose/day	NCSE latency	MRI LP Other	Treatment after cephalosporins were discontinued	Improvement
ES	52, ♂	Decline of mental status, confusion, disorientation, myoclonic jerks	CRF	Cre: 3.4 mg/dl BUN: 127 mg/dl Dialysis: 4 years	Hypertension Diabetes mellitus	Urinary tract infection	Cefazoline, 4 g/day Cefepime, 4 g/day	2nd day	Infarct sequel	BZD	Seventh day
GK	39, ♀	Loss of orientation, occasional laughing, meaningless speech	CRF	Cre: 6.51 mg/dl BUN: 56 mg/dl	Ankylosing spondylitis Amyloidosis	Septic arthritis	Cefepime, 3 g/day	6th day	Normal	BZD	Fifth day
KI (♀)	24, ♀	Confusion after GCS, consciousness did not improve	CRF Renal transplant	Cre: 2.8 mg/dl BUN: 32 mg/dl Dialysis: 3 years	HT	Recurrent urinary tract infection	Ceftriaxone, 2 g/day	3rd day	LP: Normal Hyperintense lesion PRES	BZD, PHT	Third day
VK	58, ♀	Lethargic but unresponsive, confused	CRF	Cre: 4.67 mg/dl BUN: 161 mg/dl	Mesothelioma, diabetes mellitus, coronary artery disease	Bronchopneumonia	Cefepime, 4 g/day	8th day	Normal	BZD	Fifth day
IC	79, ♂		CRF	Cre: 4.0 mg/dl BUN: 167 mg/dl	Prostate cancer Bone metastases	Pneumonia Osteomyelitis	Cefepime, 4 g/day Amoxicillin, 1000 mg/day	4th day	Normal	BZD	Fifth day
ZA (♀)	74, ♀		Rheumatoid arthritis and ankylosing spondylitis ARF?	Cre: 0.61 mg/dl BUN: 30 mg/dl	Hypertension	Pneumonia	Cefepime, 4 g/day	4th day	Normal	DZP, LEV	Fifth day
MO (♂)	79, ♂		CRF	Cre: 5.3 mg/dl BUN: 101 mg/dl	Colon cancer	Urinary tract infection	Ceftriaxone, 2 g/day	7th day	Normal	DZP	Fifth day

CRF: chronic renal failure, ARF: acute renal failure, NCSE: nonconvulsive status epilepticus, BZD: benzodiazepine, PHT: phenytoin, LEV: levetiracetam.

study, NCSE was diagnosed through EEG activity and clinical findings. It is difficult to distinguish NCSE from metabolic encephalopathy unless an EEG is obtained [18].

Electroencephalographic and clinical improvement after intravenous diazepam, phenytoin, or levetiracetam treatment indicate that the diagnosis of NCSE was accurate. Early detection and diagnosis are important in this potentially reversible condition as prolonged delays in diagnosis may result in increased morbidity or mortality [19]. Electroencephalographic activity demonstrated continuous, generalized, high-voltage, rhythmic bi/triphasic 2- to 3-Hz sharp-wave activity in patients with NCSE. Nonconvulsive status epilepticus did not immediately resolve with DZP or other AEDs but gradually resolved only after cefepime was discontinued. Responses to antiepileptic drugs can be delayed in NCSE. Furthermore, triphasic waves and other EEG alterations of metabolic origin also may be suppressed by intravenous BZDs.

Ethical publication

We confirm that we have read the Journal's position on issues involved in ethical publication and affirm that this report is consistent with those guidelines.

Conflict of interest

The authors state no conflict of interest and no financial disclosure.

References

- [1] Mutnick AH, Rhomberg PR, Sader HS, Jones RN. Antimicrobial usage and resistance trend relationships from the MYSTIC programme in North America (1999–2001). *J Antimicrob Chemother* 2004;53:290–6.
- [2] Martinez-Rodriguez JE, Barriga FJ, Santamaria J, Iranzo A, Pareja JA, Revilla M, et al. Nonconvulsive status epilepticus associated with cephalosporins in patients with renal failure. *Am J Med* 2001;111(2):115–9.
- [3] Primavera A, Cocito L, Audenino D. Nonconvulsive status epilepticus during cephalosporin therapy. *Neuropsychobiology* 2004;49:218–22.
- [4] Grill MF, Maganti R. Cephalosporin-induced neurotoxicity: clinical manifestations, potential pathogenic mechanisms, and the role of electroencephalographic monitoring. *Ann Pharmacother* 2008;42:1843–50.
- [5] Krumholz A, Sung GY, Fisher RS, Barry E, Bergey GK, Grattan LM. Complex partial status epilepticus accompanied by serious morbidity and mortality. *Neurology* 1995;45:1499–504.
- [6] Maganti R, Gerber P, Drees C, Chung S. Nonconvulsive status epilepticus. *Epilepsy Behav* 2008;12:572–86.
- [7] Anzellotti F, Ricciardi L, Monaco D, Ciccocioppo F, Borrelli I, Zhuzhuni H, et al. Cefixime-induced nonconvulsive status epilepticus. *Neurol Sci* 2012;33:325–9.
- [8] Arkaravichien W, Tamungkland J, Arkaravichien T. Cefazolin induced seizures in hemodialysis patients. *J Med Assoc Thai* 2006;89(11):1981–3.
- [9] Grill MF, Maganti RK. Neurotoxic effects associated with antibiotic use: management considerations. *Br J Clin Pharmacol* 2011;72(3):381–93.
- [10] Kim KB, Kim SM, Park W, Kim JS, Kwon SK, Kim H-Y. Ceftriaxone-induced neurotoxicity: case report, pharmacokinetic consideration, and literature review. *J Korean Med Sci* 2012;27:1120–3.
- [11] Roncan-Albuquerque R, Pires I, Martins R, Real R, Sousa G, von Hafe P. Ceftriaxone-induced acute reversible encephalopathy in a patient treated for a urinary tract infection. *Neth J Med* 2009;67:72–5.
- [12] Lam S, Gomolin IH. Cefepime neurotoxicity: case report, pharmacokinetic considerations and literature review. *Pharmacotherapy* 2006;26:1169–74.
- [13] Dakdouki GK, Al-Awar GN. Cefepime-induced encephalopathy. *Int J Infect Dis* 2004;8:59–61.
- [14] Kim A, Kim JE, Paek Y-M, Hong KS, Cho Y-J, Cho JY, et al. Cefepime-induced nonconvulsive status epilepticus (NCSE). *J Epilepsy Res* 2013;3(1):39–41.
- [15] Sugimoto M, Uchida I, Mashimo T, Yamazaki S, Hatano K, Ikeda F, et al. Evidence for the involvement of GABA(A) receptor blockade in convulsions induced by cephalosporins. *Neuropharmacology* 2003;45(3):304–14.
- [16] Alkharfy KM, Kellum JA, Frye RF, Matzke JR. Effects of ceftazidime on systemic cytokine concentrations in rats. *Anti-microb Agents Chemother* 2000;44:3217–9.
- [17] Eggers V, Fugener K, Hein OV, Heyes Rommelspach H, Kox WJ, Spies CD. Antibiotic-mediated release of tumour necrosis factor alpha and norharman in patients with hospital-acquired pneumonia and septic encephalopathy. *Intensive Care Med* 2004;30:1544–51.
- [18] Fernandez-Torre JL, Martinez-Martinez M, Gonzales-Rato J, Maestro I, Alonso I, Rodrigo E, et al. Cephalosporin-induced nonconvulsive status epilepticus: clinical and electroencephalographic features. *Epilepsia* 2005;46(9):1550–2.
- [19] Walker MC. Diagnosis and treatment of non-convulsive status epilepticus. *CNS Drugs* 2001;15:931–9.