

Single-layer Closure with Tongue Flap for Palatal Fistula in Cleft Palate Patients

Abdulla K. Als Salman, MBBS,
FRCS(I)*

Emran A. Algadiem, MBBS†

Mufeed Saeed Alwabari, MBBS‡

Fatimah Jawad Almugarrab,
MBBS§

Background: Tongue flap is a good option to close a complicated palatal fistula in cleft patients. Most surgeons advocate a double-layer closure to decrease the recurrence rates. In this study, we have reported our experience with a modified single-layer closure with tongue flap in cleft patients.

Method: All cases done by a single surgeon using this modified technique in a period of 10 years were retrospectively reviewed. A thorough description of this technique is also provided in the study.

Results: Only 5 cases were operated on using this technique. The success rate of all these cases was 100%, with no recurrence of fistula and few complications.

Conclusions: This technique provides a way to avoid nasal layer closure in cases where nasal layer is difficult or impossible to close. It also limits the need for a second flap for nasal layer closure. (*Plast Reconstr Surg Glob Open* 2016;4:e852; doi: 10.1097/GOX.0000000000000841; Published online 24 August 2016.)

Fistulas occurring after cleft palate repair are a common complication and have a prevalence of 0% to 77.8% worldwide.¹ The size of these fistulas varies from small (<2 mm) to large (>5 mm). Most of the small fistulas can be closed using local flaps or reoperative palatoplasty. The large ones are usually difficult to close and may require a more reliable flap, for example, tongue flap (Fig. 1).²⁻⁴ The tongue flap is a 2-staged procedure that is usually reserved for complicated or large fistulas due to its complexity, discomfort, and possible complications for the patients (Fig. 2). In the case of a tongue flap, there are many technical points that surgeons need to consider as a prerequisite to decrease the chances of fistula recurrence. One of these points is the emphasis on a good nasal layer closure.^{2,3,5-7} In this study, we have reported our experience with a modified single-layer closure (no nasal closure) using tongue flap for the closure of complicated palatal fistulas in cleft palate patients.

METHOD

All secondary cleft palate fistulas operated on by the main author in the past 10 years were reviewed. Only the cases of single-layer closure by tongue flap using the modified technique were included in the study. The files were reviewed for demographic data, diagnosis, procedure, complications, and follow-up. Approval from the Research and Ethics Committee of the hospital was obtained before the study. The Helsinki Declaration guidelines were followed during this study.

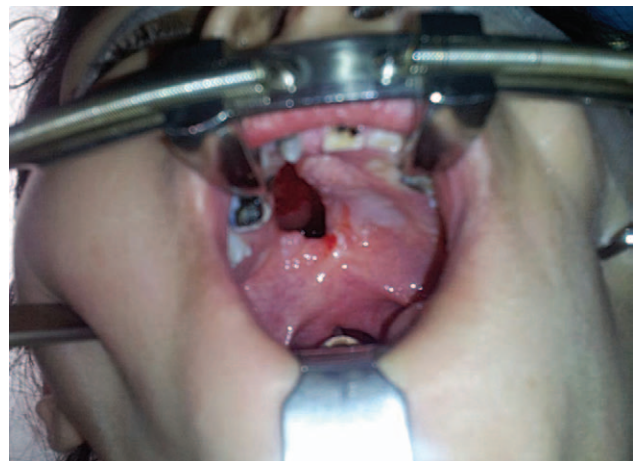

Fig. 1. Large palatal fistula. It usually occurs due to flap necrosis.

From the *Plastic Surgery Department; †Saudi Board Resident of Plastic Surgery; ‡Saudi Board Resident of General Surgery; and §Plastic Surgery Intern, King Fahad Hospital, Hofuf, Saudi Arabia.

Received for publication February 19, 2016; accepted June 8, 2016.

Copyright © 2016 The Authors. Published by Wolters Kluwer Health, Inc. on behalf of The American Society of Plastic Surgeons. All rights reserved. This is an open-access article distributed under the terms of the Creative Commons Attribution-Non Commercial-No Derivatives License 4.0 (CCBY-NC-ND), where it is permissible to download and share the work provided it is properly cited. The work cannot be changed in any way or used commercially.

DOI: 10.1097/GOX.0000000000000841

Disclosure: The authors have no financial interest to declare in relation to the content of this article. The Article Processing Charge was paid for by the authors.

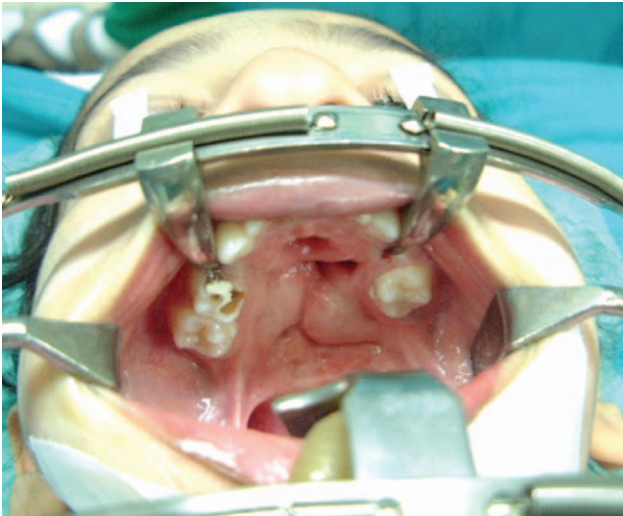

Fig. 2. Complicated, scarred palate with 2 fistulas.

Surgical Technique

All operations were performed under general anesthesia and nasal intubation. The fistula edge was marked on the oral side and injected with lidocaine/epinephrine to decrease bleeding and facilitate dissection (Figs. 3A and 4). The fistula edges were incised on the oral side and then turned to the nasal side and left

without direct closure (Figs. 3B and 5). This resulted in a doughnut-shaped nasal layer, with the center of the nasal layer left opened.

The desired size of anteriorly based tongue flap was marked (Fig. 6). The length and width of the flap were designed according to the size of the fistula. However, care was taken to ensure that the size of flap did not exceed two-thirds of the tongue width and the circumvallate papilla or the tongue tip so as to avoid compromising the tongue. The tongue flap was raised with a small amount of muscle (5mm) using a Colorado tip cautery to ensure better blood supply and healing (Fig. 7).

The flap was rested in the fistula with the nasal layer gap in the center of the flap tip. This results in 2-layer closure on the periphery of the fistula, that is, the tongue flap orally and the reflected fistula edges nasally. In contrast, the center of the fistula was covered with only one layer, that is, the tongue flap on the oral side (Fig. 3C).

Polydioxanone 4.0 or 3.0 mattress suture was used to anchor the tongue flap to the doughnut-shaped nasal layer and the palatal mucosa orally.

The donor site of the tongue was closed with polydioxanone mattress sutures after meticulous hemostasis. Some gap was left near the pedicle of the tongue to ensure no tension of the flap pedicle. No additional fixation of tongue or mouth closure was used in our practice.

The patients were kept under observation for 24 hours. If the patients began having adequate liquid diet using straw

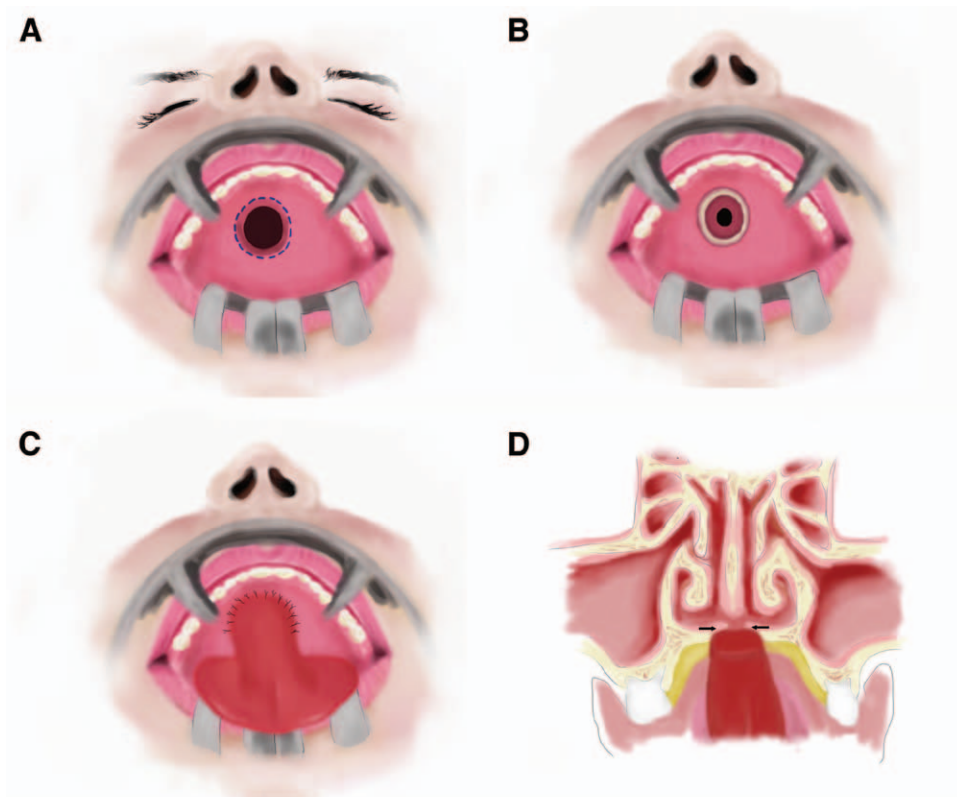


Fig. 3. Modified technique. (A) Fistula is marked on the oral side. (B) The fistula edge is reflected to the nasal side without direct closure. (C) Tongue flap is rested in the defect. (D) The reflected edge will epithelialize and close the nasal gap.

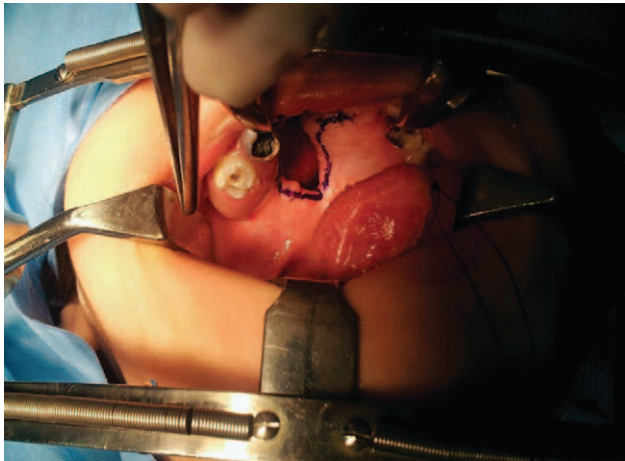


Fig. 4. Marking of the fistula on the oral side.

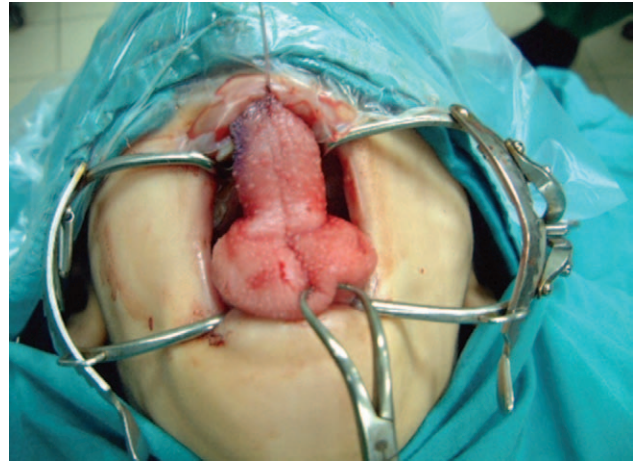

Fig. 7. Long and thick tongue flap is preferred in our experience.

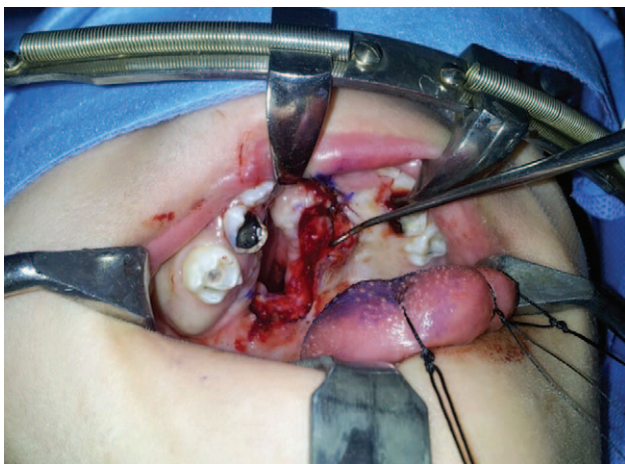


Fig. 5. Fistula edge reflection to nasal side.

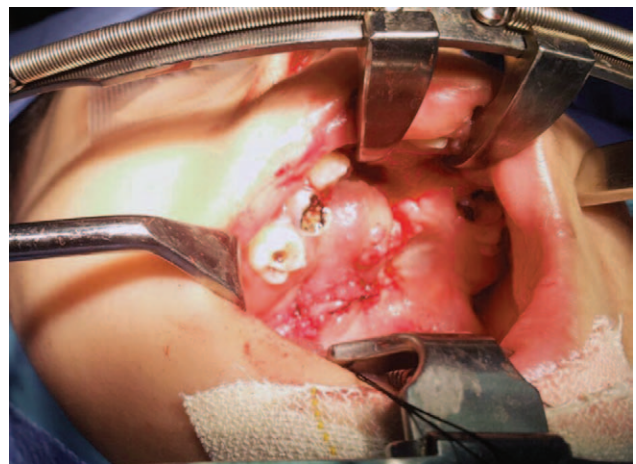

Fig. 8. Separation of the tongue flap and final resetting.

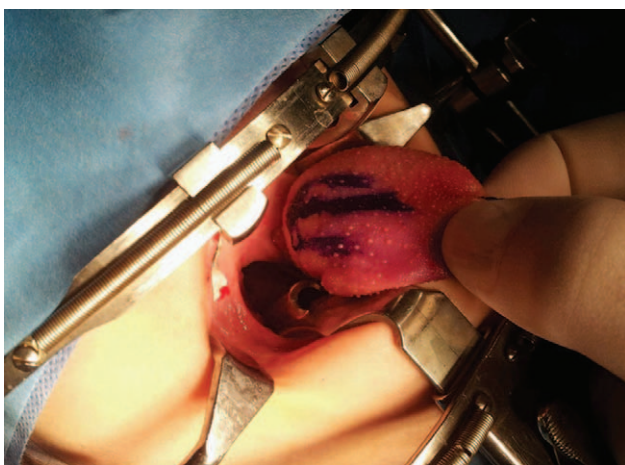


Fig. 6. Anteriorly based flap marked.

and there were no complications, they were discharged on a liquid diet with weekly visit until the second stage.

After 2 to 3 weeks, the patients were re-operated on under general anesthesia. The flap was tested with vascu-

lar loop tourniquet for adequate vascularity before separation. After separation, the final resetting of the flap was done (Fig. 8).

The remaining flap was sutured to the palatal mucosa, and the remaining flap pedicle was trimmed. The tongue donor site was closed fully with the chromic gut suture.

RESULTS

Over the past 10 years, only 5 cases were operated on using a single-layer closure with tongue flap (Table 1). Most of the fistulas reviewed were of Type IV as per the Pittsburgh Fistula Classification System.⁸

The success rate of these 5 cases was 100%, with no recurrence of fistula at an average follow-up of 18 months. Only one case was complicated with bleeding postoperatively, which required taking the patient to the operative room to cauterize the bleeder. One patient was followed with a nasoscope examination with an otorhinolaryngologist to determine the status of the nasal layer, after 3 months from the procedure. The nasal layer was reported as fully epithelialized with no fistula (Fig. 9).

Table 1. Demographic Data of the Patients

Age (yr)	Gender	Number of Prior Closures	Size (cm)	Type*	Flap Orientation	Complication	Follow-up
5	Male	1	3×2	IV	Anteriorly based	Non	3 years
2	Male	2	2×2	V	Anteriorly based	Bleeding	2 years
7	Female	3	1.5×1.5	V	Anteriorly based	Non	2 years
			3×2	IV			
4	Male	0	3.5×3	IV	Anteriorly based	Non	1 year
6	Female	0	4.5×2	IV	Anteriorly based	Non	6 months

*Classification according to the Pittsburgh Fistula Classification System.

DISCUSSION

Tongue flap is a reliable option for use in complex palatal fistulas in both cleft and noncleft patients. This technique has a success rate reaching up to 100% and is associated with few complications with little effect on the tongue (Fig. 10).²⁻⁴ The tongue flap can be oriented or modified to fit most complicated fistulas, making it a work-horse flap.^{2,9}

Many surgeons have emphasized a double-layer closure for closing a palatal fistula to ensure non-recurrence.^{2,3,5-7} In addition, some surgeons have introduced a 3-layer closure, arguing better outcomes.^{10,11} In small fistulas, the nasal layer closure can be achieved by direct closure of the nasal layer or mobilizing some of the nasal mucosa.^{2,3} However, in large fistulas or excessively scarred palatal nasal layer, it is difficult to achieve closure in most cases (Figs. 1 and 2). Therefore, a more robust flap, such as buccal flap, pharyngeal flap, or inferior turbinate flap, may be needed to close the nasal layer.¹²⁻¹⁴

It has been reported that even the double-layer closure has a recurrence rate of about 40%.⁷ On the contrary, the overall recurrence rate for fistula after tongue flap usage is very low, usually with a 0% recurrence rate.^{3,4,6} Most of the recurred fistulas after tongue flap were due to partial flap necrosis.³ The low recurrence rate of multiple-layer closure proves that tongue flap is associated with better outcomes compared with the layered closure.

In our practice, small fistulas are treated with local mucoperiosteal flaps or 2-flap reoperative palatoplasty. The tongue flap is seldom used if there is a better option

to close the fistula. As mentioned earlier, the tongue flap option is reserved for large fistula, scarred palate with no adequate tissue, and previous failure of other options. However, even if the tongue flap is used for the treatment, we prefer to close the nasal layer using 2-layered reconstructions. The tongue flap modification is used only in those cases where direct closure of the nasal layer was impossible or difficult.

In our modified flap technique, the edges of the fistula are turned to the nasal side without direct closure, leaving the nasal layer free of tension (Fig. 3B). This flipping also leaves the remaining nasal gap in the center of the tongue flap, which is the least possible fistula recurrence area because most of the flap necrosis occurs on the tip of the flap. Theoretically, if some distal flap necrosis occurs, this area would be still covered with the reflected nasal layer, which may help in lowering the recurrence of fistula (Fig. 3D). After the resetting of the flap, the well-vascularized raw area of the tongue flap will be in contact with the raw area of the fistula and the nasal gap. This raw-to-raw contact integrates the tongue flap and leads to firm healing of the surrounding area. The nasal layer gap will then start to epithelialize until the complete closure of this gap, as proven by the nasoscope follow-up (Fig. 3D). This concept of increasing the raw areas has been emphasized by other surgeons as well. Habib and Brennan⁴ and Elyassi et al.¹⁵ de-epithelialized the dorsal surface of the tongue flap and the edges of the fistula to enhance healing and for better outcomes.

Some surgeons choose to limit the movement of the tongue to ensure better healing by fixing or anchoring

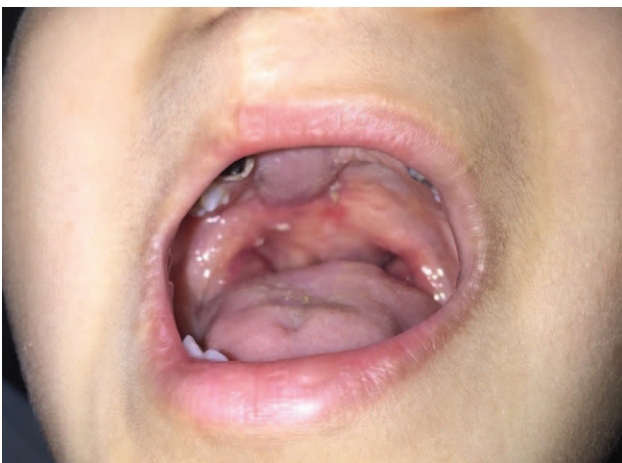

Fig. 9. Final result of the single-layer closure.

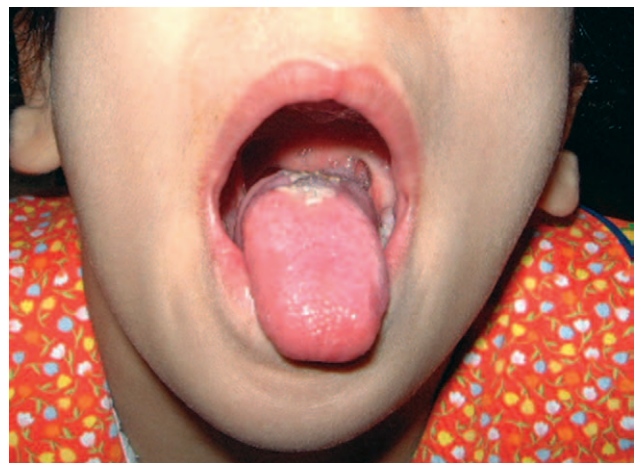

Fig. 10. Tongue looks normal after the usage of tongue flap.

the tongue flap to the nasal septum.^{4,15} Others choose more radical options like intermaxillary fixation or button suture to the lip, which makes the procedure more uncomfortable to the patients and limits the possibility of feeding, thus requiring nasogastric tube feeding.^{4,6,16} In our patients, no additional fixation was required, and no flap dehiscence occurred.

We believe that additional flap fixation is not necessary if good anchoring of the flap to the defect is achieved. In addition, we leave a long pedicle, as much as possible, so that the tongue can rest back in its position and not be tethered to the palate. This gives the tongue a little room to move and helps the patients tolerate the procedure, tolerate feeding, and be able to speak. This is helpful, especially for children, because short tethering of the tongue to the palate results in the child being in continuous agitation, trying to move his or her tongue (Fig. 7). No additional fixation has been reported by other surgeons. Mahajan et al.⁶ reported a series of 41 cases, where they used tongue flaps for closure of palatal fistula with no additional fixation of the flap. Their series consisted of 15% children below the age of 5 years. Their success rate was 100% with only one flap dehiscence, which was remedied with no residual problems.⁶

Regarding the appropriate age of patients for operations using the tongue flap, most surgeons consider the age of 5 years and above as the most appropriate age group. Older children tolerate the tongue flap better, with easier feeding and overall care.^{3,4,6}

The described modification has a number of advantages. First, the use of this modified technique decreases the need to dissect the nasal layer, resulting in less scarring. Second, it eliminates the need for a second flap in cases where the nasal layer cannot be closed. Third, it provides a tension-free nasal layer. Finally, it decreases the overall operative time that otherwise would have been spent trying to close the nasal layer. However, the limitation of this study is that the sample size is small and it is difficult to assure whether the modified technique is a reliable method for all cases of complicated palatal fistulas in cleft patients.

CONCLUSIONS

Tongue flap is a reliable option to close a complicated palatal fistula. Our modification relies on the tongue flap for optimal healing without direct closure of the nasal layer in those cases with complicated closures. This is a salvage method used only when one is faced with a difficult case.

Emran A. Algadiem, MBBS

Saudi Board Resident of Plastic Surgery

King Fahad Hospital

Hofuf 36441, Saudi Arabia

E-mail: emran.algadiem@gmail.com

REFERENCES

1. Hardwicke JT, Landini G, Richard BM. Fistula incidence after primary cleft palate repair: a systematic review of the literature. *Plast Reconstr Surg*. 2014;134:618e–627e.
2. Sadhu P. Oronasal fistula in cleft palate surgery. *Indian J Plast Surg*. 2009;42 Suppl:S123–S128.
3. Vasishta SM, Krishnan G, Rai YS, et al. The versatility of the tongue flap in the closure of palatal fistula. *Craniofac Trauma Reconstr*. 2012;5:145–160.
4. Habib A, Brennan PA. The deepithelialized dorsal tongue flap for reconstruction of anterior palatal fistulae: literature review and presentation of our experience in Egypt. *Cleft Palate Craniofac J*. 2015. [Epub 2015/08/04].
5. Sodhi SP, Kapoor P, Kapoor D. Closure of anterior palatal fistula by tongue flap: A prospective study. *J Maxillofac Oral Surg*. 2014;13:546–549.
6. Mahajan RK, Chhajlani R, Ghildiyal HC. Role of tongue flap in palatal fistula repair: a series of 41 cases. *Indian J Plast Surg*. 2014;47:210–215.
7. Diah E, Lo LJ, Yun C, et al. Cleft oronasal fistula: a review of treatment results and a surgical management algorithm proposal. *Chang Gung Med J*. 2007;30:529–537.
8. Smith DM, Vecchione L, Jiang S, et al. The Pittsburgh Fistula Classification System: a standardized scheme for the description of palatal fistulas. *Cleft Palate Craniofac J*. 2007;44:590–594.
9. Al-Qattan MM. A modified technique of using the tongue tip for closure of large anterior palatal fistula. *Ann Plast Surg*. 2001;47(4):458–460.
10. Murrell GL, Requena R, Karakla DW. Oronasal fistula repair with three layers. *Plast Reconstr Surg*. 2001;107:143–147.
11. Tuncbilek G, Konas E, Kayikcioglu A, et al. Three-layer oronasal fistula repair with sandwiched mastoid fascia graft. *J Craniofac Surg*. 2012;23(3):780–783.
12. Govilkar P, Thatte R. Tongue flaps for the treatment of large symptomatic palatal fistulae. *Eur J Plast Surg*. 1991;14(5):240–244.
13. Murthy J. Salvaging procedure for mutilated cleft palate by simultaneous tongue and pharyngeal flap surgery. *Plast Reconstr Surg*. 2008;122:29e–30e.
14. Rahpeyma A, Khajehahmadi S. Inferior turbinate flap for nasal side closure of palatal fistula in cleft patients: technical note. *Plast Reconstr Surg Glob Open*. 2014;2:e265.
15. Elyassi AR, Helling ER, Closmann JJ. Closure of difficult palatal fistulas using a “parachuting and anchoring” technique with the tongue flap. *Oral Surg Oral Med Oral Pathol Oral Radiol Endod*. 2011;112:711–714.
16. Coghlan K, O'Regan B, Carter J. Tongue flap repair of oronasal fistulae in cleft palate patients. A review of 20 patients. *J Craniofac Surg*. 1989;17:255–259.