

# The Effects of Riluzole on Cisplatin-induced Ototoxicity

Selin Üstün Bezgin<sup>1</sup> Kadir Kemal Uygur<sup>2</sup> Çağıl Gökdoğan<sup>3</sup> Çiğdem Elmas<sup>4</sup> Güleser Göktaş<sup>5</sup>

<sup>1</sup> Department of Otorhinolaryngology, Kanuni Sultan Süleyman Education and Research Hospital, İstanbul, Turkey

<sup>2</sup> Department of Otorhinolaryngology, Gazi University Faculty of Medicine, Ankara, Turkey

<sup>3</sup> Department of Otorhinolaryngology, Muğla Sıtkı Koçman University Faculty of Medicine, Muğla, Turkey

<sup>4</sup> Department of Histology and Embryology, Gazi University Faculty of Medicine, Ankara, Turkey

<sup>5</sup> Department of Histology and Embryology, Lokman Hekim University, Faculty of Medicine, Ankara, Turkey

**Address for correspondence** Selin Üstün Bezgin, MD, Department of Otorhinolaryngology, Kanuni Sultan Süleyman Education and Research Hospital, Atakent mahallesi, Turgut Özal caddesi No: 1, 34303, Altınşehir / Küçükçekmece / İstanbul, Turkey (e-mail: drselinustun@gmail.com).

Int Arch Otorhinolaryngol 2019;23:e267–e275.

## Abstract

**Introduction** Riluzole (2-amino-6-trifluoromethoxy benzothiazole) is known as a neuroprotective, antioxidant, antiapoptotic agent. It may have beneficial effects on neuronal cell death due to cisplatin-induced ototoxicity.

**Objective** To evaluate the effect of riluzole on cisplatin-induced ototoxicity in guinea pigs.

**Methods** Twenty-four guinea pigs, studied in three groups, underwent auditory brainstem response evaluation using click and 8 kHz tone burst stimuli. Subsequently, 5 mg/kg of cisplatin were administered to all animals for 3 days intraperitoneally (i.p.) to induce ototoxicity. Half an hour prior to cisplatin, groups 1, 2 and 3 received 2 ml of saline i.p., 6 mg/kg of riluzole hydrochloride i.p., and 8 mg/kg of riluzole hydrochloride i.p., respectively, for 3 days. The auditory brainstem responses were repeated 24 hours after the last drug administration. The cochleae were analyzed by transmission electron microscopy (TEM).

**Results** After drug administration, for 8,000 Hz stimulus, group 1 had significantly higher threshold shifts when compared with groups 2 ( $p < 0.05$ ) and 3 ( $p < 0.05$ ), and there was no significant difference in threshold shifts between groups 2 and 3 ( $p > 0.05$ ). Transmission electron microscopy findings demonstrated the protective effect of riluzole on the hair cells and the stria vascularis, especially in the group treated with 8 mg/kg of riluzole hydrochloride.

**Conclusion** We can say that riluzole may have a protective effect on cisplatin-induced ototoxicity. However, additional studies are needed to confirm these results and the mechanisms of action of riluzole.


## Keywords

- ▶ riluzole
- ▶ cisplatin
- ▶ ototoxicity
- ▶ auditory brainstem response
- ▶ transmission electron microscopy

## Introduction

Cisplatin (cis-diamminedichloroplatinum [CDDP]), is a chemotherapeutic agent used for the treatment of various malignancies, including testicular, ovarian, bladder, cervical, head and neck, and non-small cell lung cancers. Unfortunately, its

use is associated with dose-limiting side effects, such as nephrotoxicity, neurotoxicity and ototoxicity.<sup>1</sup> Cisplatin-induced ototoxicity generally manifests as ear pain, tinnitus or sensorineural hearing loss. The hearing loss is dose-related, cumulative, bilateral and usually symmetrical, and occurs initially in the higher frequencies. A total of 90.5% of patients had a significant hearing loss at 8 kHz. By continuation of therapy, the effect extends to lower frequencies and is often

 Selin Üstün Bezgin's ORCID is <https://orcid.org/0000-0001-9350-8046>.

received  
July 4, 2018  
accepted  
October 21, 2018

DOI <https://doi.org/10.1055/s-0038-1676654>.  
ISSN 1809-9777.

Copyright © 2019 by Thieme Revinter  
Publicações Ltda, Rio de Janeiro, Brazil

License terms



irreversible. It may also progress even once the cisplatin therapy has been completed or withdrawn.<sup>2,3</sup>

Several potential mechanisms of cisplatin-induced ototoxicity have been proposed. Among these, the most widely described is the coordinate bonding between the atoms of platinum and DNA that results in the formation of inter- and intra-strand cross-linking of DNA, induction of p53, and cell cycle arrest. Recent studies have also highlighted the relationship between reactive oxygen species (ROS) generated by cisplatin administration and apoptosis. Through the action of ROS, various pathways are believed to be involved in the induction of the apoptosis of cochlear cells, including the caspase-dependent pathway (up-regulation of Bcl-2, caspase-3 and caspase-9) or caspase-independent pathway (activation of pro-apoptotic c-Jun N-terminal kinase [JNK]), lipid peroxidation of the cell membrane, and induction of Ca<sup>2+</sup> influx. In addition, inflammatory pathways have been shown to play a role in cisplatin-induced apoptosis (including activation of nuclear factor-kb [NF-kb] and activator protein-1 [AP-1]).<sup>4,5</sup>

Following cisplatin administration, the most prominent change is seen in the organ of Corti, in animal studies, in which there is degeneration and loss of sensory cells. These changes initially start at the first row of outer hair cells (OHCs) in the basal turn of the cochlea, followed by the other OHC rows and, eventually, the inner hair cells (IHCs) in the context of prolonged administration or high cisplatin doses.<sup>6–8</sup> In addition to its destructive effect upon the organ of Corti, cisplatin also affects the stria vascularis,<sup>7</sup> and several studies have demonstrated cisplatin-induced degeneration of spiral ganglion cells (SGCs)<sup>7–9</sup> and supporting cells.<sup>10</sup>

The present study investigates the potential role of a neuroprotective, antiapoptotic agent, riluzole (2-amino-6-trifluoromethoxy benzothiazole), in preventing the degeneration of cochlear cells and thus avoiding the hearing loss resulting from cisplatin-mediated apoptosis. Riluzole has been approved by the Food and Drug Administration (FDA) for the treatment of amyotrophic lateral sclerosis.<sup>11</sup> Since it can block voltage-gated Ca<sup>2+</sup> and Na<sup>+</sup> ion channels as well as activate K<sup>+</sup> ion channels and G-protein dependent signal transduction pathways, the major mechanism of the clinical action of riluzole is thought to be its inhibition of glutamate release and noncompetitive antagonist effects on glutamate receptors.<sup>12</sup> The potential beneficial effects of riluzole in neuronal cell death have been demonstrated in animal models of retinal ischemia,<sup>13</sup> spinal cord injury,<sup>14</sup> and noise-induced hearing loss,<sup>15,16</sup> in which the cytotoxic mechanisms are believed to base on the glutamate excitotoxic pathway. The excitotoxic pathway has not been invoked before as a mechanism of cisplatin-induced ototoxicity; however, recent studies have shown that riluzole has properties independent of its effect on glutamate release, which may be of relevance in the prevention of cisplatin ototoxicity. These include the suppression of the generation of ROS and the inhibition of downstream apoptotic signals,<sup>17–19</sup> as well as the triggering of endogenous protective molecules, such as heat shock proteins (HSPs) and heme oxygenase-1 (HO-1).<sup>20–22</sup> In this study, we analyzed the hearing thresholds by auditory brainstem responses (ABRs)

and documented cell degeneration in hair cells, the stria vascularis and auditory nerve fibers, by transmission electron microscopy, to evaluate the effect of riluzole on cisplatin-induced ototoxicity

## Materials and Methods

### Animals

This study was approved and monitored by the Experiments Local Ethics Committee (G. Ü. ET - B.30.2.GÜN.0.05.06.00/80-6489). The experimental animals were 24 young adult, male, albino guinea pigs, weighing between 350 and 400 g. After the attainment of the ethics committee approval for the study, the guinea pigs were kept for 2 weeks in the Experimental Animals in Research and Application Center. All animals were housed in plastic cages with water and food available *ad libitum* and maintained on a 12-hour light/dark cycle.

### Experimental Design and Drug Administration

The animals were divided into three groups, and all were assessed for ABR before drug administration. A dose of 5 mg/kg/day of cisplatin (Cisplatin DBL; Faulding Pharmaceuticals, Warwickshire, UK) was administered for 3 days intraperitoneally (i.p.) to induce ototoxicity in all 3 groups. Group 1 ( $n = 8$ ) received 2 ml of saline i.p. for 3 days, half an hour before cisplatin. Groups 2 and 3 received, respectively, 6 mg/kg of riluzole hydrochloride (Riluzole hydrochloride 25 mg [Sigma R11]; Sigma Aldrich, Darmstadt, Germany) i.p., and 8 mg/kg of riluzole hydrochloride i.p., dissolved in saline to give a 2 ml volume on each treatment day, half an hour before cisplatin, for 3 days.

Wang et al have previously studied guinea pigs exposed to acoustic trauma and determined that that 6 mg/kg of riluzole i.p. was the minimal effective dose to prevent hearing loss and cell death in the inner ear. In addition, they noticed side effects, such as hypotonia and weight loss, at doses of 8 mg/kg and higher.<sup>15</sup> The dose selection in our study was, therefore, based on these data.

Guinea pigs were coded as S1–S8, in group 1; R6.1–R6.8 in group 2; and R8.1–R8.8 in group 3.

### Anesthesia

The animals were anesthetized with 30 mg/kg of ketamine hydrochloride (Ketalar, Eczacıbasi Ilac Sanayi ve Ticaret A.S, Luleburgaz, Turkey) and 4 mg/kg of xylazine (Rompun, Bayer Vital, Leverkusen, Germany) given as an intramuscular infusion before the electrophysiological tests.

### Auditory Brainstem Response Evaluation

The ABR evaluations of both ears ( $n:44$ ) of the guinea pigs were performed with the Bio-logic Navigator Pro device version 2.2.0 (Bio-Logic Systems Corp., Mundelein, IL, USA) twice before drug administration, and 24 hours after the last drug administrations. In the ABR evaluations, we used a 13.00 Hz rate click stimulus, 10 ms analysis time, 1,000 sweeps in averaging, 100–1,500 Hz filtration, rarefaction polarity and then tone burst stimulus at 8 kHz, 50–1,500 Hz band-pass filtration, and alternating polarity. Changes in the intensity

were made in accordance with the responses achieved in the 70 dB nHL intensity level recordings.

### Transmission Electron Microscopic Evaluation

The animals were sacrificed under deep anesthesia after the ABR measurements, and the right temporal bone of each animal was removed. The cochleae were harvested from the temporal bone. Tissue samples were decalcified by placing into ethylenediaminetetraacetic acid (EDTA) solution prepared with 2.5% glutaraldehyde. Tissue samples were then placed in 1% osmium tetroxide for 1 hour, followed by fixation and staining. After this, samples were dehydrated with alcohol series and tissues were placed in propylene oxide for 30 minutes, prior to a 30-minute waiting period in embedding material (AGR1030 epoxy-resin (Araldite CYC212) Kit [Agar Scientific, Stansted, Essex, U.K.]). After this step, tissues taken into embedding material were placed into a rotator at room temperature for 2 hours and then transferred into an oven at 40°C for another 2 hours. Tissues were embedded into horizontal embedding blocks within the same mixture. Sections were then prepared in 1 µm sizes from these blocks by LKB Leica ultramicrotome (Leica, Germany, Reichert SuperNova) and stained with toluidine blue (Code: T3260; Sigma Aldrich, Darmstadt, Germany). The slides were examined with photomicroscope (Leica, Germany, DM4000B Image Analyze System) with plus camera (Leica, Germany, DFC 280). The relevant areas were marked to be examined and thin sections in size of 0.2–0.5 µm were prepared on formyl-coated copper grids. Counter-staining was achieved with uranyl acetate and lead citrate and the sections were evaluated and captured using an electron microscope (Carl Zeiss EVO LS10, Carl Zeiss Microscopy Ltd., Cambridge, UK).

The degeneration of the stria vascularis, hair cells and auditory nerve fibers of 18 guinea pigs ( $n = 6$  in each group) was assessed under TEM through established degeneration criteria and scored as follows: 0, absent; 1, weak; 2, medium; and 3, severe, for each animal by two histologists. Previously, histologists have used this scoring for two studies.<sup>23,24</sup> The histologists were blinded as to the treatment of the guinea pigs they studied.

### Statistical Analysis

The SPSS for Windows, Version 20.0. software (IMB Corp., Armonk, NY, USA) was used for the statistical analysis. The differences among the groups were assessed with Kruskal-Wallis analysis of variance, and pairwise comparisons of groups were evaluated by Mann-Whitney U-test to identify the group responsible for differences. Statistical significance was set at  $p < 0.05$ .

## Results

### Auditory Brainstem Responses

Two guinea pigs from group 2 and group 3, respectively coded as R6.8 and R8.1, died after the 2<sup>nd</sup> day of drug administration. Therefore, we analyzed ABR thresholds in all groups before and after drug administration statistically over both ears of 22 animals for the click and the 8 kHz-frequency stimuli.

For click stimulus, mean  $\pm$  standard error of the mean (SEM) values were in group 1, 2, 3 respectively  $3.75 \pm 1.25$ ,  $2.86 \pm 1.63$ ,  $0 \pm 1.04$  before drug administration and  $17.5 \pm 1.93$ ,  $10 \pm 2.34$ ,  $10 \pm 1.81$  after drug administration. For 8,000 Hz stimulus, mean  $\pm$  SEM values were in group 1,2,3 respectively  $-0.62 \pm 1.7$ ,  $-0.71 \pm 1.95$ ,  $-2.14 \pm 1.54$  before drug administration and  $23.75 \pm 2.72$ ,  $5 \pm 2.72$ ,  $10 \pm 1.81$  after drug administration.

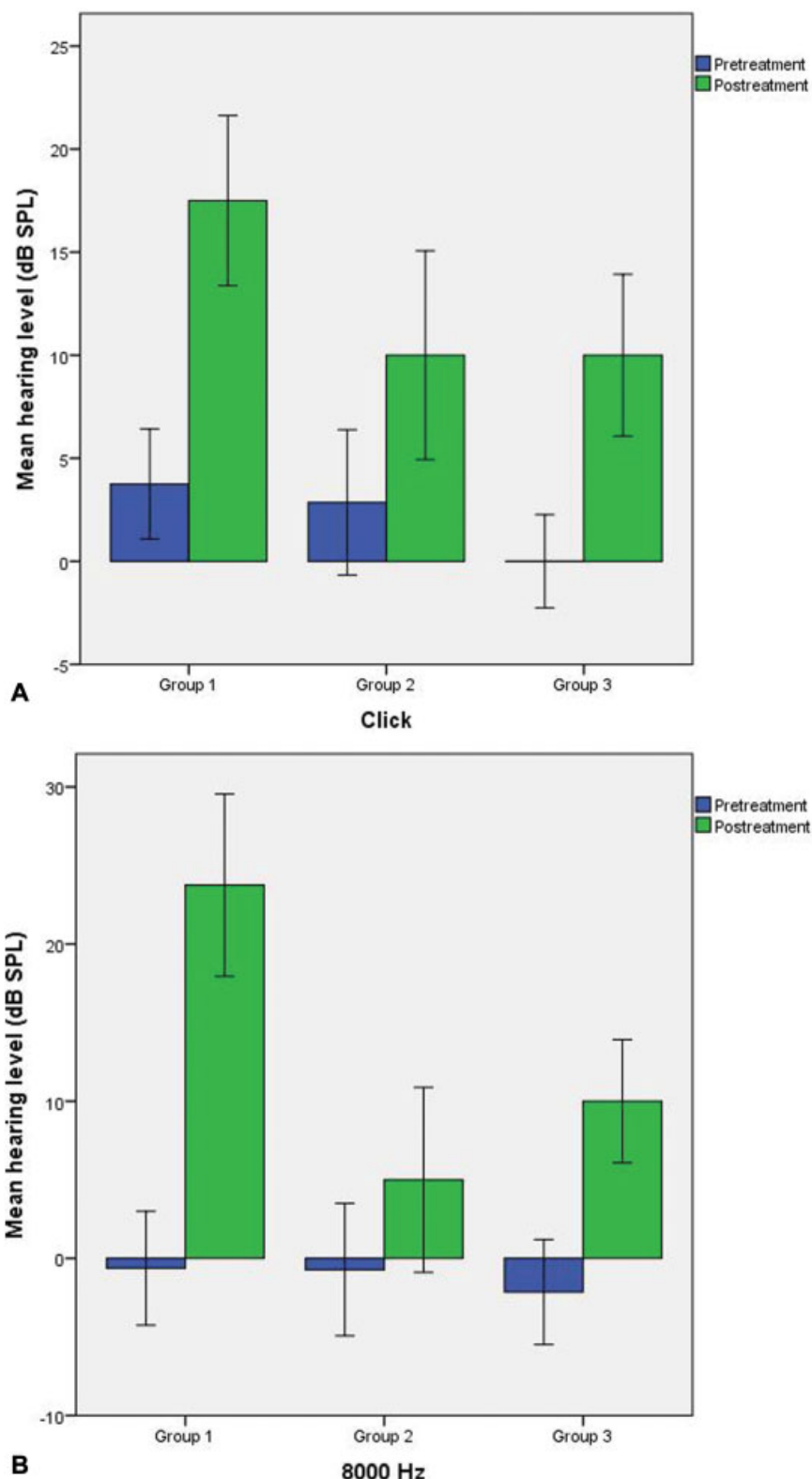
No significant difference was found between baseline ABR thresholds of the groups at both stimuli ( $p > 0.05$ ). After drug administration, in group 2, click ABR thresholds were similar ( $p > 0.05$ ) and 8 kHz ABR thresholds were significantly lower ( $p < 0.05$ ) in comparison with the control group. In group 3, click ABR thresholds were similar ( $p > 0.05$ ) and 8 kHz ABR thresholds were significantly lower ( $p < 0.05$ ) in comparison with the control group. There was no significant difference between group 2 and 3 with regard to posttreatment click and 8 kHz ABR thresholds ( $p > 0.05$ ) (**Fig. 1a** and **1b**).

### Histological Findings

Transmission electron microscopic inspection of hair cells (OHCs, IHCs), the stria vascularis and auditory nerve fibers were performed for 18 guinea pigs. The degeneration criteria for each one was determined by two histologists who were blinded to the groups and scored the structural and cellular deterioration as shown in **Tables 1, 2, and 3**. Each value in the relevant box of the tables signifies the degeneration scores of the involved specimens of six cochleae for each group. Histologists observed that in group 1, degenerative findings were evident at both outer (**Fig. 2a**) and inner hair cells (**Fig. 2b**). Marginal, intermediate and basal cells and fibroblasts, which form the stria vascularis, revealed significant degenerative appearances (**Fig. 2c**). Vascular structures of the epithelium were noted to have decreased. In the auditory nerve fibers, myelin lamellae separations, myelin figure formations in axons and inter-axonal areas, giant vacuolar formations in Schwann cells' cytoplasm and accumulations of electron-dense material in the myelin sheets were observed. Unlike group 1, the hair cell structures in animals from group 2 were substantially preserved in terms of the criteria stated in **Table 1**. Moderate loss of the stereocilia of outer and inner hair cells were observed in this group (**Figs. 3a** and **3b**). In group 2, a better view was determined at the level of the fine structures of the stria vascularis although giant vacuoles were still present (**Fig. 3c**); the same degenerative findings were found for both groups 1 and 2. Finally, in group 3, OHCs, IHCs and the stria vascularis showed normal fine structural features with the exception of some vacuolar formations (**Figs. 4a, 4b, and 4c**). Furthermore, in the auditory nerve fibers, whereas separations in the myelin sheath were significantly decreased, myelin formations were still observed in some axons and in the cytoplasm of Schwann cells.

## Discussion

The present study is the first study to investigate the effects of riluzole on cisplatin-induced ototoxicity. For click stimulus, ABR thresholds were similar among the groups before



**Fig. 1** Mean and SEM ABR values (pretreatment and posttreatment) in dB SPL for click (A) and 8 kHz tone burst stimuli (B) among the groups. Abbreviations: ABR: auditory brainstem response; SEM: standard error of the mean; SPL: sound pressure level

and after drug administration. For the 8 kHz-frequency stimulus, in the groups receiving cisplatin+ riluzole, there were significantly lower ABR thresholds when compared with the group receiving cisplatin+ saline after drug admin-

istration. For these outcomes, we believe that riluzole may have positive effect on hearing. On the other hand, no significant difference ABR thresholds was obtained between the groups receiving cisplatin + riluzole. After drug

**Table 1** Degenerative criteria and scores of outer hair cells and inner hair cells

Degenerative criteria	Outer hair cells (OHCs)			Inner hair cells (IHCs)		
	Group 1	Group 2	Group 3	Group 1	Group 2	Group 3
Loss of stereocilia	2, 2, 1, 3, 2, 3	2, 2, 1, 2, 3, 1	0, 0, 2, 1, 1, 1	2, 3, 1, 3, 3, 2	2, 1, 3, 2, 2, 2	0, 1, 1, 2, 2, 1
Deterioration in stereocilia	3, 2, 1, 3, 2, 2	2, 2, 1, 2, 2, 2	0, 1, 0, 0, 0, 1	3, 2, 2, 2, 2, 2	2, 1, 1, 1, 2, 2	0, 1, 0, 1, 0, 1
Vacuolar formations	2, 2, 2, 3, 2, 2	2, 2, 1, 1, 1, 2	1, 0, 0, 0, 1, 1	3, 3, 3, 2, 3, 3	2, 3, 3, 3, 3, 2	2, 1, 1, 1, 1, 1
Connection sides disorders	2, 1, 1, 1, 1, 1	1, 1, 1, 0, 1, 1	0, 0, 0, 1, 0, 0	2, 1, 2, 1, 1, 2	1, 1, 1, 2, 1, 1	1, 1, 0, 0, 0, 0
Disruption in mitochondrial settlement	3, 3, 3, 2, 3, 3	1, 1, 1, 2, 1, 1	1, 0, 0, 0, 0, 1	3, 3, 3, 3, 3, 3	1, 1, 1, 0, 1, 1	0, 0, 0, 0, 1, 0
Crystallization in mitochondria	2, 1, 1, 1, 1, 1	1, 1, 1, 1, 1, 1	0, 0, 1, 0, 0, 0	2, 1, 1, 1, 0, 2	1, 1, 1, 1, 0, 1	1, 0, 0, 1, 0, 1
Deterioration in afferent innervation	2, 1, 1, 2, 2, 1	1, 1, 1, 0, 1, 1	0, 1, 0, 0, 0, 0	2, 3, 2, 2, 2, 2	2, 1, 1, 1, 2, 1	1, 0, 1, 1, 1, 1
Lipid droplets	1, 0, 0, 1, 2, 2	1, 0, 0, 1, 1, 0	0, 0, 1, 0, 0, 0	1, 1, 1, 0, 1, 1	1, 1, 1, 0, 0, 1	1, 0, 0, 0, 0, 0

**Table 2** Degenerative criteria and scores of the stria vascularis

Degenerative criteria	Stria vascularis		
	Group 1	Group 2	Group 3
Giant vacuolar formations	3, 3, 3, 3, 3, 3	3, 2, 3, 2, 3, 2	2, 1, 1, 1, 1, 1
Crystallization	3, 2, 3, 3, 3, 3	3, 2, 2, 2, 2, 2	2, 1, 1, 1, 2, 2
Myelin figure formations	2, 3, 2, 2, 2, 2	2, 2, 2, 1, 2, 2	1, 2, 2, 2, 1, 1
Accumulation of electron-dense bodies	2, 2, 2, 3, 2, 2	2, 2, 2, 2, 2, 2	2, 1, 1, 1, 2, 2
Reduction of the vessels	3, 3, 3, 3, 3, 3	3, 2, 3, 2, 3, 3	2, 1, 1, 1, 1, 1
Connection sides disorders	3, 2, 2, 2, 2, 2	2, 1, 2, 2, 1, 1	1, 0, 1, 0, 0, 0
Irregular cell membrane formation at the apical region of marginal cells	0, 0, 1, 0, 1, 1	3, 3, 3, 2, 3, 2	0, 0, 1, 1, 0, 1

**Table 3** Degenerative criteria and scores of auditory nerve fibers

Degenerative criteria	Auditory nerve fibers		
	Group 1	Group 2	Group 3
The separation of myelin	3, 3, 3, 3, 3, 3	3, 2, 2, 3, 3, 3	1, 2, 2, 2, 1, 1
Myelin figure formations in inter-axons field	3, 3, 3, 2, 3, 3	3, 3, 3, 2, 3, 3	2, 3, 3, 2, 2, 2
Myelin figure formation in axons	3, 2, 3, 3, 3, 3	2, 3, 3, 2, 3, 3	2, 2, 2, 2, 2, 1
Giant vacuolar formations in cytoplasm of Schwann cells	3, 2, 2, 2, 2, 2	2, 1, 2, 2, 2, 1	1, 2, 1, 1, 1, 1
Accumulation of electro-dense bodies in myelin sheath	2, 1, 1, 1, 2, 1	1, 0, 1, 1, 1, 1	1, 0, 0, 0, 1, 0

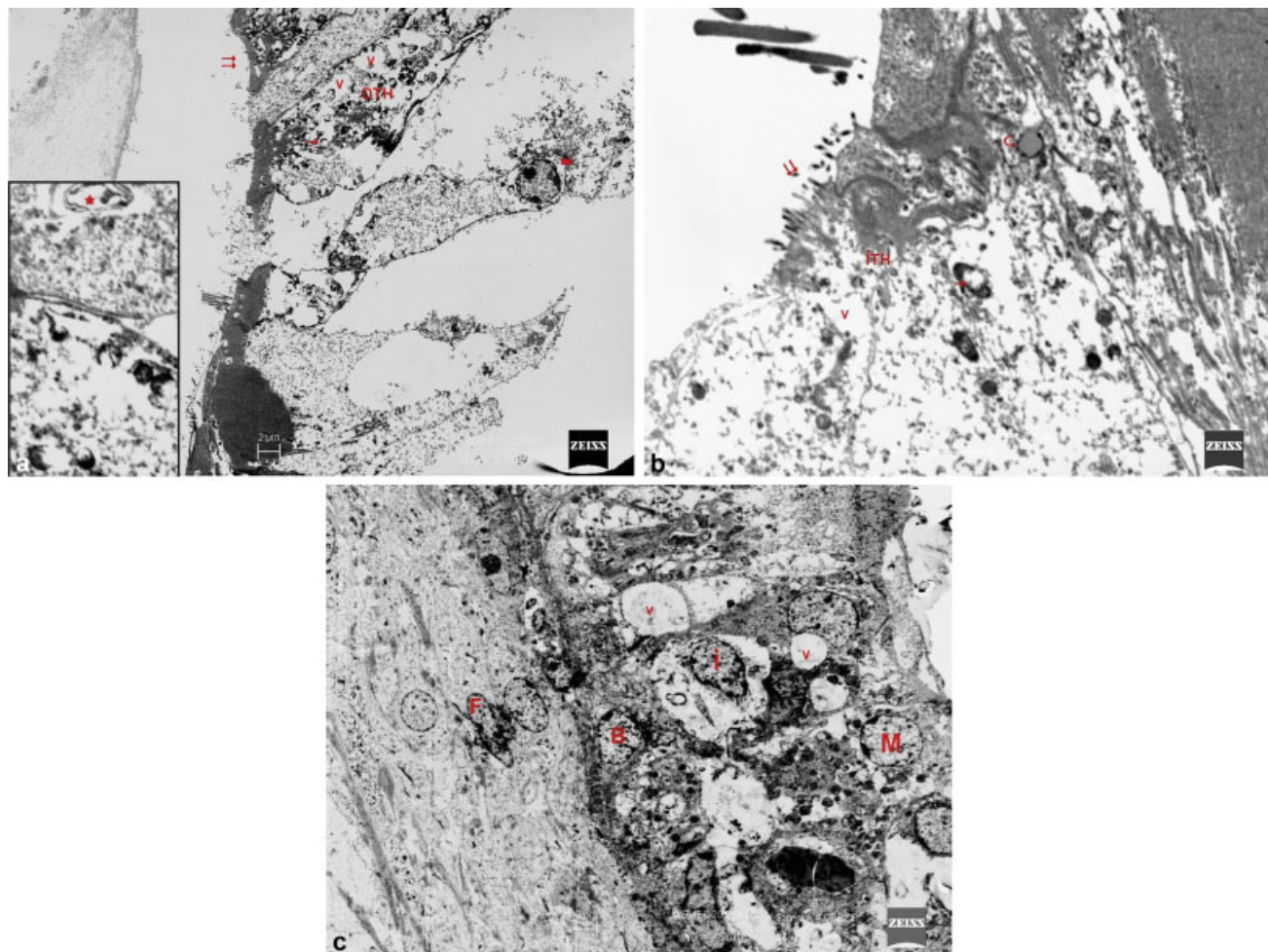
administration, we found relatively better mean ABR value in the group receiving 6 mg/kg of riluzole. The low counts of guinea pigs may be the reason of this result.

In addition, the TEM evaluation demonstrated that both doses of riluzole attenuated the degeneration of hair cells and the stria vascularis, known to be major target organs of cisplatin-induced ototoxicity in the cochlea. Unlike the ABR results, better fine structural features were observed in the groups receiving riluzole, especially in the group receiving 8 mg/kg of riluzole. For this outcome, we believe that riluzole

has a positive effect on preserving cells. Although there was discordance between the ABR results of groups 2 and 3, we can say that riluzole may have positive effects on hearing and preserving the cochlea.

The reason for morphological preservation of the stria vascularis and hair cells is unclear. Previously, the protective effect of riluzole on hair cells and ganglion neurons exposed to acoustic trauma was observed by Wang et al in an animal model. Their interpretation focused on an anti-excitotoxic mechanism for the protection of neuronal cells; this





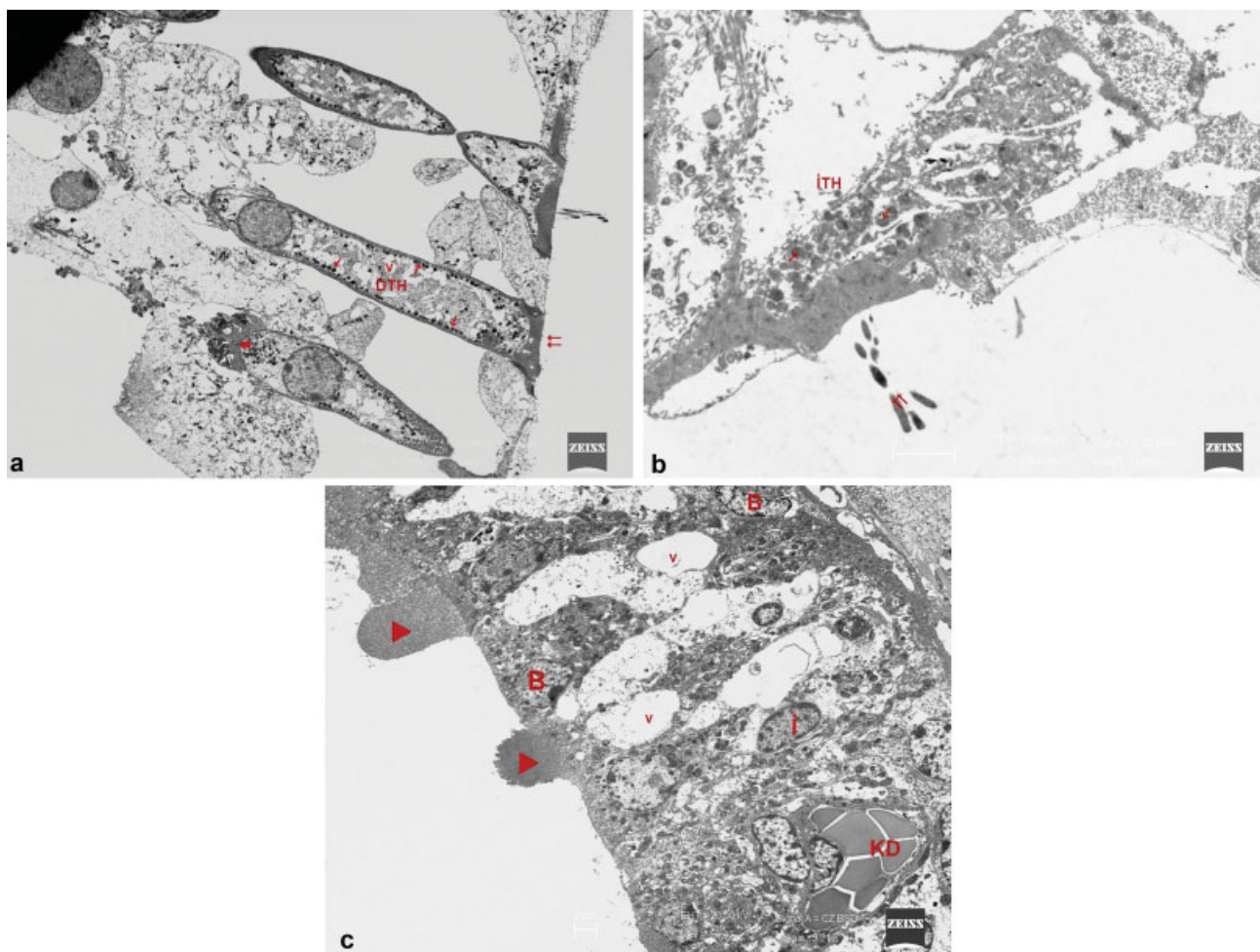
**Fig. 2** Transmission electron microscopy micrographs of OHCs, IHCs and the stria vascularis of group 1 (Uranyl acetate& Lead citrate). (a) OHCs in group 1: ⇨: the loss of stereocilia, v: vacuoles, →: crystallization in mitochondria, ▀: degeneration of afferent innervation, ★: myelin figures (b) IHCs in group 1: ⇨: the loss of stereocilia, v: vacuoles, →: crystallization in mitochondria, ◐: lipid droplets surrounded by electron condensed matter (c) Stria vascularis in group 1: M: marginal cell, I: intermediate cell, B: basal cell, F: fibroblasts, v: vacuoles. Abbreviations: IHCs: inner hair cells; OHCs: outer hair cells.

mechanism was not applicable to the preservation of hair cells, however, with riluzole being thought to act directly on hair cells via another, as yet unidentified, pathway.<sup>15</sup> We could elucidate the preservation of both hair cells and stria vascularis in our study with the same viewpoint.

There is no consensus in the current literature regarding the primary target organ of cisplatin in the cochlea. Van Ruijven et al demonstrated that cisplatin affected primarily OHC loss; this is followed by myelin sheath detachment of SGCs. Both processes then run in parallel without any obvious change in the stria vascularis.<sup>6,7</sup> In contrast, several studies have shown that damage to the stria vascularis precedes OHC loss in cisplatin ototoxicity, with Ocho et al proposing that hair cell damage is secondary to strial degeneration.<sup>25</sup> Thomas et al demonstrated the accumulation of platinum-DNA adducts by immunofluorescence, particularly in the nuclei of marginal cells in the stria vascularis, and demonstrated that OHCs had no accumulation of cisplatin-DNA adducts in the period between 4 and 48 hours after infusion of cisplatin in guinea pigs, thus concluding that the main target of cisplatin-induced ototoxicity is the stria vascularis.<sup>26</sup> Thomas et al noticed that damage of the stria

vascularis results in impaired potassium secretion into the endolymphatic space, and a decreased endocochlear potential that affects the sensorineural transduction of hair cells. Therefore, if the stria vascularis is considered as the main and the primary target organ, riluzole may have prevented the cisplatin-induced reduction of the endocochlear potential and precluded hair cell degeneration by initially providing protection to the stria vascularis.

Whereas it is well known that riluzole is a neuroprotective agent, and is generally considered an anti-glutamatergic drug, its mode of action is not entirely clear. Based on recent studies, we deduced that riluzole could also manifest protective effects in the context of cisplatin-induced ototoxicity via its antioxidant and antiapoptotic properties.<sup>17,18</sup> Roth et al demonstrated that, independent of its effect on glutamate release, riluzole could be protective against manganese (Mn) toxicity by suppressing ROS activation and could also avert downstream apoptotic signals by suppressing the activation of caspase 3 and JNK phosphorylation.<sup>17</sup> Additionally, riluzole can inhibit methylmercury (MeHg) induction of oxidative stress by triggering glutathione (GSH) synthesis; GSH is one of the most abundant and essential thiol tripeptides



**Fig. 3** Transmission electron microscopy micrographs of OHCs, IHCs and the stria vascularis of group 2 (Uranyl acetate& Lead citrate). (a) OHCs in group 2: : the loss of stereocilia, v: vacuoles →: mitochondria showing regular settlement under the cell membrane, ▀: normal afferent innervation (b) IHCs in group 2: ⇌: stereocilia, →: mitochondrion (c) Stria vascularis in group 2: M: marginal cell, I: intermediate cell, B: basal cell, v: vacuoles, ►: irregular formations in the apical portion. Abbreviations: IHCs: inner hair cells; OHCs: outer hair cells.

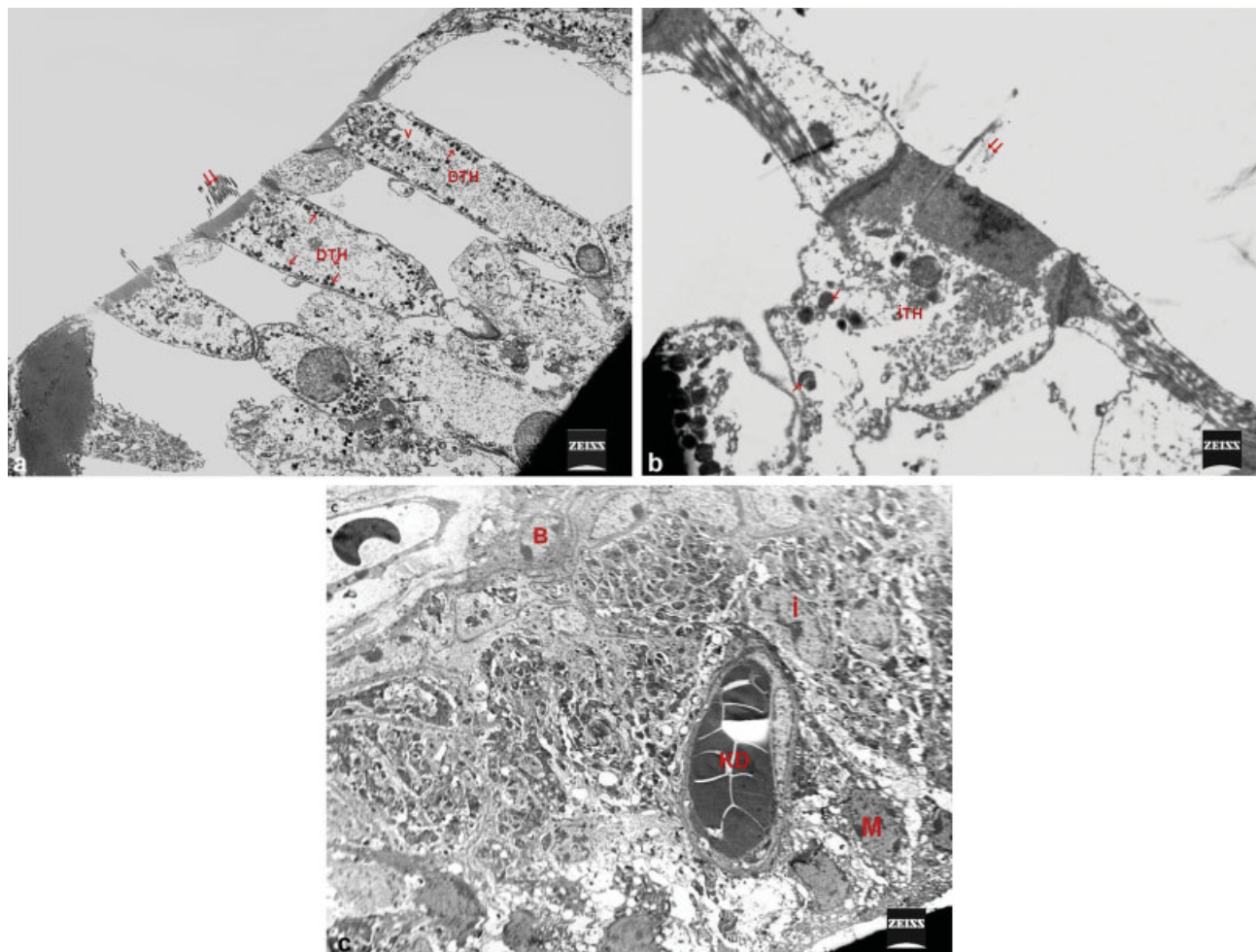
present in mammalian cells for scavenging ROS, and reduces oxidative stress,<sup>27</sup> which in turn may be a potential mechanism for the protective effect of riluzole. Unfortunately, we were not able to accrue data to investigate this specific pathway in our study.

One of the cisplatin-induced cytotoxic pathways, following the generation of ROS, is poly-(ADP-ribose) polymerase-1 (PARP-1) mediated cell death, which requires JNK to induce apoptosis. Heme oxygenase-1 (HO-1) and heat shock proteins (HSPs) 70 and 90 inhibit JNK phosphorylation and protect against cisplatin-induced ototoxicity.<sup>4,5</sup> Piperine, salicylates and the calcium channel blocker flunarizine are known to be protective agents against cisplatin-induced apoptosis by induction of HO-1.<sup>28-30</sup> Recent studies have shown that the combination of saline with riluzole at optimal doses stimulates the expression of the endogenous protective genes nuclear factor erythroid 2-related factor (NRF2) and HO-1.<sup>21,30</sup> In addition, riluzole can increase the amount of heat shock factor 1 (HSF-1) present in the neuronal cell system to boost HSPs.<sup>20,21</sup> The riluzole's mechanism of protection of the cochlea against cisplatin ototoxicity by may also involve inhibition of JNK phosphorylation by

increased levels of expression of endogenous protective genes.

Cisplatin administration induces the generation of ROS by employing the nicotinamide adenine dinucleotide phosphate (NADPH) oxidase 3 (NOX3), an isoform of NADPH oxidase that regulates stress-related genes in the cochlea, such as transient receptor potential vanilloid 1 (*TRPV 1*) and kidney injury molecule-1 (*KIM-1*), and initiates apoptosis in the cochlea. The expression of *TRPV 1* contributes to cell death by increasing the influx of  $Ca^{2+}$  into the cell and subsequently activating caspases.<sup>4</sup> Accordingly, the action of riluzole on voltage-gated calcium channels in cisplatin-induced cytotoxicity has also been considered. Long lasting (L)-type calcium channels, gated by high voltage, are expressed in the lateral wall, the organ of Corti and the SGN.<sup>31-33</sup> In cultured embryonic rat motor neurons, riluzole has been found to block L-type high voltage-activated (HVA)  $Ca^{2+}$  channels,<sup>34</sup> and administration of a T-type calcium channel antagonist (flunarizine) decreased apoptosis when compared with control in cisplatin-treated cells.<sup>30</sup> Perhaps the protective effect of riluzole on cisplatin-induced apoptosis is in part due to its capacity to block calcium channels.





**Fig. 4** Transmission electron microscopy micrographs of OHCs, IHCs and the stria vascularis of group 3 (a) OHCs in group 3: ⇌: stereocilia, v: vacuoles, →: regular settlement of mitochondria under the cell membrane (b) IHCs in group 3: ⇌: stereocilia, →: mitochondrion (c) Stria vascularis in group 3: M: marginal cell, I: intermediate cell, B: basal cell. Abbreviations: IHCs: inner hair cells; OHCs: outer hair cells.

## Conclusion

This is a preliminary study for evaluating the potential ability of riluzole to act as an otoprotective drug in the face of cisplatin ototoxicity. The results suggest that riluzole may have positive effects on hearing and on the degeneration of the cochlea in guinea pigs. However, additional studies are needed to confirm these results and the mechanism of action of riluzole.

### Note

This study was done in Gazi University Faculty of Medicine, Ankara, Turkey.

This study was approved and monitored by Gazi University Animal Experiments Local Ethics Committee (G. Ü. ET - B.30.2.GÜN.0.05.06.00/80-6489).

### Financial Disclosure

The study was supported by a grant from the Scientific Research Projects Commission.

### Conflicts of Interest

The authors do not have any conflict of interest to declare.

## Acknowledgment

This study was funded by the Gazi University Scientific Research and Projects Commission (01/2011-102).

## References

- Rybak LP, Ramkumar V. Ototoxicity. *Kidney Int* 2007;72(08):931–935
- Bokemeyer C, Berger CC, Hartmann JT, et al. Analysis of risk factors for cisplatin-induced ototoxicity in patients with testicular cancer. *Br J Cancer* 1998;77(08):1355–1362
- Rybak LP, Mukherjea D, Jajoo S, Ramkumar V. Cisplatin ototoxicity and protection: clinical and experimental studies. *Tohoku J Exp Med* 2009;219(03):177–186
- Casares C, Ramírez-Camacho R, Trinidad A, Roldán A, Jorge E, García-Berrocal JR. Reactive oxygen species in apoptosis induced by cisplatin: review of physiopathological mechanisms in animal models. *Eur Arch Otorhinolaryngol* 2012;269(12):2455–2459
- Rybak LP. Mechanisms of cisplatin ototoxicity and progress in otoprotection. *Curr Opin Otolaryngol Head Neck Surg* 2007;15(05):364–369
- van Ruijven MW, de Groot JCMJ, Klis SFL, Smoorenburg GF. The cochlear targets of cisplatin: an electrophysiological and morphological time-sequence study. *Hear Res* 2005;205(1-2):241–248
- van Ruijven MW, de Groot JCMJ, Smoorenburg GF. Time sequence of degeneration pattern in the guinea pig cochlea during cisplatin



- administration. A quantitative histological study. *Hear Res* 2004; 197(1-2):44-54
- 8 Cardinaal RM, de Groot JCMJ, Huizing EH, Veldman JE, Smoorenburg GF. Dose-dependent effect of 8-day cisplatin administration upon the morphology of the albino guinea pig cochlea. *Hear Res* 2000;144(1-2):135-146
  - 9 Feghali JG, Liu W, Van De Water TR. L-n-acetyl-cysteine protection against cisplatin-induced auditory neuronal and hair cell toxicity. *Laryngoscope* 2001;111(07):1147-1155
  - 10 Ramírez-Camacho R, García-Berrocal JR, Buján J, Martín-Marero A, Trinidad A. Supporting cells as a target of cisplatin-induced inner ear damage: therapeutic implications. *Laryngoscope* 2004; 114(03):533-537
  - 11 Cheah BC, Vucic S, Krishnan AV, Kiernan MC. Riluzole, neuroprotection and amyotrophic lateral sclerosis. *Curr Med Chem* 2010; 17(18):1942-199
  - 12 Bellingham MC. A review of the neural mechanisms of action and clinical efficiency of riluzole in treating amyotrophic lateral sclerosis: what have we learned in the last decade? *CNS Neurosci Ther* 2011;17(01):4-31
  - 13 Ettaiche M, Fillacier K, Widmann C, Heurteaux C, Lazdunski M. Riluzole improves functional recovery after ischemia in the rat retina. *Invest Ophthalmol Vis Sci* 1999;40(03): 729-736
  - 14 Lang-Lazdunski L, Heurteaux C, Mignon A, et al. Ischemic spinal cord injury induced by aortic cross-clamping: prevention by riluzole. *Eur J Cardiothorac Surg* 2000;18(02):174-181
  - 15 Wang J, Dib M, Lenoir M, et al. Riluzole rescues cochlear sensory cells from acoustic trauma in the guinea-pig. *Neuroscience* 2002; 111(03):635-648
  - 16 Ruel J, Wang J, Pujol R, Hameg A, Dib M, Puel JL. Neuroprotective effect of riluzole in acute noise-induced hearing loss. *Neuroreport* 2005;16(10):1087-1090
  - 17 Roth JA, Sridhar S, Singleton ST. Effect of glutamate and riluzole on manganese-induced apoptotic cell signaling in neuronally differentiated mouse P19 Cells. *Neurochem Int* 2012;61(01): 25-33
  - 18 Koh JY, Kim DK, Hwang JY, Kim YH, Seo JH. Antioxidative and proapoptotic effects of riluzole on cultured cortical neurons. *J Neurochem* 1999;72(02):716-723
  - 19 Mu X, Azbill RD, Springer JE. Riluzole improves measures of oxidative stress following traumatic spinal cord injury. *Brain Res* 2000;870(1-2):66-72
  - 20 Liu AYC, Mathur R, Mei N, Langhammer CG, Babiarsz B, Firestein BL. Neuroprotective drug riluzole amplifies the heat shock factor 1 (HSF1)- and glutamate transporter 1 (GLT1)-dependent cytoprotective mechanisms for neuronal survival. *J Biol Chem* 2011;286 (04):2785-2794
  - 21 Yang J, Bridges K, Chen KY, Liu AYC. Riluzole increases the amount of latent HSF1 for an amplified heat shock response and cyto-protection. *PLoS One* 2008;3(08):e2864
  - 22 Chang G, Guo Y, Jia Y, et al. Protective effect of combination of sulforaphane and riluzole on glutamate-mediated excitotoxicity. *Biol Pharm Bull* 2010;33(09):1477-1483
  - 23 Elmas Ç, Bahçelioğlu M, Erdoğan D, et al. Immunohistochemical and Ultrastructural Changes Related To Methylphenidate In Rat Pituitary and Pineal Glands. *J Neurol Sci* 2012;29(03):476-493
  - 24 Elmas Ç, Erdoğan D, Gökteş G, et al. İyonize Radyasyon Uygulaması Yapılmış Rat Pineal Bezi Üzerinde Melatoninin Koruyucu Etkisi Var mıdır? *Kronobiyolojik ve Elektron Mikroskopik Çalışma*. *Kafkas Univ Vet Fak Derg* 2013;19(01):153-160
  - 25 Ocho S, Iwasaki S, Umemura K, Hoshino T. A new model for investigating hair cell degeneration in the guinea pig following damage of the stria vascularis using a photochemical reaction. *Eur Arch Otorhinolaryngol* 2000;257(04):182-187
  - 26 Thomas JP, Lautermann J, Liedert B, Seiler F, Thomale J. High accumulation of platinum-DNA adducts in strial marginal cells of the cochlea is an early event in cisplatin but not carboplatin ototoxicity. *Mol Pharmacol* 2006;70(01):23-29
  - 27 Deng Y, Xu ZF, Liu W, Xu B, Yang HB, Wei YG. Riluzole-triggered GSH synthesis via activation of glutamate transporters to antagonize methylmercury-induced oxidative stress in rat cerebral cortex. *Oxid Med Cell Longev* 2012;2012:534705
  - 28 Choi BM, Kim SM, Park TK, et al. Piperine protects cisplatin-induced apoptosis via heme oxygenase-1 induction in auditory cells. *J Nutr Biochem* 2007;18(09):615-622
  - 29 Li G, Sha SH, Zotova E, Arezzo J, Van de Water T, Schacht J. Salicylate protects hearing and kidney function from cisplatin toxicity without compromising its oncolytic action. *Lab Invest* 2002;82(05):585-596
  - 30 So HS, Kim HJ, Lee JH, et al. Flunarizine induces Nrf2-mediated transcriptional activation of heme oxygenase-1 in protection of auditory cells from cisplatin. *Cell Death Differ* 2006;13(10):1763-1775
  - 31 Hafidi A, Dulon D. Developmental expression of Ca(v)1.3 ( $\alpha 1d$ ) calcium channels in the mouse inner ear. *Brain Res Dev Brain Res* 2004;150(02):167-175
  - 32 Layton MG, Robertson D, Everett AW, Mulders WH, Yates GK. Cellular localization of voltage-gated calcium channels and synaptic vesicle-associated proteins in the guinea pig cochlea. *J Mol Neurosci* 2005;27(02):225-244
  - 33 Chen WC, Xue HZ, Hsu Y, Liu Q, Patel S, Davis RL. Complex distribution patterns of voltage-gate calcium channel  $\alpha$ -subunits in the spiral ganglion. *Hear Res* 2011;278(1-2):52-68
  - 34 Hubert JP, Burgevin MC, Terro F, Hugon J, Doble A. Effects of depolarizing stimuli on calcium homeostasis in cultured rat motoneurons. *Br J Pharmacol* 1998;125(07):1421-1428