

Case Report

Treatment for Giant Fusiform Aneurysm Located in the Cavernous Segment of the Internal Carotid Artery Using the Pipeline Embolization Device

Se-yang Oh, M.D.,^{1*} Myeong Jin Kim, M.D.,³ Bum-soo Kim, M.D.,² Yong Sam Shin, M.D.¹

Departments of Neurosurgery,¹ Radiology,² Seoul St. Mary's Hospital, The Catholic University of Korea College of Medicine, Seoul, Korea
Department of Neurosurgery,³ Gachon University, Gil Hospital, Incheon, Korea

The pipeline embolization device (PED) is a new endovascular device for treatment of complex, fusiform and wide-neck intracranial aneurysms. The main mechanism of this stent is to divert the flow in the parent artery with reduction of inflow in the aneurysm leading to thrombosis. We treated a 40-year-old woman who had left facial pain and orbit discomfort. Angiography showed a giant fusiform aneurysm located in the cavernous segment of the left internal carotid artery. A PED was successfully deployed across the aneurysm. The procedure and post-procedural course were uneventful. After 3 months, angiography showed complete obliteration of the aneurysm with good patency of the branching vessels originating from the deployed segment. The patient's symptoms improved completely without complications.

Key Words : Pipeline embolization device · Fusiform aneurysm.

INTRODUCTION

The pipeline embolization device (PED) (EV3, Irvine, CA, USA) has emerged an efficient treatment for complex intracranial aneurysms, especially wide-necked, large or giant, fusiform shaped aneurysms^{1,2,4,8,14,19,21}. The PED is a self-expanding, microcatheter-delivered, cylindrical mesh device composed of 48 braided cobalt chromium and platinum strands⁷. This low-porosity stent has main two mechanisms. It redirects blood flow along the normal course of the parent artery, favoring blood stasis and thrombosis inside the aneurysm, and it allows neointimal growth along the stented segment, resulting in endoluminal reconstruction^{7,15,17,26}. In this case report, we describe our first use of PED for a symptomatic, giant fusiform aneurysm located in the cavernous segment of the internal carotid artery.

CASE REPORT

A 40-year-old woman presented with a 5-year history of sharp

left facial pain and discomfort of the left orbit when she moved her eye. Digital subtraction angiography (DSA) revealed a giant fusiform aneurysm involving the cavernous segment of the left internal carotid artery (ICA) (Fig. 1). The aneurysm was measured by 25×11 mm. The A1 segment of the anterior cerebral artery of the left ICA was nondominant. A cross filling test with manual compression of the left ICA showed a lack of blood supply from the anterior communicating and posterior communicating arteries. As a result, a balloon occlusion test was not indicated. Because of the size, fusiform shape and poor-collateral blood supply of the aneurysm, we decided to treat the patient with a PED. The patient received 100 mg of aspirin and 75 mg of clopidogrel per day for 1 week before the procedure.

After starting general anesthesia, the patient was given a bolus of heparin and activated clotting time was maintained at 2 to 3 times baseline throughout the procedure. After accessing the right femoral artery, a 6 Fr Envoy guiding catheter (Cordis, Miami, FL, USA) was placed just proximal to the petrous segment of the left ICA using a coaxial technique. We gained con-

• Received : May 24, 2013 • Revised : June 30, 2013 • Accepted : December 16, 2013

* Move to : Department of Neurosurgery, Inje University School of Medicine, Seoul, Korea

• Address for reprints : Yong Sam Shin, M.D.

Department of Neurosurgery, Seoul St. Mary's Hospital, The Catholic University of Korea College of Medicine, 222 Banpo-daero, Seocho-gu, Seoul 137-701, Korea
Tel : +82-2-2258-6125, Fax : +82-2-594-4248, E-mail : nsshin@gmail.com

• This is an Open Access article distributed under the terms of the Creative Commons Attribution Non-Commercial License (<http://creativecommons.org/licenses/by-nc/3.0>) which permits unrestricted non-commercial use, distribution, and reproduction in any medium, provided the original work is properly cited.

trol angiography to measure the size of the aneurysm and the parent arteries. The diameter of the inflow vessel at the petrous segment was 4.1 mm and the diameter of the outflow vessel at the cavernous segment was 3.2 mm. A Marksman microcatheter (EV3, Irvine, CA, USA) with a 0.027-inch diameter was introduced at the M1-M2 junction. A 4.0×20 mm PED was delivered via microcatheter. The PED was deployed across the targeted landing zone by repeated maneuvers of microcatheter un-sheathing, delivery-wire stabilization and advancement, and microcatheter loading²⁰. Postprocedural angiography demonstrated that filling of the aneurysmal sac was slower than observed by preprocedural angiography. DynaCT and three-dimensional reconstructive angiography showed good stent position with no redundant portions between the PED and the wall of the parent vessel (Fig. 2). The periprocedural course was uneventful. The patient's facial pain was markedly improved the day after the procedure and the patient was discharged.

The patient returned for a 3-month follow-up angiography, having maintained antiplatelet medication of 100 mg aspirin and 75 mg clopidogrel per day. Symptoms had gradually reduced without neurological changes. DSA demonstrated anatomic reconstruction of the parent artery with complete occlusion of the aneurysm (Fig. 3). The distal portion of the PED covered the origin of the meningohypophyseal trunk; however, the meningohypophysial trunk was easily visualized by angiography. DynaCT and three-dimensional reconstruction angiography showed proper patency of the in-stent lumen without stenosis. The PED remained in the same position without migration or change in shape.

DISCUSSION

After the advent of flow-diverting devices such as PEDs and Silk (Balt Extrusion, Montmorency, France), the aneurysm treatment changed rapidly. Flow-diverting devices are a significant advance in endovascular remodeling strategies for aneurysm treatment⁷. Initial results with PEDs have been excellent, and several studies demonstrated rates of complete occlusion from 80% to 95% at 6 months^{15,17,24,29}. In the Pipeline for Uncoilable or Failed Aneurysms (PUFS) trial, the complete occlusion rate at 6 months was 81.8% with a major complication rate of 5.6% among 107 patients treated. In April 2011, on the basis of the results of the PUFS trial, the US Food and Drug Administration

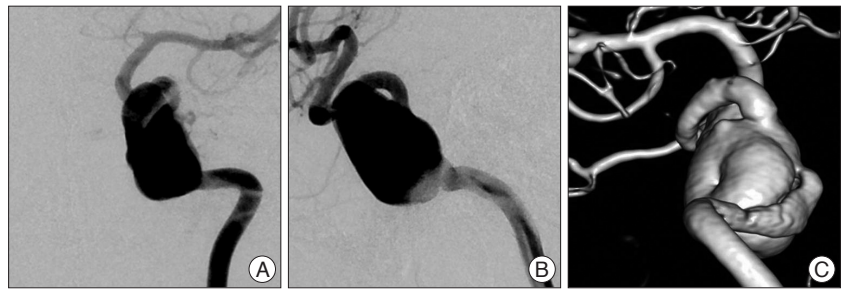


Fig. 1. Preprocedural angiography with AP (A) and lateral (B) views and three-dimensional reconstruction angiography (C) show a giant fusiform aneurysm involving the cavernous segment of the left internal carotid artery.

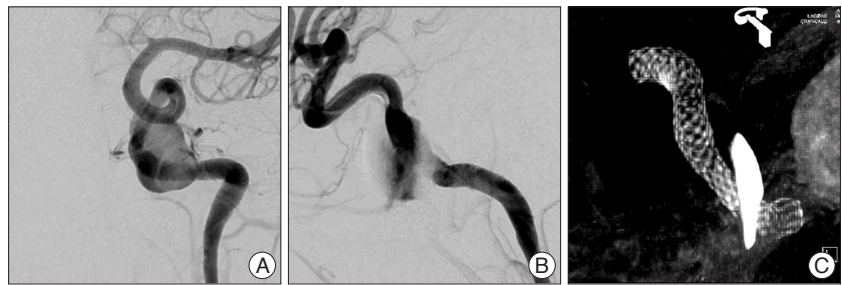

Fig. 2. Immediate postprocedural angiography with AP (A) and lateral (B) views show that filling of the aneurysmal sac is slower than preprocedural angiography. DynaCT (C) shows stagnation of the contrast within the sac and good position with no redundant portions or stenosis of the device.

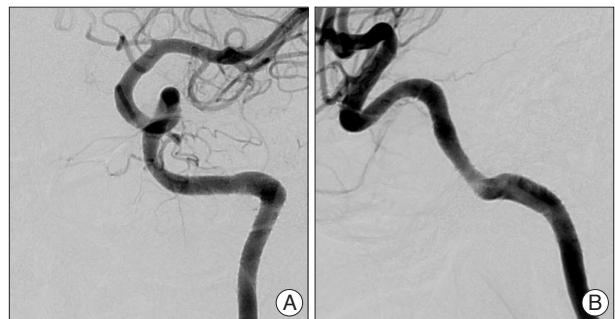

Fig. 3. AP (A) and lateral (B) views of 3-month angiography demonstrate anatomic reconstruction of the parent artery with complete occlusion of the aneurysm with the meningohypophyseal trunk preserved.

approved the PED for the treatment of large or giant wide-necked intracranial aneurysms for petrous to superior hypophyseal segments of the ICA²⁷. More recent reports on postmarket data, and results of mid-, and long-term follow-up have supported these results^{9,19,21}.

The PED has not yet been widely used in Korea. This is the first follow-up report of initial three cases have been treated using PEDs in Korea. The procedure was finished successfully without periprocedural complications and the patient's symptoms were markedly improved the day after the procedure. We supposed that decline of pulsation of the aneurysm provide the dramatic relieves of the pain immediately after procedure. Clinical and radiologic results at the 3-month follow-up were excellent. The aneurysm of this case report was completely obliterated and the meningohypophyseal trunk originating from the segment covered by the PED was preserved.

After our initial experience, we reviewed some potential consideration revealed in our case and previously reported cases. First, the possibility of complications is considerable. Some series reported trivial complication rates of 5% to 20% and morbidity and mortality of 0% to 7%^{1,2,4,8,14,19,21}. In previous reports, complication rates were acceptable compared with previous modalities; however, the periprocedural and postprocedural complications of PED were still considerable. Early and delayed aneurysm ruptures following treatment with flow-diverting devices have been reported^{3,12,19,26}. Rates of hemorrhagic events were 0% to 6% in large case series^{8,17,19,24}. Suggested possible causes were perforation of branches and aneurysm during procedure, hemorrhage within ischemic tissue, microemboli, and antiplatelet medications^{8,19,22,24}. For prevention of delayed rupture or re-bleeding of aneurysm, adjunctive coiling with PEDs was suggested^{17,19,21,22}. Although the proved evidence of the benefits of adjunctive coiling is still lack, some authors suggested that the technique would be valuable for some aneurysms including acute stage of ruptured aneurysms with high jet flows^{5,19}. Thromboembolic complications during the periprocedural period, early and late follow-up were reported in several series and case reports^{8,10,11,16,17,24,28}. The rate of major infarction in large case series was 0.5% to 7%^{8,9,14,17,19}. The possible causes include resistance to antiplatelet medication, improper deployment of the device, compromise of covered branches, and in-stent stenosis¹⁹. Second, interventionists must establish proper indications for using a flow diverter for an aneurysm. Recent meta-analyses and large studies have expressed concerns regarding the feasibility, effectiveness, and high occlusion rates of flow diverters^{2,9,16,19}. However, delayed rupture, especially ruptured and larger aneurysms^{1,3,5,16} and severe ischemic stroke caused by perforator infarctions in aneurysms in posterior circulation locations^{10,18,29} have been reported in some PED series. Coil embolization and microsurgery are excellent methods in terms of efficiency, convenience, cost, and durability. Reconstructive surgery using artery-to-artery bypass with the occluding parent artery is a proven radical method for complex aneurysms^{6,13,20,23}. An interdisciplinary team approach for determining the proper indications for each aneurysm would lead to better outcomes. Finally, successful deployment of a PED requires considerable expertise in endovascular treatment. PEDs have different qualities and profiles than previously used stents and stent-like devices. Careful unsheathing, delivery-wire stabilization and advancement, and pushing of the wire and the loading the next segment of the PED must be accurately and sequentially applied to completely deploy the PED¹⁹. Conventional unsheathing and deploying methods likewise other intracranial stents cannot be used to deploy the PED. In previous reports, the possible causes of device migration and malposition were explained by some technical faults : 1) inadequate vessel wall apposition when deploying the device, and 2) mismatch in diameter between the vessel and the device^{4,14,19}. To prevent technical complications, a complete understanding of the properties of the flow-diverter and sufficient experiences in

endovascular procedure is mandatory.

CONCLUSION

We treated a giant fusiform aneurysm located in the cavernous segment of left ICA using a PED. After 3 months, angiography showed complete obliteration of the aneurysm with preservation of the branched vessels. The patient's symptoms improved without complication. Safe use of the device requires establishment of proper indication, and sufficient experience is essential.

References

- Berge J, Biondi A, Machi P, Brunel H, Pierot L, Gabrillargues J, et al. : Flow-diverter silk stent for the treatment of intracranial aneurysms : 1-year follow-up in a multicenter study. *AJNR Am J Neuroradiol* 33 : 1150-1155, 2012
- Brinjikji W, Murad MH, Lanzino G, Cloft HJ, Kallmes DF : Endovascular treatment of intracranial aneurysms with flow diverters : a meta-analysis. *Stroke* 44 : 442-447, 2013
- Cebral JR, Mut F, Raschi M, Scrivano E, Ceratto R, Lylyk P, et al. : Aneurysm rupture following treatment with flow-diverting stents : computational hemodynamics analysis of treatment. *AJNR Am J Neuroradiol* 32 : 27-33, 2011
- Chalouhi N, Satti SR, Tjoumakaris S, Dumont AS, Gonzalez LF, Rosenwasser R, et al. : Delayed migration of a pipeline embolization device. *Neurosurgery* 72 (2 Suppl Operative) : ons229-ons234; discussion ons234, 2013
- Cruz JP, Chow M, O'Kelly C, Marotta B, Spears J, Montanera W, et al. : Delayed ipsilateral parenchymal hemorrhage following flow diversion for the treatment of anterior circulation aneurysms. *AJNR Am J Neuroradiol* 33 : 603-608, 2012
- Evans JJ, Sekhar LN, Rak R, Stimac D : Bypass grafting and revascularization in the management of posterior circulation aneurysms. *Neurosurgery* 55 : 1036-1049, 2004
- Fiorella D, Woo HH, Albuquerque FC, Nelson PK : Definitive reconstruction of circumferential, fusiform intracranial aneurysms with the pipeline embolization device. *Neurosurgery* 62 : 1115-1120; discussion 1120-1121, 2008
- Fischer S, Vajda Z, Aguilar Perez M, Schmid E, Hopf N, Bätzner H, et al. : Pipeline embolization device (PED) for neurovascular reconstruction : initial experience in the treatment of 101 intracranial aneurysms and dissections. *Neuroradiology* 54 : 369-382, 2012
- Kan P, Siddiqui AH, Veznedaroglu E, Liebman KM, Binning MJ, Dumont TM, et al. : Early postmarket results after treatment of intracranial aneurysms with the pipeline embolization device : a U.S. multicenter experience. *Neurosurgery* 71 : 1080-1087; discussion 1087-1088, 2012
- Klisch J, Turk A, Turner R, Woo HH, Fiorella D : Very late thrombosis of flow-diverting constructs after the treatment of large fusiform posterior circulation aneurysms. *AJNR Am J Neuroradiol* 32 : 627-632, 2011
- Kulcsár Z, Ernemann U, Wetzel SG, Bock A, Goericke S, Panagiotopoulos V, et al. : High-profile flow diverter (silk) implantation in the basilar artery : efficacy in the treatment of aneurysms and the role of the perforators. *Stroke* 41 : 1690-1696, 2010
- Kulcsár Z, Houdart E, Bonafé A, Parker G, Millar J, Goddard AJ, et al. : Intra-aneurysmal thrombosis as a possible cause of delayed aneurysm rupture after flow-diversion treatment. *AJNR Am J Neuroradiol* 32 : 20-25, 2011
- Lawton MT, Hamilton MG, Morcos JJ, Spetzler RF : Revascularization and aneurysm surgery : current techniques, indications, and outcome. *Neurosurgery* 38 : 83-92; discussion 92-94, 1996

14. Lubicz B, Collignon L, Raphaeli G, De Witte O : Pipeline flow-diverter stent for endovascular treatment of intracranial aneurysms : preliminary experience in 20 patients with 27 aneurysms. *World Neurosurg* **76** : 114-119, 2011
15. Lylyk P, Miranda C, Ceratto R, Ferrario A, Scrivano E, Luna HR, et al. : Curative endovascular reconstruction of cerebral aneurysms with the pipeline embolization device : the Buenos Aires experience. *Neurosurgery* **64** : 632-642; discussion 642-643; quiz N6, 2009
16. McAuliffe W, Wycoco V, Rice H, Phatouros C, Singh TJ, Wenderoth J : Immediate and midterm results following treatment of unruptured intracranial aneurysms with the pipeline embolization device. *AJNR Am J Neuroradiol* **33** : 164-170, 2012
17. Nelson PK, Lylyk P, Szikora I, Wetzel SG, Wanke I, Fiorella D : The pipeline embolization device for the intracranial treatment of aneurysms trial. *AJNR Am J Neuroradiol* **32** : 34-40, 2011
18. Pierot L : Flow diverter stents in the treatment of intracranial aneurysms : Where are we? *J Neuroradiol* **38** : 40-46, 2011
19. Saatci I, Yavuz K, Ozer C, Geyik S, Cekirge HS : Treatment of intracranial aneurysms using the pipeline flow-diverter embolization device : a single-center experience with long-term follow-up results. *AJNR Am J Neuroradiol* **33** : 1436-1446, 2012
20. Sekhar LN, Duff JM, Kalavakonda C, Olding M : Cerebral revascularization using radial artery grafts for the treatment of complex intracranial aneurysms : techniques and outcomes for 17 patients. *Neurosurgery* **49** : 646-658; discussion 658-659, 2001
21. Shankar JJ, Vidorpe R, Pickett G, Maloney W : SILK flow diverter for treatment of intracranial aneurysms : initial experience and cost analysis. *J Neurointerv Surg* **5 Suppl 3** : iii11-iii15, 2013
22. Siddiqui AH, Kan P, Abl AA, Hopkins LN, Levy EI : Complications after treatment with pipeline embolization for giant distal intracranial aneurysms with or without coil embolization. *Neurosurgery* **71** : E509-E513; discussion E513, 2012
23. Spetzler RF, Carter LP : Revascularization and aneurysm surgery : current status. *Neurosurgery* **16** : 111-116, 1985
24. Szikora I, Berentei Z, Kulcsar Z, Marosfoi M, Vajda ZS, Lee W, et al. : Treatment of intracranial aneurysms by functional reconstruction of the parent artery : the Budapest experience with the pipeline embolization device. *AJNR Am J Neuroradiol* **31** : 1139-1147, 2010
25. Turjman F, Acevedo G, Moll T, Duquesnel J, Eloy R, Sindou M : Treatment of experimental carotid aneurysms by endoprosthesis implantation : preliminary report. *Neurol Res* **15** : 181-184, 1993
26. Turowski B, Macht S, Kulcsár Z, Hänggi D, Stummer W : Early fatal hemorrhage after endovascular cerebral aneurysm treatment with a flow diverter (SILK-Stent) : do we need to rethink our concepts? *Neuroradiology* **53** : 37-41, 2011
27. U.S. Food and Drug Administration : Summary of Safety and Effectiveness Data, Pipeline Embolization Device, P100018 : 2011, http://www.accessdata.fda.gov/cdrh_docs/pdf10/P100018a.pdf
28. van Rooij WJ, Sluzewski M : Perforator infarction after placement of a pipeline flow-diverting stent for an unruptured A1 aneurysm. *AJNR Am J Neuroradiol* **31** : E43-E44, 2010
29. Wong GK, Lau JC, Poon WS : Flow diverting stents for cerebral aneurysm treatment : time to replace coiling? *J Clin Neurosci* **18** : 1143, 2011