

Comparability and repeatability of pachymetry in keratoconus using four noncontact techniques

Mukesh Kumar, Rohit Shetty, Chaitra Jayadev, Debarun Dutta¹

Purpose: To compare and determine the repeatability of central corneal thickness (CCT) measurements using four noncontact pachymetry instruments in eyes with keratoconus. **Materials and Methods:** The CCT of consecutive patients with keratoconus was measured during a single visit using the swept source optical coherence tomography (SS-OCT, Casia SS-1000°CT, Tomey, Nagoya, Japan), a rotating Scheimpflug camera system (Pentacam, Oculus Optikgerate GmbH, Wetzlar, Germany), scanning slit topographer (Orbscan IIz topography, Bausch and Lomb Surgical Inc., San Dimas, CA, USA), and a hand-held spectral domain OCT (HHSD-OCT, Biotigen Inc., Durham, North Carolina, USA). Test-retest variability, correlation between measurements and interdevice agreement were analyzed. **Results:** Fifty eyes of 25 participants were analyzed in this study. All measurement methods correlated well with each other ($r > 0.9$, $P < 0.001$). Mean \pm standard deviation CCT measured by HHSD-OCT, Orbscan IIz, SS-OCT, and Pentacam was $462 \pm 41 \mu\text{m}$, $458 \pm 41 \mu\text{m}$, $454 \pm 40 \mu\text{m}$, and $447 \pm 42 \mu\text{m}$, respectively. While the HHSD-OCT over-estimated the CCT ($P < 0.001$), there was a good correlation between the measurements obtained from the other three devices. However, the numerical difference was high and this trend was seen in all the paired comparisons. **Conclusions:** Though the measurements by different devices correlated well, the numerical agreement may be inadequate for their interchangeable use in clinical practice.

Key words: Central corneal thickness, hand-held spectral domain optical coherence tomography, ultrasound pachymetry

Keratoconus is a noninflammatory progressive condition of the cornea characterized by corneal ectasia and thinning which results in astigmatism (irregular and regular) and decrease in vision.^[1] Since thinning of the cornea is initially noted in the central region, the progression and severity of keratoconus can be monitored by measuring the central corneal thickness (CCT) and the degree of protrusion. It is known that central and inferotemporal corneal thickness is significantly less in keratoconus than in normal corneas.^[2,3] Early detection and follow-up of changes in the CCT, especially in progressive keratoconus can help to prognosticate the disease.

At present, there are various contact and noncontact techniques available to measure CCT. Accuracy and repeatability of these techniques in measuring the CCT in keratoconus patients assume greater importance with the advent of newer prophylactic and therapeutic corneal intervention such as intrastromal corneal ring segment implantation,^[4-8] collagen crosslinking,^[9] and deep lamellar keratoplasty.^[10]

The CCT in keratoconus has previously been measured with anterior segment optical coherence tomography (AS-OCT), ultrasound pachymetry (USP), and Orbscan IIz (Bausch and Lomb Surgical Inc., San Dimas, CA, USA) and these studies

have shown a high correlation between the techniques.^[11] Though USP is still considered the gold standard, it is a contact type pachymetry, and there is an associated increased risk of corneal injury and infections.^[12] A PubMed search did not reveal any studies that have measured the CCT with a hand-held spectral-domain OCT (HHSD-OCT, Biotigen Inc., Durham, North Carolina, USA) or Pentacam (Oculus Optikgerate GmbH, Wetzlar, Germany) in established keratoconus. Since these instruments are currently available for clinical use, it is important to know if the pachymetry values generated by the newer techniques are comparable to the others that are being used for years.

Hence, we conducted a prospective observational study to compare the pachymetry values obtained using a swept source OCT (SS-OCT, Casia SS-1000°CT, Tomey, Nagoya, Japan), Pentacam, Orbscan IIz and HHSD-OCT in established keratoconus to evaluate the repeatability and agreement between them.

Materials and Methods

In this prospective, observational, comparative study, consecutive patients with established keratoconus were

This is an open access article distributed under the terms of the Creative Commons Attribution-NonCommercial-ShareAlike 3.0 License, which allows others to remix, tweak, and build upon the work non-commercially, as long as the author is credited and the new creations are licensed under the identical terms.

For reprints contact: reprints@medknow.com

Cite this article as: Kumar M, Shetty R, Jayadev C, Dutta D. Comparability and repeatability of pachymetry in keratoconus using four noncontact techniques. Indian J Ophthalmol 2015;63:722-7.

Access this article online

Website:
www.ijo.in

DOI:
10.4103/0301-4738.170987

Quick Response Code:



Department of Cornea and Refractive Surgery, Narayana Nethralaya Super Specialty Eye Hospital, Bengaluru, Karnataka, India, ¹School of Optometry and Vision Science, The University of New Wales, Sydney, New South Wales, Australia

Correspondence to: Mr. Mukesh Kumar, Narayana Nethralaya, 121/C, Chord Road, 1st "R" Block, Rajaji Nagar, Bengaluru - 560 010, Karnataka, India. E-mail: mukesh.opt@gmail.com

Manuscript received: 08.01.15; **Revision accepted:** 12.11.15

enrolled from the cornea clinic of a tertiary care eye hospital in India. The initial diagnosis of keratoconus was based on the presence of a characteristic elevation on corneal topography (i.e. central or paracentral steepening) with a simulated keratometric reading of more than 48.6 diopter (D) and one or more of the following slit lamp findings: Central or paracentral thinning, anterior bulging or conicity, hemosiderin deposition (Fleischer's ring), stromal striae (Vogt's striae), Descemet's membrane breaks, and apical scars. Eyes with previous acute corneal hydrops or a history of corneal surgery were excluded from the study. The study adhered to the tenets of the Declaration of Helsinki and was approved by the Institutional Review Board; all participants provided a written informed consent. All subjects underwent comprehensive ophthalmic examination including visual acuity measurement using the Snellen's chart, intraocular pressure measurement using a noncontact tonometer (Topcon CT80, Japan), slit lamp biomicroscopy, and dilated fundus evaluation.

For each patient, three consecutive measurements by SS-OCT, Pentacam, Orbscan IIz topography, and HHSD-OCT were performed by a single examiner. To minimize any diurnal variation, measurements were done only at 11 a.m. ± 1 h and at the same sitting.

Instrumentation

Pentacam

Pentacam uses a rotating Scheimpflug camera and a monochromatic slit light source that rotate together around the optical axes of the eye to obtain a three-dimensional model of the AS.^[13] It takes a few seconds to generate an image and data on topography, CCT, corneal curvature, anterior chamber angle, depth, and volume are calculated from up to 25,000 data points.

Orbscan IIz

Orbscan IIz produces multiple slit lamp images of the AS using a horizontally moving camera.^[14,15] CCT is calculated from the difference in the elevation between the anterior and posterior surfaces. Positioning of the patient and fixation of the eye are similar to that used during Pentacam measurements.

Hand-held spectral domain optical coherence tomography

The Bioptigen HHSD-OCT imaging system is capable of acquiring a series of 100 horizontal spectral domain OCT images, each containing 1000 A-scans, in under 6 s.^[16] The distance between the scans is approximately 80–100 μm , and the axial resolution is about <5 μm . This image acquisition rate results in a reduction of motion artefacts. For this study, we used a standard, commercially available HHSD-OCT device, originally designed to measure retinal thickness. We demonstrate the applicability of this HHSD-OCT to perform imaging studies on the cornea and to measure the CCT. Since, this is a hand-held OCT, subjects were asked to fixate at a distance target with fellow eye and Bioptigen HHSD-OCT was held perpendicular to the corneal surface with the central grid aligned with the middle of limbus-to-limbus diameter. In addition, to confirm good centration scans were aligned to visual axis and adjusted to be on the geometrical axis of the eye.

Swept source optical coherence tomography

SS-AS-OCT was performed using a Fourier-domain OCT system. A swept laser source operating at 1310 nm wavelength

can achieve an axial resolution of 10 μm or less and a transverse resolution of 30 μm or less and provide 30 000 axial scans (A-scans) per second.^[17,18] The software automatically analyzes the recorded images and provides various corneal maps, as well as a quantitative and qualitative AS evaluation. To achieve good centration, all scans were aligned on its visual axis and then adjusted to be on the geometrical axis according to the manufacturer's guidelines.

Statistical analysis

Statistical Package for Social Sciences (SPSS) version 17.0 (SPSS, Inc., Chicago, IL, USA) was used for analysis of data. Normality of data was confirmed using the Kolmogorov–Smirnov test and graphical methods. A $P < 0.05$ was considered statistically significant. One-way analysis of variance for repeated measurements was used to compare CCT values obtained using the four different methods. Correlations between measurement methods were examined using the Pearson's correlation analysis. For device pairs, descriptive variables reflecting the level of agreement were calculated, including mean paired difference, maximum difference, median absolute difference, and 95% limits of agreement (LOA = mean \pm 1.96 standard deviation [SD]). In addition, Bland–Altman plots were drawn, in which agreements of the methods were graphically represented in terms of 95% LOA estimated by mean difference \pm 1.96 SD of the differences. Test-retest reliability (repeatability) was evaluated using the Pearson's correlation analysis and through comparison of mean values obtained at each acquisition using the one-way analysis of variance for repeated measurements and the Student's *t*-test for paired samples was used for pairwise comparisons.

Results

Fifty eyes of 25 subjects were included in the study. The mean age of the subjects was 20.4 ± 4.5 years (range: 10–28 years). Sixteen were male, and nine were female.

Comparison of different pachymetry methods

Agreement between all the device pairs were highly significant with correlation coefficients of 0.99 between Orbscan IIz and Pentacam, 0.986 between Orbscan IIz and SS-OCT, 0.98 between Orbscan IIz and HHSD-OCT, 0.989 between SSOCT and Pentacam, 0.98 between HHSD-OCT and Pentacam, and 0.979 between SS-OCT and HHSD-OCT ($P < 0.001$ for all comparisons).

The pairwise comparison revealed that HHSD-OCT gave significantly higher values and thus overestimated CCT compared to the other instruments ($P < 0.001$). Fig. 1 shows the Bland–Altman plots for the agreement between SSOCT, Pentacam, Orbscan IIz, and HHSD-OCT for CCT measurements in keratoconus eyes.

Orbscan IIz and Pentacam measurements displayed the smallest range of LOA (20.8 μm), whereas SSOCT and HHSD-OCT displayed the widest range (34 μm). The median absolute difference was smallest between Orbscan IIz and SS-OCT measurements (0.7 μm). Table 1 gives the parameters related to the agreement of the methods.

The slopes of the regression lines were not significantly different from zero in none of the device pairs, indicating

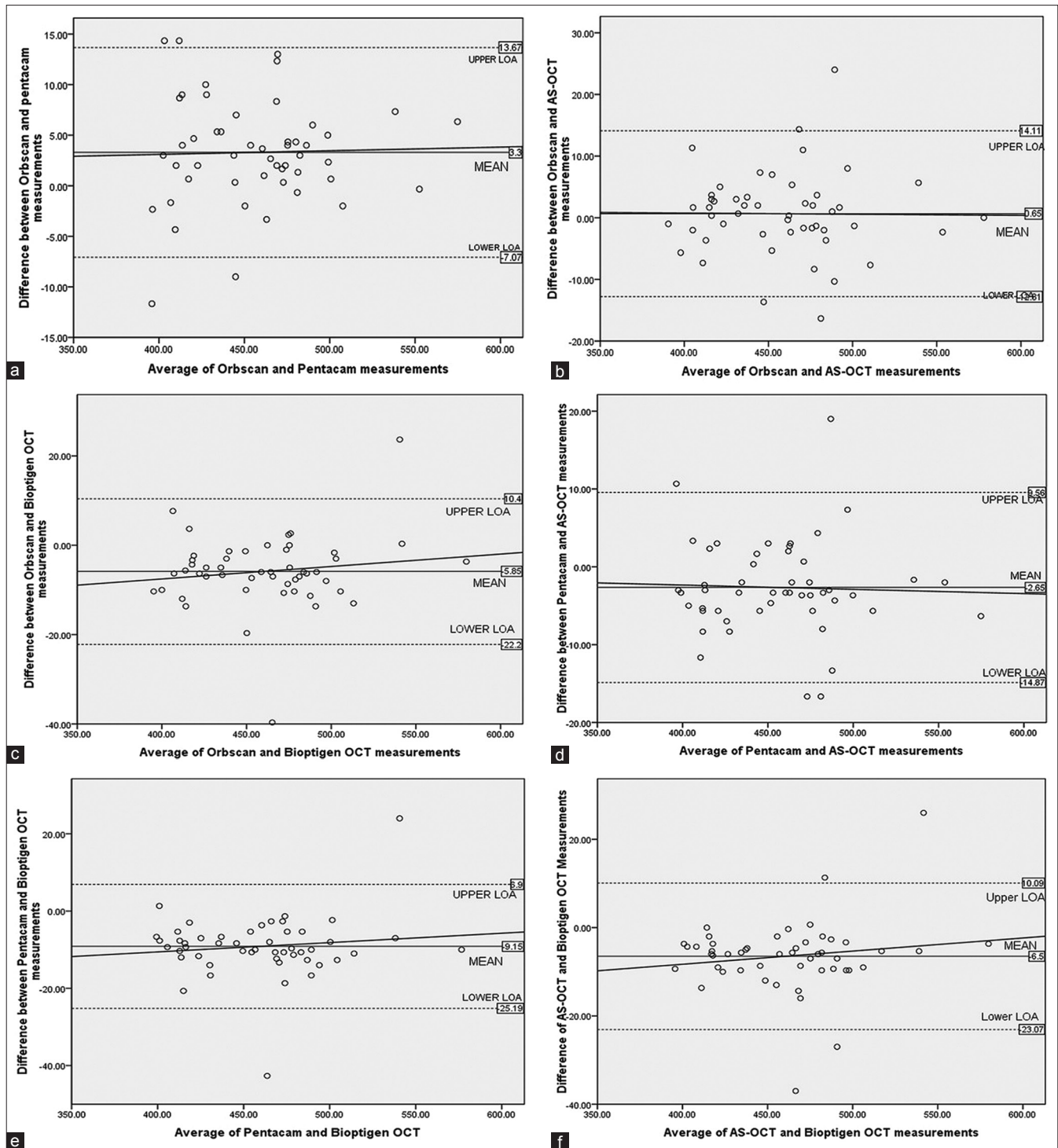


Figure 1: (a-f) Bland-Altman plots comparing central corneal thickness measurements with two different methods. Upper and lower limits of agreement lines denote 95% limits of agreement

that there was no bias. Thus, the magnitudes of the differences were similar at different degrees of corneal thickness.

Test-retest variability of the measurements

For SS-OCT, HHSD-OCT, Pentacam, and Orbscan IIz, there was a high level of agreement between the first and consecutive measurements with correlation coefficients ranging between

0.99 and 0.93 ($P < 0.001$ for all correlations), confirming the repeatability of the results [Table 2].

Discussion

In this study, we compared CCT measurements obtained using HHSD-OCT, Pentacam, Orbscan IIz, and SS-OCT. Numerous studies have demonstrated that the CCT measurement in

normal eyes was comparable between USP and Orbscan IIz when the appropriate correction factor was used.^[19-22] However, this is the first study to evaluate the precision of CCT measurements with four different systems including the Pentacam, HHSD-OCT, Orbscan IIz, and SS-OCT in keratoconic eyes. The most significant finding of this study is that CCT was over-estimated by the HHSD-OCT in keratoconus by an average of 6 µm when compared to Orbscan IIz. The CCT values of Orbscan IIz, Pentacam, and SS-OCT correlated well numerically but had a high magnitude of difference.

Grewal *et al.*^[23] compared the CCT finding of Pentacam and AS-OCT measurements in keratoconic eyes. They found

that AS-OCT measured significantly higher readings than the Pentacam with a mean difference of 2 µm. In contrast to this, our study found that the CCT measured by SS-OCT was overestimated by 7 µm when compared to the Pentacam. Uçakhan *et al.*^[24] in their study also found that the mean CCT in keratoconic eyes as measured with Pentacam was underestimated by 6 µm as compared to measurements with USP. The tendency of the Pentacam to underestimate the mean CCT in normal corneas has also been reported.^[25]

Our study found that Orbscan IIz (acoustic factor corrected) significantly overestimated CCT by an average of 21 µm in contrast to the previous study.^[11] However, Dutta *et al.*^[11] compared Orbscan IIz findings with USP, which is a contact method. Whereas, another study has reported that Orbscan IIz measurement of CCT was significantly lower in keratoconic eyes than those obtained by USP.^[26] In this study, we did not find any significant difference in the CCT in keratoconic eyes using the SS-OCT and Orbscan IIz. In contrast, Jhanji *et al.*^[27] reported that in 46 keratoconic eyes, the difference in CCT was 21 µm and 19 µm with Orbscan IIz and SS-OCT, respectively, which is much higher compared to our result. This difference could be because corneal elevation data is obtained in Orbscan using algorithms which use lower order polynomials, and this excludes small irregularities on the corneal surface. An acoustic equivalent correction factor of 0.92 was obtained when Orbscan measurements were calibrated in the normal population. However, such algorithms may not apply to abnormal corneas such as keratoconus and postrefractive surgery.^[28]

The clarity of the cornea is an important factor while obtaining accurate measurements using Orbscan as the measurements are based on the reflected light beam from the corneal surface. When the corneal medium is not clear, the pathway of the light rays may be interrupted.^[29] Fakhry *et al.*^[30] in their study reported that Orbscan IIz gives accurate CCT measurements in normal eyes with results similar to those of USP, but in cases with stromal/epithelial haze after photorefractive keratectomy, the USP readings were more accurate as compared to those from the Orbscan. Alteration of the regular arrangement of collagen fibrils,^[31] elongated epithelial cells in the corneal apex,^[32] and changes in reflectivity of the anterior stroma^[33] have all been documented in keratoconic eyes. These anatomic changes may affect the optical clarity as well as the measurement accuracy for CCT when compared to the healthy cornea. Kim *et al.*^[34] demonstrated no significant difference between Pentacam and Orbscan measurement of CCT, although they found a tendency of the Orbscan to underestimate CCT measurement, especially for measurements <450 µm. Contrary to this, in our study we found that the Orbscan IIz overestimated the CCT by an average of 4 µm. Several other studies have shown lower CCT measurements with AS-OCT when compared to Pentacam or Orbscan.^[35] In our study, HHSD-OCT gave significantly higher CCT readings compared to the other instruments. The CCT measurement using OCT has the advantage of measuring the true corneal thickness from the anatomic anterior to the posterior corneal surface. However, as the measurements are done manually using callipers, small errors in placement of callipers may lead to large differences in the readings. There may be an interobserver error in pinpointing the exact location of the center of the cornea leading to a decrease in the accuracy of measurement.

Table 1: Pairwise comparisons of the CCT measurement acquired by four different devices

	Mean paired difference with±SD	Maximum difference	Median absolute difference
Orbscan IIz versus Pentacam	3.3±5.2	14.3	4
Orbscan IIz versus SS-OCT	0.7±6.7	24	0
Orbscan IIz versus Biotigen	-5.9±8.1	-39.6	-6
Pentacam versus SS-OCT	-2.7±6.1	19	-4
Pentacam versus Biotigen	-9.2±8.0	-42.67	-10
SS-OCT versus Biotigen	-6.5±8.3	-37	-6

SD: Standard deviation, SS-OCT: Swept source optical coherence tomography, CCT: Central corneal thickness

Table 2: CCT statistics for the four instruments in central cornea

Instruments	CCT mean±SD	P analysis of variance ^a	Correlation ^b	ICC
Orbscan IIz				
1	459.4±39.5	0.634	-	0.9922
2	456.2±41.6		r=0.972 (P<0.001)	
3	458.2±41.2		r=0.984 (P<0.001)	
Pentacam				
1	454.1±40.1	0.645	-	0.9984
2	455.2±40.3		r=0.996 (P<0.001)	
3	454.6±40.8		r=0.994 (P<0.001)	
SS-OCT				
1	454.9±40.8	0.628	-	0.9987
2	457.5±40.4		r=0.999 (P<0.001)	
3	459.4±40.5		r=0.998 (P<0.001)	
Biotigen				
1	462.7±41.3	0.367	-	0.9837
2	465.3±41.0		r=0.999 (P<0.001)	
3	463.3±37.7		r=0.931 (P<0.001)	

^aAnalysis of variance for repeated measurement, ^bVersus first acquisition. ICC: Interclass correlation coefficient (P) Pearson correlation coefficient. CCT: Central corneal thickness, SD: Standard deviation, SS-OCT: Swept source optical coherence tomography

This study found that the HHSD-OCT, Orbscan IIz, Pentacam, and SS-OCT have highly repeatable measurements of the CCT in keratoconic eyes. High repeatability in keratoconic eyes, with an interclass correlation coefficient (ICC) of 0.980 and 0.963 has also been reported by Szalai *et al.*^[36] Our results showed a similar intraobserver repeatability (ICC = 0.998, 0.998, 0.9922, and 0.9837) for CCT measurements by Pentacam, SS-OCT, Orbscan IIz, and HHSD-OCT in keratoconic eyes.

Although there have been multiple studies that have studied the comparability of CCT measurements by different instruments, this is the first study to use the HHSD-OCT for pachymetry measurement in keratoconic eyes and compare it to three other instruments.

The limitations of this study are: First, all the measurements were done by a single examiner; even though this eliminated the risk of interobserver error, it may contribute to a bias in readings. Second, the pachymetry was measured at the center of the cornea and not at the thinnest point which may have been away from the center since the thinnest point could not be precisely marked with the OCT devices. Third, the sample size was relatively small and lastly we did not compare our measurements to USP, which is considered the gold standard for measurement of the CCT.

Conclusion

There was a significant difference in the measurements derived from the four devices and hence they cannot be used interchangeably for CCT measurements in keratoconus patients. Further studies which compare the HHSD-OCT to USP in normal eyes may validate the usefulness and reliability of this instrument for the measurement of CCT.

Financial support and sponsorship

Nil.

Conflicts of interest

There are no conflicts of interest.

References

- Krachmer JH, Feder RS, Belin MW. Keratoconus and related noninflammatory corneal thinning disorders. *Surv Ophthalmol* 1984;28:293-322.
- Gromacki SJ, Barr JT. Central and peripheral corneal thickness in keratoconus and normal patient groups. *Optom Vis Sci* 1994;71:437-41.
- Pflugfelder SC, Liu Z, Feuer W, Verm A. Corneal thickness indices discriminate between keratoconus and contact lens-induced corneal thinning. *Ophthalmology* 2002;109:2336-41.
- Colin J, Cochener B, Savary G, Malet F. Correcting keratoconus with intracorneal rings. *J Cataract Refract Surg* 2000;26:1117-22.
- Colin J, Cochener B, Savary G, Malet F, Holmes-Higgin D. INTACS inserts for treating keratoconus: One-year results. *Ophthalmology* 2001;108:1409-14.
- Siganos CS, Kymionis GD, Kartakis N, Theodorakis MA, Astryrakakis N, Pallikaris IG. Management of keratoconus with Intacs. *Am J Ophthalmol* 2003;135:64-70.
- Boxer Wachler BS, Christie JP, Chandra NS, Chou B, Korn T, Nepomuceno R. Intacs for keratoconus. *Ophthalmology* 2003;110:1031-40.
- Colin J, Velou S. Implantation of Intacs and a refractive intraocular lens to correct keratoconus. *J Cataract Refract Surg* 2003;29:832-4.
- Snibson GR. Collagen cross-linking: A new treatment paradigm in corneal disease – A review. *Clin Experiment Ophthalmol* 2010;38:141-53.
- Manche EE, Holland GN, Maloney RK. Deep lamellar keratoplasty using viscoelastic dissection. *Arch Ophthalmol* 1999;117:1561-5.
- Dutta D, Rao HL, Addepalli UK, Vaddavalli PK. Corneal thickness in keratoconus: Comparing optical, ultrasound, and optical coherence tomography pachymetry. *Ophthalmology* 2013;120:457-63.
- Buehl W, Stojanac D, Sacu S, Drexler W, Findl O. Comparison of three methods of measuring corneal thickness and anterior chamber depth. *Am J Ophthalmol* 2006;141:7-12.
- Oliveira CM, Ribeiro C, Franco S. Corneal imaging with slit-scanning and Scheimpflug imaging techniques. *Clin Exp Optom* 2011;94:33-42.
- Cairns G, McGhee CN. Orbscan computerized topography: Attributes, applications, and limitations. *J Cataract Refract Surg* 2005;31:205-20.
- Liu Z, Huang AJ, Pflugfelder SC. Evaluation of corneal thickness and topography in normal eyes using the Orbscan corneal topography system. *Br J Ophthalmol* 1999;83:774-8.
- Rootman DB, Gonzalez E, Mallipatna A, Vandenhoven C, Hampton L, Dimaras H, *et al.* Hand-held high-resolution spectral domain optical coherence tomography in retinoblastoma: Clinical and morphologic considerations. *Br J Ophthalmol* 2013;97:59-65.
- Wylegala E, Teper S, Nowinska AK, Milka M, Dobrowolski D. Anterior segment imaging: Fourier-domain optical coherence tomography versus time-domain optical coherence tomography. *J Cataract Refract Surg* 2009;35:1410-4.
- Yasuno Y, Madjarova VD, Makita S, Akiba M, Morosawa A, Chong C, *et al.* Three-dimensional and high-speed swept-source optical coherence tomography for *in vivo* investigation of human anterior eye segments. *Opt Express* 2005;13:10652-64.
- Fukuda S, Kawana K, Yasuno Y, Oshika T. Anterior ocular biometry using 3-dimensional optical coherence tomography. *Ophthalmology* 2009;116:882-9.
- Amano S, Honda N, Amano Y, Yamagami S, Miyai T, Samejima T, *et al.* Comparison of central corneal thickness measurements by rotating Scheimpflug camera, ultrasonic pachymetry, and scanning-slit corneal topography. *Ophthalmology* 2006;113:937-41.
- Prospero Ponce CM, Rocha KM, Smith SD, Krueger RR. Central and peripheral corneal thickness measured with optical coherence tomography, Scheimpflug imaging, and ultrasound pachymetry in normal, keratoconus-suspect, and post-laser *in situ* keratomileusis eyes. *J Cataract Refract Surg* 2009;35:1055-62.
- Fujioka M, Nakamura M, Tatsumi Y, Kusuhara A, Maeda H, Negi A. Comparison of Pentacam Scheimpflug camera with ultrasound pachymetry and noncontact specular microscopy in measuring central corneal thickness. *Curr Eye Res* 2007;32:89-94.
- Grewal DS, Brar GS, Grewal SP. Assessment of central corneal thickness in normal, keratoconus, and post-laser *in situ* keratomileusis eyes using Scheimpflug imaging, spectral domain optical coherence tomography, and ultrasound pachymetry. *J Cataract Refract Surg* 2010;36:954-64.
- Uçakhan OO, Ozkan M, Kanpolat A. Corneal thickness measurements in normal and keratoconic eyes: Pentacam comprehensive eye scanner versus noncontact specular microscopy and ultrasound pachymetry. *J Cataract Refract Surg* 2006;32:970-7.
- O'Donnell C, Maldonado-Codina C. Agreement and repeatability of central thickness measurement in normal corneas using ultrasound pachymetry and the OCULUS Pentacam. *Cornea*

- 2005;24:920-4.
26. Gherghel D, Hosking SL, Mantry S, Banerjee S, Naroo SA, Shah S. Corneal pachymetry in normal and keratoconic eyes: Orbscan II versus ultrasound. *J Cataract Refract Surg* 2004;30:1272-7.
 27. Jhanji V, Yang B, Yu M, Ye C, Leung CK. Corneal thickness and elevation measurements using swept-source optical coherence tomography and slit scanning topography in normal and keratoconic eyes. *Clin Experiment Ophthalmol* 2013;41:735-45.
 28. Rainer G, Findl O, Petternel V, Kiss B, Drexler W, Skorpik C, *et al.* Central corneal thickness measurements with partial coherence interferometry, ultrasound, and the Orbscan system. *Ophthalmology* 2004;111:875-9.
 29. Iskander NG, Anderson Penno E, Peters NT, Gimbel HV, Ferenowicz M. Accuracy of Orbscan pachymetry measurements and DHG ultrasound pachymetry in primary laser *in situ* keratomileusis and LASIK enhancement procedures. *J Cataract Refract Surg* 2001;27:681-5.
 30. Fakhry MA, Artola A, Belda JI, Ayala MJ, Alió JL. Comparison of corneal pachymetry using ultrasound and Orbscan II. *J Cataract Refract Surg* 2002;28:248-52.
 31. Daxer A, Fratzl P. Collagen fibril orientation in the human corneal stroma and its implication in keratoconus. *Invest Ophthalmol Vis Sci* 1997;38:121-9.
 32. Somodi S, Hahnel C, Slowik C, Richter A, Weiss DG, Guthoff R. Confocal *in vivo* microscopy and confocal laser-scanning fluorescence microscopy in keratoconus. *Ger J Ophthalmol* 1996;5:518-25.
 33. Suzuki S, Oshika T, Oki K, Sakabe I, Iwase A, Amano S, *et al.* Corneal thickness measurements: Scanning-slit corneal topography and noncontact specular microscopy versus ultrasonic pachymetry. *J Cataract Refract Surg* 2003;29:1313-8.
 34. Kim SW, Byun YJ, Kim EK, Kim TI. Central corneal thickness measurements in unoperated eyes and eyes after PRK for myopia using Pentacam, Orbscan II, and ultrasonic pachymetry. *J Refract Surg* 2007;23:888-94.
 35. Li EY, Mohamed S, Leung CK, Rao SK, Cheng AC, Cheung CY, *et al.* Agreement among 3 methods to measure corneal thickness: Ultrasound pachymetry, Orbscan II, and Visante anterior segment optical coherence tomography. *Ophthalmology* 2007;114:1842-7.
 36. Szalai E, Berta A, Hassan Z, Módos L Jr. Reliability and repeatability of swept-source Fourier-domain optical coherence tomography and Scheimpflug imaging in keratoconus. *J Cataract Refract Surg* 2012;38:485-94.