

Dystopic Os Odontoideum Causing Cervical Myelopathy: A Rare Case Report and Review of Literature

Abstract

Os odontoideum (OO) was first described by Giacomini in 1886 as separation of the odontoid process from the body of the axis. Instability can consequently occur at this level due to the failure of the transverse atlantal ligament (TAL) and this atlantoaxial instability can be a cause of progressive neurological deficits. It is considered a rare anomaly of the odontoid process. It is a disease with controversial etiology, debatable incidence, and only a partly known natural history owing to the paucity of the literature on this topic. There are insufficient demographic data about the occurrence of the disease, and most of the management is dictated by the isolated case reports and few studies which have been carried out at handful of institutes. OO is classified into two types by Fielding *et al.* based on the anatomic location: orthotopic and dystopic. Orthotopic OO consists of an ossicle that moves with the anterior arch of the atlas, whereas the dystopic type presents as an ossicle near the basion or one that is fused with the clivus. In one magnetic resonance imaging (MRI) study of odontoid morphology, a 0.7% (1 case of 133 patients) incidence was reported. The spectrum of the clinical presentation varies from completely asymptomatic individuals to patients presenting with features of cervical myelopathy. Here, we present a case of 35-year-old-male with dystopic OO who presented to us with features of gradually progressing cervical myelopathy without any obvious history of neck trauma. On investigations, he was found to have atlantoaxial instability with wide atlanto-dens interval. He was treated with the posterior C1-C2 stabilization and reduction of atlantoaxial instability.

Keywords: Cervical, dystopic, myelopathy, Os odontoideum

**Aditya Raj,
Sudhir Kumar
Srivastava,
Nandan Marathe,
Sunil Bhosale,
Shaligram Purohit**

*Department of Orthopaedics,
Seth GS Medical College and
KEM Hospital, Parel, Mumbai,
Maharashtra, India*

Case Report

A 25-year-old male presented to us with insidious onset of difficulty in walking and instability while walking later associated with handgrip weakness of 1-year duration which was gradually progressive. He could not recollect any history of previous trauma or fall or any history of previous neck pain. He had difficulty in carrying out routine activities of daily living which was also affecting his employment. He had no other comorbidities. On examination was found to have signs of cervical myelopathy with severe wasting of thenar and hypothenar muscles. His gait was wide-based, spastic, and unsteady. His left upper and lower extremities had muscle weakness of Grade 3 or 4 of 5. He had symmetrical hyperreflexia, as well as positive Hoffmann and Babinski signs bilaterally. He was Nurick Grade 3 at the presentation and modified Japanese Orthopedic Association (mJOA) score of ten

with sensory deficits in the upper limb and no micturition difficulty. Plain radiographic assessment was suggestive of atlantoaxial instability with an increased atlantodens interval [Figure 1]. Computed topographic scans (CT) were also done which confirmed the atlantoaxial instability with the presence of a dystopic OO near the basion but not fused to the clivus [Figures 2 and 3]. MRI scans were carried out which were suggestive of mechanical cord compression and cervical myelopathy [Figure 4]. Dynamic lateral neck radiographs were suggestive of the partial reduction of the atlantoaxial instability. Other serological investigations were unremarkable.

After confirmation of the diagnosis of dystopic OO, posterior instrumentation in the form of C1 lateral mass screws and C2 pedicle screws were planned. To achieve appropriate atlantoaxial reduction and stability special polyaxial screws of 4-mm diameter with reduction tabs (similar

Address for correspondence:

*Dr. Aditya Raj,
6th Floor, Orthopedics Office
Multi Storey New Building,
Seth GS Medical College
and KEM Hospital, Parel,
Mumbai, Maharashtra, India.
E-mail: adityagmck@gmail.com*

Access this article online

Website: www.asianjns.org

DOI: 10.4103/ajns.AJNS_35_19

Quick Response Code:



This is an open access journal, and articles are distributed under the terms of the Creative Commons Attribution-NonCommercial-ShareAlike 4.0 License, which allows others to remix, tweak, and build upon the work non-commercially, as long as appropriate credit is given and the new creations are licensed under the identical terms.

For reprints contact: reprints@medknow.com

How to cite this article: Raj A, Srivastava SK, Marathe N, Bhosale S, Purohit S. Dystopic Os odontoideum causing cervical myelopathy: A rare case report and review of literature. Asian J Neurosurg 2020;15:236-40.

Submission: 07-02-2019 **Accepted:** 10-01-2020
Published: 25-02-2020

to the ones found in reduction pedicle screws) were used. Posterior stabilization was performed with the standard midline approach and necessary instrumentation performed with the screw and rod construct [Figures 5 and 6]. This was followed by excision of the posterior arch of atlas. We have used autologous iliac crest cancellous graft retrieved from the posterior iliac crest and put in the atlantoaxial joints posteriorly after instrumentation to achieve bony fusion. Postoperative CT scans were suggestive of adequate stabilization and reduction of atlanto-dens interval along with maintenance of the clivus canal angle [Figure 7]. Postoperatively, patient had an uneventful outcome and was mobilized with the help of philadelphia collar. At 14-months follow-up patient had reduced spasticity along with improved mJOA score of 16 as compared to preoperative score of 10.

Discussion

OO is a rare disorder of the odontoid process of C2 vertebra as described by Giacomini.^[1] It is defined radiographically as an oval or round-shaped ossicle that has no continuity with the body of C2. It has smooth circumferential cortical

margins representing the remnants of odontoid process. Fielding *et al*^[2] have classified it into two types based on anatomic location: Orthotopic and dystopic. It is usually found on in asymptomatic individuals with an estimated prevalence of 0.7%,^[3] but fulminant myelopathy is also described secondary to minor trauma. The TAL functions by restraining atlantoaxial motion. In OO, there is failure of this ligament secondary to the loss of bony support by the odontoid process. This becomes important as the person then suffers from mobile or insufficient dens, and it may cause translation of the atlas on the axis and may compress the cervical cord or vertebral arteries.^[4] The exact etiology still remains obscure because those malformations mostly are incidentally detected in asymptomatic patients or are diagnosed only when patients become symptomatic. There are several reports of patients with OO becoming quadriparetic after minor trauma.^[5] Although OO is a rare condition, its exact frequency remains unknown since no large-scale screening studies have been performed. Nevertheless, in a study made by Perdikakis

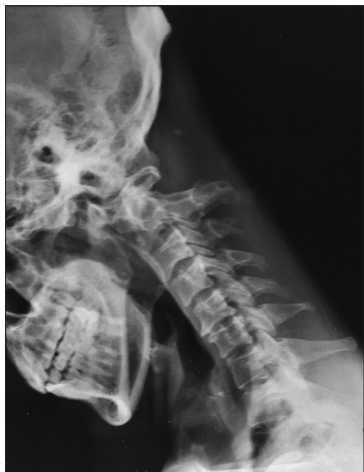

Figure 1: Increased atlanto dens interval

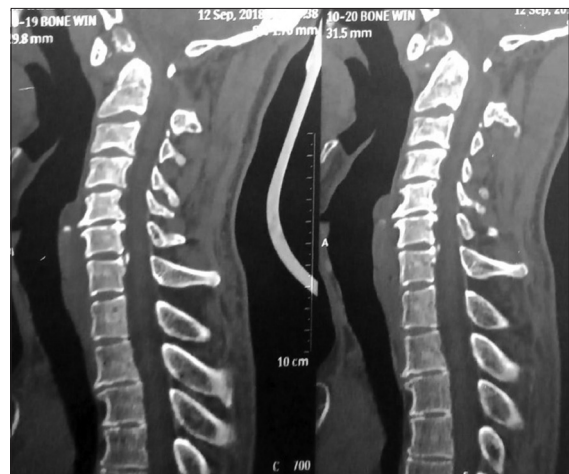


Figure 2: Sagittal computed tomographic scan demonstrating dystopic Os odontoideum

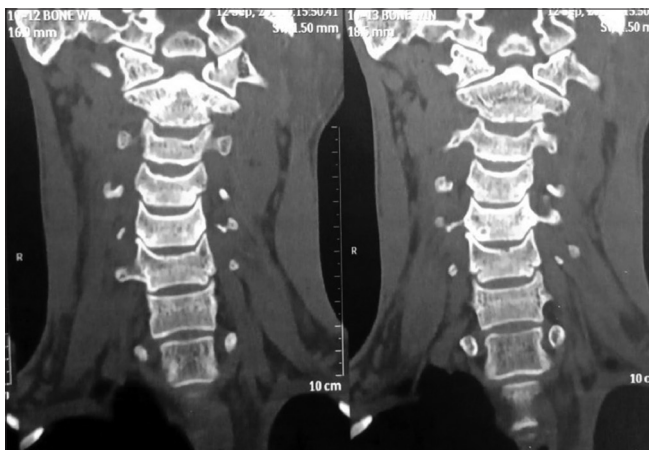


Figure 3: Coronal computed tomographic scan demonstrating dystopic

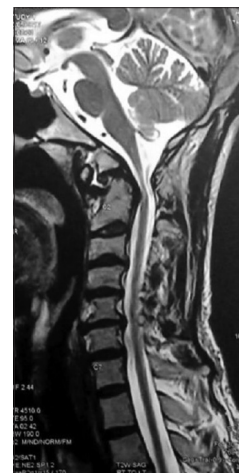

Figure 4: Sagittal T2-weighted magnetic resonance imaging scan showing cervical cord compression secondary to Os odontoideum

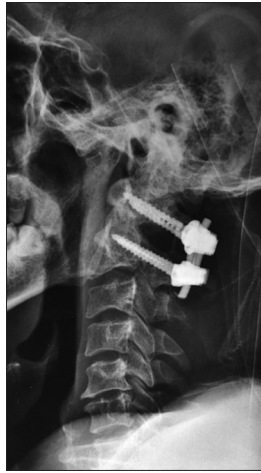

Figure 5: Postoperative plain roentgenogram demonstrating atlanto-axial stabilization and restored atlanto dens interval

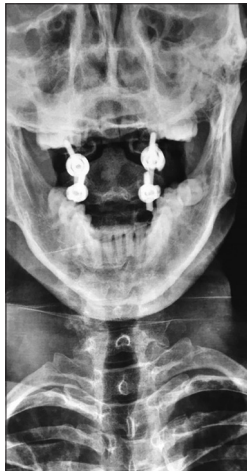

Figure 6: Postoperative anteroposterior roentgenogram demonstrating atlanto-axial stabilization

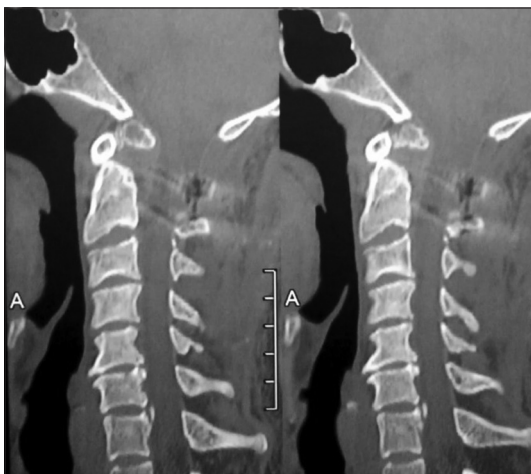

Figure 7: Postoperative computed tomographic scan suggestive of adequate stabilization and reduction of atlanto dens interval along with the maintenance of clivus canal angle

and Skoulikaris^[3] they described the MR appearance of the odontoid process and calculated the prevalence of its

morphological variants. They retrospectively reviewed 133 patients, age range between 19 and 81 years, which were examined within a period of 7 years and found OO in only one case (0.7%) whereas Sankar *et al.*^[6] in their study detected it in 3.1% of children with abnormal cervical radiographs. This lesion usually presents clinically in the pediatric population; moreover, most authors today believe it might represent an unrecognized fracture or damage to the epiphyseal plate during the first few years of life.^[7] Some believe that it may represent a congenital anomaly instead of occult trauma. During the embryological development, part of the odontoid process is derived from the fourth occipital sclerotome giving rise to the apex of the odontoid, which is called the ossiculum terminale or the apical odontoid epiphysis. The first and second cervical sclerotomes are the ones which contribute to the odontoid and axis bodies. The odontoid usually has an epiphyseal growth plate, which separates the first and second cervical sclerotomes, and it is frequently known as the neurocentral synchondrosis. This structure lies below the level of the superior articular facets of the axis and is usually visible in children younger than 3 or 4 years but disappears by 8 years of age. The odontoid process carries a unique blood supply because of its dependence from the terminal apical arcade for the majority of the vasculature. This anastomoses with the caudal supply from the deep penetrating branches arising off the posterior ascending arteries which in turn comes from the vertebral artery. This also provides an explanation for the increased risk of ischemia due to the precarious blood supply of the odontoid process. Since no vessels pass through the transient epiphyseal plate between the odontoid process and the axis, this arterial apparatus is extremely crucial early in life. The relatively fixed position of the dens as the atlas rotates provides insufficient vascularization by the anterior and posterior branches of the vertebral arteries. Consequently, there is a great dependence of odontoid process on a terminal descending supply superiorly (the apical arcade). This apparent vascular insufficiency of the odontoid blood supply predisposes it particularly vulnerable to ischemia and necrosis, especially in traumatic events. Moreover, the blood vessels traverse closely alongside the odontoid process; hence, the blood supply of the odontoid process may be unstable because it can be easily obstructed. It is hypothesized that such an obstruction might lead to ischemia which consequently might contribute to poor fracture healing and callus formation. It is associated with many congenital malformations such as Morquio's disease,^[8] the Klippel-Feil syndrome,^[9] multiple epiphyseal dysplasia,^[8] achondroplasia,^[10] the Larsen syndrome,^[11] the Wolcott-Rallison syndrome,^[12] and chondrodystrophia calcificans. The other hypothesis for development of OO is originated mainly from the work of Fielding and Griffin which is the posttraumatic or acquired hypothesis. They have concluded that OO forms after an unrecognized fracture to the odontoid with the subsequent contraction

of the apical and alar ligaments, the distraction of the fractured fragment, and the abrupt termination of blood supply, leading to the formation of an ossicle. This is also supported by the fact that OO is most commonly located at the base of the dens and not at the synchondrosis where a fusion failure is expected, as reported in other studies. There at times can be multiple ossicles instead of a single-ossicle. Several other studies have supported the posttraumatic etiology.^[13,14]

Most patients have their first onset of symptoms in childhood with neck pain or neurologic symptoms due to cord compression from the posterior translation of the Os into the cord in extension or the odontoid into the cord in flexion. There is, however, another group of patients presenting in adulthood with symptoms of cervical myelopathy secondary to mechanical cord compression often secondary to minor trauma which cannot be recollected. Increased motion at the C-1 to C-2 level can lead to symptoms of central cord syndrome, Brown-Sequard syndrome, hypoventilation syndrome (Ondine's curse), and cardiorespiratory failure in severe cases. In extremely rare scenarios it can also cause cerebellar infarction secondary to mechanical effects of compression leading to embolization.^[15] The presence of atlanto-axial instability in adults is usually a result of traumatic ligamentous rupture and consequent instability and as a result of rheumatoid arthritis. The presence of basilar invagination and syringomyelia together with atlanto axial instability typically leads to a diagnosis of Chiari malformations which should also be kept in mind while investigating such patients. The diagnosis of OO is primarily radiographic. It can be clearly visualized using plain radiographs with the open mouth, anteroposterior, and lateral views. In the lateral radiographs dynamic views performed in flexion and extension should be done for further evaluation of atlanto-axial instability and reducibility. Although quite useful in diagnosis, the exact sensitivity and specificity of standard plain radiographs in diagnosing OO have not been studied.^[15] For a detailed anatomical analysis CT scans and MRI scans are important for a better illustration of osseous abnormalities and spinal cord compression and pathology, respectively. Addition of CT angiography to these studies is important to look for vertebral artery position and anomalies which can be commonly found with syndromic patients. It is important both for diagnosis and further surgical planning which is frequently a posterior approach.^[16] Furthermore, Hughes *et al.* recommended the use of kinematic MRI in diagnosing OO, given the advantage of directly visualizing the motions of joint components and the surrounding soft tissues.^[17] However, an initial examination of patients with myelopathy using a conventional MRI scan can occasionally lead to a misdiagnosis of an intramedullary spinal cord tumor in cases of chronic cervical spine instability secondary to OO.

The management of symptomatic OO is usually a well-defined surgical indication in terms of instrumented

stabilization and C1 C2 fusion. Due to paucity of literature regarding the natural history of untreated OO, the course of treatment for asymptomatic individuals with incidentally detected OO is still debatable. There have been reports of conservative management and close observation as reported by Dai *et al.* who have reported that at 1-year follow-up it remained stable. However, some authors^[18] believe that all asymptomatic patients even those with a "stable" OO, should undergo C1-C2 fusion to avert any neurological complications. This is also better appreciated when we consider reports in the literature on sudden death,^[19] significant neurological complications^[8] following minor injuries in previously undiagnosed OO, and patients who suffer late neurological deterioration.

Declaration of patient consent

The authors certify that they have obtained all appropriate patient consent forms. In the form the patient(s) has/have given his/her/their consent for his/her/their images and other clinical information to be reported in the journal. The patients understand that their names and initials will not be published and due efforts will be made to conceal their identity, but anonymity cannot be guaranteed.

Financial support and sponsorship

Nil.

Conflicts of interest

There are no conflicts of interest.

References

- Giacomini C. Sull' esistenza dell' "os odontoideum" nell' uomo. *Gior Accad Med Torino* 1886;49:24-8.
- Fielding JW, Hensinger RN, Hawkins RJ. Os Odontoideum. *J Bone Joint Surg Am* 1980;62:376-83.
- Perdikakis E, Skoulikaris N. The odontoid process: Various configuration types in MR examinations. *Eur Spine J* 2014;23:1077-83.
- Tejada Meza H, Modrego Pardo P, Gazulla Abio J. Cervical myelopathy as the initial manifestation of os odontoideum. *Neurologia* 2016;31:278-9.
- Zhang Z, Wang H, Liu C. Acute traumatic cervical cord injury in pediatric patients with os odontoideum: A series of 6 patients. *World Neurosurg* 2015;83:1180.e1-6.
- Sankar WN, Wills BP, Dormans JP, Drummond DS. Os odontoideum revisited: The case for a multifactorial etiology. *Spine (Phila Pa 1976)* 2006;31:979-84.
- White IK, Mansfield KJ, Fulkerson DH. Sequential imaging demonstrating os odontoideum formation after a fracture through the apical odontoid epiphysis: Case report and review of the literature. *Childs Nerv Syst* 2013;29:2111-5.
- Stevens JM, Chong WK, Barber C, Kendall BE, Crockard HA. A new appraisal of abnormalities of the odontoid process associated with atlanto-axial subluxation and neurological disability. *Brain* 1994;117 (Pt 1):133-48.
- Morgan MK, Onofrio BM, Bender CE. Familial os odontoideum. Case report. *J Neurosurg* 1989;70:636-9.
- Yukata K, Katoh S, Sairyō K, Matsui Y, Hamada Y, Yasui N. Os odontoideum in achondroplasia: A case report. *J Pediatr Orthop*

- B 2008;17:103-5.
11. Komreich L, Horev G, Schwarz M, Karmazyn B, Laron Z. Laron syndrome abnormalities: Spinal stenosis, os odontoideum, degenerative changes of the atlanto-odontoid joint, and small oropharynx. *AJNR Am J Neuroradiol* 2002;23:625-31.
 12. Dias RP, Buchanan CR, Thomas N, Lim S, Solanki G, Connor SE, *et al.* Os odontoideum in Wolcott-Rallison syndrome: A case series of 4 patients. *Orphanet J Rare Dis* 2016;11:14.
 13. Ricciardi JE, Kaufer H, Louis DS. Acquired os odontoideum following acute ligament injury. Report of a case. *J Bone Joint Surg Am* 1976;58:410-2.
 14. Visocchi M, Di Rocco C. Os odontoideum syndrome: Pathogenesis, clinical patterns and indication for surgical strategies in childhood. *Adv Tech Stand Neurosurg* 2014;40:273-93.
 15. Sasaki H, Itoh T, Takei H, Hayashi M. Os odontoideum with cerebellar infarction: A case report. *Spine (Phila Pa 1976)* 2000;25:1178-81.
 16. Arvin B, Fournier-Gosselin MP, Fehlings MG. Os odontoideum: Etiology and surgical management. *Neurosurgery* 2010;66:22-31.
 17. Hughes TB Jr., Richman JD, Rothfus WE. Diagnosis of os odontoideum using kinematic magnetic resonance imaging. A case report. *Spine (Phila Pa 1976)* 1999;24:715-8.
 18. Dai L, Yuan W, Ni B, Jia L. Os odontoideum: Etiology, diagnosis, and management. *Surg Neurol* 2000;53:106-8.
 19. Michaels L, Prevost MJ, Crang DF. Pathological changes in a case of os odontoideum (separate odontoid process). *J Bone Joint Surg Am* 1969;51:965-72.