

Non-thrombotic superficial venous phlebitis secondary to Covid-19 vaccine or subsequent Covid-19 infection

SAGE Open Medical Case Reports
Volume 10: 1–3
© The Author(s) 2022
Article reuse guidelines:
sagepub.com/journals-permissions
DOI: 10.1177/2050313X221124378
journals.sagepub.com/home/sco



Mark S Whiteley  and Judy M Holdstock

Abstract

A 43-year-old woman presented with localised areas of prominent, tender superficial veins in her right arm and both legs, and chest pain, following the second dose of AstraZeneca vaccine and possible contemporaneous Covid-19 infection. Electrocardiogram, troponin and D-dimer had all been normal. However, a venous duplex ultrasound scan showed a perivenous inflammation without thrombosis in the areas of her limbs with prominent tender veins, but not elsewhere. We suggest that patients may present with prominent and tender superficial veins secondary to non-thrombotic phlebitis following Covid-19 infection or the AstraZeneca vaccine, which appears to be self-limiting. In addition, this case raises the possibility that Covid-19 infection or the AstraZeneca vaccine may directly affect cells in the vein wall, resulting in phlebitis without any evidence of thrombosis or microthrombosis. This phenomenon appears to be transient and self-limiting.

Keywords

Covid-19, vaccine, veins, phlebitis, non-thrombotic

Date received: 5 January 2022; accepted: 18 August 2022

Introduction

Covid-19 is predominantly a respiratory viral infection caused by SARS-CoV-2 (severe acute respiratory syndrome coronavirus 2) virus.¹ However, there is a link between this infection and the development of thromboses² stimulating interest in the effect of the virus on the blood clotting system and endothelium.³ We have not been able to find any reports, published or unpublished, of non-thrombotic phlebitis due to either Covid-19 infection or any of the vaccines against this disease.

We report a case of a woman who developed chest pain and prominent tender veins of arms and legs following her second vaccination with the AstraZeneca vaccine, with a possible Covid-19 infection evidenced by a positive polymerase chain reaction (PCR). In addition, ultrasound evidence showed non-thrombotic phlebitis of some of her peripheral superficial veins.

Case

A previously healthy 43-year-old woman presented in October 2021 with localised areas of prominent and tender veins in her right arm and both legs.

A venous duplex ultrasound (VDU) showed a distinct ‘halo’ of inflammatory type reaction around the affected veins, which remained patent with no intra-luminal thrombus. Other asymptomatic superficial veins elsewhere had a normal appearance. These original images were lost during a service of the ultrasound machine, and 11 days later, when we found the images missing, we asked the patient to return for repeat scans. At this stage, the ultrasound signs of perivenous inflammation were much reduced but were still present (Figures 1 and 2). C-reactive protein (CRP), erythrocyte sedimentation rate (ESR) and white cell count (including differential) were all normal at this stage.

Five weeks later, the veins had become significantly less prominent and tender. A further VDU showed complete resolution of the perivenous inflammation.

The history began in June 2021, when the patient had her second vaccination for Covid-19, 8 weeks following her first dose. Both doses were the AstraZeneca vaccine. One day

The Whiteley Clinic, Guildford, UK

Corresponding Author:

Mark S Whiteley, The Whiteley Clinic, 1 Stirling House, Stirling Road, Guildford GU2 7RF, Surrey, UK.
Email: mark@thewhiteleyclinic.co.uk



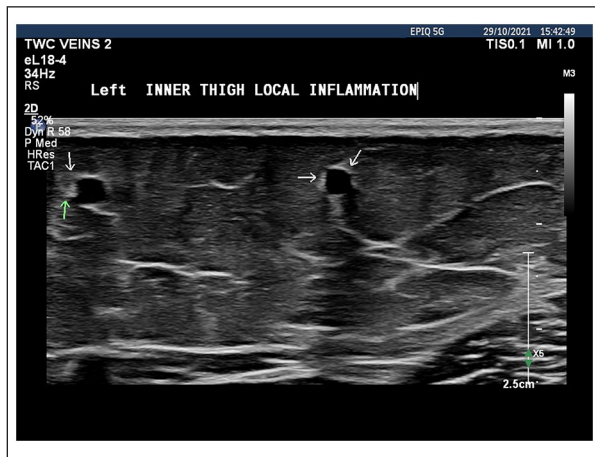

Figure 1. Ultrasound showing two superficial veins in the transverse section in the left thigh's sub-cutaneous fat, with perivenous inflammation (arrows).

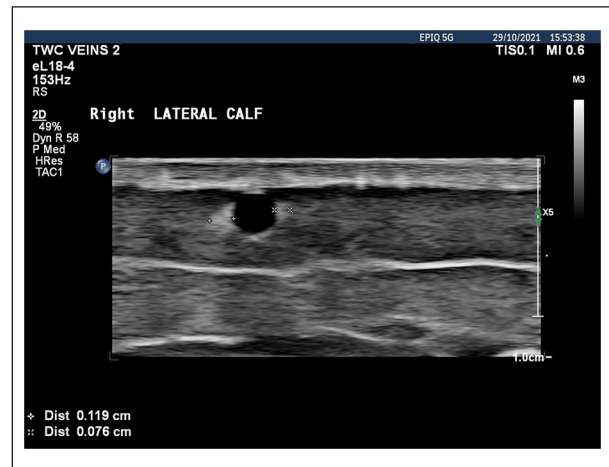


Figure 2. Ultrasound showing a superficial vein in the transverse section in the right calf's sub-cutaneous fat, with the lateral extent measured on both sides by the calipers.

after the second vaccination, the patient felt very tired, particularly after walking. Six days post second vaccination, the patient started experiencing chest pain and palpitations. She described the chest pain as a 'pressure', worse on movement and with no radiation. On the 12th day, they had become severe enough for her to visit accident and emergency for chest pain. All her tests, including an electrocardiogram (ECG), troponin and D-dimer, were reported normal, so she was discharged home without treatment.

Four days later, she continued to feel tired and unwell, developed pain in her left calf and still had chest pain. She visited a second accident and emergency department, and her investigations, including troponin and D-dimer, were reported to be normal.

Five days later (21 days after her second dose of vaccine), she paid for a private PCR test which was positive for Covid-19.

Her chest pain started to ease, although she reported that her tiredness continued, and she started noticing 'brain fog'.

One month after the second vaccination, she reported pins and needles in her limbs and heaviness and aching in her left leg. Her family doctor organised a D-dimer test to exclude deep vein thrombosis (DVT), which was negative.

On 6 August 2021, she started feeling a sensation of burning in her left thigh. She noted that some superficial veins in the area were becoming raised and extending to her left calf. She was prescribed low-molecular-weight heparin based on a Wells score and the positive PCR test for Covid-19, and a VDU scan for DVT was booked on 9 August.

She noted that veins in her right arm started becoming prominent and started getting discomfort in her right leg. VDU scan of her veins on 9 August was reported to be negative for DVT and superficial venous thrombosis. CRP and white cell counts were normal.

On 16 August, she consulted a consultant vascular surgeon. A VDU of her tender veins was reported as normal.

The vascular surgeon suggested gabapentin for 'nerve pain', although she did not take this. Three days later, her family doctor started her on aspirin 75 mg daily.

She then continued to suffer from her chest symptoms, developed a pounding in the back of her head and continued to have discomfort in her prominent right arm veins and those of both legs. At this point, she presented to the authors and was found to have perivenous inflammation around the veins that she reported being prominent and tender.

Discussion

Although Covid-19 is predominantly an acute respiratory viral infection, it also causes thromboses.² These thromboses are primarily venous, although arterial thromboses have been described,⁴ and there is a clear association between the presence and extent of thrombosis and the severity of the illness.⁵⁻⁷ Hence, considerable research has focused on how the SARS-CoV-2 virus interacts with the blood clotting system^{8,9} in conjunction with the endothelium^{3,10} to promote thrombosis. The AstraZeneca vaccine, in particular, has also been associated with the formation of venous thromboses,¹¹ although at a much lower incidence.

The associated chest pain in this patient is of unknown aetiology. It is unknown whether it is associated with the non-thrombotic phlebitis or unrelated, such as costochondritis.

These findings might represent a vasculitis unrelated to Covid-19 or the vaccination. Although we did not take blood for specific inflammatory markers, the CRP was normal when tested on 8 August, and both CRP and ESR were normal on 29 October. The patient had never had similar symptoms or signs previously and has not had any since.

Hence, the time course suggests a link between Covid-19 infection, vaccination and the presenting complaint of localised prominent and tender superficial veins. The fact

that the white cell count, CRP and ESR were normal might be due to one of two factors. It could be due to the timing of the blood tests, being too late to catch any acute inflammatory changes. Alternatively, it might be due to the areas of inflammation being small, mild and localised and possibly too small and mild to elicit a significant systemic response.

Since the beginning of the Covid-19 pandemic, we have had several enquiries from patients complaining of localised areas of prominent and tender veins on the arms and legs and asking whether these might be associated with Covid-19 infection or vaccination. Before this case, we had always said 'no' unless there was an associated superficial venous thrombosis. However, the unexpected finding of a perivenous inflammation in this patient, only present in those prominent and tender veins in the right arm and both legs, has forced us to accept that non-thrombotic phlebitis can occur in peripheral veins. However, due to this patient's history of vaccination and subsequent positive PCR, we cannot tell whether it is related to her second dose of the AstraZeneca vaccine or a Covid-19 infection that occurred at approximately the same time.

The reported case of non-thrombotic phlebitis raises the possibility that Covid-19 infection, or the AstraZeneca vaccine, may not only directly affect the blood clotting system and venous endothelial cells, but also affect the cells of the vein walls.

Conclusion

This case suggests that patients may develop prominent and tender veins in their arms and legs secondary to Covid-19 infection or vaccination. These prominent and tender veins are not secondary to thrombosis and appear to be non-thrombotic phlebitis. Although concerning for the patient, it seems to be transient and self-limiting.

Declaration of conflicting interests

The author(s) declared no potential conflicts of interest with respect to the research, authorship and/or publication of this article.

Ethical Approval

The patient has given written consent for her case and images to be published.

Funding

The author(s) received no financial support for the research, authorship and/or publication of this article.

Guarantor

Prof. Mark S Whiteley is the guarantor of this article.

Informed consent

Written informed consent was obtained from the patient for their anonymised information to be published in this article.

ORCID iD

Mark S Whiteley  <https://orcid.org/0000-0001-6727-6245>

References

1. Andersen KG, Rambaut A, Lipkin WI, et al. The proximal origin of SARS-CoV-2. *Nat Med* 2020; 26(4): 450–452.
2. Zhou X, Cheng Z and Hu Y. COVID-19 and venous thromboembolism: from pathological mechanisms to clinical management. *J Pers Med* 2021; 11(12): 1328.
3. Mizurini DM, Hottz ED, Bozza PT, et al. Fundamentals in COVID-19-associated thrombosis: molecular and cellular aspects. *Front Cardiovasc Med* 2021; 8: 785738.
4. Oba S, Hosoya T, Amamiya M, et al. Arterial and venous thrombosis complicated in COVID-19: a retrospective single center analysis in Japan. *Front Cardiovasc Med* 2021; 8: 767074.
5. Douillet D, Riou J, Penalzoza A, et al. Risk of symptomatic venous thromboembolism in mild and moderate COVID-19: a comparison of two prospective European cohorts. *Thromb Res* 2021; 208: 4–10.
6. Srivastava R, Parveen R, Mishra P, et al. Venous thromboembolism is linked to severity of disease in COVID-19 patients: a systematic literature review and exploratory meta-analysis. *Int J Clin Pract* 2021; 75(12): e14910.
7. Zdanyte M, Rath D, Gawaz M, et al. Venous thrombosis and SARS-CoV-2. *Hamostaseologie*. 2021; 42: 240–247.
8. Tang N, Li D, Wang X, et al. Abnormal coagulation parameters are associated with poor prognosis in patients with novel coronavirus pneumonia. *J Thromb Haemost* 2020; 18(4): 844–847.
9. Violi F, Pignatelli P, Cammisotto V, et al. COVID-19 and thrombosis: clinical features, mechanism of disease, and therapeutic implications. *Kardiol Pol* 2021; 79(11): 1197–1205.
10. Lim MS and Mcrae S. COVID-19 and immunothrombosis: pathophysiology and therapeutic implications. *Crit Rev Oncol Hematol* 2021; 168: 103529.
11. Bilotta C, Perrone G, Adelfio V, et al. COVID-19 vaccine-related thrombosis: a systematic review and exploratory analysis. *Front Immunol* 2021; 12: 729251.