

Case of probable Vogt–Koyanagi–Harada syndrome: A rare presentation

Kervi N Mehta, Sachin Daigavane

Key words: Probable VKH, sunset fundus, uveitis

Vogt–Koyanagi–Harada (VKH) syndrome is a multisystemic autoimmune disease. It is a non-necrotizing diffuse granulomatous uveitis disease, commonly affecting various organs such as eyes, central nervous system, inner ear, and skin.^[1,2] It is characterized by ocular signs such as panuveitis, serous or exudative retinal detachment, “sunset glow fundus” with optic disk hyperemia, neurologic signs like

tinnitus, headache, meningitis, and cranial nerve palsies, and dermatologic signs like alopecia, vitiligo, and poliosis.

A 32-year-old female came to the ophthalmology outpatient department (OPD) with the chief complaints of diminution of vision in right eye in the last 6 months, which was gradual in onset, progressive, and painless in nature and was associated with headache on and off. She gave history of redness in the past. Treatment was taken for the same; however, documentation was not available. She did not give any history of joint pain, immunodeficiency disorder such as acquired immune deficiency syndrome, tuberculosis, syphilis, malignancy, or vascular diseases. She also denied any history of eye trauma and ocular surgery in the past. There was no history of depigmentation of skin or hair, poliosis, weakness of limbs, backpain, or tinnitus.

On ocular examination, her best corrected visual acuity (BCVA) in the right eye was counting finger close to face with projection of rays accurate in all four quadrants and 6/36 in the left eye. On slit-lamp examination of the anterior segment, there was no evidence of conjunctival congestion or circumcorneal congestion [Fig. 1]. There was presence of multiple old mutton fat keratic precipitates bilaterally with no anterior chamber cells and depth. However, there was loss

Access this article online	
Quick Response Code:	Website: www.ijo.in
	DOI: 10.4103/ijo.IJO_495_22

Department of Ophthalmology, Datta Meghe Institute of Medical Sciences, Wardha, Maharashtra, India

Correspondence to: Dr. Kervi Mehta, Plot no-4 Ratitalai Main Road, Near Nayak hospital Banswara, Udaipur Rajasthan - 327 001, India. E-mail: mehta.kervi@gmail.com

Received: 10-Mar-2022

Revision: 19-Mar-2022

Accepted: 12-May-2022

Published: 30-Jun-2022

This is an open access journal, and articles are distributed under the terms of the Creative Commons Attribution-NonCommercial-ShareAlike 4.0 License, which allows others to remix, tweak, and build upon the work non-commercially, as long as appropriate credit is given and the new creations are licensed under the identical terms.

For reprints contact: WKHLRPMedknow_reprints@wolterskluwer.com

Cite this article as: Mehta KN, Daigavane S. Case of probable Vogt–Koyanagi–Harada syndrome: A rare presentation. Indian J Ophthalmol 2022;70:2684-6.

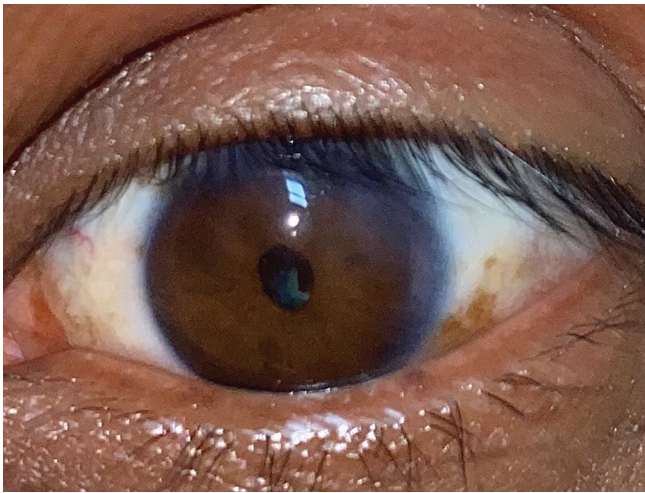


Figure 1: Clinical photograph of the patient

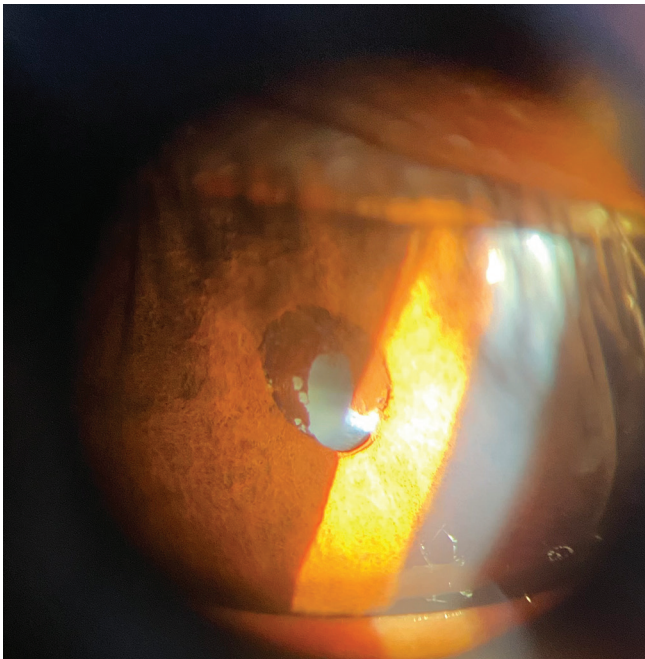


Figure 3: Slit lamp photograph of the patient

of iris color and pattern, with irregular pupil of size 2–3 mm with dense annular posterior synechiae suggestive of seclusio pupillae. Both eyes had complicated cataract [Fig. 2]. The intraocular pressure was 14 and 16 mmHg in the right and left eye, respectively. B-scan ultrasonography showed no evidence of exudative retinal detachment or choroidal thickening.

Patient underwent cataract extraction by phacoemulsification with hydrophilic posterior chamber intraocular lens implantation in the right eye. Fundus examination was done postoperatively, which showed depigmentation with bright red-orange choroid and pale disk suggestive of sunset glow fundus [Fig. 3]. On ENT referral, audiometry showed normal results. Complete blood count including white blood cells count, erythrocyte sedimentation rate, and C-reactive protein showed no abnormality.

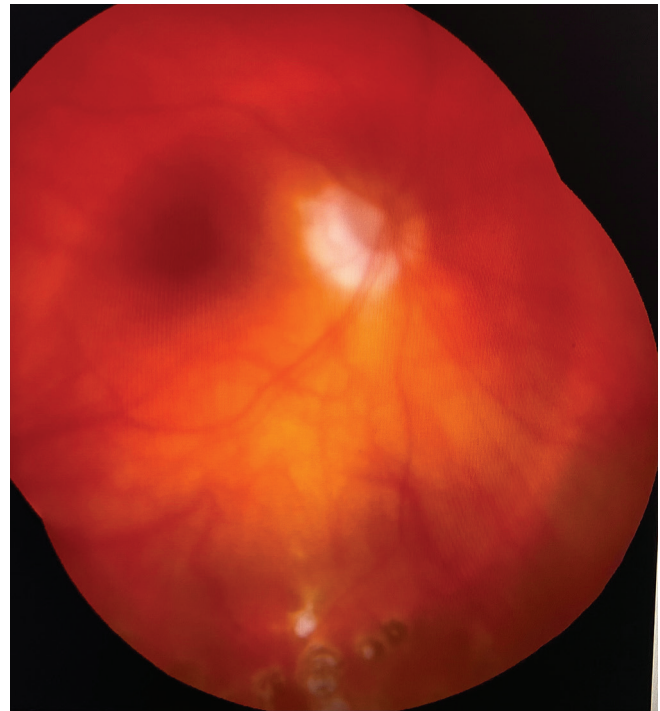


Figure 2: Fundus photograph showing typical sunset glow

Discussion

VKH is a multisystem autoimmune disorder, and the diagnosis is made clinically by the presence of ocular signs and the absence of ocular trauma or surgery.^[3] The most commonly used criteria for diagnosing it are the international revised criteria of VKH which includes complete VKH, incomplete VKH, and probable VKH.

The First International Workshop on VKH syndrome had revised the diagnostic criteria as follows – complete VKH is defined as bilateral involvement with neurologic or auditory findings and integumentary findings; incomplete VKH is defined as bilateral involvement with neurologic or auditory findings or integumentary findings; and probable VKH is defined as bilateral ocular involvement only.

The VKH syndrome is divided into four stages clinically, which are as follows:

1. Prodromal stage which includes symptoms like fever, headache, myalgia, and vertigo lasting for a few days.
2. Uveitic stage involving one eye and the second eye a few days later. Symptoms like blurred vision, scotoma, and photophobia are present. Most common presentation is serous retinal detachment.
3. Chronic (convalescent) stage, which is characterized by the presence of vitiligo and hair loss. This stage lasts for several months and is characterized by sunset glow fundus.
4. Chronic recurrent stage is characterized by episodic exacerbations of anterior uveitis associated with glaucoma, posterior synechiae, or posterior subcapsular cataract.

The American Uveitis Society (AUS)^[4] diagnostic criteria for VKH syndrome include the following:

1. No history of ocular trauma or ocular surgery in the past and
2. Presence of at least three out of the following four findings:

- Bilateral chronic uveitis;
- Posterior uveitis with retinal detachment, disk edema, and sunset glow fundus;
- Neurologic signs like central nervous system disorder, tinnitus, neck stiffness, and headache; and
- Dermatologic signs like alopecia, poliosis, or vitiligo.

The patient was diagnosed as a case of probable VKH syndrome as there was only ocular involvement with no dermatologic or neurologic involvement. After making correct diagnosis and tailored management, our patient showed a BCVA of 6/12 in the right eye postoperatively. Complete VKH syndrome with integumentary findings is commonly seen and managed, whereas probable VKH syndrome is rarely diagnosed. Therefore, we want to report this particular case. Its prevalence in developing countries like India^[5] is 1.4%–3.5%, and the etiology of this subtype is not studied in detail, while some consider it to have a genetic inheritance.

As the patient complained of headache associated with blurring of vision, timely diagnosis of probable VKH syndrome and its treatment was important in providing symptomatic therapy and achieving BCVA, as the patient's age was less. Our treatment primarily focused on providing vision to the patient and to further prevent sight-threatening complications like exudative retinal detachment, for which we kept the patient on strict follow-ups.

There was no clinical evidence of any ocular injury or immune recovery uveitis in our patient in the past.^[6,7] But our timely diagnosis and prompt treatment helped in shortening of duration of this disease.

We monitored the patient's intraocular pressure at each follow-up visit, as secondary glaucoma is a well-known complication of this disease. Recurrence of the disease is also very common, so all the patients of VKH syndrome should be counseled for regular follow-up to prevent further ocular complications.

Declaration of patient consent

The authors certify that they have obtained all appropriate patient consent forms. In the form the patient(s) has/have given his/her/their consent for his/her/their images and other clinical information to be reported in the journal. The patients understand that their names and initials will not be published and due efforts will be made to conceal their identity, but anonymity cannot be guaranteed.

Financial support and sponsorship

Nil.

Conflicts of interest

There are no conflicts of interest.

References

1. Moorthy RS, Inomata H, Rao NA. Vogt-Koyanagi-Harada syndrome *Surv Ophthalmol* 1995;39:265-92.
2. Read RW. Vogt-Koyanagi-Harada disease. *Ophthalmol Clin North Am* 2002;15:333-41, vii. doi: 10.1016/s0896-1549(02)00025-1.
3. Boyd SR, Young S, Lightman S. Immunopathology of the noninfectious posterior and intermediate uveitides. *Surv Ophthalmol* 2001;46:209-33.
4. Read RW, Holland GN, Rao NA, Tabbara KF, Ohno S, Arellanes-Garcia L, *et al.* Revised diagnostic criteria for Vogt-Koyanagi-Harada disease: Report of an international committee on nomenclature. *Am J Ophthalmol* 2001;131:647-52.
5. Patil YB, Garg R, Rajguru JP, Sirsalmath M, Bevinakatti VA, Kumar M, *et al.* Vogt-Koyanagi-Harada (VKH) syndrome: A new perspective for healthcare professionals. *J Family Med Prim Care* 2020;9:31-5.
6. Karavellas MP, Lowder CY, Macdonald C, Avila CP Jr, Freeman WR. Immune recovery vitritis associated with inactive cytomegalovirus retinitis: A new syndrome. *Arch Ophthalmol* 1998;116:169-75.
7. Karavellas MP, Plummer DJ, Macdonald JC, Torriani FJ, Shufelt CL, Azen SP, *et al.* Incidence of immune recovery vitritis in cytomegalovirus retinitis patients following institution of successful highly active antiretroviral therapy. *J Infect Dis* 1999;179:697-700.