

## Letters

Advance Access publication 6 October 2009

### Adrenal insufficiency in a haemodialysis patient

Sir,

Abnormalities in the hypothalamic–pituitary–adrenocortical (HPA) axis do not usually lead to severe adrenal insufficiency in haemodialysis (HD) patients. However, drug administration may trigger a paradigm shift.

A 67-year-old man receiving HD therapy for 4 years was admitted to our hospital due to a traumatic fracture of the right rib. Treatment with nonsteroidal anti-inflammatory drugs was started on the first hospital day. On the sixth hospital day, the patient's body temperature rose to 38.0°C and he became disoriented. His condition worsened over time. A presumptive diagnosis of viral, fungal or tuberculous meningitis was made. Although the patient was given isoniazid, streptomycin sulfate and fluconazole, the fever and disorientation continued and he fell into a coma. On the 18th hospital day, the patient received mechanical ventilation due to Cheyne-Stokes breathing. Repeated blood cultures were found to be negative. Plasmapheresis was performed, but the patient remained in a coma. Four months from admission, adrenal insufficiency was suspected. Nine days later, the patient's body temperature rose to 40.0°C. A blood culture yielded *Serratia marcescens*. Antibiotic (short-term) and steroid (long-term) therapies were given. The patient became afebrile and was completely free from the coma and disorientation.

We evaluated the HPA axis. Corticotropin-releasing hormone (CRH) induced an ACTH response, but not a cortisol response (Figure 1b, c). The dexamethasone suppression test lowered the plasma ACTH level. Magnetic resonance imaging did not disclose any structural abnormalities (data not shown). Plasma levels of the pituitary hormones were within the normal range. Insulin reduced the blood glucose levels; however, the responsiveness of ACTH (Figure 1f), cortisol (Figure 1f), growth hormone (data not shown) and catecholamine (data not shown) was poor. Adrenal insufficiency with a disturbed hypothalamic regulation was strongly indicated. The HPA axis and hypothalamic abnormalities have been described in HD patients. Reports on adrenal insufficiency in HD patients are rare and diverse (Table 1) and include cases of tuberculous Addison's disease [1], primary adrenal insufficiency and panhypopituitarism

due to systemic AA-amyloidosis [2], isolated adrenocorticotrophic hormone deficiency [3] and steroid withdrawal in rejected renal allografts [4].

Our patient was exposed to multiple predisposing factors, such as trauma, infection and drug administration. In infection, a dysfunction of the HPA axis at the hypothalamus–pituitary level has been observed [5]. Fluconazole is an anti-fungal agent capable of interfering with steroid biosynthesis by inhibiting P450-dependent enzyme synthesis [5] and inducing adrenal insufficiency. Central nervous system symptoms may occur in adrenal failure. Importantly, soon after our patient received anti-fungal therapy, his disorientation worsened. This temporal association strongly indicated that fluconazole worsened the adrenal insufficiency.

In conclusion, we have described an HD patient with adrenal insufficiency in whom abnormalities of the HPA axis, especially those at the hypothalamic level, emerged. We should bear in mind the possibility that drug administration may promptly induce severe adrenal dysfunction in HD patients with a background of multiple predisposing factors.

*Conflict of interest statement.* None declared.

Division of Nephrology  
Department of Medicine, Showa  
University Fujigaoka Hospital  
1-30 Fujigaoka, Aoba-ku  
Yokohama 227-8501, Japan  
E-mail: morita@  
showa-university-fujigaoka.gr.jp

Ryuji Suzuki  
Hiroyuki Morita  
Hiroyuki Nishiwaki  
Ashio Yoshimura

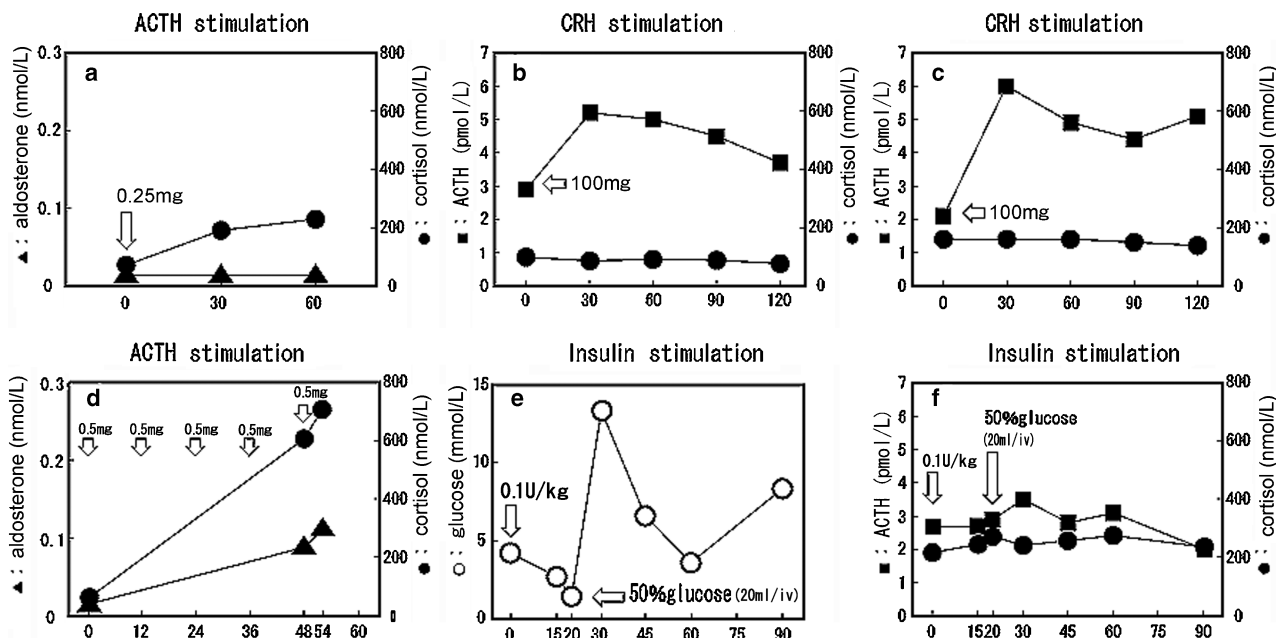
1. Neill JD, Lapkin RA. Tuberculous addison disease complicating dialysis. *Conn Med* 1982; 46: 254–257
2. Erdkamp FLG, Gans ROB, Hoorntje SJ. Endocrine organ failure due to systemic AA-amyloidosis. *Neth J Med* 1991; 38: 24–28
3. Kato A, Shinozaki S, Goga T *et al.* Isolated adrenocorticotrophic hormone deficiency presenting with hypercalcemia in a patient on long-term hemodialysis. *Am J Kidney Dis* 2003; 42: 1–5
4. Sever MS, Turkmen A, Yildiz A *et al.* Fever in dialysis patients with recently rejected renal allografts. *Int J Artif Organs* 1998; 21: 403–407
5. Bornstein SR. Predisposing factors for adrenal insufficiency. *N Engl J Med* 2009; 360: 2328–2339

doi: 10.1093/ndtplus/sfp143

**Table 1.** Cases of adrenal insufficiency in haemodialysis patients

Case	52 y/o F	54 y/o F	44 y/o F	33 y/o M	36 y/o F
Type	Primary	Panhypo-pituitarrism, primary	Isolated ACTH deficiency	Primary	Primary
Cause	Tuberculosis	Amyloidosis	Unknown	Steroid withdrawal	Steroid withdrawal
Clinical findings	Hyper-pigmentation	Fever	Fever	Fever	Fever
Treatment	PSL 10 mg/day	Cortisone acetate 37.5 mg/day	Without glucocorticoid supplementation	mPSL 30 mg/day	mPSL 20 mg/day
HPA axis	ACTH very high	ACTH not measured	ACTH very low	ACTH not measured	ACTH not measured
Ref.	Neill [1]	Erdkamp [2]	Kato [3]	Sever [4]	Sever [4]

y/o; year-old, F; female, M; male, ACTH; adrenocorticotrophic hormone, PSL; prednisolone, mPSL; methylprednisolone, HPA; hypothalamic-pituitary-adrenal, Ref.; reference.



**Fig. 1.** Time course of stimulation tests to evaluate the HPA axis. Blood levels of aldosterone (▲-▲), cortisol (●-●) and ACTH (■-■) shown, as well as described in the text, were measured at the Health Sciences Research Institute, Yokohama, Japan. Open circles in (e) (○-○) indicate blood glucose levels. Values under a horizontal axis of each figure indicate minutes elapsed. Informed consent was obtained for each test performed.

Advance Access publication 3 November 2009

### Successful treatment of spontaneous kidney graft decapsulation 18 years after renal transplantation: a case report

Sir,

The detection of a perirenal fluid collection causing graft dysfunctions is common in the early postoperative phase after renal transplantation. These are typically lymphocèles, urinomas, abscesses and haematomas, and treatment is well established. Perirenal fluid collection causing acute or sub-acute renal failure several years after engraftment is unusual. A rare, but potentially treatable condition is acute spontaneous decapsulation of the kidney graft. We hereby present a case of spontaneous decapsulation and rapid decline of renal function 18 years after engraftment.

A 41-year-old Caucasian male with end-stage renal failure was diagnosed in 1989 with chronic glomerulonephri-

tis (not biopsy verified) and received a renal transplant in 1990 at age 23, from his HLA-identical 21-year-old brother (CMV+ to +, PRA-). There were no rejections or other early complications. Graft function remained steady over the next 18 years with s-creatinine 100–120  $\mu\text{mol/L}$ . Immunosuppression consisted of CsA (125 mg b.i.d.,  $C_0$  target level 75–125), prednisolone (5 mg  $\times$  1/day) and azathioprine (75 mg/day, 6-TGN target 100). In 2003, an ultrasound of the renal graft and in 2005 a CT scan of the abdomen was done with normal findings regarding the graft.

During a routine control at the local hospital s-creatinine had increased from a stable value (100–120  $\mu\text{mol/L}$ ) to 150  $\mu\text{mol/L}$ . The development of chronic allograft nephropathy was suspected. Azathioprine was replaced by mycophenolate mofetil (MMF; 750 mg b.i.d.), and an ultrasound-guided renal biopsy was planned. The day after switch from azathioprine to MMF, the patient experienced a sudden onset of severe pain, and swelling in the graft was localized. S-creatinine at admission had further increased to 201  $\mu\text{mol/L}$ .