



## CASE REPORT

# REVISED Case Report: Co-infection with SARS-CoV-2 and influenza H1N1 in a patient with acute respiratory distress syndrome and a pulmonary sarcoidosis [version 2; peer review: 2 approved]

Lekbir Baala <sup>1,2\*</sup>, Dalila Benzekri-Lefevre<sup>3\*</sup>, Laurent Bret<sup>1</sup>, Toufik Kamel<sup>3</sup>, Clémence Guillaume<sup>1</sup>, Laura Courtellemont<sup>1</sup>, Abdelkrim El Khalil<sup>4</sup>, Thomas Guery<sup>1</sup>, Sophie Iquel<sup>1</sup>, Olivier Perche<sup>1,2</sup>, Khalid Khadre<sup>5</sup>, Thomas Brungs<sup>1</sup>, Julien Decker<sup>1</sup>, Thomas Francia<sup>1</sup>, Julie Bois<sup>1</sup>, Benoit Delamare<sup>1</sup>, Jérôme Guinard<sup>1</sup>, Laurence Got<sup>1</sup>, Sylvain Briault<sup>1,2</sup>, Thierry Boulain <sup>3</sup>, Eric Legac <sup>1</sup>

<sup>1</sup>Pole de Biopathologie , CS 86709, 45067 Orléans CEDEX , France, Centre Hospitalier Régional d'Orléans, 14 Avenu de l'Hôpital, Orléans, France

<sup>2</sup>UMR7355 INEM Immunologie et Neurogénétique Expérimentales & Moléculaires, CNRS & Université d'Orléans, 3B rue de la Ferrollerie, Orléans CEDEX 2, 45071, France

<sup>3</sup>Service de Médecine Intensive Réanimation, Pole Métiers de l'Urgence, Centre Hospitalier Régional d'Orléans, 14 Avenu de l'Hôpital, CS 86709, Oréans, 45067, France

<sup>4</sup>Service de Pneumologie, Centre Hospitalier Régional d'Orléans, Orléans, 45067, France

<sup>5</sup>Service de Radiologie, Centre Hospitalier Régional d'Orléans, Orléans, 45067, France

\* Equal contributors

**V2** First published: 18 Dec 2020, 9:1482  
<https://doi.org/10.12688/f1000research.26924.1>  
 Latest published: 03 May 2022, 9:1482  
<https://doi.org/10.12688/f1000research.26924.2>

## Abstract

Coronavirus disease 2019 (COVID-19) is caused by severe acute respiratory syndrome coronavirus 2 (SARS-CoV-2) infection and has been a global public health concern. We report coinfection of SARS-CoV-2 and 2009 H1N1 Influenza strain in a French patient with pneumonia leading to acute respiratory distress syndrome. The patient also had a medical history of pulmonary sarcoidosis with a restrictive ventilatory syndrome and obesity, which would be a supplementary risk to develop a poor outcomes. This case highlights the possible coinfection of two severe SARS-CoV-2 and influenza H1N1 viruses in comorbid patient, which presents a higher risk to extend the care duration. The overlapping clinical features of the two respiratory syndromes is a challenge, and awareness is required to recommend an early differential diagnosis and it's necessary to adopt the vigilant preventive measures and therapeutic strategies to prevent a deleterious impacts in patients with comorbid factors.

## Open Peer Review

Approval Status

	1	2
<b>version 2</b> (revision) 03 May 2022	 view	
<b>version 1</b> 18 Dec 2020	 view	 view

1. Louise E. Lansbury , University of Nottingham, Nottingham, UK  
 NIHR Nottingham Biomedical Research Centre, Nottingham, UK

**Keywords**

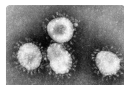
Co-infection, SARS-CoV-2, Influenza H1N1, Pulmonary sarcoidosis, Comorbidity




This article is included in the **Global Public Health** gateway.



This article is included in the **Emerging Diseases and Outbreaks** gateway.



This article is included in the **Coronavirus** collection.

2. **Khalid Sadki** , Mohammed V University, Rabat, Morocco

Any reports and responses or comments on the article can be found at the end of the article.

**Corresponding author:** Lekbir Baala ([lekbir.baala@chr-orleans.fr](mailto:lekbir.baala@chr-orleans.fr))

**Author roles:** **Baala L:** Conceptualization, Data Curation, Investigation, Validation, Writing – Original Draft Preparation; **Benzekri-Lefevre D:** Data Curation, Formal Analysis, Investigation, Validation; **Bret L:** Conceptualization, Data Curation, Investigation, Writing – Original Draft Preparation; **Kamel T:** Investigation; **Guillaume C:** Data Curation, Investigation, Validation; **Courtellemont L:** Data Curation, Investigation, Validation; **El Khalil A:** Data Curation, Investigation, Validation; **Guery T:** Investigation, Validation, Visualization; **Iquel S:** Formal Analysis, Visualization; **Perche O:** Data Curation, Investigation, Software, Writing – Original Draft Preparation; **Khadre K:** Data Curation, Validation; **Brungs T:** Data Curation, Validation; **Decker J:** Data Curation, Validation; **Francia T:** Data Curation, Validation, Visualization; **Bois J:** Data Curation, Investigation, Validation; **Delamare B:** Data Curation, Formal Analysis, Investigation; **Guinard J:** Data Curation, Investigation, Validation; **Got L:** Data Curation, Investigation, Supervision, Validation; **Briault S:** Conceptualization, Data Curation, Investigation, Validation, Writing – Original Draft Preparation; **Boulain T:** Data Curation, Supervision, Validation; **Legac E:** Data Curation, Project Administration, Supervision, Validation

**Competing interests:** No competing interests were disclosed.

**Grant information:** This study was supported by Centre Hospitalier Régional d'Orléans (CHRO).

**Copyright:** © 2022 Baala L *et al.* This is an open access article distributed under the terms of the [Creative Commons Attribution License](https://creativecommons.org/licenses/by/4.0/), which permits unrestricted use, distribution, and reproduction in any medium, provided the original work is properly cited.

**How to cite this article:** Baala L, Benzekri-Lefevre D, Bret L *et al.* **Case Report: Co-infection with SARS-CoV-2 and influenza H1N1 in a patient with acute respiratory distress syndrome and a pulmonary sarcoidosis [version 2; peer review: 2 approved]** F1000Research 2022, 9:1482 <https://doi.org/10.12688/f1000research.26924.2>

**First published:** 18 Dec 2020, 9:1482 <https://doi.org/10.12688/f1000research.26924.1>

**REVISED Amendments from Version 1**

In the second version, we have taken into account the interesting remarks of the reviewers. We had added some molecular, clinical, and therapeutic details during the patient's hospitalization. But the most important remark is the fact that the co-infection occurred in a patient with a history of pulmonary sarcoidosis, it seems more original and deserves more emphasis in the discussion and in the title. Also, it is very important to note that it is necessary to adopt the vigilant preventive measure and therapeutic strategies to prevent a deleterious impact on infected and comorbid patients. We have added Dr. Toufik Kamel in the author list.

**Any further responses from the reviewers can be found at the end of the article**

**Introduction**

Coinfections involving SARS-CoV-2 and respiratory viruses influenza viruses (A or B) have been rarely reported<sup>1-9</sup>. One recent meta-analysis indicated that overall 1.2% of COVID-19 patients had influenza co-infection<sup>10</sup>. However, there was no more evaluation of the infection effect in clinical outcomes and less in patients with other comorbidity factors. Our patient presented concurrent COVID-19 and Influenza infections with a history of pulmonary sarcoidosis.

**Case report**

A 41-year-old man presented to the hospital's emergency unit with fever and cough that has been progressing for several days. The SARS-CoV-2 RT-PCR test carried on the 3 targets genes *RdRp*, *N*, *E* was positive on March 22<sup>nd</sup> 2020, whereas the cough and fever had already been evolving for three to four days before. On March 24<sup>th</sup> 2020, the patient had developed a dyspnea aggravation and was taken care of by a medical unit at home. He has a medical history of pulmonary sarcoidosis with a restrictive ventilatory syndrome, which was being treated with Methotrexate (15mg per week) and folic acid (0,4mg one tablet per day). He also had malaria in 2004 from a trip to Central Africa.

Physical examination on the 24<sup>th</sup> March revealed a respiratory rate of 41 breaths/minute (normal range (NR) 12–20 breaths/minute) and oxygen saturation SpO<sub>2</sub> of 75% (reference range (R-R) 95–100%) on ambient air. The SpO<sub>2</sub> became at 96% when given mask flow oxygen at a rate of 12l/minute. The patient was transferred to the emergency room with 97% SpO<sub>2</sub>, body temperature 37.2°C, and respiratory rate of 30 breaths per minute. The patient presented with superficial polypnea, dyspnea with little effort, difficulty in speaking and bilateral “crackles”. Neurological and cardiovascular examinations were normal.

On supplemental oxygen (12l/min), arterial blood gas analysis revealed pH 7.50 (R-R 7.35–7.45), PCO<sub>2</sub> 35 mmHg (NR 35–45 mmHg), PO<sub>2</sub> 88 mmHg (NR 75–100 mmHg), HCO<sub>3</sub><sup>-</sup> 27.3 mmol/l (R-R 22–26 mmol/l), and SaO<sub>2</sub> 94.4% (R-R 95–100%). The patient was then transferred to intensive care unit (ICU). Respiratory panel tests were negative for adenovirus (subtypes 2, 3, 6, 7.1 and 8), coronaviruses (229E, HKU1, NL63 and OC43), human metapneumovirus, rhinovirus, enterovirus, MERS-CoV, parainfluenza virus (1,2,3 and 4), respiratory

syncytial virus, and *Bordetella pertussis* and *parapertussis*. However, influenza A, subtype influenza A-H1 variant 2009, was positive. The molecular and genetic analysis of the 3 target genes (*RdRp*, *N*, *E*) of SARS-CoV-2 revealed the persistence of virus for 3 weeks.

A chest computed tomography scan revealed a predominant left interstitial lung condensation syndrome. Routine laboratory tests revealed higher parameters during patient hospitalization: creatine phosphokinase 2999 UI/l (R-R 30–200UI/l); gamma glutamyl transferase 119 UI/l (R-R 12–64UI/l); D-Dimers, which has increased two fold in one week, 3620 ng/ml (April 6<sup>th</sup>) to 7520 (April 15<sup>th</sup>) (R-R 40–500UI/l). Other parameters were also elevated: fibrinogen 8.58g/l (R-R 2–4g/l); aspartate-aminotransferase 55 UI/l (R-R 5–34UI/l); platelets 599x10<sup>9</sup>/l (April 7<sup>th</sup>) (R-R 150–450x10<sup>9</sup>/l); leukocytes 15.4x10<sup>9</sup>/l (R-R 4–10x10<sup>9</sup>/l) (Table 1).

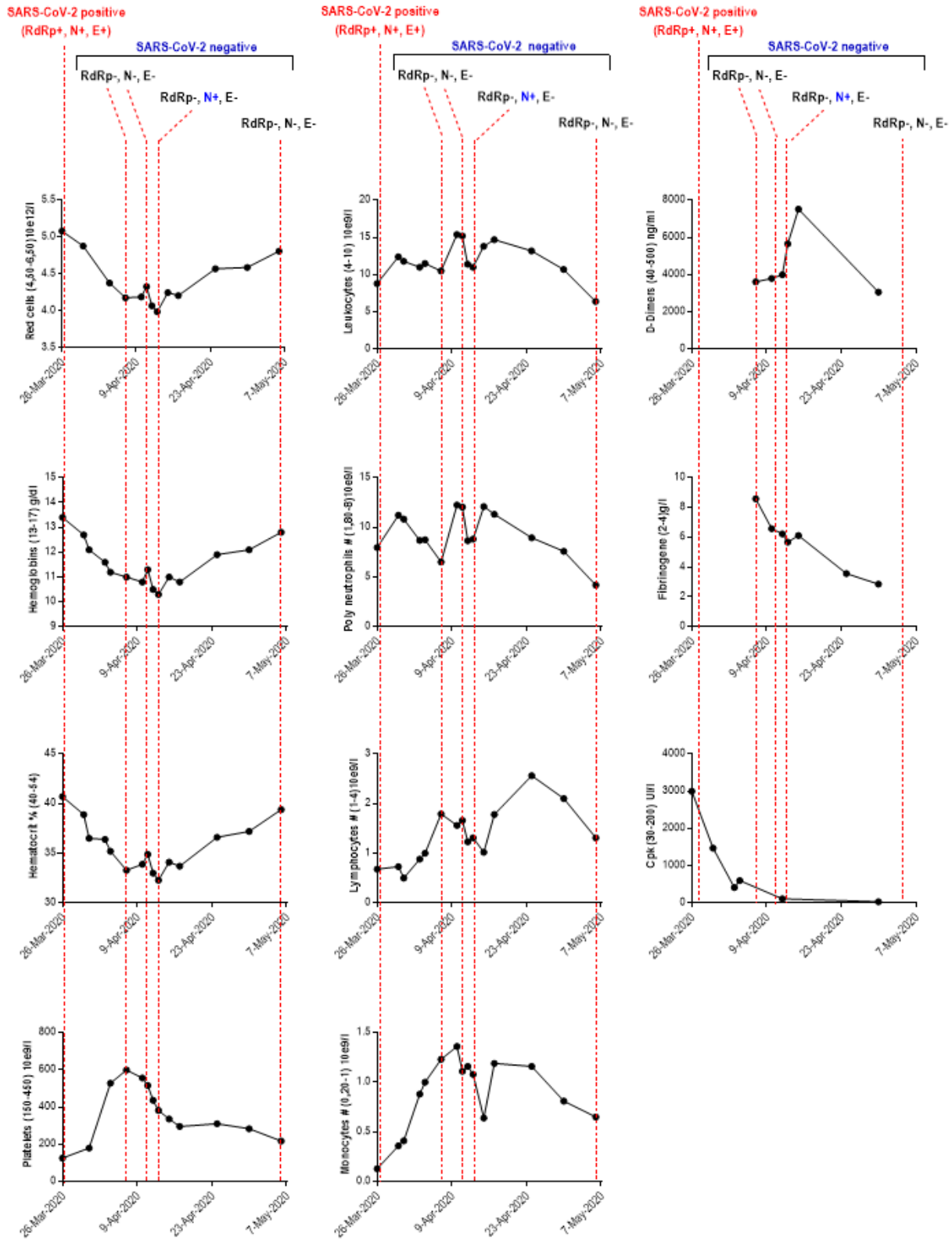
Other parameters showed decreased values such as red cells, hemoglobins, hematocrits and mean corpuscular hemoglobin content (Table 1). The number of leukocytes and neutrophils underwent fluctuations with high rates between April 7<sup>th</sup> and 10<sup>th</sup> (Figure 1). In this period, bacteriological examination culture revealed infection by additional pathogens, with the presence of yeasts (*Candida albicans*) and bacteria (*Klebsiella pneumoniae*) in bronchial sampling, probably with nosocomial origin. Indeed, *Klebsiella pneumoniae* was isolated on the deep bronchial sample of March 28<sup>th</sup>, 2020, five days after his admission and mechanical ventilation. On the 14<sup>th</sup> day of admission (April 4<sup>th</sup> 2020), *Klebsiella pneumoniae* was found once again at 10<sup>6</sup> in a bronchoalveolar lavage which means the failure of treatment with imipenem, meropenem is then introduced. Also, *Candida albicans* was found in the same bronchoalveolar lavage at 10<sup>4</sup>.

The patient stayed at ICU for 26 days from March 24<sup>th</sup> to April 19<sup>th</sup> with orotracheal intubation and using Etomidate (40 mg intravenous dose) for sedation and 120mg of Celcurine for curarization. Enoxaparin (40mg /day) was administered by subcutaneous injection as a preventive anticoagulation up to April 1<sup>st</sup> and increased to 80 mg/day according to the patient being overweight (Body Mass Index 33.8) and to evolution of biological criteria (D-Dimers 1890ng/l, Fibrinogen 10.82g/l, platelets 528x10<sup>9</sup>/l). Unfractionated heparin was used as relay according to the high probability of pulmonary embolism. Mechanical ventilation was used with several sessions of prone position and then oxygen therapy on April 19<sup>th</sup>. He was treated with hydroxychloroquine for 10 days (Plaquenil, 200mg every eight hours), and by Oseltamivir (4 days, oral suspension 6mg/ml: 75mg twice/day) for influenza H1N1 infection. *Klebsiella pneumoniae* infection was treated using Meropenem (intravenous 1 g every four hours) from 6<sup>th</sup> to 15<sup>th</sup> April and *Enterococcus faecalis* infection was treated using Clamoxyl (intravenous 2 g every eight hours). Venous echodoppler performed on April 14<sup>th</sup> found no thrombosis and no pulmonary embolism.

On April 19<sup>th</sup>, the patient was transferred to the pulmonology department where he has a good respiratory evolution allowing oxygen weaning on April 23<sup>rd</sup>. He was discharged on April 28<sup>th</sup>, receiving kinesitherapy treatment, and taking

**Table 1. Laboratory findings in the patient with coinfection of SARS-CoV-2 and influenza H1N1.** NA: data non available.

Laboratory parameters (reference range)	March, 26	March, 26	March, 31	April, 03	April, 04	April, 07	April, 10	April, 11	April, 12	April, 13	April, 15	April, 17	April, 24	April, 30	May, 06
Leukocytes (4–10x10e9/l)	8.8	12.4	11.8	11	11.5	10.5	15.4	15.2	11.4	11	13.8	14.7	13.2	10.7	6.4
Red cells (4.50–6.50x10e12/l)	5.08	4.88	NA	NA	4.38	4.18	4.19	4.33	4.07	3.99	4.25	4.21	4.57	4.59	4.81
Hemoglobins (13–17 g/dl)	13.4	12.7	12.1	11.6	11.2	11	10.8	11.3	10.5	10.3	11	10.8	11.9	12.1	12.8
Hematocrit (40–54%)	40.7	38.9	36.5	36.4	35.2	33.3	33.9	34.9	33	32.3	34.1	33.7	36.6	37.2	39.4
Mean corpuscular volume (80 um3)	80	80	79	81	NA	80	81	81	81	81	80	80	80	81	82
Mean corpuscular haemoglobin concentration (27–32 pg)	26.5	26.1	26.2	25.7	25.6	26.4	25.7	26	25.8	25.9	25.1	25.8	25.9	26.3	26.6
Red cell distribution width (12–16%)	15.9	NA	NA	NA	NA	NA	NA	16.2	16.5	16.2	15.4	15.6	16.8	17.9	18
Platelets (150–450x10e9/l)	126	NA	180	NA	528	599	556	516	437	382	336	296	311	284	218
Total neutrophils (1.80–8x10e9/l)	7.98	11.23	10.83	8.69	8.75	6.52	12.26	12.04	8.66	8.82	12.1	11.32	8.96	7.6	4.19
Total lymphocytes (1–4x10e9/l)	0.68	0.73	0.5	0.88	1	1.79	1.56	1.66	1.23	1.31	1.02	1.78	2.56	2.1	1.31
Total monocytes (0.20–1x10e9/l)	0.13	0.36	0.41	0.88	1	1.23	1.36	1.11	1.16	1.08	0.64	1.19	1.16	0.81	0.65
D-Dimers (40–500 ng/ml)	NA	NA	NA	NA	NA	3620	3800	NA	4000	5660	7520	NA	NA	3070	NA
Fibrinogen (2–4 g/l)	NA	NA	NA	NA	NA	8.59	6.58	NA	6.23	5.68	6.12	NA	3.57	2.86	NA
Blood protein (64–83 g/l)	57	NA	53	56	55	61	NA	61	56	57	66	63	NA	68	68
Blood creatinine (64–104 µmol/l)	80	NA	NA	NA	NA	NA	NA	NA	60	NA	46	53	61	67	NA
Urea (3.2–7.4 µmol/l)	NA	NA	NA	9.9	10.3	11.1	NA	9.8	10.2	9.2	5.1	NA	NA	NA	NA
Creatine phosphokinase (30–200 UJ/l)	2999	1473	NA	415	602	NA	NA	NA	111	NA	NA	NA	NA	34	NA
Aspartate aminotransferase (5–34 UJ/l)	NA	55	NA	NA	45	NA	NA	NA	23	NA	NA	NA	13	NA	29
Gamma glutamyl transpeptidase (12–64 UJ/l)	NA	119	NA	109	110	90	NA	81	66	NA	NA	58	51	NA	35
Total bilirubin (5–21 UJ/l)	NA	NA	NA	NA	4	4	NA	NA	4	3	NA	NA	7	NA	7



**Figure 1. Dynamic profile of laboratory findings in patient with coinfection including SARS-CoV-2 and influenza H1N1.** RdRp: RNA-dependent RNA polymerases; N: envelope protein N; S: Spike protein; CpK: creatine phosphokinase; SARS-CoV-2: severe acute respiratory syndrome coronavirus-2; Mar: March; Apr: April; #: Total count. The values between parentheses (‘) in the ordinate axis correspond to the reference range values.

a preventive anticoagulant therapy (Enoxaparine 4000 IU /0.4ml once daily by SC injection) for three weeks. The CT scan control on April 30<sup>th</sup> 2020 revealed reduction of affection to less than 25% with appearance of more or less symmetrical, predominantly peripheral, bilateral pulmonary ground glass areas. The patient was integrated into the post COVID-19 rehabilitation program.

## Discussion

We report a case of coinfection with SARS-CoV-2 and seasonal influenza H1N1 in a French comorbid patient. The prolonged intensive care and detection of SARS-CoV-2 viral RNA on the bronchoalveolar sample for at least three weeks might be explained by the immunosuppression caused by lung polyinfection (viral, bacterial and fungal) and also by his medical history of pulmonary sarcoidosis with a restrictive ventilatory syndrome and obesity. Indeed, this disease was diagnosed in January 2019 and treated with corticosteroid therapy until December 2019, then in February 2020 under corticosteroids and methotrexate due to the relapse. The patient had a handicap of stage 2 exertional dyspnea according to Medical Research Council (MRC). The patient presented obesity as an additional comorbidity factor.

Bacterial coinfections in COVID-19 patients have been reported in several studies with a rate varying from less than 4% to 8% of bacterial/fungal co-infection cases with some bacterial infections frequently occurred in patients with prolonged hospitalization<sup>11,12</sup>. Meanwhile, clinicians should be vigilant for nosocomial bacterial infections<sup>12</sup>. Different studies have reported co-infection with SARS-CoV-2 and influenza viruses (A or B)<sup>1-9</sup>. According to a systematic review and meta-analysis of 3070 COVID-19 patients and 79 patients with concurrent COVID-19 and Influenza infections, the frequency of influenza virus co-infection among patients with COVID-19 was 4.5% and the prevalence of influenza infection was 0.8% in patients confirmed with COVID-19<sup>10</sup>. The overall of COVID-19

patients who had influenza co-infection was 1.2%. One other meta-analysis study revealed that co-infection with SARS-CoV-2 and influenza showed a high heterogeneity for overall mortality<sup>13</sup>. However, the relationship with the severity of COVID19 disease in the case of co-infection associated with one or more comorbidity factors such as diabetes, cardiovascular diseases, hypertension, malignancies, chronic obstructive pulmonary disease, and other comorbidities has been largely reported and could induce a life-threatening situation<sup>14-16</sup>. For example, the risk for ICU admissions in COVID-19 individuals with diabetic comorbidity is 14.2% higher than individuals without diabetes<sup>15</sup>. Cuadrado-Payán *et al.*<sup>5</sup> reported that all COVID-19 patients studied with medical history of hypertension, end-stage kidney disease, or type 2 diabetes attended the emergency unit<sup>5</sup>.

The co-detection of SARS-CoV-2 and Influenza H1N1 in our case with comorbidity factor the pulmonary sarcoidosis and obesity demonstrates the challenge to screen in the onset of the respiratory illness for a panel of viruses, which have overlapping clinical patterns and might exacerbate clinical symptoms, increase morbidity and prolong ICU stay. Hence, this case highlights the higher risk and poor outcomes caused by co-infection and the importance to achieve a differential diagnosis of respiratory distress syndromes specially in comorbid patients, to recommend seasonal influenza vaccination in addition of SARS-CoV-2 vaccine. It's necessary to adopt the vigilant preventive measure and therapeutic strategies to prevent a deleterious impact and health service demand on infected and comorbid individuals.

## Consent

Written informed consent was obtained from the patient for the publication of this article and any associated images.

## Data availability

All data underlying the results are available as part of the article and no additional source data are required.

## References

1. Wu D, Lu J, Ma X, *et al.*: **Coinfection of Influenza Virus and Severe Acute Respiratory Syndrome Coronavirus 2 (SARS-COV-2)**. *Pediatr Infect Dis J*. 2020; **39**(6): e79. [PubMed Abstract](#) | [Publisher Full Text](#) | [Free Full Text](#)
2. Wu X, Cai Y, Huang X, *et al.*: **Co-infection with SARS-CoV-2 and Influenza A Virus in Patient with Pneumonia, China**. *Emerg Infect Dis*. 2020; **26**(6): 1324-1326. [PubMed Abstract](#) | [Publisher Full Text](#) | [Free Full Text](#)
3. Ding Q, Lu P, Fan Y, *et al.*: **The clinical characteristics of pneumonia patients coinfecting with 2019 novel coronavirus and influenza virus in Wuhan, China**. *J Med Virol*. 2020; **92**(9): 1549-1555. [PubMed Abstract](#) | [Publisher Full Text](#) | [Free Full Text](#)
4. Khodamoradi Z, Moghadami M, Lotfi M: **Co-infection of Coronavirus Disease 2019 and Influenza A: A Report from Iran**. *Arch Iran Med*. 2020; **23**(4): 239-243. [PubMed Abstract](#) | [Publisher Full Text](#)
5. Cuadrado-Payán E, Montagud-Marrahi E, Torres-Elorza M, *et al.*: **SARS-CoV-2 and Influenza Virus Co-Infection**. *Lancet*. 2020; **395**(10236): e84. [PubMed Abstract](#) | [Publisher Full Text](#) | [Free Full Text](#)
6. Wehl G, Laible M, Rauchenzauner M: **Co-infection of SARS CoV-2 and influenza A in a Pediatric Patient in Germany**. *Klin Padiatr*. 2020. **232**(4): 217-218. [PubMed Abstract](#) | [Publisher Full Text](#)
7. Hashemi S, Safamanesh S, Ghafouri M, *et al.*: **Co-infection with COVID-19 and influenza A virus in two died patients with acute respiratory syndrome, Bojnurd, Iran**. *J Med Virol*. 2020; **92**(11): 2319-2321. [PubMed Abstract](#) | [Publisher Full Text](#) | [Free Full Text](#)
8. Stowe J, Tessier E, Zhao H, *et al.*: **Interactions between SARS-CoV-2 and influenza, and the impact of coinfection on disease severity: a test-negative design**. *Int J Epidemiol*. 2021; **50**(4): 1124-1133. [PubMed Abstract](#) | [Publisher Full Text](#) | [Free Full Text](#)
9. Jing R, Vunnam RR, Schnaubelt E, *et al.*: **Co-infection of COVID-19 and influenza A in a hemodialysis patient: a case report**. *BMC Infect Dis*. 2021; **21**(1): 68. [PubMed Abstract](#) | [Publisher Full Text](#) | [Free Full Text](#)
10. Dadashi M, Khaleghnejad S, Abedi Elkhichi P, *et al.*: **COVID-19 and Influenza Co-infection: A Systematic Review and Meta-Analysis**. *Front Med (Lausanne)*. 2021; **8**: 681469. [PubMed Abstract](#) | [Publisher Full Text](#) | [Free Full Text](#)
11. Rawson TM, Moore LSP, Zhu N, *et al.*: **Bacterial and Fungal Coinfection in Individuals with Coronavirus: A Rapid Review To Support COVID-19**

- Antimicrobial Prescribing.** *Clin Infect Dis.* 2020; **71**(9): 2459–2468.  
[PubMed Abstract](#) | [Publisher Full Text](#) | [Free Full Text](#)
12. Westblade LF, Simon MS, Satlin MJ: **Bacterial Coinfections in Coronavirus Disease 2019 (Review).** *Trends Microbiol.* 2021; **29**(10): 930–941.  
[Publisher Full Text](#)
  13. Guan Z, Chen C, Li Y, *et al.*: **Impact of Coinfection With SARS-CoV-2 and Influenza on Disease Severity: A Systematic Review and Meta-Analysis.** *Front Public Health.* 2021; **9**: 773130.  
[PubMed Abstract](#) | [Publisher Full Text](#) | [Free Full Text](#)
  14. Yang J, Zheng Y, Gou X, *et al.*: **Prevalence of comorbidities and its effects in patients infected with SARS-CoV-2: a systematic review and meta-analysis.** *Int J Infect Dis.* 2020; **94**: 91–95.  
[PubMed Abstract](#) | [Publisher Full Text](#) | [Free Full Text](#)
  15. Wang D, Hu B, Hu C, *et al.*: **Clinical characteristics of 138 hospitalized patients with 2019 novel coronavirus-infected pneumonia in Wuhan, China.** *JAMA.* 2020; **323**(11): 1061–1069.  
[PubMed Abstract](#) | [Publisher Full Text](#) | [Free Full Text](#)
  16. Ejaz H, Alsrhani A, Zafar A, *et al.*: **COVID-19 and comorbidities: Deleterious impact on infected patients.** *J Infect Public Health.* 2020; **13**(12): 1833–1839.  
[PubMed Abstract](#) | [Publisher Full Text](#) | [Free Full Text](#)

# Open Peer Review

Current Peer Review Status:  

---

## Version 2

Reviewer Report 03 May 2022

<https://doi.org/10.5256/f1000research.129014.r136555>

© 2022 Lansbury L. This is an open access peer review report distributed under the terms of the [Creative Commons Attribution License](#), which permits unrestricted use, distribution, and reproduction in any medium, provided the original work is properly cited.

 **Louise E. Lansbury** 

<sup>1</sup> Division of Epidemiology and Public Health, University of Nottingham, Nottingham, UK

<sup>2</sup> NIHR Nottingham Biomedical Research Centre, Nottingham, UK

Thank you for your satisfactory responses to my comments. I have no further comments to add.

**Competing Interests:** No competing interests were disclosed.

**Reviewer Expertise:** Respiratory pathogens

**I confirm that I have read this submission and believe that I have an appropriate level of expertise to confirm that it is of an acceptable scientific standard.**

---

## Version 1

Reviewer Report 20 July 2021

<https://doi.org/10.5256/f1000research.29738.r86503>

© 2021 Sadki K. This is an open access peer review report distributed under the terms of the [Creative Commons Attribution License](#), which permits unrestricted use, distribution, and reproduction in any medium, provided the original work is properly cited.

 **Khalid Sadki** 

Laboratory of Human Pathologies Biology, Faculty of Sciences, Mohammed V University, Rabat, Morocco

The work submitted by the authors is an interesting case report. They report a French patient co-infected by two severe viruses, SARS-CoV-2 and 2009 H1N1 Influenza strain.



The most important physical examination and diagnostic tests are reported in the case report. The methodology followed is well reported. However, data concerning the genetic investigations for both viruses is missed. It is recommended to discuss it, taking into consideration the specific phenotype observed in this case.

**Is the background of the case's history and progression described in sufficient detail?**

Yes

**Are enough details provided of any physical examination and diagnostic tests, treatment given and outcomes?**

Yes

**Is sufficient discussion included of the importance of the findings and their relevance to future understanding of disease processes, diagnosis or treatment?**

Partly

**Is the case presented with sufficient detail to be useful for other practitioners?**

Yes

**Competing Interests:** No competing interests were disclosed.

**Reviewer Expertise:** Immunology and immunogenetics

**I confirm that I have read this submission and believe that I have an appropriate level of expertise to confirm that it is of an acceptable scientific standard.**

Author Response 24 Mar 2022

**lekbir BAALA**, Centre Hospitalier Régional d'Orléans, 14 Avenu de l'Hôpital, Orléans, France

I am Dr. BAALA, a co-author of this article, I thank Pr. SADKI for his review and I am pleased to respond to his comments:

*We didn't give more details of the molecular data used for the SARS-CoV-2 and H1N1 tests since we were limited by the number of words not to be exceeded in the article. However, we may include some Ct data for SARS-CoV2 to indirectly indicate viral load kinetics.*

*As Pr Sadki and Pr Lansbury (first reviewer) suggested regarding the phenotype of the patient, the fact that the co-infection by SARS-Cov-2 and H1N1 viruses occurred in a patient with a history of pulmonary sarcoidosis, we will give more notice to the role of this immunosuppression history and poor outcome in the discussion.*

**Competing Interests:** No competing interests were disclosed.

Reviewer Report 21 June 2021

<https://doi.org/10.5256/f1000research.29738.r86504>

© 2021 Lansbury L. This is an open access peer review report distributed under the terms of the [Creative Commons Attribution License](#), which permits unrestricted use, distribution, and reproduction in any medium, provided the original work is properly cited.



**Louise E. Lansbury**

<sup>1</sup> Division of Epidemiology and Public Health, University of Nottingham, Nottingham, UK

<sup>2</sup> NIHR Nottingham Biomedical Research Centre, Nottingham, UK

In this case report, Baala *et al.* describe the clinical course of a patient with a history of pulmonary sarcoidosis who was co-infected with SARS-CoV-2 and influenza A (H1N1) virus and developed acute respiratory distress syndrome, requiring a prolonged ICU stay. The case is generally well-described and a useful reminder that the clinical presentation of SARS-CoV2 and influenza infections may overlap, and of the importance of the timely recognition of co-infection of SARS-CoV2 with other respiratory pathogens. However, the authors may wish to consider the following points:

**Abstract:**

- Please clarify the sentence: "Co-infection of SARS-CoV-2 and other respiratory syndrome has rarely been reported". Do you mean: "Co-infection with SARS-CoV2 and other respiratory pathogens"?
- Italicisation of 'respiratory distress syndrome' is not required (also italicised in the title)

**Introduction:**

- "To date, there is no published case with a co-infection between SARS-CoV-2 and influenza H1N1". This can no longer be claimed as there are now several reports of co-infections with these viruses from several countries.

**Case Report:**

- "The SARS-CoV-2 RT-PCR test was positive on March 22<sup>nd</sup> 2020." Is there information on the date of onset of symptoms in relation to the timing of this test?
- Did the patient receive the seasonal influenza vaccine prior to the 2019-2020 influenza season?
- Would it be possible to present the chest CT-scan?
- How many days had the patient been in ICU before *Candida albicans* and *Klebsiella pneumoniae* were first isolated?
- The authors indicate that an infection with *Enterococcus faecalis* infection was also treated; what was believed to be the source of this infection?

**Discussion:**

- As per the previous comment, this is no longer the first case report of a co-infection with SARS-CoV-2 and influenza A (H1N1). However, the fact that it occurred in a patient with a

history of pulmonary sarcoidosis is perhaps more original and may be worth emphasising more in the discussion (and perhaps also in the title?).

- The effect of SARS-CoV-2 and influenza co-infection on prognosis could perhaps be considered in a little more detail in the Discussion. The studies cited (Ding *et al.*, Cuadrado-Payán *et al.*) indicated that the clinical and analytic courses of their patients did not differ from patients infected only with SARS-CoV-2. However, other studies have suggested that co-infection may be associated with worse outcomes (e.g. see Stowe *et al.*<sup>1</sup> and Hashemi *et al.*<sup>2</sup>).

Overall, I believe the case study contributes to the literature on patients who are co-infected with SARS-CoV-2 and influenza as there are many uncertainties regarding these patients. I support indexing but would recommend the clarifications I have suggested are considered.

### References

1. Stowe J, Tessier E, Zhao H, Guy R, et al.: Interactions between SARS-CoV-2 and influenza, and the impact of coinfection on disease severity: a test-negative design. *Int J Epidemiol.* 2021. [PubMed Abstract](#) | [Publisher Full Text](#)
2. Hashemi S, Safamanesh S, Ghafouri M, Taghavi M, et al.: Co-infection with COVID-19 and influenza A virus in two died patients with acute respiratory syndrome, Bojnurd, Iran. *Journal of Medical Virology.* 2020; **92** (11): 2319-2321 [Publisher Full Text](#)

**Is the background of the case's history and progression described in sufficient detail?**

Yes

**Are enough details provided of any physical examination and diagnostic tests, treatment given and outcomes?**

Yes

**Is sufficient discussion included of the importance of the findings and their relevance to future understanding of disease processes, diagnosis or treatment?**

Partly

**Is the case presented with sufficient detail to be useful for other practitioners?**

Partly

**Competing Interests:** No competing interests were disclosed.

**Reviewer Expertise:** Respiratory pathogens

**I confirm that I have read this submission and believe that I have an appropriate level of expertise to confirm that it is of an acceptable scientific standard, however I have significant reservations, as outlined above.**

Author Response 18 Mar 2022

**Lekbir BAALA**, Centre Hospitalier Régional d'Orléans, 14 Avenu de l'Hôpital, Orléans, France

Dear All,

I'm Dr. Lekbir BAALA, the author of this article. I thank Dr. Louise E. Lansbury for her comments and I'm pleased to give answers below in italics.

**Abstract:**

• **Please clarify the sentence: "Co-infection of SARS-CoV-2 and other respiratory syndrome has rarely been reported". Do you mean: "Co-infection with SARS-CoV2 and other respiratory pathogens"?**

◦ *Yes, we mean co-infection with SARS-CoV2 and other respiratory pathogens. it's corrected.*

• **Italicisation of 'respiratory distress syndrome' is not required (also italicised in the title**

◦ *Ok, it was corrected.*

**Introduction:**

• **"To date, there is no published case with a co-infection between SARS-CoV-2 and influenza H1N1". This can no longer be claimed as there are now several reports of co-infections with these viruses from several countries.**

◦ *Yes, as we submitted our case report in December 2020, at that time no case with H1N1 and SARS-CoV-2 co-infection has been published in PUBMED, but now it is. We have changed the sentence.*

**Case Report:**

• **"The SARS-CoV-2 RT-PCR test was positive on March 22nd 2020." Is there information on the date of onset of symptoms in relation to the timing of this test?**

◦ *Yes, the PCR was positive on 22nd March 2020. The cough and fever had already been evolving for three to four days, which is what motivated screening (clinical investigation).*

• **Did the patient receive the seasonal influenza vaccine prior to the 2019-2020 influenza season?**

◦ *Not known as vaccinated against influenza.*

• **Would it be possible to present the chest CT-scan?**

◦ *We have obtained the chest CT Scan for the patient. The conclusion was: "Appearance of more or less symmetrical, predominantly peripheral, bilateral pulmonary ground glass areas compatible with Covid 19 type pneumopathy in the context of the epidemic...".*

• **How many days had the patient been in ICU before Candida albicans and Klebsiella pneumoniae were first isolated?**

◦ *Klebsiella pneumonia was isolated on the deep bronchial sample of March 28, 2020, so five days after his admission and mechanical ventilation, he was on C3G (ceftriaxone) empirically at that time.*

◦ *On the 14th day of admission (06/04/2020), Klebsiella pneumonia was found once again at  $10^6$  in a bronchoalveolar lavage which means the failure of treatment with imipenem, meropenem is then introduced. Also found in this bronchoalveolar lavage candidas albicans  $10^4$ .*

• **The authors indicate that an infection with Enterococcus faecalis infection was also**

**treated; what was believed to be the source of this infection?**

- *It is probably the digestive tract, the patient had presented abdominal pain, diarrhea, and vomiting which were attributed to poor tolerance of enteral nutrition. There was no specific digestive exploration because the evolution of this disorder was rapidly favorable.*

**Discussion:**

• **As per the previous comment, this is no longer the first case report of a co-infection with SARS-CoV-2 and influenza A (H1N1). However, the fact that it occurred in a patient with a history of pulmonary sarcoidosis is perhaps more original and may be worth emphasising more in the discussion (and perhaps also in the title?).**

- *We take into account this relevant remark on the prevalence. One meta-analysis (June 2021) of prevalence studies revealed that the frequency of influenza virus (A/B) co-infection among patients with COVID-19 was 4.5% in Asia, and 0.4 % from the American continent. This meta-analysis indicated that overall 1.2% of COVID-19 patients had influenza co-infection.*

- *We will add to the discussion the notion of the vulnerability of the immunocompromised (in our case sarcoidosis under methotrexate)*

• **The effect of SARS-CoV-2 and influenza co-infection on prognosis could perhaps be considered in a little more detail in the Discussion. The studies cited (Ding et al., Cuadrado-Payán et al.) indicated that the clinical and analytic courses of their patients did not differ from patients infected only with SARS-CoV-2. However, other studies have suggested that co-infection may be associated with worse outcomes (e.g. see Stowe et al.1 and Hashemi et al.2).**

- *Indeed the data in the literature are divergent, but a large series of patients are needed or a review of the literature is probably necessary to conclude. The recent review meta-analyses (June 2021) indicated that the outcomes of COVID-19-Influenza co-infection were reported in 11 studies with 2 of 29 patients who died (6.9%), and 17 out of 29 patients recovered (58.6%), but more studies are needed to evaluate the exact effect of SARS-CoV-2 and influenza co-infection on prognosis and clinical outcomes (Masoud Dadashi et al. 2021).*
- *The impact of co-infection with SARS-CoV-2 and influenza (H1N1) have been recently developed in animal models. For example, the sequential infection with H1N1 and SARS-CoV-2 aggravated COVID-19 pathogenesis in a mammalian model (Linlin Bao Signal Transduct Target Ther 2021). They conclude that co-infection with H1N1 and SARS-CoV-2 extended the duration of clinical manifestation of COVID-19, and enhanced pulmonary damage.*

**Competing Interests:** No competing interests were disclosed.

The benefits of publishing with F1000Research:

- Your article is published within days, with no editorial bias
- You can publish traditional articles, null/negative results, case reports, data notes and more
- The peer review process is transparent and collaborative
- Your article is indexed in PubMed after passing peer review
- Dedicated customer support at every stage

For pre-submission enquiries, contact [research@f1000.com](mailto:research@f1000.com)

**F1000Research**