

Expression of α -Smooth Muscle Actin in Liver Diseases

Eunsil Yu, M.D., Gheeyoung Choe, M.D., Gyungyub Gong, M.D.,
and Inchul Lee, M.D.

Department of Pathology, Asan Medical Center, College of Medicine, University of Ulsan
Seoul, Korea

To evaluate the distribution of α -smooth muscle actin (α -SMA) positive cells in various liver diseases, we undertook an immunohistochemical study of liver diseases including chronic persistent hepatitis, chronic active hepatitis, liver cirrhosis, intrahepatic cholelithiasis and hepatocellular carcinoma. As a control, fetal livers (gestational age: 22-26 weeks) showed α -SMA positive cells along the blood vessels of the portal area, terminal hepatic venules and at perisinusoidal spaces. Perisinusoidal α -SMA positive cells were bipolar shaped and had round nuclei. In chronic persistent hepatitis, a few α -SMA positive cells were admixed with the inflammatory infiltrates mostly along the intact limiting plate. They were also detected multifocally in a linear pattern along the dilated sinusoid. In chronic active hepatitis, very strong α -SMA staining was detected at the site of piecemeal necrosis and adjacent lobules. α -SMA expression was decreased in some cases after interferon treatment. In cases of transplanted liver biopsies, expression of intralobular α -SMA was diffusely increased but showed no correlation with degree of acute rejection. Cirrhotic livers revealed strong α -SMA positivity in fibrous septae as well as in the perisinusoidal space of intact hepatocytes at the leading edge of the fibrosis. Interlobular bile ducts were concentrically circumscribed by α -SMA positive cells in cases of intrahepatic cholelithiasis. In trabecular type hepatocellular carcinomas, most sinusoidal lining cells were positive for α -SMA. Most intralobular α -SMA positive cells represent, if not all, perisinusoidal cells (PSCs) which are involved in intralobular fibrogenesis in various liver diseases. It is suggested that intralobular expression of α -SMA may be reversible and correlate with the activity of necrosis and fibrosis in chronic liver diseases.

Key Words: α -smooth muscle actin, fibrosis, liver, perisinusoidal cells

INTRODUCTION

In cases of chronic liver disease, it is clinically important to predict disease activity and reversibility

Address for correspondence: Inchul Lee, Department of pathology, Asna Medical Center, College of Medicine, University of Ulsan 388-1 Poongnap-Dong, Songpa-Gu, Seoul 138-040, Korea. Tel: 82-02-480-3314, Fax: 82-02-484-2474

as early as possible. Among nonparenchymal cells of the liver, PSCs (fat storing cells or Ito cells) are known to play a major role in liver fibrogenesis (Minato et al., 1983; Ballardini et al., 1983; Friedman et al., 1985; Schmitt-Graff et al., 1991). They are positive for desmin in rats (Yokoi et al., 1984; Burt et al., 1986), and De Leeuw et al. (1984) showed that cultured fat storing cells contain collagen, vimentin, actin and tubulin. Although electron microscopy have been a specific method for detecting human perisinusoidal cells, α -SMA has also been identified in fat storing cells by cDNA

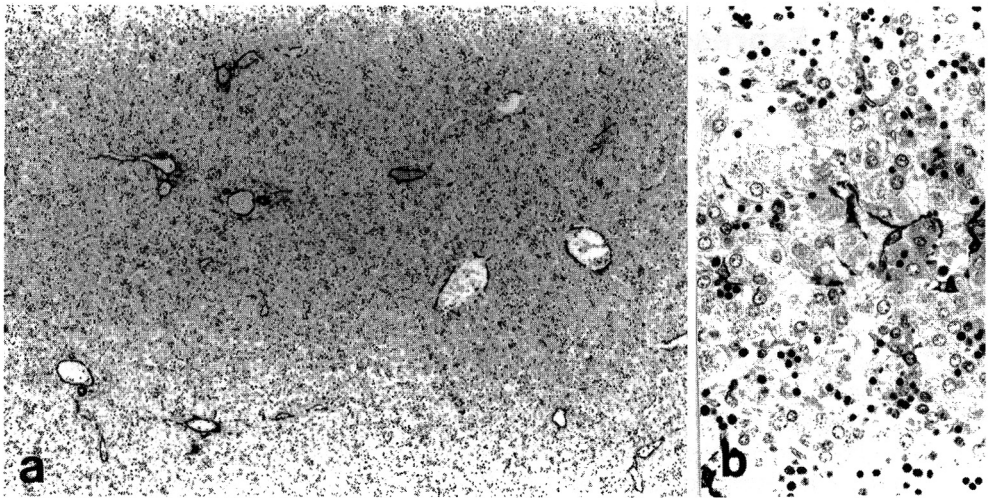


Fig. 1a. Fetal liver of 28 weeks gestational age: note α -SMA positive cells along the portal vein and hepatic artery. Terminal hepatic venules are continuously surrounded by α -SMA positive cells. There are many scattered intralobular α -SMA positive cells. (ABC, $\times 13.2$).

Fig. 1b. Intralobular α -SMA positive cells are located in the perisinusoidal space adjacent to hepatocyte. They are stellate shaped and have a round or ovoid nucleus with slender elongated cytoplasm. (ABC, $\times 60$).

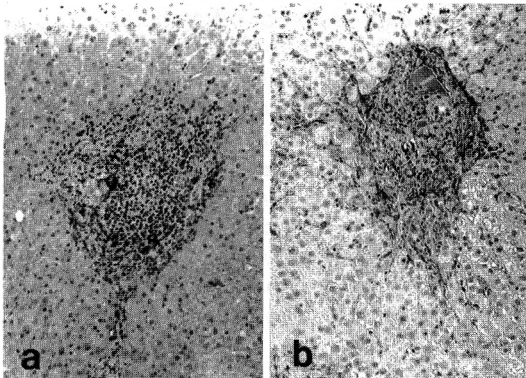


Fig. 2a. Chronic persistent hepatitis: note dense chronic inflammatory cell infiltration and a few α -SMA expressing cells within the portal space. (ABC, $\times 33$).

Fig. 2b. Chronic active hepatitis: increased numbers of α -SMA positive cells are seen at the site of piecemeal necrosis and adjacent hepatic lobule. (ABC, $\times 33$).

probe and monoclonal antibody (Ramadori et al., 1990). In addition there are morphological studies which have suggested the possibility that PSCs may evolve into myofibroblasts (Cenacchi et al., 1983; Mak et al., 1984). However it has not been established whether PSCs and myofibroblasts are separate cellular components or the latter is trans-

formed PSCs. Therefore α -SMA may be indicative of proliferation of the transformed PSCs or myoblastic participation within the hepatic lobules. In the present study, we examined the distribution of α -SMA positive cells in various liver diseases to evaluate the role of PSCs or myofibroblasts in hepatic fibrogenesis.

MATERIALS AND METHODS

Specimens were obtained by percutaneous needle biopsy or surgical resection. Fetal liver tissues were from autopsies. Specimens were fixed in 10% buffered formalin and embedded in paraffin. For immunohistochemistry, 4-6 μ m thick sections were cut from 10% formalin fixed and paraffin embedded specimens. Snap frozen tissues were used to compare immunohistochemical stainability with fixed tissues. Immunohistochemical staining was done following the avidin-biotin complex method with the ABC kit (Vector Laboratory, CA). We used monoclonal antibody against human α -SMA (diluted 1:50, DAKOPATTS, CA) and polyclonal antibody to factor VIII related antigen. For double immunofluorescent staining, monoclonal anti-human α -SMA antibody was followed by rhodamine conjugated anti-mouse IgG antibody, and polyclonal anti-Factor VIII related antigen anti-

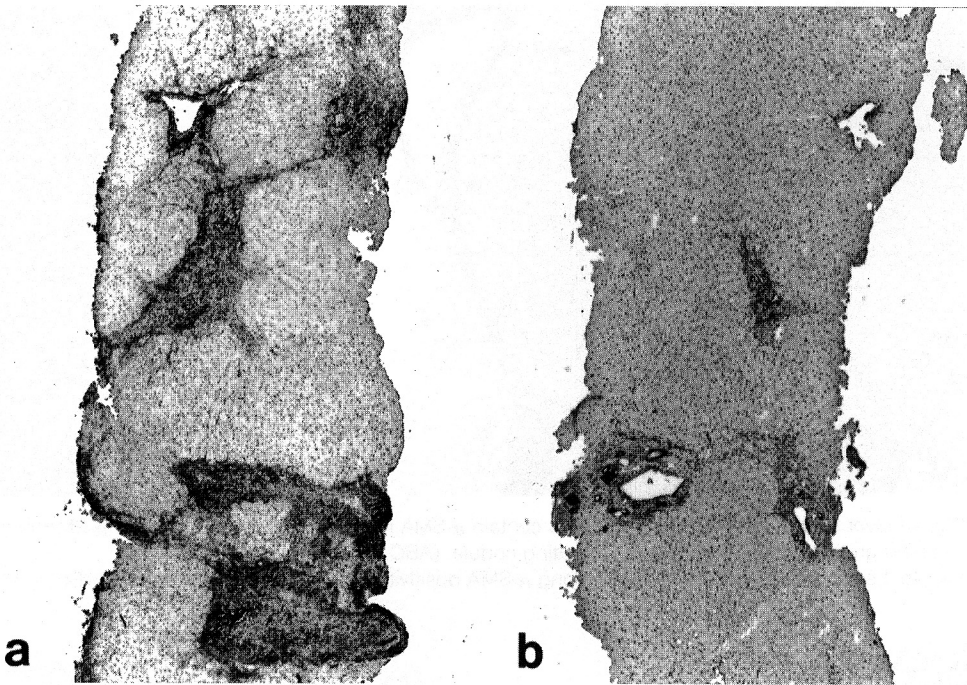


Fig. 3a & b. Serial liver biopsies of chronic active hepatitis treated with interferon: note marked decrease in α -SMA expressing cells after treatment (b).

body by FITC-conjugated anti-rabbit IgG antibody. Diagnoses were made on the basis of light microscopic findings and clinical information. Cases examined in this study included 4 normal fetal livers, 4 chronic persistent hepatitis, 21 chronic active hepatitis, 8 cirrhosis, 3 trasplanted livers (6 biopsies), 1 submassive hepatic necrosis, 2 intrahepatic cholelithiasis, and 9 hepatocellular carcinomas.

RESULTS

Fetal liver

α -SMA expressing cells were seen along the portal vein and hepatic arteries within the portal tracts (Fig. 1a). Presumptive terminal hepatic venules revealed discontinuous single layers of α -SMA positive cells. Within the lobules, bipolar shaped cells were irregularly scattered. They seemed to be tightly attached to hepatocytes. They have round nuclei in contrast to endothelial cells with flat nuclei (Fig. 1b). Numbers of α -SMA positive cells were variable but consistently present in normal human fetal livers. Hepatocytes or bile duct epithelia were all negative for α -SMA.

Chronic persistent hepatitis

Distribution of α -SMA positive cells was variable case by case, however they were consistently located in the portal areas, perivenular areas and adjacent perisinusoidal spaces. Within the portal areas, they were mainly located along the intact limiting plate (Fig. 2a). In addition, intralobular α -SMA expressing cells were seen in the areas of spotty necrosis.

Chronic active hepatitis

Very strong α -SMA expression was detected at the site of piecemeal necroses and adjacent hepatic lobules (Fig. 2b). The stainability showed good correlation with the severity of portal inflammation. Serial biopsies were done in 4 cases before and after interferon treatment. In one case, α -SMA expression was much more decreased along with prominent improvement of portal inflammation and fibrosis (Fig. 3a & b).

Cirrhosis

Along the complete thick fibrous septae, spindle cells were strongly and diffusely stained for α -SMA

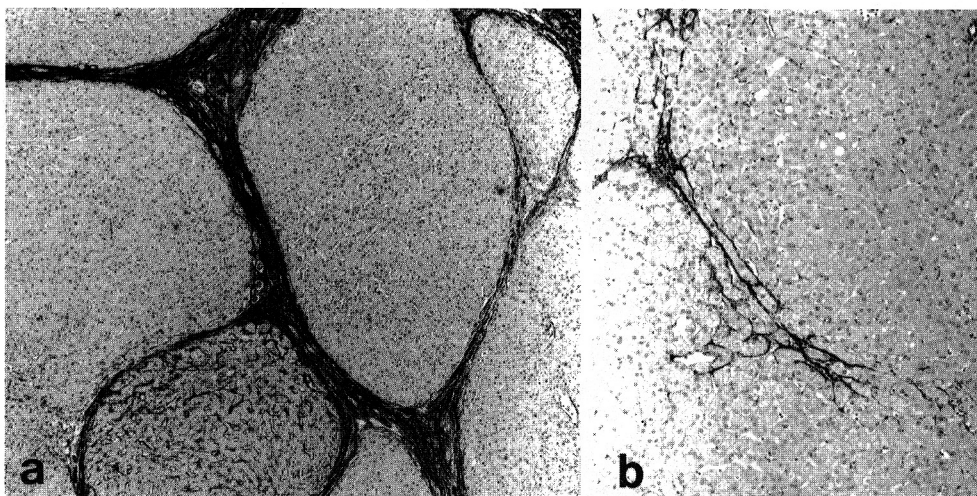


Fig. 4a Liver cirrhosis: dense fibrous bands contain α -SMA reactive cells. The number of α -SMA positive cells are increased within the regenerating nodule. (ABC, x 16).

Fig. 4b. Leading edge of fibrosis: note strong α -SMA positivity in the perisinusoidal space. (ABC, x 33).

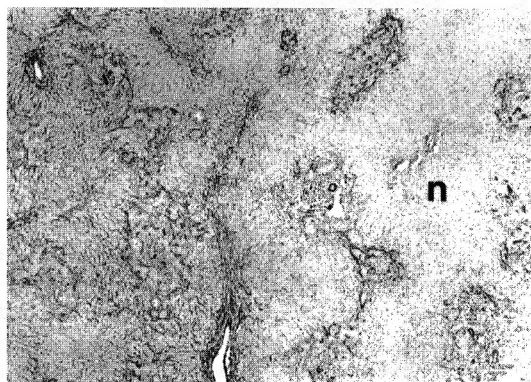


Fig. 5. Submassive hepatic necrosis: note prominent increase in α -SMA positive cells throughout the entire hepatic parenchyma in contrast to the necrotic area (n). (ABC, x 10).

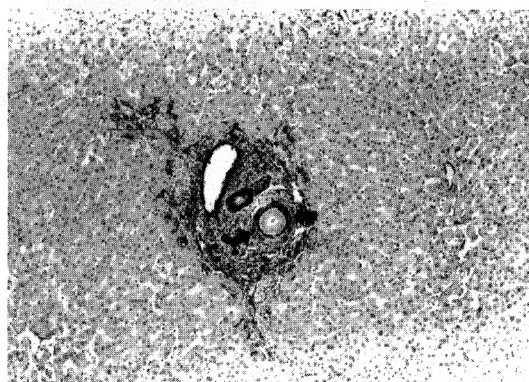


Fig. 6. Hepatolithiasis: concentrically proliferating peri-ductal stromal cells are immunoreactive for α -SMA (arrow). (ABC, x 33).

(Fig. 4a). Strong α -SMA positivity was revealed in the perisinusoidal spaces at the leading edge of the fibrosis where the hepatocytes were unremarkable by hematoxylin-eosin staining (Fig. 4b).

Transplanted liver

A case of hepatocellular carcinoma and two cases of macronodular cirrhosis were transplanted. Consecutive needle biopsies of the donor livers were done. Expression of intralobular α -SMA were diffusely increased and showed no correlation with degree of acute rejection. One case with no evi-

dence of rejection also showed diffuse increase of α -SMA expressing cells.

Submassive hepatic necrosis

α -SMA was not expressed within the areas of confluent necrosis. In contrast, the adjacent viable hepatic parenchyma revealed strong and diffuse α -SMA positivity (Fig. 5).

Hepatolithiasis and obstructive hepatopathy

Interlobular bile ducts were increased and were surrounded concentrically by spindle cells which

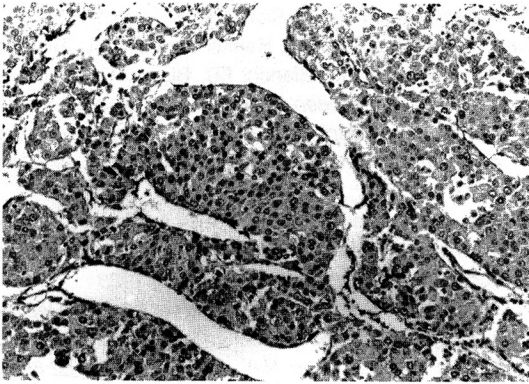


Fig. 7. Hepatocellular carcinoma: tumor trabeculae are discontinuously surrounded by flat α -SMA expressing cells. (ABC, x 66)

were strongly positive for α -SMA (Fig. 6).

Hepatocellular carcinoma

Nine cases of hepatocellular carcinoma were either trabecular or solid type of Edmondson grade II or III. In cases of the trabecular type of hepatocellular carcinoma, there was little or no stroma between trabeculae. Well developed sinusoids were lined mostly by spindle-shaped α -SMA-expressing cells (Fig. 7). Factor VIII related antigen-positive endothelial cells were rarely detected along the sinusoids. Neither α -SMA nor factor VIII related antigen coexpressing cells were seen by double immunofluorescent staining.

DISCUSSION

Among four nonparenchymal cells, PSCs located in the spaces of Disse are generally regarded as the adventitial connective cells and have also been likened to the contractile myofibroblasts of granulation tissue. PSCs have been reported to express desmin, a marker of smooth muscle-related cells in rats. Because muscle actins (Carroll et al. 1986) are more specific markers for muscle differentiation than desmin and are expressed in myofibroblasts, α -SMA was applied as a phenotypic marker for PSCs. Schmitt-Graff et al. (1991) displayed anti- α -SMA labelling of microfilament bundles in fat storing PSCs.

In the fetal liver, perivenular α -SMA positive cells are either PSCs or pericytes. Location of α -SMA positive cells between hepatocytes and the sinusoidal spaces and their round nucleus with bipolar

cytoplasmic processes suggest that α -SMA expressing cells represent, if not all, PSCs rather than endothelial cells or Kupffer cells. α -SMA expressing cells were consistently distributed in fetal liver, whereas this phenotype is rare in normal adult liver tissue. These findings suggest that cytoskeletal composition of PSCs may be modulated during development.

Population of α -SMA expressing PSCs is variable according to the pathologic conditions and they are mainly associated with inflammatory reaction, such as spotty necroses or piecemeal necroses in cases of hepatitis. In a case of submassive hepatic necrosis, the adjacent viable hepatic parenchyma revealed strong α -SMA positivity as well as prominent increase of activated Kupffer cells, which may suggest that they can be activated by Kupffer cell derived factors or various cytokines such as IL-1, TGF- β 1 and TNF (Cazja et al., 1989; Sporn et al., 1987; Weiner et al., 1990). PSCs isolated from rat liver with alcoholic fibrogenesis are activated to produce more collagen by Kupffer cell-derived factors compared to PSCs from normal livers (Matsuoka et al., 1989).

Hepatic fibrogenesis can be associated with many pathologic conditions with preceding parenchymal necrosis. Nonparenchymal cells, especially PSCs are now generally considered to play an important role of collagen synthesis in normal and fibrotic liver (Friedman et al., 1985; Milani et al., 1989; Milani et al., 1990). Thus increase of α -SMA in the areas of hepatocytic necroses may be closely related with fibrogenesis. Severity as well as irreversibility of fibrosis may have a clinical impact on patient's prognosis. The occurrence of α -SMA expressing cells is easily seen at a stage of disease earlier than overt hepatic fibrosis as in the cases of acute allograft rejection and leading edge of precirrhotic liver. Furthermore because expression of α -SMA in PSCs precedes extracellular deposit of collagen fibers, immunohistochemical staining for α -SMA is a more sensitive tool to detect early fibrogenesis. However intensity and number of intralobular α -SMA positive cells were not always correlated with the severity of fibrosis. We can not exclude that among α -SMA expressing cells, those in capsule or fibrous septae surrounding regenerating nodules originate from pre-existing fibroblastic cells as well as from smooth muscle cells or pericytes because they also reveal desmin as well as α -SMA.

In hepatolithiasis, concentric proliferation of spindle cells especially around interlobular bile ducts

is a characteristic feature. They were strongly immunostained for α -SMA. Therefore α -SMA expressing periductal mesenchymal cells in cases of hepatolithiasis may correspond to myofibroblasts of granulation tissue rather than PSCs.

In cases of the trabecular type hepatocellular carcinomas, well developed sinusoids were lined by flat spindle cells which have been known as endothelial cells (Anthony, 1987). However in this study, most sinusoidal lining cells of hepatocellular carcinomas were strongly positive for α -SMA. There are two possibilities that sinusoidal lining cells of hepatocellular carcinoma are PSCs or modified endothelial cells expressing α -SMA. Endothelial cells can coexpress a specific endothelial cell marker (Banceiraea simplicifolia) as well as α -SMA protein and mRNA in culture condition with depletion of heparin and ECGF (Amberger et al., 1991). However we could not detect coexpression of α -SMA and Factor VIII related antigen by double immunofluorescent staining (data not published). These findings indicate that most sinusoidal lining cells may be PSCs rather than endothelial cells.

REFERENCES

- Amberger A, Bauer H, Tontsch U, Gabbiani G, Kocher O, Bauer HC: *Reversible expression of sm alpha-actin protein and sm alpha-actin mRNA in cloned cerebral endothelial cells. Febs Letters 287:223-225, 1991*
- Anthony PP: *Tumors and tumor-like lesions of the liver and biliary tract. in MacSween RNM, Anthony PP, Scheuer PJ(eds): Pathology of the liver(ed2). Edinburgh London Melbourne and New York. Churchill livingstone. 1987, p.607*
- Ballardini G, Degli Esposti S, Bianchi FB, Badiali De Giorgi L, Faccani A, Biolchini L, Busachi CA, Pisi E: *Correlation between Ito cells and fibrogenesis in an experimental model of hepatic fibrosis. A sequential stereological study. Liver3:58-63, 1983*
- Burt AD, Robertson JL, Heir J, MacSween RNM: *Desmin-containing stellate cells in rat liver; distribution in normal animals and response to experimental acute liver injury. J Pathol 150:29-35, 1986*
- Carroll SL, Bergsma DJ, Schwartz RJ: *Structure and complete nucleotide sequence of the chicken a-smooth muscle (aortic) actin gene. J Biol Chem 216: 8965-8976, 1986*
- Czaja MJ, Weiner FR, Flanders KC, Giambrome M-A, Wind R, Biempica L, Zern MA: *In vitro and in vivo association of transforming growth factor-beta₁ with hepatic fibrosis. J Cell Biol 108:2477-2482, 1989*
- Cenacchi G, Ballardini G, Badiali De Giorgi L, Busachi CA, Del Rosso M, Bianchi FB, Biagini G, Laschi R: *Relationship between connective tissue cells and fibronectin in a sequential model of experimental hepatic fibrosis. Virchows Arch (Cell Pathol) 43:75-84, 1983*
- De Leeuw AM, McCarthy SP, Geerts A, Knook DL: *Purified rat liver fat-storing cells in culture divide and contain collagen. Hepatology 4:392-403, 1983*
- Friedman S, Roll FJ, Boyles J, Bissel DN M: *Hepatic lipocytes: the principal collagen-producing cells of normal rat liver. Proc Natl Acad Sci USA 82:8681-8685, 1985*
- Mak K, Leo MA, Lieber CS: *Alcohol liver injury in baboons: transformation of lipocytes to transitional cells. Gastroenterology 87:188-200, 1984*
- Matsuoka M, Pham NT, Tsukamoto H: *Differential effects of inteleukin-1 α , tumor necrosis factor α , and transforming growth factor b1 on cell proliferation and collagen formation by cultured fat-storing cells. Liver 9: 71-78, 1989*
- Milani S, Herbst H, Schuppan D, Hahn EG, Stein H: *In situ hybridization for procollagen types I, III and IV mRNA in normal and fibrotic rat liver; Evidence for prominent expression in nonparenchymal liver cells. Hepatology 10:84-92, 1989*
- Milani S, Herbst H, Schuppan D, Kim KY, Riecken EO, Stein H: *procollagen expression by nonparenchymal rat liver cells in experimental biliary fibrosis. Gastroenterology 98:175-184, 1990*
- Minato Y, Hasumura Y, Takeuchi J: *The role of fat storing cells in Disse space fibrogenesis in alcoholic liver disease. Hepatology 3:559-566, 1983*
- Ramadori G, Veit T, Schwogler S, Dienes HP, Knittel T, Rieder H, Meyer zum Buschenfelde KH: *Expression of the gene of the a-smooth muscle-actin isoform in rat liver and in rat fat-storing (ITO) cells. Virch Arch Cell Pathol (B) 59:349-357, 1990*
- Schmitt-Graff A, Kruger S, Bocharo F, Gabbiani G, Denk H: *Modulation of alpha smooth muscle actin and desmin expression in perisinusoidal cells of normal and diseased human livers. Am J Pathol 138:1233-1242, 1991*
- Solis-Herruzo JA, Brenner DA, Chojkier M: *Tumor necrosis factor a inhibits collagen gene transcription and collagen synthesis in cultured human fibroblasts. J Biol Chem 263:5841-5845, 1988*
- Sporn MB, Roberts AB, Wakefield LM, de Crombughe B: *Some recent advances in the chemistry and biology of transforming growth factor-beta. J Cell Biol 105: 1039-1045, 1987*
- Tsutsumi M, Takada A, Takase S, Yasuhara M, Matsuda

- Y: Characterization of isolated and cultured fat-storing cells of rat livers. In: Kirn A, Knook DL, Wisse E (eds) Kupffer cell foundation, Cells of the hepatic sinusoid 1:264-264, 1986
- Weiner FR, Giambone M-A, Czaja MJ, Shah A, Giorgio A, Shizuko T, Eghbali M, Zern MA: Ito-cell gene expression and collagen regulation. *Hepatology* 11:111-117, 1990
- Yokoi Y, Namihisi T, Kuroda H, Komatsu I, Miyazaki A, Watanabe S, Usui K: Immunocytochemical detection of desmin in fat-storing cells (Ito cells). *Hepatology* 4: 709-714, 1984