



# The Multiple V-Y Advancement Modification for the Surgical Correction of Cryptotia

Nguyen Quang Duc, MD, PhD<sup>1</sup> Nguyen Phuong Tien, MD<sup>1</sup>

<sup>1</sup>Center for Craniofacial and Plastic Surgery, 108 Military Central Hospital, Hanoi, Vietnam

Arch Plast Surg 2023;50:26–29.

Address for correspondence Nguyen Quang Duc, MD, PhD, Center for Craniofacial and Plastic Surgery, 108 Military Central Hospital, 1 Tran Hung Dao Street, Hanoi 11610, Vietnam (e-mail: drduc108@gmail.com).

## Abstract

Cryptotia is a rare congenital auricular deformity among Caucasians but more common in Asians. Various operative techniques have been described, such as skin graft, V-Y plasty, Z plasty, and islands skin flap. Among those techniques, V-Y plasty has many advantages and is indicated for severe cases. However, several problems remain when this method is adopted, such as conspicuous scars and lowered hairline. To overcome these problems, the authors have developed a new technique, multiple V-Y advancement modification, which stitches the skin flaps together to a tight, discrete central focal point. This technique has the advantage of hiding scars behind the earlobe, providing enough skin for the deformed areas, minimizing the condition of the hairline being lowered and auriculocephalic sulcus depth.

## Keywords

- ▶ auricular
- ▶ multiple V-Y
- ▶ cryptotia
- ▶ advancement flap

## Introduction

Cryptotia is a relatively common congenital auricular deformity in Asians but rare in Caucasians. The characteristic anatomic feature of cryptotia is the invagination of the superior half of the auricle under the temporal skin.<sup>1</sup> With this deformity, the buried portion can be pulled out by hand, but it falls back into the skin again if released. Patients have difficulty wearing glasses and masks, which affect aesthetics. Treatment goals can be summarized as follows: (1) restoration of the auriculocephalic sulcus, (2) replacement of the deficient skin flap to cover embedded cartilage, (3) establishment of collapsed cartilage, and (4) release of abnormal intrinsic auricular muscles.

Various operative techniques have been described, such as Z plasty, skin graft, and local skin flap, among which V-Y advancement has been effectively applied in all cases of cryptotia. Despite its many advantages, the disadvantages of V-Y advancement are the development of a visible scar and a lowered hairline. In this study, we introduce a new tech-

nique: Multiple V-Y plasty advancement modification or using multiple consecutive V-Y flaps in the postauricular area. This advancement can overcome the disadvantages of the previous V-Y technique, such as a visible scar and a lowered hairline but still retain the inherent advantages.

## Idea

The main disadvantage of the previous V-Y technique is that the V-flap must be long and wide enough for skin supplementation. Therefore, the correction of cryptotia using the technique is mainly designed for the hair-bearing scalp area. After the flap slides down to create auriculocephalic sulcus, the area where the flap is taken leaves a scar. This scar area can be covered by hair, but most of it is still exposed, affecting the aesthetics. The temporal triangular flap has hair, so when it slides down, the hairline is lowered. Our idea was to use multiple small consecutive V-Y flaps with short incisions in the retroauricular region to limit scarring while not lowering the hairline (▶ **Fig. 1**).

received

May 27, 2022

accepted after revision

October 13, 2022

DOI <https://doi.org/10.1055/a-1962-6784>.

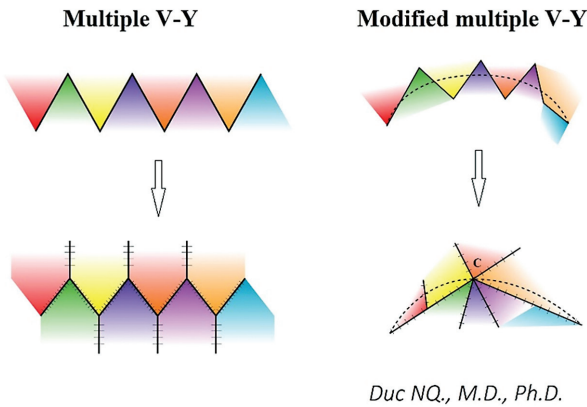
10.1055/a-1962-6784.

eISSN 2234-6171.

© 2023. The Korean Society of Plastic and Reconstructive Surgeons. All rights reserved.

This is an open access article published by Thieme under the terms of the Creative Commons Attribution-NonDerivative-NonCommercial-License, permitting copying and reproduction so long as the original work is given appropriate credit. Contents may not be used for commercial purposes, or adapted, remixed, transformed or built upon. (<https://creativecommons.org/licenses/by-nc-nd/4.0/>)

Thieme Medical Publishers, Inc., 333 Seventh Avenue, 18th Floor, New York, NY 10001, USA

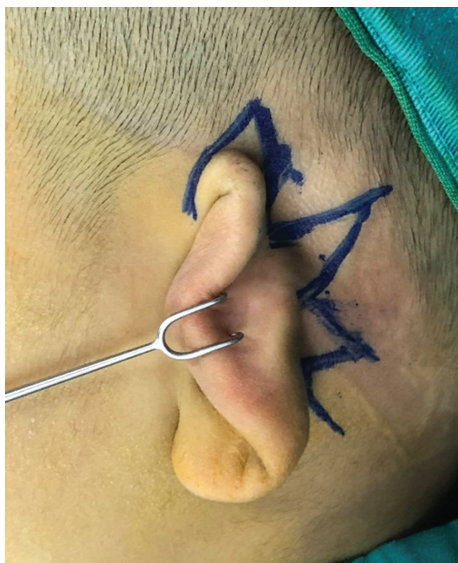

**Fig. 1** Diagram to illustrate multiple V-Y and modified multiple V-Y. The flaps were sutured together to a discrete central focal point (C point). The dashed line is the expected auriculocephalic sulcus.

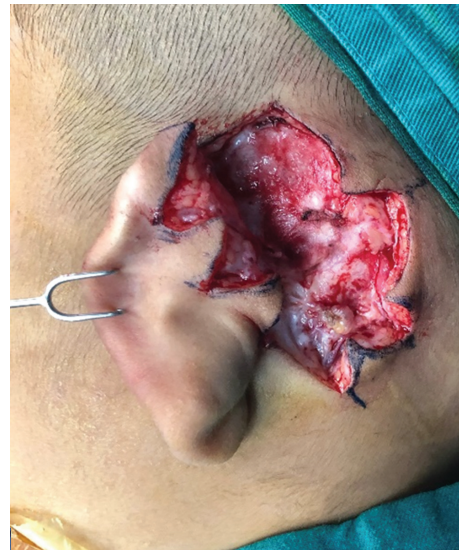## Surgical Steps

### Patients Receive General Anesthesia

1. Skin incision design: The buried portion is pulled out by hand, and the position of the auriculocephalic sulcus is drawn. A zig-zag line is designed in the temporal skin and superior skin of the auricle. The zig-zag line is created by three consecutive V-Y flaps that are not on a straight line but on a curve (position of auriculocephalic). The beginning point of the line is in the skin of the anterior part of the buried portion of the superior helix. The posterior point is the endpoint of the auriculocephalic sulcus fissure to be reconstructed (►Fig. 2).
2. Skin incision and flap dissection: Before skin incision, physiologic saline to which epinephrine had been added is injected into the auricle to reduce bleeding. The triangular flaps are elevated from the temporal scalp above the superficial temporal fascia level and slid to both sides (►Fig. 3). Abnormal intrinsic auricular muscles in the



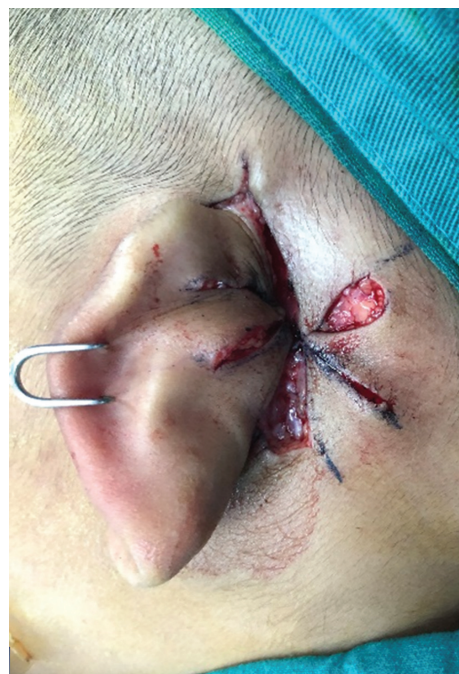**Fig. 2** Skin incision design.



**Fig. 3** Surgical skin incision of triangular flaps. Abnormal intrinsic auricular muscles were removed.

- cartilage are removed, and cartilage deformities are fixed with autogenous cartilage grafting if necessary.
3. Stitch closure: The skin flaps are sutured together to a central focal point (C Point) located in the auriculocephalic sulcus (►Fig. 4). Nylon 5.0 sutures are used to stitch the subcutaneous organization of the flap edge with cartilage to deepen the auriculocephalic sulcus. The skin incisions were closed with Vicryl 5.0 and the outer layer with Nylon 6.0 sutures. Sutures were cut after 7 days of operation.

The authors have received written consent from the patient's parents for permission to use the images.



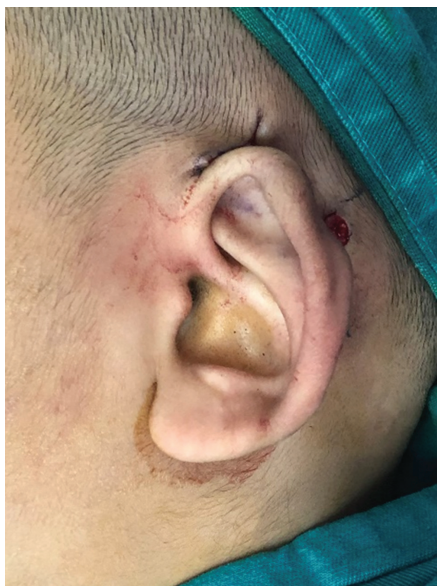**Fig. 4** The flaps were sutured together to a discrete central focal point. The subcutaneous tissues were sutured to the cartilage to form the auriculocephalic sulcus.

## Discussion

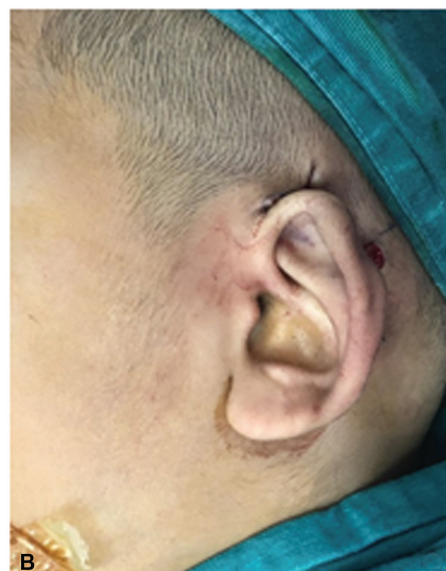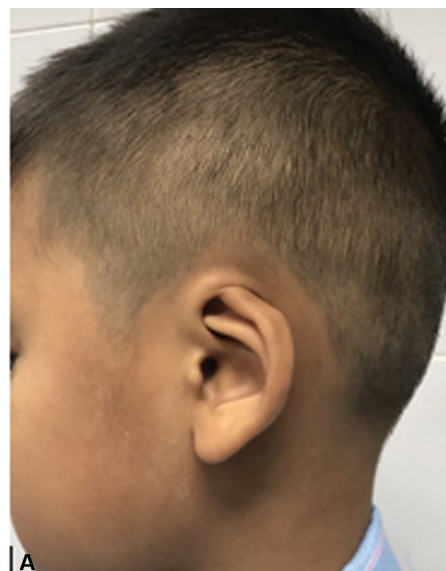Many operative methods to treat malformations have been reported, such as skin graft,<sup>2</sup> subcutaneous pedicled flap,<sup>3</sup> Z plasty,<sup>4</sup> local rotation flap,<sup>5</sup> and V-Y plasty.<sup>6</sup> Each method has its advantages and disadvantages with respect to skin flap deficiencies. Among these methods, the V-Y flap is said to have many advantages in recreating cryptotia from mild-to-severe cases. The application of the V-Y advancement flap to treat cryptotia was first reported by Kubo and then improved by many other authors for better effectiveness.<sup>3,7-9</sup> Cho and Han have summarized and briefly outlined the characteristics of the V-Y flap as follows: (1) simple, straightforward design and a short operation time; (2) provision of enough skin to the upper and posterior portions of the auricle; (3) provision of sufficient depth of auriculocephalic sulcus; (4) correction of cartilage deformities with unrestricted access; (5) no need for additional skin grafting; (6) applicable for other ear deformities including constricted ear; (7) visible scarring at the donor site; and (8) lowered hairline created by advancement of the temporal triangular flap.

The problems of adopting the V-Y technique were the development of a visible scar on the temporal skin and lowered hairline, which have not been effectively solved with any measures. Therefore, we propose the multiple V-Y advancement modification to enhance the cryptotia treatment techniques further. Multiple Y-V flaps were first used by Bier et al in 1922 for the treatment of soft tissue defects or stretch marks caused by burns.<sup>10</sup> We improved this technique for reconstructing cryptotia by creating maximal sliding flaps and suturing the postauricular triangular flaps together to a discrete central focal point. With this technique, we have found the following advantages:

- Triangular flaps are designed in the retroauricular region, so the scar is less visible as it is located in the retroauricular region (→Fig. 5).



**Fig. 5** After suturing the incision. The scar was located in the retroauricular region so it is less visible.



**Fig. 6** Preoperative (A), immediate postoperative (B), and 4-year postoperative (C) views of a patient.

- The skin flaps are small and not located in the hair-bearing scalp, so the hairline is not lowered.
- Multiple V-Y flaps and maximum sliding flaps are used so more skin could be mobilized to cover the cartilage, and no skin grafting was required.
- There was a scar line in the auriculocephalic sulcus, ensuring the depth of the auriculocephalic sulcus. Scars were fixed, reducing the possibility of recurrence.
- Long and low skin incision facilitated easy access and repair of cartilage deformities.

A high percentage of cryptotia patients presents cartilage adhesion malformations.<sup>11</sup> Depending on the deformations of auricular cartilage, the surgery was performed to remove the fibrous fascia or thin muscle layer, a piece of conchal cartilage was harvested and fixed to the postauricular cartilage where the released space was widened for correction and creation of the curve of antihelical fold.

According to Cho et al, the conchal cartilage was used in mild cases; Medpor sheet was used in severe cases to the posterior aspect of the corrected sharply curved antihelical crus for preventing relapse as a splinting.<sup>4</sup>

From 2018 to 2022, six cryptotia patients were treated by multiple V-Y advancement modification including five male and one female. Two patients had bilateral and four patients had unilateral cryptotia.

This technique has shown high efficiency. On long-term follow-up postoperatively, there were no complications such as skin necrosis, infection, cartilage inflammation, or recurrence (► **Fig. 6**). However, there was one patient with hypertrophic scar.

The disadvantage of the technique is that the design is more complicated than the V-Y technique, but due to the elasticity of the skin, the design line is flexible and does not require strict precision.

#### Patient Consent

The patient provided written informed consent for the publication and the use of his images.

#### Authors' Contribution

Conceptualization: N.Q.D. Data curation: N.Q.D. Writing-original draft: N.Q.D. and N.P.T. Writing-review & editing: N.Q.D. and N.P.T.

#### Ethical Approval

Ethical approval was obtained from institutional review board of local faculty and the participating hospital.

#### Conflict of Interest

None declared.

#### References

- 1 Paredes AA Jr, Williams JK, Elsayh NI. Cryptotia: principles and management. *Clin Plast Surg* 2002;29(02):317-326
- 2 Nishimura Y. Correction of cryptotia (pocket ear). *Jpn J Plast Reconstr Surg* 1975;18:696-698
- 3 Yotsuyanagi T, Yamashita K, Shinmyo Y, Yokoi K, Sawada Y. A new operative method of correcting cryptotia using large Z-plasty. *Br J Plast Surg* 2001;54(01):20-24
- 4 Cho YK, Bae SG, Cho BC. Comparison between Z-plasty and V-Y advancement for the surgical correction of cryptotia. *Arch Craniofac Surg* 2014;15(01):7-13
- 5 Uemura T, Matsumoto N, Tanabe T, Saitoh T, Matsushita S, Mitsukawa N. Surgical correction of cryptotia combined with intraoperative distention using isotonic saline injection and rotation flap method. *J Craniofac Surg* 2005;16(03):473-476
- 6 Kubo I. Cryptotia and otoplasty. *Jpn Otorhinolaryngology* 1993; 6:105-109
- 7 Cho BC, Han KH. Surgical correction of cryptotia with V-Y advancement of a temporal triangular flap. *Plast Reconstr Surg* 2005;115(06):1570-1581
- 8 Kim YS. Correction of cryptotia with upper auricular deformity: double V-y advancement flap and cartilage strut graft techniques. *Ann Plast Surg* 2013;71(04):361-364
- 9 Nakajima T, Yoneda K, Yoshimura Y. Correction of cryptotia using a subcutaneous pedicled flap. *Br J Plast Surg* 1991;44(06): 406-409
- 10 Cooper MA. The multiple Y-V plasty in linear burn scar contraction release. *Br J Plast Surg* 1990;43(02):145-149
- 11 Park C. Upper auricular adhesion malformation: definition, classification, and treatment. *Plast Reconstr Surg* 2009;123(04): 1302-1312