



Case Report

Ictal conduction aphasia and ictal angular gyrus syndrome as rare manifestations of epilepsy: The importance of ictal testing during video-EEG monitoring



Johann Philipp Zöllner^{a,*}, Anja Haag^{b,c}, Anke Hermsen^a, Sebastian Bauer^{a,b}, Friederike Stahl^a, Karina Wulf^b, Katja Menzler^b, Philipp S. Reif^a, Marlies Wagner^d, Axel Pagenstecher^e, Ulrich Sure^f, Susanne Knake^b, Felix Rosenow^{a,b}, Adam Strzelczyk^{a,b}

^a Department of Neurology and Epilepsy Center Frankfurt Rhine-Main, Goethe-University, Frankfurt am Main, Germany

^b Department of Neurology and Epilepsy Center Hessen, Philipps-University, Marburg, Germany

^c Vitos Clinical Center for Psychiatry and Psychotherapy, Giessen-Marburg, Germany

^d Institute of Neuroradiology, Goethe-University, Frankfurt am Main, Germany

^e Department of Neuropathology, Philipps-University, Marburg, Germany

^f Department of Neurosurgery, University Hospital Essen, Germany

ARTICLE INFO

Article history:

Received 15 June 2017

Received in revised form 20 July 2017

Accepted 30 July 2017

Available online 03 August 2017

Keywords:

Seizure

Gerstmann's syndrome

Semiology

Acalculia

Left–right disorientation

ABSTRACT

The aim of these two case reports is to demonstrate that a predefined, structured, multimodal clinical bed-side testing during seizures in a long-term video-EEG monitoring setting facilitates diagnosis of complex neuropsychological syndromes. To the best of our knowledge, we present the first case of conduction aphasia as the sole ictal semiology, and a patient with focal seizures producing an angular gyrus syndrome in the speech dominant hemisphere. The relevance of diagnosing ictal aphasic and angular gyrus syndromes and localizing the symptomatogenic zone is discussed. Current pathophysiological concepts are presented regarding conduction aphasia and Gerstmann's syndrome.

© 2017 The Authors. Published by Elsevier Inc. This is an open access article under the CC BY-NC-ND license (<http://creativecommons.org/licenses/by-nc-nd/4.0/>).

1. Introduction

Bed-side clinical evaluation of seizures during long-term video-EEG monitoring is performed not only to ensure patient's safety during a seizure but also to gain important clinical knowledge of the seizure semiology. Many clinical aspects cannot be adequately assessed without interacting with the patient. Salient examples of this are speech disturbances, which often do not present spontaneously. Thus, the extent of ictal testing plays a significant role in recognizing all potential ictal symptoms. With these two case presentations, we aim to illustrate the effectiveness of a structured ictal testing procedure in elucidating complex neuropsychological dysfunction and to give an outline for a concise ictal speech testing scheme.

2. Case report A

A 58-year-old patient with a history of seizures since the age of 31 presented for presurgical evaluation. Drug-resistant epilepsy with unspecific auras and seizures included speech disturbance that he could not define explicitly. Long-term video-EEG monitoring revealed left temporal sharp waves, with a maximum at the left sphenoidal electrode (Sp1). On discontinuation of anti-seizure medication, two seizures with a left temporal EEG onset at left sphenoidal electrode were recorded (Fig. 1). Detailed ictal testing revealed solely a conduction aphasia, as the patient was not able to repeat given sentences. During the seizure there was no sign of motor ("Broca's") or sensory ("Wernicke's") aphasia as he was able to follow commands, correctly answer questions and read and name presented objects (Table 1). On MRI a left lateral temporal cystic structure was present without signs of hippocampal sclerosis (Fig. 2). Functional MRI and functional transcranial Doppler sonography confirmed a left sided language lateralization (Fig. 3). A diagnosis of left neocortical temporal lobe epilepsy was established and epilepsy surgery offered. The patient underwent a lesionectomy without extra- or

* Corresponding author at: Department of Neurology, J.W. Goethe-University Frankfurt, Schleusenweg 2-16, Haus 95, 60528 Frankfurt am Main, Germany.

E-mail address: johannphilipp.zoellner@kgu.de (J.P. Zöllner).

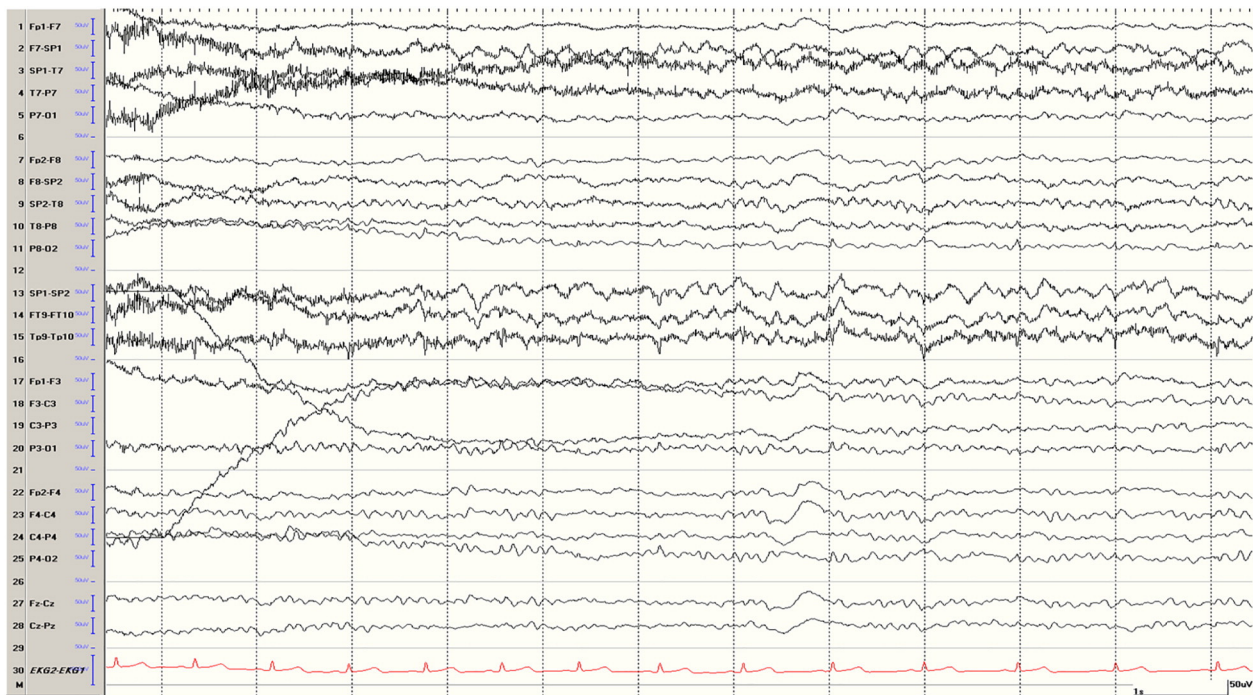


Fig. 1. EEG showing a left temporal seizure pattern with a maximum at the left sphenoidal electrode (Sp1) during ictal conduction aphasia in case A [10–20 bipolar montage].

intraoperative language mapping. Histologic examination revealed the lesion to be an epidermoid cyst (Fig. 4). The patient is now seizure-free (ILAE 1, Engel Ia) for more than six years and had no post-operative speech deficits.

3. Case report B

A 44-year-old patient with a history of episodes comprising a visual aura and a subsequent headache since resection of a left sided tentorial meningioma at the age of 36 presented for differential evaluation. Prior to his presentation at our hospital, these episodes had been diagnosed as migraine with visual aura. However, strict localization of the visual phenomena to the right upper quadrant and the absence of vegetative symptoms as well as no phono- or photophobia during the episodes suggested the possibility of epileptic seizures. In addition, the patient described paroxysmal episodes of a few minutes duration during which he experienced a difficulty in finding the correct words and

was also unable to read words or sentences. Long-term video-EEG monitoring revealed left occipital sharp waves with a maximum at the left occipital electrode (O1). On discontinuation of anti-seizure medication, the patient developed a total of four clinical and five subclinical seizures. Three of his seizures manifested only with a visual aura. One of the seizures manifested as a focal status epilepticus with a duration of 10 min and 4 s, controlled by 5 mg of intranasal midazolam [1]. During focal status epilepticus, the visual aura was followed by dyscalculia/acalculia, anomia and alexia as well as left-right confusion. For details of ictal testing please refer to Table 2. Evaluation of the parallel EEG trace demonstrated a left temporo-parieto-occipital seizure pattern (maximum P3 > T5/O1, Fig. 5a-d). The patient showed no signs of interictal speech disturbance or any other neuropsychological deficit that was found during the seizures. MRI showed a large post-surgical defect extending from the left temporal to the left occipital lobe including the occipital pole (Fig. 6). The patient continued to be seizure free on a combination of levetiracetam 2000 mg and lacosamide 200 mg daily.

4. Ictal testing

In both patients testing during and after the seizures was conducted by specially trained medical technicians, as is common in the setting of long-term video-EEG monitoring [2,3]. Medical technicians are trained in using neurophysiological monitoring equipment and management of seizure-related emergencies. When the patient's safety is secured, they usually perform a short set of cognitive tasks (see Tables 1, 2). Clinical aspects are discussed daily on multiprofessional ward rounds and in some cases, provisions are made to test for specific neurological ictal deficits. For example, in the case of self-reported visual aura, a fixation cross is put on the wall to facilitate quadrant localisation. Complex or rare neuropsychological syndromes are however difficult to detect by history taking as the patients or their relatives have difficulties to describe ictal phenomena. Further, rare neuropsychological syndromes are not usually discussed on ward rounds before their detection during seizures. In our setting, we use a standardized set of cognitive tasks, comprising naming of presented objects on print-out cards, reading words on print-out cards, sentence repetition, following

Table 1

Transcript of ictal speech testing of patient in Case A.

T:	Please repeat: "Today is a wonderful day in Marburg."
P:	Today is (incorrect)
T:	Please read (card with word "bed" shown)
P:	Bed. (correct)
T:	Please repeat: "Today is a wonderful day in Marburg."
P:	Today is the name.... (incorrect)
T:	Please read (card "rainbow" shown)
P:	Rainbow. (correct)
T:	Please count backward from 5 on.
P:	5,4,3,2,1. (correct)
T:	Please repeat: "Today is a wonderful day in Marburg."
P:	Today is the name.... (incorrect)
T:	Do you know where you are?
P:	Yes.
T:	Which city?
P:	Marburg. (correct)
T:	What is that? Picture of camel shown.
P:	Camel. (correct)

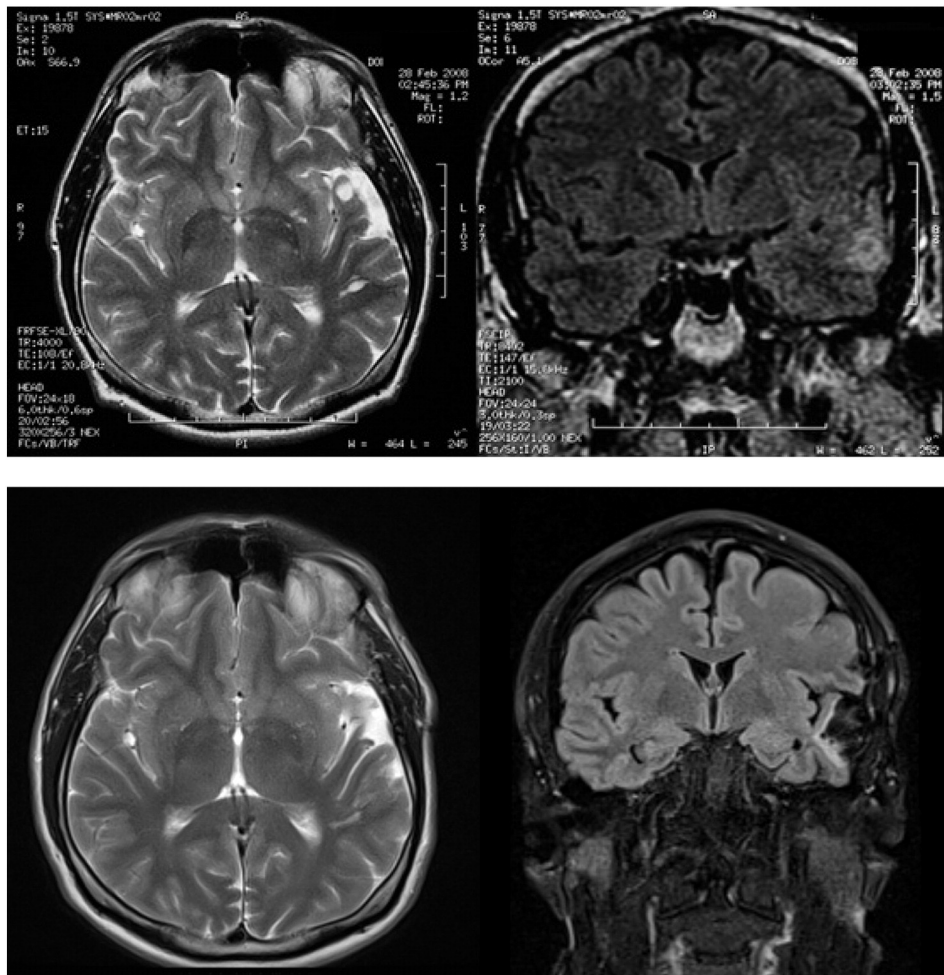


Fig. 2. Structural MR images (axial T2 and coronal FLAIR) of the left temporal lesion preoperatively (top) and after surgery (bottom) in case A.

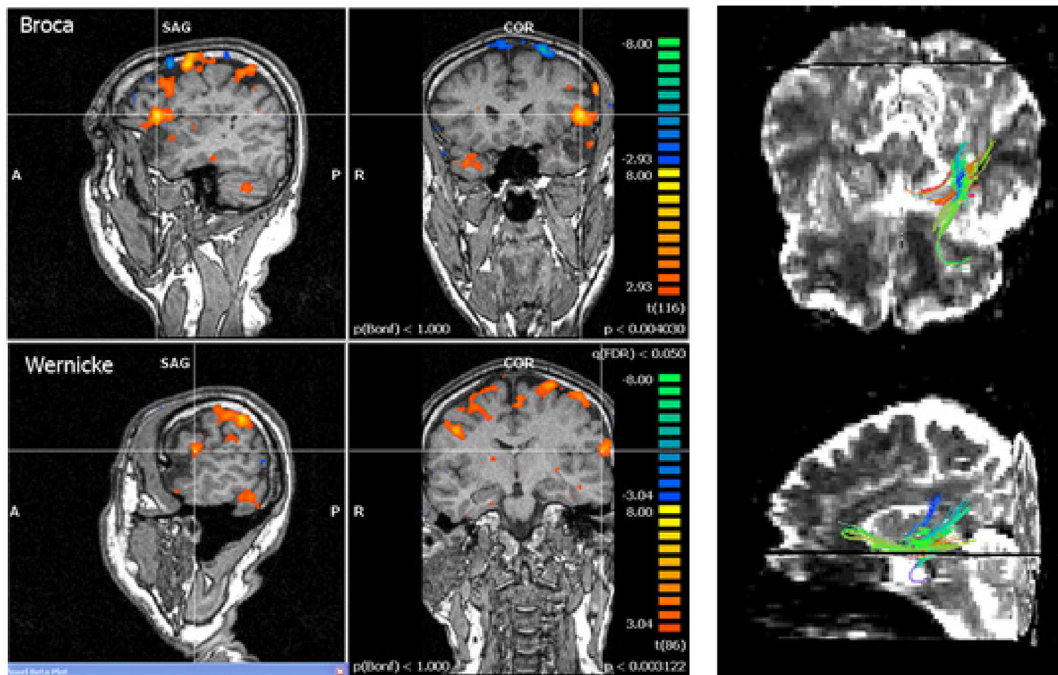


Fig. 3. fMRI of a speech paradigm (left side) and DTI-tractography (right side) in case A. On the left side, crosshairs are centred over clusters with maximum correlation to modelled paradigm in the left inferior frontal gyrus (“Broca”) and left superior temporal gyrus (“Wernicke”).

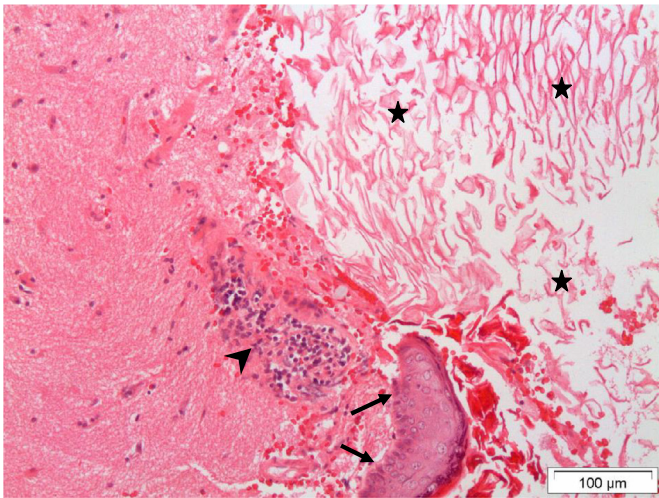


Fig. 4. Histological image of the left temporal epidermoid cyst in case A. There is a small portion of stratified keratinizing epithelium (arrow) and masses of keratin lamellae in the cyst (asterisk). In the border zone to the surrounding brain lymphocytic infiltrates are found (arrowhead).

verbal as well as non-verbal commands, calculation and memorizing words (see [Tables 1, 2](#)). In both cases, the structured testing was performed by the medical technicians and no additional patient-specific language testing was discussed beforehand. Seizures were retrospectively evaluated on an online digital video-EEG system (Nihon Kohden Corp., Tokyo, Japan, Case A; Micromed SpA, Mogliano Veneto, Italy, Case B).

We report two patients with uncommon disturbances of speech function demonstrating the importance of a detailed speech testing during seizures in a video-EEG monitoring setting. In both cases, complex neuropsychological dysfunctions could be retrospectively assessed based on a structured, bed-side testing performed by medical technicians.

5. Discussion

To our knowledge this is the first clinical report of a case of ictal conduction aphasia (case A). Clinically, conduction aphasia is characterised

Table 2
Transcript of ictal testing of patient in Case B.

07:59:25 EEG seizure onset at O1,T5,P3
07:59:29 clin seizure onset
T: Please tell me where we are.
P: I am in Frankfurt ... I have this flickering [light] in my eye.
T: In what quadrant do you see it.
P: Upper right [quadrant].
T: Could you please read this carefully. (Card with the word forest ["Wald"] shown)
P: I cannot, no.
T: Or at least partially.
P: No.
T: Could you please tell me the name of the object I am holding. (examiner holds up pen).
P: I cannot say [its name].
T: Could you please extend both of your arms in front of you. (correct)
T: Please rotate your palms upwards (correct)
T: Please repeat after me: "Today is a beautiful day".
P: Today is a beautiful day. (correct)
T: Very well, can you please calculate what is five plus five"
P: Five plus five.
T: What does that give. (patient shakes head, does not answer)
T: Okay, please calculate again five plus five.
P: That's nine. (incorrect)
T: Please give me your right hand. (incorrect, patient extends left hand)
P: No please, the right hand. (patient extends other hand)
08:09:29 EEG seizure end

by a disability to repeat speech and by primarily phonemic paraphasias, while receptive speech functions remain relatively intact [4]. Patients tend to approach correct speech production with successive attempts, called a "conduite d'approche". Conduction aphasia has for a long time been attributed to a disruption of the arcuate fasciculus (AF), which was assumed to connect a receptive temporal ("Wernicke's") with a productive frontal ("Broca's") language area. In this line of thinking, disruption of the AF then should primarily result in a subcortical disconnection syndrome [5,6]. Indeed, conduction aphasia could be produced by subcortical stimulation of the AF [7]. The view of conduction aphasia as a purely subcortical phenomenon has repeatedly been questioned based on pathophysiological [8] and functional [9] as well as anatomical [4] considerations. Besides, magnetic resonance diffusion tensor imaging (DTI) revealed that the AF does not terminate rostrally at the inferior frontal gyrus (Broca's area), but rather in the precentral gyrus [10]. Bernal and Ardilo therefore suggested only a supportive role of the AF in conduction aphasia [11]. Supporting a potential cortical origin, conduction aphasia has been induced by cortical stimulation of the posterior superior temporal gyrus in two patients suffering from structural epilepsy [12,13]. The posterior superior temporal gyrus has also been suggested as an anatomical correlate of phonemic-level disorder as a mechanism of conduction aphasia [9,14] in functional imaging studies. Conduction aphasia has further been divided into a parietal and a temporal form [4,5]. These forms roughly correspond to anatomical deficits in a proposed dual stream model of speech processing [15–17]. Thus, conduction aphasia can be understood as dysfunction of either the ventral or dorsal stream, with lesions in the dorsal stream explaining patients with more errors in repetition and lesions in the ventral stream explaining patients with semantic impairments, i.e. comprehension deficits [15]. In our case, thorough ictal testing revealed language deficit in our patient to be conduction aphasia with a pure impairment in repetition, as we were able to exclude ictal deficits in naming, auditory and written comprehension. The epileptogenic lesion in case A was present in the left middle and inferior temporal gyrus. We assume that propagation to the frontal lobe and insula resulted in ictal conduction aphasia. While a pure understanding of the dual stream model should predict predominantly semantic impairments in the case of a lesion in the middle temporal gyrus, in clinical practice, these two pathways show considerable clinical overlap [15].

Angular gyrus syndrome is an uncommon presentation for epileptic seizures (case B). The clinical tetrad of finger agnosia, acalculia, agraphia and left–right disorientation was first described in 1924 by Josef Gerstmann, an Austria-born neurologist [18,19]. Beginning in 1930, he suggested that such a tetrad defines a separate clinical syndrome that suggests lesioning of the angular gyrus on the speech dominant hemisphere [20]. The virtue of combining these separate clinical deficits in the manner of a syndrome has since repeatedly been called into question. Among the criticisms were the lack of a statistically salient inner association among its constituents relative to other possible neuropsychological deficits, especially constructional apraxia and dyslexia [21]. In particular, it was noted that incomplete forms were common and that the likelihood of developing the full tetrad increased with the size of the parenchymal lesion and at the same time with the likelihood of developing further neuropsychological deficits, especially dysphasia [22]. Other criticisms included the ambiguousness of potential clinical deficits leading to elements of the syndrome and ultimately Gerstmann's claim at a common pathophysiological and cognitive root ("Grundstörung") of the syndrome [23]. Gerstmann's syndrome has since been described in its pure form in patients with parenchymal lesions [24,25] as well as produced by direct cortical stimulation of a subdural electrode grid in the setting of pre-surgical epilepsy evaluation in a single patient [26], where all four elements could be located to two closely adjacent electrode contacts in the left posterior perisylvian area. Interestingly, additional deficits could be elicited by stimulation inferior to this region, among them alexia, anomia and constructional apraxia [26]. Further stimulation in a group of patients undergoing open brain

surgery also elicited Gerstmann's syndrome in the angular gyrus of the speech dominant side [27], often close to sites eliciting anomia. Indeed, the angular gyrus has been implicated in the task of semantic retrieval, mapping meaning to form [28,29]. Rusconi et al. suggested the relevance of a subcortical disconnection in the dominant parietal lobe as a cause of the syndrome [30].

To our knowledge, two cases of ictal Gerstmann's syndrome have been published. Hojo and Fukushima reported on a 21 year old patient with focal status epilepticus presenting with right homonymous hemianopsia who demonstrated amnesic aphasia in addition to Gerstmann's syndrome [31]. Shimotake et al. reported a case of a 34-year-old patient with recurrent focal seizures due to a left parieto-occipital astrocytoma. During seizures, he exhibited all elements of Gerstmann's syndrome but except left-right disorientation. A seizure pattern involving P3, O1 and T5 was noted during seizures [32]. In our

patient, the onset of speech symptoms followed a visual aura and occurred simultaneously with a left parieto-occipital (P3/O1) seizure pattern. Our case, which demonstrates two clinical elements of Gerstmann's syndrome but also some of those neuropsychological deficits often found in conjunction with the original tetrad [33] can thus be labelled as an "angular gyrus syndrome". Of note, the particular constituents of the syndrome as well as associated deficits (apart from self-reported paroxysmal dyslexia and "word finding difficulties") were neither expected in this patient nor were the syndrome known to the medical technicians performing the bedside testing. Of course, our case does not allow any inference as to the debated issue of a common cognitive origin in this particular parietal lobe dysfunction. It however demonstrates that with concise clinical testing, even complex neuropsychological deficits can be retrospectively assessed without prior knowledge of the syndrome.

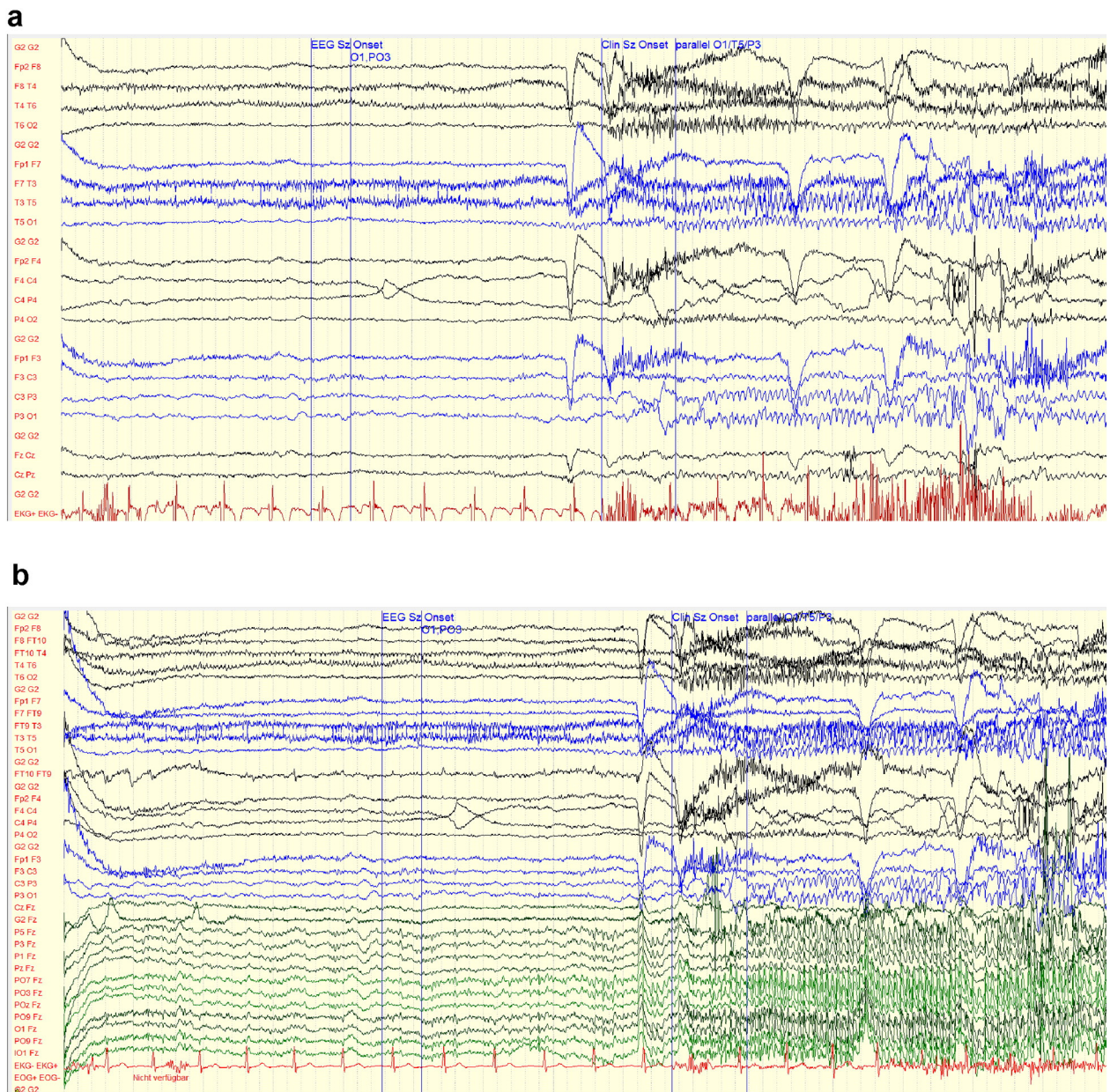
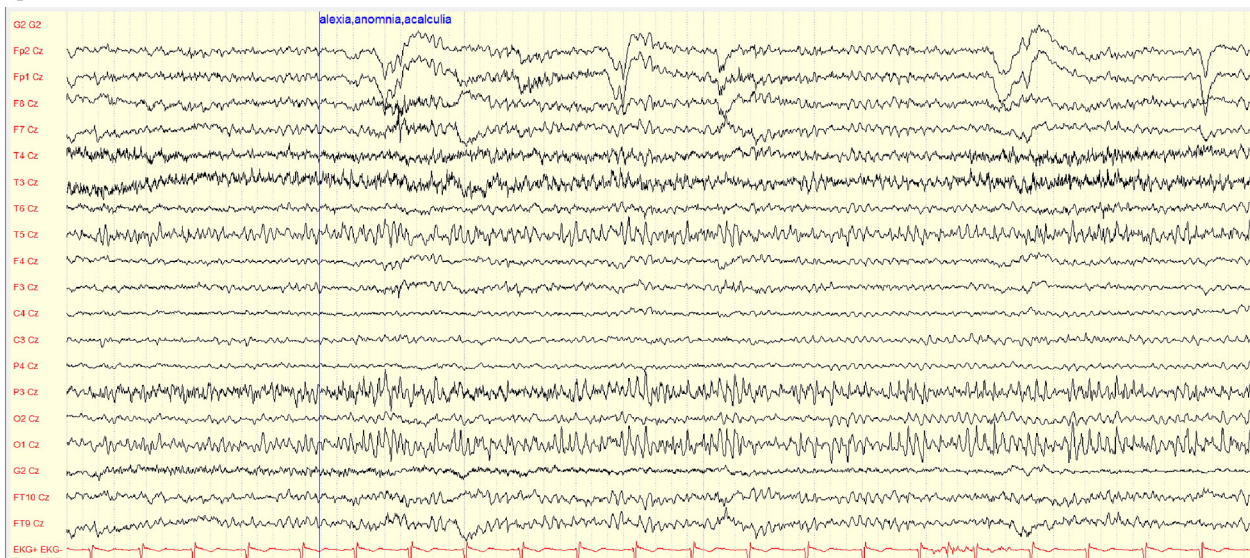


Fig. 5. a. EEG seizure onset in Case B beginning in the left occipital EEG leads (O1/P03) [10–20 bipolar montage] b. EEG seizure onset in Case B beginning in the left occipital EEG leads (O1/P03) [10–20 Fz referenced montage with additional leads in the left occipito-posterior region according to the 10–10 system of electrode placement] c. The EEG trace in Case B occurred in parallel to the deficits in naming, reading and calculation and shows a left temporo-parieto-occipital seizure pattern (T5/P3/O1), [10–10 Cz referenced montage] d. Parallel to the left temporo-parieto-occipital seizure pattern (P3 > T5/O1), the patient was still able to follow spoken commands without problems [10–10 Cz referenced montage].

C



d

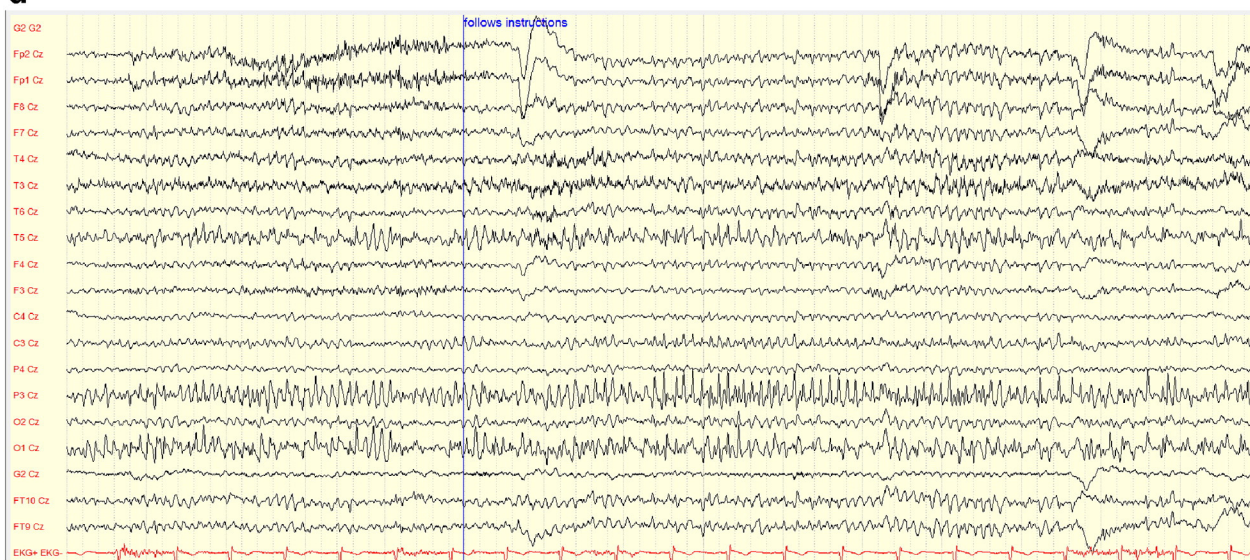


Fig. 5 (continued).

Aphasic seizures lateralize the epileptogenic zone to the speech dominant hemisphere. It is important that the patient remains awake and otherwise responsive during the aphasic seizure, as a lack of responsiveness to questioning can be confused with aphasia [34]. While the lateralizing value of ictal aphasia is undisputed, the localising value of distinguishing between different forms of ictal aphasia has repeatedly been called into question [35]. Unlike aphasias resulting from strokes, the exact type of aphasia has been shown to be of little localizing value, as seizures implicating different eloquent areas on the EEG recording can lead to varying aphasic syndromes [35]. Sperli et al. reported the case of a patient with left parietal cavernoma that exhibited aphasic symptoms as well as elements of Gerstmann's syndrome (acalculia, agraphia) in addition to repetition problems. On EEG, a left temporal seizure onset (T3/T5) with propagation to the left parietal region was present [36]. In our case B, we cannot completely rule out the possibility of alexia without aphasia, which can be induced by stimulation of the speech dominant side posterior fusiform gyrus (visual word form area), roughly contributing to the EEG activity recorded at the T5 electrode site [37,38].

Both our cases underline the importance of standardized ictal speech testing. Ictal bed-side testing during long-term video-EEG monitoring should always include testing the patient's alertness and responsiveness (in a verbal and non-verbal fashion) to rule out reduced general responsiveness as a mimic of aphasia. For the same reason, the patient's memory during the seizure should be assessed post-ictally [39]. The patient's expressive as well as receptive language functions should be tested by issuing commands, testing the naming of common objects, reading common words and the repetition of simple sentences. Testing should include both semantic, text-based and graphical-pictorial presentation of language cues. To reveal non-fluent receptive aphasia, the patient should be instructed to follow simple but explicit motor commands. Further testing can include the instruction to calculate or write.

The lateralizing value of diagnosing ictal and post-ictal aphasia is well recognized. However, the precise classification of the kind of ictal syndrome presented in both cases does not seem to add any localizing value beyond that. It is known from cortical stimulation in pre-surgical epilepsy patients that very different aphasic symptoms can be elicited by

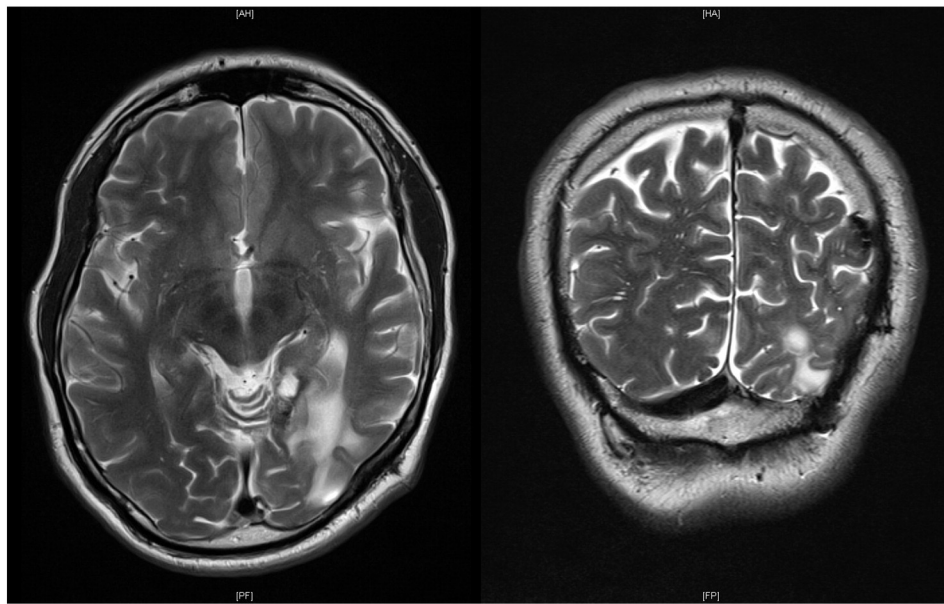


Fig. 6. Axial and coronal oriented T2w MR images of the lesion in Case B; T2w hyperintense area (gliosis) in the left occipital and parietal lobes as a postoperative residue after removal of a left tentorial meningioma; part of the posterior horn of the left lateral ventricle is seen on the coronal view directly adjacent to the gliosis due to vacuolization.

stimulation of traditionally defined language areas (e.g. comprehension deficits arising from the electrical stimulation of Broca's area) [40]. The functional deficits induced by stimulation are also related to the intensity of the stimulation. For that matter, stimulation of one single cortical site can produce different aphasia syndromes depending on stimulation intensity. Very strong stimulation can elicit global aphasia in almost any language area. Since seizures can lead to equivocal clinical signs and symptoms (see case B), a complete evaluation is always necessary if it is possible, but inferences from individual aphasic syndrome to the symptomatogenic and especially epileptogenic zone are necessarily limited.

6. Conclusion

In our case series of two patients with uncommon ictal language deficits, precise pre-determined testing of seizure semiology allowed us to exactly define the rare syndromes of ictal conduction aphasia and angular gyrus syndrome. Speech assessment should include expressive and receptive functions. Such testing can be performed during seizures by medical technicians and analysed in an inter-disciplinary setting. Ictal language testing is valuable to lateralize the seizure onset zone, but further localising value is limited.

Acknowledgement

We are indebted to all of our medical technicians for the excellent technical and clinical support in our video-EEG monitoring units in Frankfurt and Marburg.

Disclosure

None of the authors report conflict of interests related to the content of this case reports.

We confirm that we have read the Journal's position on issues involved in ethical publication and affirm that this report is consistent with those guidelines.

References

- [1] Kay L, Reif PS, Belke M, et al. Intranasal midazolam during presurgical epilepsy monitoring is well tolerated, delays seizure recurrence, and protects from generalized tonic-clonic seizures. *Epilepsia* 2015;56(9):1408–14.
- [2] Rosenow F, Bast T, Czech T, et al. Revised version of quality guidelines for presurgical epilepsy evaluation and surgical epilepsy therapy issued by the Austrian, German, and Swiss working group on presurgical epilepsy diagnosis and operative epilepsy treatment. *Epilepsia* 2016;57(8):1215–20.
- [3] American Clinical Neurophysiology Society. Guideline twelve: guidelines for long-term monitoring for epilepsy. *J Clin Neurophysiol* 2008;25(3):170–80.
- [4] Axer H, von Keyserlingk AG, Berks G, von Keyserlingk DG. Supra- and infrasyllabic conduction aphasia. *Brain Lang* 2001;76(3):317–31.
- [5] Benson DF, Sheremata WA, Bouchard R, Segarra JM, Price D, Geschwind N. Conduction aphasia. *Arch Neurol* 1973;28(5):339–46.
- [6] Geschwind N. Disconnection syndromes in animals and man. I. *Brain* 1965;88(2):237–94.
- [7] Mandonnet E, Nouet A, Gatignol P, Capelle L, Duffau H. Does the left inferior longitudinal fasciculus play a role in language? A brain stimulation study. *Brain* 2007;130(Pt 3):623–9.
- [8] Brown JW. The problem of repetition: A study of "conduction" aphasia and the "isolation" syndrome. *Cortex* 1975;11(1):37–52.
- [9] Hickok G, Poeppel D. Towards a functional neuroanatomy of speech perception. *Trends Cogn Sci* 2000;4(4):131–8.
- [10] Catani M, Mesulam M. The arcuate fasciculus and the disconnection theme in language and aphasia: history and current state. *Cortex* 2008;44(8):953–61.
- [11] Bernal B, Ardila A. The role of the arcuate fasciculus in conduction aphasia. *Brain* 2009;132(Pt 9):2309–16.
- [12] Quigg M, Fountain NB. Conduction aphasia elicited by stimulation of the left posterior superior temporal gyrus. *J Neurol Neurosurg Psychiatry* 1999;66:393–6.
- [13] Anderson JM, Gilmore R, Roper S, et al. Conduction aphasia and the arcuate fasciculus: a reexamination of the Wernicke-Geschwind model. *Brain Lang* 1999;70(1):1–12.
- [14] Buchsbaum BR, Baldo J, Okada K, et al. Conduction aphasia, sensory-motor integration, and phonological short-term memory - an aggregate analysis of lesion and fMRI data. *Brain Lang* 2011;119(3):119–28.
- [15] Kummerer D, Hartwigsen G, Kellmeyer P, et al. Damage to ventral and dorsal language pathways in acute aphasia. *Brain* 2013;136(Pt 2):619–29.
- [16] Weiller C, Bormann T, Saur D, Musso M, Rijntjes M. How the ventral pathway got lost: and what its recovery might mean. *Brain Lang* 2011;118(1–2):29–39.
- [17] Saur D, Kreher BW, Schnell S, et al. Ventral and dorsal pathways for language. *Proc Natl Acad Sci U S A* 2008;105(46):18035–40.
- [18] Gerstmann J. Fingeragnosie und isolierte Agraphie: ein neues Syndrom. *Z Ges Neurol Psychiatr* 1927;108:152–77.
- [19] Gerstmann J. Fingeragnosie. Eine umschriebene Störung der Orientierung am eigenen Körper. *Wien Klin Wochenschr* 1924;37:1010–2.
- [20] Gerstmann J. Syndrome of finger agnosia, disorientation for right and left, agraphia and acalculia. *Arch Neuropsych* 1940;44(2):398.
- [21] Benton AL. The fiction of the "GERSTMANN syndrome". *J Neurol Neurosurg Psychiatry* 1961;24(2):176–81.
- [22] Heimburger RF, Demyer W, Reitan RM. Implications of Gerstmann's syndrome. *J Neurol Neurosurg Psychiatry* 1964;27:52–7.
- [23] Critchley M. The enigma of Gerstmann's syndrome. *Brain* 1966;89(2):183–98.
- [24] Mayer E, Martory MD, Pegna AJ, Landis T, Delavelle J, Annoni JM. A pure case of Gerstmann syndrome with a subangular lesion. *Brain* 1999;122(Pt 6):1107–20.
- [25] Tucha O, Steup A, Smely C, et al. Toe agnosia in Gerstmann syndrome. *J Neurol Neurosurg Psychiatry* 1997;63(3):399–403.

- [26] Morris HH, Luders H, Lesser RP, Dinner DS, Hahn J. Transient neuropsychological abnormalities (including Gerstmann's syndrome) during cortical stimulation. *Neurology* 1984;34(7):877–83.
- [27] Roux F-E, Boetto S, Sacko O, Chollet F, Trémoulet M. Writing, calculating, and finger recognition in the region of the angular gyrus: a cortical stimulation study of Gerstmann syndrome. *J Neurosurg* 2003;99(4):716–27.
- [28] Price CJ. The anatomy of language: a review of 100 fMRI studies published in 2009. *Ann N Y Acad Sci* 2010;1191:62–88.
- [29] Mesulam MM. From sensation to cognition. *Brain* 1998;121:1013–52.
- [30] Rusconi E, Pinel P, Eger E, et al. A disconnection account of Gerstmann syndrome: functional neuroanatomy evidence. *Ann Neurol* 2009;66(5):654–62.
- [31] Hojo K, Fukushima Y. A case of partial status epilepticus with various neuropsychological symptoms. *Folia Psychiatr Neurol Jpn* 1979;33(3):291–4.
- [32] Shimotake A, Fujita Y, Ikeda A, et al. Ictal Gerstmann's syndrome in a patient with symptomatic parietal lobe epilepsy. *Rinsho Shinkeigaku* 2008;48(3):208–10.
- [33] Poeck K, Orgass B. Gerstmann's syndrome and aphasia. *Cortex* 1966;2(4):421–37.
- [34] Tufenkjian K, Luders HO. Seizure semiology: its value and limitations in localizing the epileptogenic zone. *J Clin Neurol* 2012;8(4):243–50.
- [35] Benatar M. Ictal aphasia. *Epilepsy Behav* 2002;3(5):413–9.
- [36] Sperli F, Placidi F, Izzi F, et al. Ictal aphasia as manifestation of partial status epilepticus in a long-lasting misdiagnosed symptomatic epilepsy: an emblematic case. *Int J Neurosci* 2009;119(4):531–7.
- [37] Dehaene S, Cohen L. The unique role of the visual word form area in reading. *Trends Cogn Sci* 2011;15(6):254–62.
- [38] Mani J, Diehl B, Piao Z, Schuele SS, Lapresto E, Liu P, et al. Evidence for a basal temporal visual language center cortical stimulation producing pure alexia. *Neurology* 2008;71(20):1621–7.
- [39] Lüders H, Noachtar S. *Epileptic seizures: pathophysiology and clinical semiology*. 1st ed. New York: Churchill Livingstone; 2000.
- [40] Schäffler L, Lüders HO, Dinner DS, Lesser RP, Chelune GJ. Comprehension deficits elicited by electrical stimulation of Broca's area. *Brain* 1993;116(3):695–715.