

# Endoscopic submucosal dissection of the pharyngeal region using anchored hemoclip with surgical thread: A novel method

## Authors

Hitomi Minami, Maiko Tabuchi, Kayoko Matsushima, Yuko Akazawa, Naoyuki Yamaguchi, Ken Ohnita, Fuminao Takeshima, Kazuhiko Nakao

## Institution

Department of Gastroenterology and Hepatology, Nagasaki University Hospital

## submitted

20. December 2015

## accepted after revision

2. May 2016

## Bibliography

DOI <http://dx.doi.org/10.1055/s-0042-108802>

Published online: 9.8.2016

Endoscopy International Open

2016; 04: E828–E831

© Georg Thieme Verlag KG

Stuttgart · New York

E-ISSN 2196-9736

## Corresponding author

**Hitomi Minami, MD, PhD, FASGE**

Department of

Gastroenterology and  
Hepatology

Nagasaki University Hospital

1-7-1, Sakamoto

Nagasaki, Japan, 8528501

Fax: +81-95-819-7482

le7novembre@gmail.com

**Background and study aims:** Endoscopic submucosal dissection (ESD) of the pharyngeal region has not been well accepted, although ESD of the gastrointestinal tract is a standard procedure for treating early cancers. However, early detection and treatment of pharyngeal cancers is highly beneficial because surgical resection can be highly invasive and cause serious cosmetic deformi-

ties, swallowing disorders, dysgeusia, and speech defects. On the other hand, application of an anchored clip with surgical thread during ESD of the gastrointestinal tract has been reported to be beneficial. This pilot case series reveals the usefulness and clinical feasibility of applying a clip with thread in ESD of the pharyngeal region.

## Introduction

Endoscopic submucosal dissection (ESD) has been widely accepted as a standard treatment for early gastrointestinal tract cancers. However, ESD of the pharyngeal region is still not well developed because of the poor maneuverability of the devices and distinctive anatomical features of the region. On the other hand, benefits of hemoclip with surgical thread during ESD of the esophagus and stomach have been reported recently [1,2]. This is the first pilot case series, describing the application of surgical thread knotted to endoscopic hemoclip as a traction device during ESD of the pharyngeal region.

specially designed, curved rigid laryngoscope (Nagashima Medical Instruments company, Ltd, Tokyo, Japan) was inserted by an otolaryngologist for visualizing the surgical field in the pharyngeal lumen (Fig. 1).

A forward-viewing endoscope (GIF-Q260J; Olympus Medical Systems, Tokyo) with a transparent distal cap attachment (D-201-11804, Olympus) was used in all the procedures. Flush knife (DK2618JB; FTS) or Dual knife (KD-650L, Olympus) was utilized for cutting and dissecting the submucosal layer. An electrogenerator, VIO300d (ERBE, Germany), was also used.

## Case Reports

Five consecutive patients with early pharyngeal cancer underwent ESD using anchored hemoclip with surgical thread between May and September 2015. All of the individuals were male (54–70 years old) with a history of massive intake of alcohol and tobacco. All the lesions were preoperatively diagnosed as epithelial or slightly subepithelial invasive squamous cell carcinoma. Characteristics of each case are summarized in Table 1.

## Anchored clip

Surgical silk thread (2–0, 60 cm) was tied to a hemoclip (HX-610-090L, Olympus, Tokyo) that was already inserted into the working channel of the endoscope (Fig. 2). Thread was knotted to the body of the clip, stabilizing the clip during delivery through the oral cavity.

## Setting of ESD

All the procedures were performed under general anesthesia with tracheal intubation. Patients were kept in the supine position. Prior to ESD, a

## ESD procedure

All of the procedures were carried out by an experienced endoscopist who had performed more than 500 ESDs in the gastrointestinal tract including pharyngeal cases. Following tracheal intubation and exposure of the pharyngeal region, 1.0% iodine solution was sprayed using a spraying catheter for the confirmation of the tumor margin (Fig. 3). Markings were put approximately 1 or 2 mm outside the lesion using a knife. Normal saline mixed with indigocarmine and small

## License terms



	Age	Gender	Location	Size	Tobacco	Alcohol
Case 1	58	Male	Oropharynx posterior wall	10	30 × 15 yr	40 g/day × 40 yr
Case 2	54	Male	Oropharynx posterior wall	15	15 × 30 yr	66 g/day × 30 yr
Case 3	69	Male	Hypopharynx piriform sinus	30	10 × 12 yr	100 g/day × 50 yr
Case 4	70	Male	Hypopharynx piriform sinus	10	50 × 45 yr	62 g/day × 40 yr
Case 5	47	Male	Hypopharynx piriform sinus	25	40 × 25 yr	80 g/day × 25 yr

**Table 1** Details about the clinical backgrounds of each patient.

amount of epinephrine was injected along the markings to create a submucosal lift.

Initial incision followed by circumferential incision was performed using either a flush knife or a dual knife. A deeper incision of the submucosal tissue on the oral side was made to create a mucosal flap for inserting the clip. Either flush or dual knife was used in each procedure.

The clip was intended to capture subepithelial tissue beneath the mucosal flap or the mucosal flap itself (Fig. 4). A mosquito forceps was placed at the other end of the thread to obtain an appropriate tension. The thread attached to the specimen created proper counter traction to maintain fine visualization of the dissecting plane.

### Histologic evaluation

Histologic evaluation was made in accordance with the World Health Organization classification of tumors (head and neck). Evaluation of the tumor depth was made according to the general rules for clinical studies of head and neck cancer by the Japanese Society for Head and Neck Cancer.

### Results

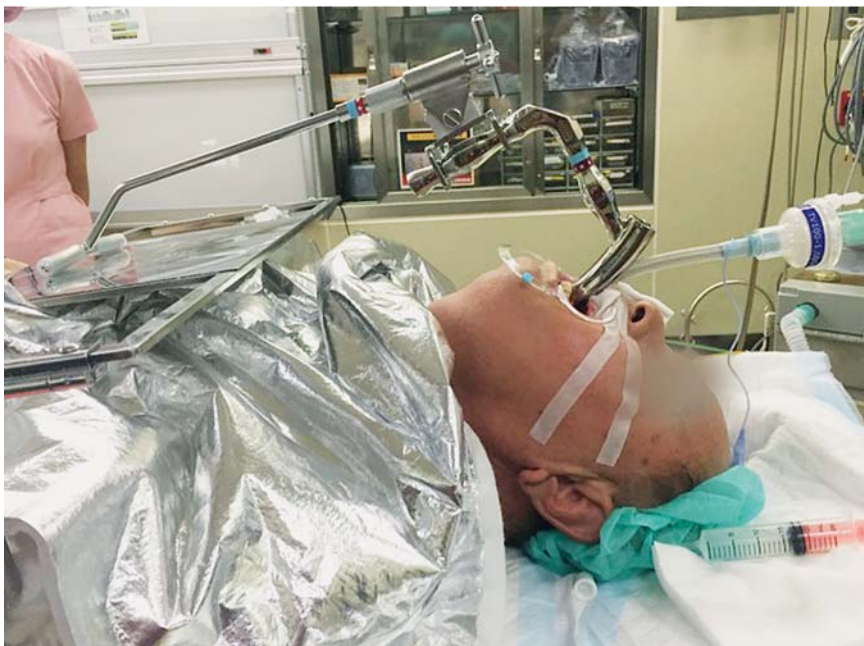ESD was successfully performed in all cases with uneventful extubation. No complications were experienced. All the lesions were pathologically diagnosed as superficial squamous cell carcinoma

and confirmed as completely resected. Detailed results of the procedure are shown in Table 2.

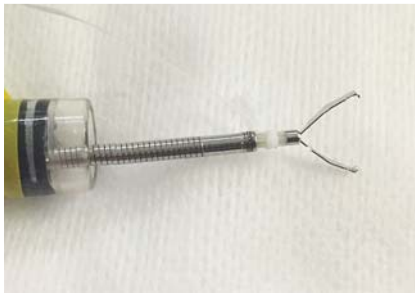Mean operative time was 67.8 minutes (35–78 minutes; median, 55 minutes). Use of an anchored clip was remarkably helpful for visualizing and dissecting the submucosal tissue during the procedure (Fig. 5). Mean operative time after clipping was 17 minutes (10–34 minutes).

### Discussion

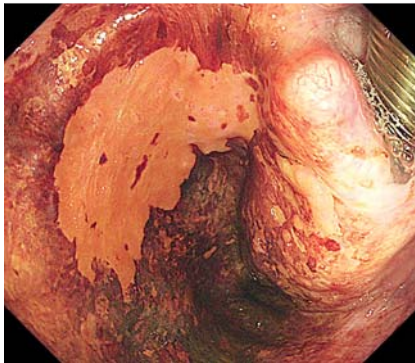
The current study demonstrates that ESD using an anchored clip with surgical thread as a traction device for superficial pharyngeal cancer is clinically feasible with no severe adverse events. Introduction of narrow band imaging allowed better detection of superficial pharyngeal lesions [3]. On the other hand, ESD of the pharyngeal region is not widely used, although ESD of the gastrointestinal tract has been well accepted as a standard treatment. Necessity of general anesthesia with tracheal intubation might be the reason for the low level of acceptance of this procedure. Surgical resection in the pharyngeal region can be highly invasive and can cause serious cosmetic deformities, swallowing disorders, dysgeusia, and speech defects. Shimizu and Kuwabara et al. reported the usefulness of endoscopic resection for laryngo-pharyngeal cancer [4,5]. However, limitations of the procedure included a longer operative time and technical difficulties due to poor maneuverability of the devices without “the right hand” that holds the tissue during the operation.



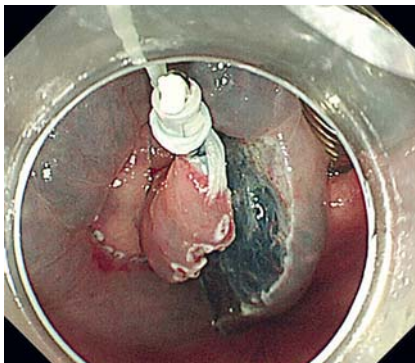
**Fig. 1** Patients were kept in the supine position. Prior to ESD, a specially designed, curved rigid laryngoscope was inserted by an otolaryngologist to visualize the surgical field.



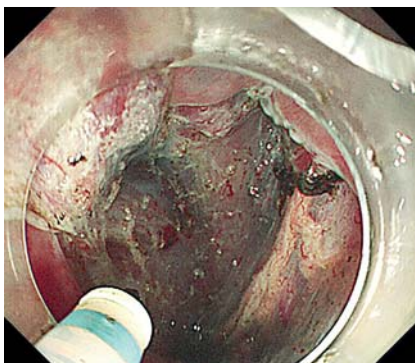
**Fig. 2** Surgical silk thread was tied to the body of a hemoclip that was already inserted into the working channel of the endoscope.



**Fig. 3** Tumor margin was confirmed with iodine spray for accurate marking.



**Fig. 4** A clip was placed on the submucosal tissue directly beneath the flap and provided proper counter traction during the procedure.



**Fig. 5** The anchored clip was remarkably helpful for visualizing and dissecting the submucosal tissue during the procedure.

Tateya et al. reported the usefulness of the technique called endoscopic laryngo-pharyngeal surgery (ELPS), which is a hybrid of head and neck surgery and endoscopic treatment. ELPS is performed by an otolaryngologist using curved grasping forceps and an electro-surgical needle knife under orally-inserted endoscopic view preserving both swallowing and phonation functions [6]. The novel method described in this report allowed us to dissect the mucosal lesion with a shorter operative time and minimum damage to both the specimen and the pharyngeal wall. However, it involves special devices, such as curved grasping forceps (Nagashima Medical Instruments Company, Ltd, Tokyo, Japan) and curved electro-surgical needle knife (Olympus Medical Systems, Tokyo, Japan), and has to be performed by an otolaryngologist. Another difficulty for the procedure is that the endoscope and other devices interfere with each other because of the narrow space of the pharynx.

Iizuka et al. reported on a similar technique, ELPS, in 2012 [7]. Fraenkel laryngeal forceps were used to creating proper counter traction during ESD in the pharyngeal region. This forceps has a special cup-shaped tip and rotatability, which enable smooth handling of the specimen. The method was reported to have made ESD in the pharyngeal area easier than conventional ESD. ESD with an anchored clip caused minimum damage to the specimen and the pharyngeal wall without extending operative time. Interestingly, the rate of negative resection margin was 100% pathologically. We speculate that the reason for clear margin is that the dissecting plane is always directly visible with this method, which also enabled us to minimize damage to the specimen. The operative time was actually no shorter with the clipping method compared to ELPS. However, the most beneficial aspects of this clipping method are that the devices no longer interfere with each other in the narrow space of the oral cavity and pharyngeal ESD can be achieved by a single team of gastroenterologists.

The limitations of this study were that it was a retrospective analysis of a prospective case series which was performed in a single referral center at Nagasaki and the number of cases also was limited.

## Conclusion

This novel method of using an anchored clip was feasible and beneficial for obtaining better visualization during the procedure and maneuverability of the devices during ESD of the pharyngeal region. Furthermore, it achieved a high negative resection margin.

**Competing interests:** None

**Table 2** Pathological results with the resected specimens.

	Operative time (min)	Time after clipping (min)	R0 resection	Complications	Pathology	Size	Depth		ly/v
Case 1	65	10	R0	None	SCC	9	EP	n. a.	ly0 v0
Case 2	78	34	R0	None	SCC	7	EP	n. a.	ly0 v0
Case 3	65	20	R0	None	SCC	27	SEP	250 μm	ly0 v0
Case 4	63	12	R0	None	SCC	9	EP	n. a.	ly0 v0
Case 5	35	10	R0	None	SCC	23	SEP	300 μm	ly0 v0

SCC, squamous cell carcinoma; EP, epithelial; SEP, subepithelial.

## References

- 1 Ota M, Nakamura T, Hayashi K et al. Usefulness of clip traction in the early phase of esophageal endoscopic submucosal dissection. *Dig Endosc* 2012; 24: 315–318
- 2 Yoshida M, Takizawa K, Ono H et al. Efficacy of endoscopic submucosal dissection with dental floss clip traction for gastric epithelial neoplasia: a pilot study (with video). *Surg Endosc* 2015
- 3 Muto M, Minashi K, Yano T et al. Early detection of superficial squamous cell carcinoma in the head and neck region and esophagus by narrow band imaging: a multicenter randomized controlled trial. *J Clin Oncol* 2010; 28: 1566–1572
- 4 Shimizu Y, Yamamoto J, Kato M et al. Endoscopic submucosal dissection for treatment of early stage hypopharyngeal carcinoma. *Gastrointest Endosc* 2006; 64: 255–259 ; discussion 260-262
- 5 Kuwabara T, Hiyama T, Oka S et al. Clinical features of pharyngeal intraepithelial neoplasias and outcomes of treatment by endoscopic submucosal dissection. *Gastrointest Endosc* 2012; 76: 1095–1103
- 6 Tateya I, Muto M, Morita S et al. Endoscopic laryngo-pharyngeal surgery for superficial laryngo-pharyngeal cancer. *Surg Endosc* 2016; 30: 323–329
- 7 Lizuka T, Kikuchi D, Hoteya S et al. A new technique for pharyngeal endoscopic submucosal dissection: peroral countertraction (with video). *Gastrointest Endosc* 2012; 76: 1034–1038