

Received: 2014.05.15  
Accepted: 2014.07.06  
Published: 2014.10.09

## Annular Pancreas: A Cause of Gastric Outlet Obstruction in a 20-Year-Old Patient

Authors' Contribution:  
Study Design A  
Data Collection B  
Statistical Analysis C  
Data Interpretation D  
Manuscript Preparation E  
Literature Search F  
Funds Collection G

ABCDEF **Raha Alahmadi**  
EF **Saud Almuhammadi**

Department of General Surgery, King Faisal Specialist Hospital and Research Center (Gen Org) Jeddah Branch, Jeddah, Saudi Arabia

**Corresponding Author:** Raha Alahmadi, e-mail: [c\\_black\\_121@yahoo.com](mailto:c_black_121@yahoo.com)  
**Conflict of interest:** None declared

**Patient:** Female, 20  
**Final Diagnosis:** Annular pancreas  
**Symptoms:** Food intolerance • vomiting  
**Medication:** —  
**Clinical Procedure:** —  
**Specialty:** Gastroenterology and Hepatology

**Objective:** Congenital defects/diseases





**Background:** Annular pancreas is a congenital anomaly that consists of a ring of pancreatic tissue partially or completely encircling the descending portion of the duodenum. It is formed due to the failure of the ventral bud to rotate, thus it elongates and encircles the upper part of the duodenum. It can present in a wide range of clinical severities, and can affect neonates to the elderly, making it difficult to diagnosis. Although diagnosis of annular pancreas can be made pre-operatively by upper GI series, upper GI endoscopy, or CT scan, 40% of diagnoses require surgery for confirmation.

**Case Report:** We report the case of a 20-year-old woman presenting with history of vomiting and weight loss since childhood. We present the clinical characteristics, surgical management in the form of bypass procedure done through a duodenojejunostomy, and follow-up of the patient.

**Conclusions:** Annular pancreas occasionally presents in adults. Variable presentations have been described in the literature, including pancreatic neoplasm, pancreatitis, obstructive jaundice, duodenal obstruction, and peptic ulcer diseases. Most studies of these lesions are single case reports or small series, which do not allow a surgeon to accumulate extensive experience; therefore, reliance on the combined experience of others in recognition and appropriate management has been the norm.

**MeSH Keywords:** Duodenostomy • Gastric Outlet Obstruction • Pancreatic Diseases • Pancreatic Ducts

**Full-text PDF:** <http://www.amjcaserep.com/abstract/index/idArt/891041>

 1518  —  1  23



## Background

Annular pancreas is a congenital anomaly consisting of a ring of pancreatic tissue partially or completely encircling the descending portion of the duodenum [1]. The condition was first described by Tiedemann [1,2] in 1818 and named “annular pancreas” by Ecker [1,3,4] in 1862. It is rarely detected in adult life after the development of complications. We report the case of 20-year-old female patient who presented with history of vomiting and weight loss since childhood, discussing its clinical characteristics and surgical management.

The pancreas is normally formed from the fusion of the dorsal and ventral pancreatic buds between the first 4–8 weeks of embryonic life. Annular pancreas results due to failure of the ventral bud to rotate and elongates to encircle the upper part of the duodenum. Annular pancreas is one of few medical conditions that can present with a wide range of clinical severities. It affects neonates to the elderly, thereby making the diagnosis difficult [5].

## Case Report

A 20-year-old woman not known to have any medical illness presented with history of vomiting since childhood. She had not previously sought any medical advice despite her intermittent vomiting and underweight. She was vomiting gastric contents including food particles, mainly post-prandial, associated with epigastric pain and heartburn, which was relieved after vomiting. All these symptoms progressed during the last year. There was no history of smoking or alcohol consumption.

On examination, she appeared underweight (BMI 17% kg/m<sup>2</sup>) and her vital signs were within normal range. The abdomen was soft without any tenderness and no palpable masses or organomegaly. All her blood indices were within the normal limits. The patient was investigated in another hospital by Barium meal and follow-through, which revealed a stricture between the second and third part of the duodenum, with no filling defect seen, and slow passage of contrast through the stricture. The possibility of a band was raised by the radiologist. In addition, she had an abdominal CT scan that showed a distended stomach with air-fluid level, and dilated first part of the duodenum without an apparent transition. There was no clear diagnosis of an annular pancreas but it was suggested as one of the differential diagnoses.

Esophagogastroduodenoscopy (OGD) done in that hospital revealed narrowing between the second and third part of the duodenum, with a membranous stenosis in the second part of the duodenum, suggesting a duodenal web, with dilated upper part of the duodenum and food residue within the stomach.

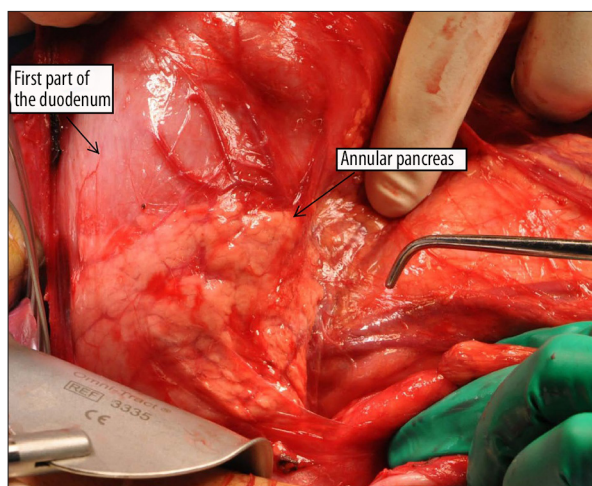


Figure 1. Annular pancreas.

A biopsy was taken, which was negative for malignancy. The differential diagnosis was annular pancreas versus duodenal web, or a combination of both. Later, she presented at our hospital with the image of the obstruction, where she was taken to the operating room for laparotomy.

At laparotomy, there was a complete annular pancreas associated with significant gastric outlet obstruction, with massive dilatation of the stomach, pylorus, and upper part of the duodenum. Although the annular pancreas did not seem to be causing a tight band or external compression, it was still the transition point (Figure 1). On opening the duodenum, there was a duodenal web at the transition point in the second and third part of the duodenum; therefore, a bypass procedure was performed through a duodenojejunostomy proximal to the annular pancreas.

The patient made an uneventful recovery and was discharged 7 days after surgery. She remained well, and had gained 2Kg at 3-month follow-up with better food tolerance.

## Discussion

Annular pancreas is an uncommon congenital condition in adults. Five theories have been suggested to explain the pathogenesis of annular pancreas, although various abnormalities appear to be involved in the developmental process [6–9]:

1. Hypertrophy of both dorsal and ventral primordial.
2. Persistence and enlargement of the left bud of the paired ventral primordium.
3. Fixation of the right bud of the ventral primordium prior to rotation.
4. Adherence of the right ventral pancreatic bud to the duodenum.
5. Adherence of the tip of the left ventral angle to the duodenum.

Annular pancreas represents a spectrum of diseases. Autopsy series indicated a prevalence of 5–15 cases per 100 000 adults. There are 2 peaks of presentation – in infancy (52%) and in the fourth decade of life (48%) [10]. This anomaly is frequently associated with other congenital anomalies in adults, and malrotation, duodenal web, and Schatzki ring were some of the more common anomalies. Long Cheng et al. reported a case of annular pancreas concurrent with pancreaticobiliary maljunction presenting with symptoms in an adult patient [11]. The annulus itself can be complete, partial, intramural, or extramural.

A literature review revealed 160 cases of annular pancreas and 76 cases of duodenal webs in adults. They all showed that the diagnosis is often overlooked in favor of gastric outlet obstruction. Duodenal webs can be mistaken for scarring from duodenal ulcer disease [12]. Therefore, annular pancreas should be considered as a possible cause of adult duodenal obstruction. In a review by Zyromski et al. [13], the commonest presentation in 24% of patients is due to gastric outlet obstructive symptoms; 75% had abdominal pain as the primary complaint; 11% presented with jaundice; 22% with acute pancreatitis, a finding that is possibly related to the high incidence of pancreas divisum (29%), with variable duration of symptoms from a few months to several years.

Zheng et al. [1] suggest that although annular pancreas may encircle the duodenum completely in adults, food usually can pass through the duodenum without trouble. However, the cause of the obstruction may be related to ulceration as a result of compression and obstruction from the annulus to the duodenum secondary to chronic pancreatitis. In these cases, the level of the stenosis was at or above the papilla of Vater, suggesting the annulus prevented the passage of alkaline secretions from the bile duct and pancreas, but patients with duodenal stenosis below the papilla have no ulcer, nor do patients without duodenal stenosis [1].

In another review, by Maker et al. [14], some of the patients who presented with gastric outlet obstruction had coexisting peptic ulcer disease (PUD). They mentioned a classification system proposed in the Canadian surgical literature in the 1970s with extramural (type 1) annular pancreas causing symptoms of gastric outlet obstruction, and intramural ring (type 2) related to presentation more consistent with PUD.

A number of case reports have documented neoplasia and adenocarcinoma arising in the setting of annular pancreas [15]. Zyromski et al. reported nearly one-quarter of adults in their study with annular pancreas developed neoplasia of some type, including 10% with pancreaticobiliary neoplasia [13].

Our case report describes late presentation of an annular pancreas with vague abdominal symptoms since childhood. This

points more towards the diagnosis of a duodenal web anomaly that might explain the patient's symptoms. Duodenal web anomalies in more than one-third of patients do not manifest signs or symptoms until adulthood. The lesion can be asymptomatic or present as gastric outlet obstruction, resulting in antral dilation and secondary hypergastrinemia commonly associated with PUD.

The diagnosis of annular pancreas can be made preoperatively using numerous radiologic and endoscopic studies, including upper GI tract studies and computed tomography (CT). However, in over 40% of cases, the diagnosis is only made at laparotomy [5,16]. In CT and magnetic resonance imaging (MRI), a ring of pancreatic tissue is seen surrounding the descending duodenum, in continuity with the pancreatic head [17–19], and a magnetic resonance cholangiopancreatography (MRCP) or an endoscopic retrograde cholangiopancreatography (ERCP) can identify the annular pancreatic duct encircling and extending to the right side of the duodenum [19]. The annular pancreatic duct usually communicates with the main pancreatic duct, but may drain into the intrapancreatic common bile duct, the duct of Wirsung, or the duct of Santorini [19]. Endoscopic ultrasonography can also be useful in non-obstructive forms [20,21].

The treatment of symptomatic, obstructing annular pancreas has classically been surgical. The preferred treatment is a bypass operation such as gastro- or duodenojejunostomy, but some cases were treated by division of the annulus with transverse duodenoplasty, duodenoduodenostomy, or Whipple's procedure in extreme cases, depending on the case and the intra-operative findings [10,16,22].

Early attempts at resection or division of the annulus resulted in more complications of duodenal leak, pancreatitis, and pancreatic fistula, which is why it is safer to bypass the annular constriction by duodenoduodenostomy or duodenojejunostomy, from the proximal duodenal bulb to the Jejunum.

In summary, annular pancreas occasionally presents in adults. Variable presentations have been described in the literature, including pancreatic neoplasm, pancreatitis, obstructive jaundice, duodenal obstruction, and peptic ulcer diseases. The diagnosis of annular pancreas can be made pre-operatively by upper GI series, upper GI endoscopy, or CT scan, although 40% of diagnoses required surgery for confirmation. The treatment of symptomatic, obstructing annular pancreas has classically been surgical, as has been reported in the literature.

## Conclusions

With advancements in imaging modalities and an index of suspicion, both may assist in finding more cases of symptomatic

and asymptomatic annular pancreas in adults. Most studies of these lesions are single case reports or small series, which do not allow a single surgeon to accumulate extensive experience; therefore, the management of this congenital anomaly should be individualized according to the associated complications.

## References:

1. Zheng HM, Cai XJ, Shen LG, Finley R: Surgical treatment of annular pancreas in adults: a report of two cases. *Chin Med J*, 2007; 120(8): 724–25
2. Tieddmann F: Über die Verschiedenheiten des Ausführungsgangs der Bauchspeicheldrüse bei den Menschen und Säugetieren. *Dtsch Arch Physiol*, 1818; 4: 403 [in German]
3. Ecker A: Bildungsfehler des pancreas und Herzens. *Z Rat Med*, 1862; 14: 354 [in German]
4. Yogi Y, Shibue T, Hashimoto S: Annular pancreas detected in adults, diagnosed by endoscopic retrograde cholangiopancreatography: report of four cases. *Gastroenterol Jpn*, 1987; 22: 92–99
5. Whittingham-Jones PM, Riaz AA, Clayton G, Thompson HH: Annular pancreas – a rare cause of gastric obstruction in an 82-year-old patient. *Ann R Coll Surg Engl*, 2005; 87(1): W13–15
6. Fu PF, Yu JR, Liu XS et al: Symptomatic adult annular pancreas: report of two cases and a review of the literature. *Hepatobiliary Pancreat Dis Int*, 2005; 4(3): 468–71
7. Langman J: *Medical Embryology*. 4<sup>th</sup> Edition. Baltimore. Williams and Wilkins, 1981; 220–22
8. Nobukawa B, Otaka M, Suda K et al: An annular pancreas derived from paired ventral pancreata, supporting Baldwin's hypothesis. *Pancreas*, 2000; 20: 408–10
9. Kamisawa T, Yuyang T, Egawa N et al: A new embryologic hypothesis of annular pancreas. *Hepatogastroenterology*, 2001; 48: 277–78
10. Ravitch MM: The pancreas in infants and children. *Surg Clin North Am*, 1975; 55: 377–85
11. Cheng L, Tian F, Zhao T et al: Annular pancreas concurrent with pancreaticobiliary maljunction presented with symptoms until adult age: case report with comparative data on pediatric cases. *BMC Gastroenterology*, 2013; 13: 153
12. Ladd AP, Madura JA: Congenital Duodenal Anomalies in the Adult. *Arch Surg*, 2001; 136: 576–84
13. Zyromski NJ, Sandoval JA, Pitt HA et al: Annular Pancreas: Dramatic Differences Between Children and Adults. *J Am Coll Surg*, 2008; 206(5): 1019–27
14. Johnston DW: Annular pancreas: A new classification and clinical observation. *Can J Surg*, 1978; 21: 241–44
15. Foo FJ, Gill U, Verbeke CS et al: Ampullary carcinoma associated with an annular pancreas. *JOP*, 2007; 8: 50–54
16. Urayama S, Kozarek R, Ball T et al: Presentation and treatment of annular pancreas in an adult population. *Am J Gastroenterol*, 1995; 90: 995–99
17. Rizzo RJ, Szucs RA, Turner MA: Congenital abnormalities of the pancreas and biliary tree in adults. *Radiographics*, 1995; 15: 49–68; quiz 147–48
18. Nijs EL, Callahan MJ: Congenital and developmental pancreatic anomalies: ultrasound, computed tomography, and magnetic resonance imaging features. *Semin Ultrasound CT MR*, 2007; 28: 395–401
19. Türkvatan A1, Erden A, Türkoğlu MA, Yener Ö: Congenital Variants and Anomalies of the Pancreas and Pancreatic Duct: Imaging by Magnetic Resonance Cholangiopancreatography and Multidetector Computed Tomography. *Korean J Radiol*, 2013; 14(6): 905–13
20. Kandpal H, Bhatia V, Garg P, Sharma R: Annular pancreas in an adult patient: diagnosis with endoscopic ultrasonography and magnetic resonance cholangiopancreatography. *Singapore Med J*, 2009; 50: 29–31
21. Zeineb M, Sadri BA, Nizar M et al: Annular pancreas intra operatively discovered: a case report. *Clin Pract*, 2011; 1(4): e82
22. McGuigan JE, Ament ME: *Anatomy and developmental anomalies*. In: Sleisenger MH, Fordtran JS, eds. *Gastrointestinal disease*. Philadelphia: WB Saunders, 1993; 459–77

## Competing interests declared

None.