

# Anterior Cruciate Ligament Repair Using a Knotless Suture Implant



Keon Ariel Youssefzadeh, B.S., Spencer Matthew Stein, M.D., and Orr Limpisvasti, M.D.

**Abstract:** Recent orthopedic literature has shown that primary repair for femoral-sided avulsion tears of the anterior cruciate ligament (ACL) can be successful. Primary ACL repair avoids invasive reconstruction techniques, graft-site morbidity, and the loss of native anatomy while producing excellent results in appropriately selected patients. Here we describe our patient selection parameters, ACL repair technique, and rehabilitation protocol.

Early attempts at primary anterior cruciate ligament (ACL) repair in the 1970s and 1980s were plagued by high re-rupture rates and poor results. With the development of successful ACL-reconstruction techniques, ACL repair was largely abandoned during the 1990s.<sup>1,2</sup>

Recently, however, there has been resurging interest in modernizing and augmenting primary ACL repair.<sup>3-5</sup> This is due to modern technological advances in arthroscopic surgery, increased understanding of orthobiologics, advances in rehabilitation, and refined patient selection. Primary ACL repair may avoid the pitfalls of ACL reconstruction, such as graft-site morbidity, invasive drilling, loss of vascularity, and destruction of proprioceptive fibers. In addition, revision surgery, if required, is technically simpler after primary repair than reconstruction.

Recent literature has reported good-to-excellent outcomes with primary ACL repair.<sup>5,6</sup> However, the indication for ACL repair must be closely considered for it to succeed. To produce excellent outcomes after ACL repair, acute Sherman type I (femoral avulsion) tear patterns with excellent remnant tissue quality must be confirmed.<sup>3-5</sup>

As the popularity of primary ACL repair grows, new surgical techniques will allow for more successful repair of the ACL. The goal of this paper is to outline a technique for ACL repair using a knotless suture-based implant.

## Surgical Technique (With Video Illustration)

The patient is positioned in the supine position with the use of a lateral post for standard knee arthroscopy (Video 1). Anterolateral viewing and anteromedial working portals are established. In addition, a far anteromedial portal also can be added as necessary. The ACL is probed to judge tissue quality and tear pattern (Fig 1). Intact periligamentous synovial sheath, which contains penetrating blood vessels of the middle geniculate artery, is frequently seen in these types of injuries. Maintenance of the synovial sheath's femoral attachment allows blood supply to ACL, lending confidence to the repair.<sup>7</sup> If a femoral avulsion tear with good tissue quality and vascularity is confirmed, we will proceed with primary repair.

## Anchor Placement

First, marrow venting is performed at the femoral attachment site of the ACL (PowerPick; Arthrex, Naples, FL) to promote a biologic environment conducive to tissue healing. Next, a 3-cm × 10-mm passport canula (Arthrex) is inserted through the anteromedial portal. Using this portal, the appropriate drill is used to create a site for anchor placement at the native ACL femoral footprint. Without removing the drill guide, a 2.6-mm knotless suture implant (FiberTak; Arthrex) is gently impacted into place (Fig 2A). A gentle pull on the repair suture helps seat this implant (Fig 2B).

From the Kerlan-Jobe Orthopaedic Clinic, Los Angeles, California, U.S.A.  
The authors report that they have no conflicts of interest in the authorship and publication of this article. Full ICMJE author disclosure forms are available for this article online, as [supplementary material](#).

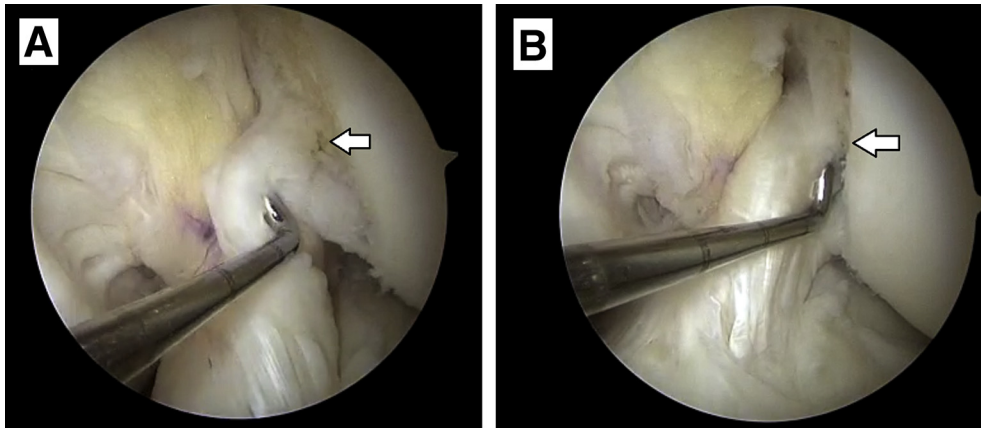
Received October 17, 2019; accepted January 9, 2020.

Address correspondence to Keon Youssefzadeh, B.S., 6801 Park Terrace #140, Los Angeles, CA 90045. E-mail: [Keon.Youssef@gmail.com](mailto:Keon.Youssef@gmail.com)

© 2020 by the Arthroscopy Association of North America. Published by Elsevier. This is an open access article under the CC BY-NC-ND license (<http://creativecommons.org/licenses/by-nc-nd/4.0/>).

2212-6287/191273

<https://doi.org/10.1016/j.eats.2020.01.013>



**Fig 1.** Images of the left ACL before and after surgery as viewed from the anterolateral portal. (A) Probing of the ACL reveals a Sherman type 1 tear of the ACL's posterolateral bundle and parts of the anteromedial bundle. Tissue shows no fraying and is of excellent quality. (B) The final construct being probed following ACL repair using a knotless suture implant. (ACL, anterior cruciate ligament.)

### Suture Passage and ACL Fixation

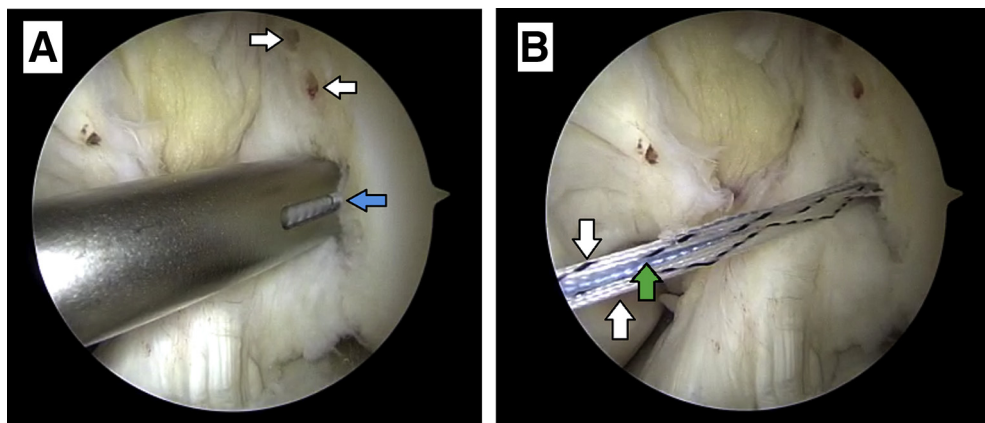
The repair suture of the anchor is loaded onto an antegrade self-retrieving suture passer (Scorpion; Arthrex). Approaching from the anteromedial portal, the suture is passed across the ACL from proximal to the middle one third and from lateral to medial (Fig 3A). The retrieved tail is again loaded into the self-retrieving suture passer and is passed back across the ACL from middle one third to proximal and from medial to lateral (Fig 3B). Next, the retrieved repair suture (blue suture) is shuttled through the implant using the shuttle suture (black-white speckled). This is accomplished using short quick tugs that are in line with the implant (Fig 4A). Once the repair stitch has been passed through the anchor, it can be pulled tightly to completely reduce the ACL to the femur. Given that this is a direct repair of an ACL avulsion, over- or undertensioning of the ACL has not been a concern. Finally, the excess suture is cut using an arthroscopic suture cutter (Fig 4B). The final repaired ACL construct is probed and noted to be stable (Fig 1B).

### Rehabilitation

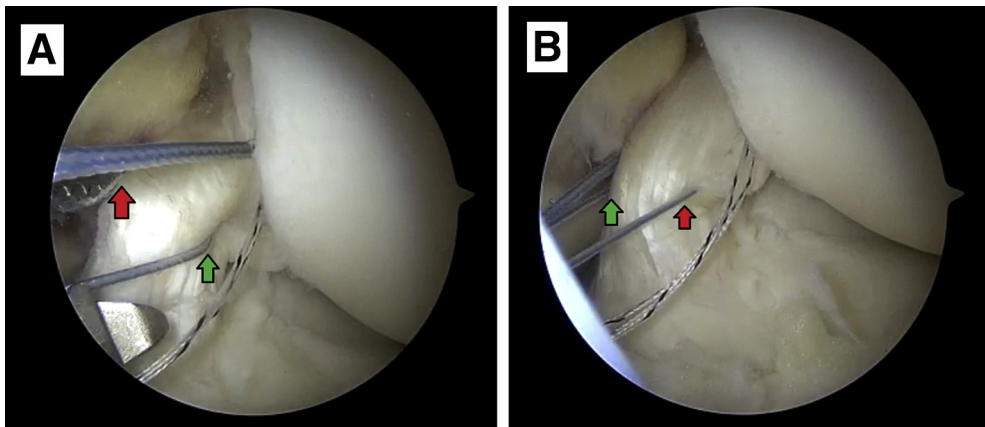
For the first 4 weeks postoperatively, weight bearing as tolerated is allowed with the knee locked in full extension using a hinged knee brace. Immediate range of motion from 0 to 90° is encouraged. After 4 weeks, the patient begins progressive range of motion and strengthening as tolerated. At 3 months postoperatively, neuromuscular and return to sport training are initiated as tolerated.

### Discussion

Paired with the proper indications, ACL repair has proven itself to be a viable treatment in the surgical management of primary ACL injuries.<sup>5,6</sup> Furthermore, ACL repair possess several advantages over ACL reconstruction. ACL repair avoids the need for graft harvest, which can produce discomfort and disability for patients. Autograft patellar harvesting has been associated with significant anterior knee pain, whereas hamstring harvest may lead to weakening of the ACL-protective knee flexor musculature.<sup>8,9</sup>



**Fig 2.** All suture anchor implantation and deployment viewed from the anterolateral portal of the left knee. (A) The anchor is impacted into the femoral footprint of the ACL without removing the drill guide (blue arrow). Two of six marrow venting sites around the femoral footprint of the ACL also can be visualized (white arrows). (B) Deployed anchor, showing both tails of the preloaded passing suture (white arrow) as well as the tail of the repair suture (green arrow). (ACL, anterior cruciate ligament.)



**Fig 3.** The 2 passes of the repair suture through the ACL using an antegrade self-retrieving suture passer viewed from the anterolateral portal of the left knee. (A) The first pass of the repair suture through the ACL, which is from the proximal to the middle one third in a lateral (green arrow) to medial (red arrow) direction. (B) The second pass of the repair suture which is done from the middle one third to proximal and from medial (green arrow) to lateral (red arrow). (ACL, anterior cruciate ligament.)

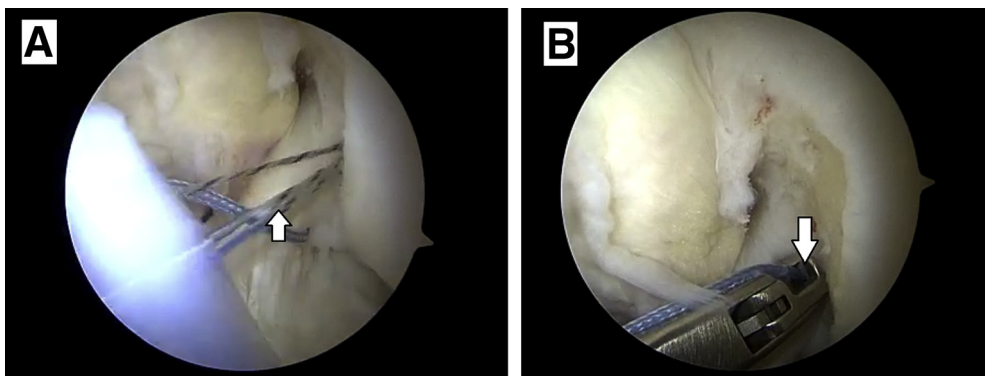
There is evidence that proprioception correlates better with postoperative function and satisfaction than mechanical stability.<sup>10</sup> The native ACL has proprioceptive receptors,<sup>11,12</sup> and patients with ACL-deficient knees have known loss of proprioception.<sup>13-15</sup> ACL repair, as opposed to reconstruction, has the advantage of retaining native tissue and therefore proprioceptive fibers.

From a biological perspective, there are apparent advantages of ACL repair over reconstruction. In fact, there have been previous positive outcomes reported with marrow stimulation in conjunction with repair of partial ACL tears.<sup>6</sup> There is also emerging evidence from a basic science perspective that the ACL has an inherent ability to heal. Murray et al.<sup>16,17</sup> have noted that an egress of cells when human ACL tissue is placed in culture. In addition, there is evidence that mesenchymal stem cells reside in the collagenous matrix and

adjacent to small blood vessels around the ACL. These stem cells have the potential to provide a superior basis for biological repair.<sup>18</sup> Recently, good outcomes with no re-rupture rate have been reported in bridge-enhanced ACL repairs at 2-year follow-up.<sup>19</sup> In the unfortunate but possible scenario that subsequent surgery is required, revision of a failed ACL reconstruction may require extensive removal of hardware, bone grafting, surgical staging, and lesser outcomes. Using the described all-inside, knotless suture anchor repair technique, these issues are avoided.

We believe the major limitation of this technique is patient selection (Table 1). Only a fraction of patients with ACL injury are eligible for repair. Improper selection of these patients may lead to poor results, as demonstrated in early ACL repair cohorts.<sup>2,20</sup>

With the advent of new arthroscopic techniques and the understanding of the underlying ACL biology,



**Fig 4.** Shuttling and removal of excess repair suture as seen through the anterolateral portal of the left knee. (A) The repair suture is shuttled through the implant using the looped end of the preloaded shuttle suture (white arrow). This cinches the repaired tissue back to the femoral footprint of the ACL. (B) Removal of the excess repair suture using an arthroscopic suture cutter (white arrow). (ACL, anterior cruciate ligament.)

**Table 1.** Indications, Pearls, and Pitfalls

Indications	Pearls	Pitfalls
Femoral avulsion tear pattern (Sherman type 1) as seen on MRI and confirmed during diagnostic arthroscopy. Good ACL quality.	Use of the repair suture to set the implant in bone.  Venting of the adjacent bone marrow may aid in ACL healing by producing a more biologically robust environment for healing.  Use quick sharp tugs in line with the implant when shuttling the repair sure back through the knotless implant.	Inappropriate selection of patients on which ACL repair is performed.

ACL, anterior cruciate ligament; MRI, magnetic resonance imaging.

primary ACL repair has re-emerged as a viable option to treat appropriately indicated ACL ruptures. We believe our technique provides advantages over ACL reconstruction when treating acute femoral avulsion tears of the ACL. The use of a knotless suture implant allows for efficient and minimally invasive repair of the ACL in cases of femoral avulsion tears with good remnant tissue quality.

## References

- Mahapatra P, Horriat S, Anand BS. Anterior cruciate ligament repair—past, present and future. *J Exp Orthop* 2018;5(1).
- Feagin JA, Curl WW. Isolated tear of the anterior cruciate ligament: 5-year follow-up study. *Am J Sports Med* 1976;4:95-100.
- van der List JP, DiFelice GS. Primary repair of the anterior cruciate ligament: A paradigm shift. *Surgeon* 2017;15:161-168.
- Jonkergouw A, van der List JP, DiFelice GS. Arthroscopic primary repair of proximal anterior cruciate ligament tears: Outcomes of the first 56 consecutive patients and the role of additional internal bracing. *Knee Surg Sport Traumatol Arthrosc* 2019;27:21-28.
- Achtnich A, Herbst E, Forkel P, et al. Acute proximal anterior cruciate ligament tears: Outcomes after arthroscopic suture anchor repair versus anatomic single-bundle reconstruction. *Arthroscopy* 2016;32:2562-2569.
- Gobbi A, Whyte GP. Long-term outcomes of primary repair of the anterior cruciate ligament combined with biologic healing augmentation to treat incomplete tears. *Am J Sports Med* 2018;46:3368-3377.
- Petersen W, Tillmann B. Structure and vascularization of the cruciate ligaments of the human knee joint. *Anat Embryol (Berl)* 1999;200:325-334.
- Kartus J, Movin T, Karlsson J. Donor-site morbidity and anterior knee problems after anterior cruciate ligament reconstruction using autografts. *Arthroscopy* 2001;17:971-980.
- Ardern CL, Webster KE, Taylor NF, Feller JA. Hamstring strength recovery after hamstring tendon harvest for anterior cruciate ligament reconstruction: A comparison between graft types. *Arthroscopy* 2010;26:462-469.
- Barret DS. Proprioception and function after anterior cruciate reconstruction. *J Bone Joint Surg B* 1991;73:833-837.
- Johansson H, Sjolander P, Sojka P. A sensory role for the cruciate ligaments. *Clin Orthop Relat Res* 1991;(268):161-178.
- Fromm B, Kummer W. Nerve supply of anterior cruciate ligaments and of cryopreserved anterior cruciate ligament allografts: A new method for the differentiation of the nervous tissues. *Knee Surgery, Sport Traumatol Arthrosc* 1994;2:118-122.
- Barrack RL, Skinner HB, Buckley SL. Proprioception in the anterior cruciate deficient knee. *Am J Sports Med* 1989;17:1-6.
- Kim HJ, Lee JH, Lee DH. Proprioception in patients with anterior cruciate ligament tears: A meta-analysis comparing injured and uninjured limbs. *Am J Sports Med* 2017;45:2916-2922.
- Relph N, Herrington L, Tyson S. The effects of ACL injury on knee proprioception: A meta-analysis. *Physiotherapy* 2014;100(3):187-195.
- Murray MM, Spector M. The migration of cells from the ruptured human anterior cruciate ligament into collagen-glycosaminoglycan regeneration templates in vitro. *Bio-materials* 2001;22:2393-2402.
- Murray MM, Bennett R, Zhang X, Spector M. Cell outgrowth from the human ACL in vitro: Regional variation and response to TGF- $\beta$ 1. *J Orthop Res* 2002;20:875-880.
- Steinert AF, Kunz M, Prager P, et al. Mesenchymal stem cell characteristics of human anterior cruciate ligament outgrowth cells. *Tissue Eng Part A* 2011;17:1375-1388.
- Murray MM, Kalish L, Fleming BC, et al. Bridge-enhanced ACL repair: Two year results of the first in human study. *Orthop J Sport Med* 2019;7:2325967118824356.
- Engebretsen L, Benum P, Fasting O, Molster A, Strand T. A prospective, randomized study of three surgical techniques for treatment of acute ruptures of the anterior cruciate ligament. *Am J Sports Med* 1990;18:585-590.