





## Case Report

# Retrograde ureteroscopic lithotripsy in cross-fused renal ectopia

Shinya Somiya,  Toshifumi Takahashi,  Katsuhiko Ito,  Yoshihito Higashi, Hitoshi Yamada and Toru Kanno 

Department of Urology, Ijinkai Takeda General Hospital, Kyoto, Japan

### Abbreviations

CFRE = cross-fused renal ectopia  
 CT = computed tomography  
 N.S. = not stated  
 UAS = ureteral access sheath  
 URSL = retrograde ureteroscopic lithotripsy  
 UVJ = ureterovesical junction

**Correspondence:** Toru Kanno M.D., Ph.D., Department of Urology, Ijinkai Takeda General Hospital, 28-1 Ishida Moriminami-cho, Fushimi-ku, Kyoto, 601-1495, Japan. Email: t.kan@kuhp.kyoto-u.ac.jp

### How to cite this article:

Somiya S, Takahashi T, Ito K, Higashi Y, Yamada H, Kanno T. Retrograde ureteroscopic lithotripsy in cross-fused renal ectopia. *IJU Case Rep.* 2021; 4: 232–234.

This is an open access article under the terms of the Creative Commons Attribution-NonCommercial-NoDerivs License, which permits use and distribution in any medium, provided the original work is properly cited, the use is non-commercial and no modifications or adaptations are made.

Received 8 February 2021;  
 accepted 7 April 2021.  
 Online publication 3 May 2021

**Introduction:** Cross-fused renal ectopia is a rare congenital malformation, and few cases of urolithiasis have been treated by retrograde ureteroscopic lithotripsy. We report a case of urolithiasis in right-to-left and superior-type cross-fused renal ectopia, successfully treated by the retrograde approach.

**Case presentation:** A 69-year-old woman with two 14-mm renal stones in cross-fused renal ectopia underwent retrograde ureteroscopic lithotripsy. Although we did not recognize the anomaly preoperatively, we could diagnose urolithiasis in the ectopic kidney intraoperatively. The patient had no complication, and follow-up computed tomography after 3 months showed only a 5-mm renal stone.

**Conclusion:** Although urolithiasis in patients with cross-fused renal ectopia is a challenging condition for the urologist, the retrograde approach is a safe and effective treatment method. It is necessary to carefully examine the urinary tract especially in a patient with a history of unidentified solitary kidney.

**Key words:** cross-fused renal ectopia, retrograde ureteroscopic lithotripsy, urolithiasis.

## Keynote message

The subject of this case report is a 69-year-old woman with renal stones in cross-fused renal ectopia. The patient underwent retrograde ureteroscopic lithotripsy with no complication. The retrograde approach is a safe and effective treatment method.

## Introduction

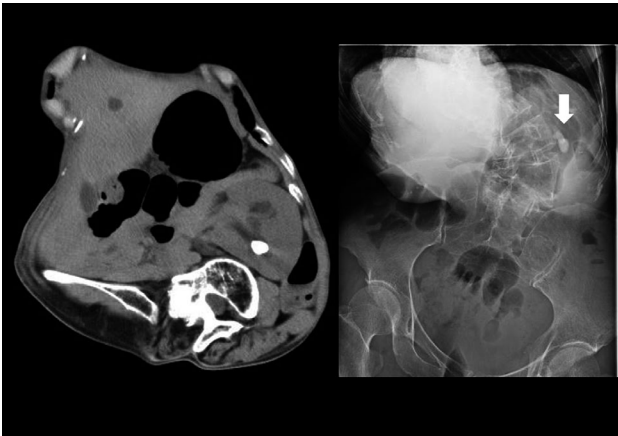
CFRE is a rare congenital malformation. In this condition, both kidneys are fused and located on the same side, whereas the ureter of the ectopic kidney crosses the midline and enters the bladder at its normal position. Although several cases of urolithiasis have been reported, few cases have been managed by retrograde URSL. We report a case of urolithiasis in right-to-left and superior-type CFRE successfully treated by URSL.

## Case presentation

A 69-year-old woman presented to our hospital with enlarging renal stones. She had no relevant medical history, except for scoliosis and stones in the left solitary kidney. Noncontrast CT showed a left solitary kidney accompanied by two 14-mm stones located at the upper calyx, without any other abdominal abnormalities (Fig. 1). It is embarrassing, but we overlooked CFRE and misdiagnosed it as just solitary kidney. The renal function and other laboratory tests showed no abnormalities.

With the large volume of stones, percutaneous nephrolithotripsy would be preferred in many cases, but scoliosis made puncture difficult, while avoiding the bowel, and URSL was performed. A semi-rigid ureteroscope (Ureterorenoscope 8.0/9.8-Fr; Richard Wolf, Knittlingen, Germany) was used to reach the renal pelvis, but no stones were identified. Then, retrograde pyelography was performed but did not show the upper calyx. Suspecting complete ureteral duplication, the other ureteral orifice was examined, but no other orifice was found, except the right ureteral orifice.

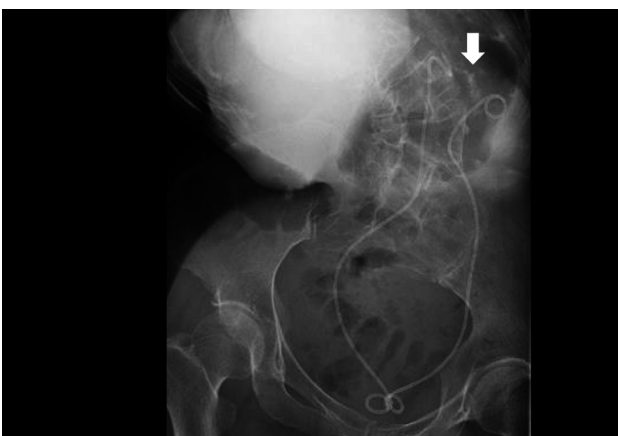A 0.035-inch guidewire was inserted into the right ureteral orifice and crossed the midline to reach the left upper calyx. This guidewire was placed as a safety wire, and another was



**Fig. 1** Preoperative CT and radiographic image showing 14-mm stone (arrow) located at the upper calyx

inserted as a working wire. The semi-rigid ureteroscope was inserted over the working guidewire to confirm the absence of stones and stenoses in the ureter. Since the ureter was large enough, a 12/14-Fr ureteral access sheath (UAS, Flexor<sup>®</sup>; Cook Medical, Bloomington, IN, USA) was passed over the guidewire under fluoroscopic guidance. Stones were detected by a flexible 8.4-Fr ureteroscope (URF-V3<sup>®</sup>; Olympus, Tokyo, Japan) and fractured to 2–3 mm with a 200- $\mu$ m holmium laser (Medilas H Solvo<sup>®</sup>; Dornier Medtech, Munchen, Germany). Finally, new 6-Fr double-J stents were inserted into both ureters because we place postoperative stent after URSL routinely, whether rigid or flexible (Fig. 2). The total operation time was 138 min and the calculus analysis was calcium oxalate.

She was discharged after 3 days without removal of right ureteral stent and prescribed an alpha-blocker as medical expulsive therapy because X-ray photo of kidney-ureter-bladder (KUB) showed stone street in lower ureter. KUB after 2 months showed no ureteral stones and the ureteral stent was removed. Follow-up CT after 3 months showed only a 5-mm renal stone and the patient did not want more treatment.



**Fig. 2** Radiographic image at one day postoperatively showing two double-J ureteral stent and many residual stones (arrow)

## Discussion

CFRE is known as a condition in which a kidney is located on the opposite side and fused and the ureter of the ectopic kidney inserts into the bladder in the original position. Although the exact incidence of CFRE is unknown because most patients are asymptomatic, the incidence rate is approximately 1 in 7500 to 1 in 1000 live births. CFRE is the second most common fusion anomaly after horseshoe kidney.<sup>1,2</sup> CFRE has been classified into six categories: inferior CFRE, sigmoid kidney, lump kidney, disc kidney, L-shaped kidney, and superior CFRE. While inferior CFRE is the most frequently observed type, superior CFRE is the least frequently observed. Since left-to-right CFRE develops three times more frequently than right-to-left ectopy, this is the rarest case in which the right kidney was located on the upper side of the left kidney.

In horseshoe kidney, the most common kidney fused anomaly, urolithiasis is the most common complication because impaired urinary drainage may cause crystal aggregation and infection. Like horseshoe kidney, it is believed that urinary drainage is impeded, and urolithiasis is likely to form in CFRE. Cao et al. reported 35 cases of CFRE associated with stones after a review of available literature. The treatment methods included open nephrectomy, open nephrolithotomy, conservative therapy, extracorporeal shock wave lithotripsy, percutaneous nephrolithotomy, URSL, and open or laparoscopic pyelolithotomy. In addition, the proportion of patients who did not need further treatment were five of five in open or laparoscopic surgery, six of six in conservative therapy, three of seven in extracorporeal shock wave lithotripsy, eight of nine in percutaneous nephrolithotomy<sup>3</sup>. To the best of our knowledge, only six cases of urolithiasis treated with URSL in patients with CFRE are reported in PubMed (Table 1).

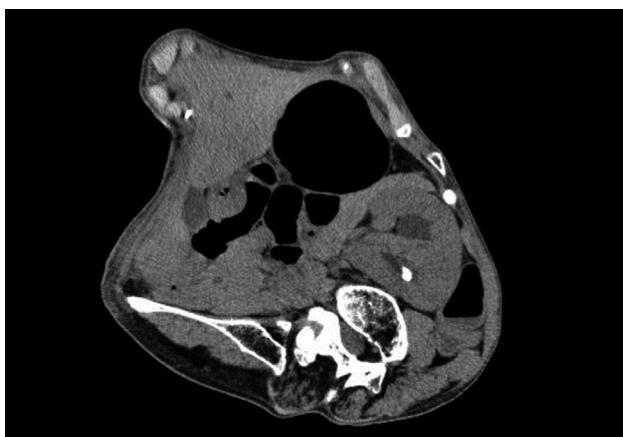Since twisting of the ureter to the other side causes tortuosities and angulations, we consider that straightening of the ureter is important. The use of UAS is recommended for anomalous kidneys to straighten the ureter and improve drainage after fragmentation.<sup>4</sup> Although extra care should be taken in CFRE while the UAS passes through the tortuosities or angulations to prevent inadvertent ureteral injury and perforation, the use of UAS may be especially important to straighten the ureter. Additionally, pre-stenting would be important to straighten the ureter and to help UAS, though preoperative stent is not discussed in previous report. In the current case, the use of two guidewires could have straightened the ureter and allowed the semi-rigid ureteroscope to reach the pelvis without preoperative stent. However, if CFRE was diagnosed before surgery, we would perform pre-stenting to easily and safely use UAS.

The point of reflection in this case is that the crossed-fused kidney was overlooked even though CT was performed. At a later time, a review of the preoperative CT result reveals at least a duplicated renal pelvis (Fig. 3). If duplicated renal pelvis had been suspected, retrograde pyelography or CT urography would have been performed, and the ureter leading to the superior calyx would have been

**Table 1** Previous reports on retrograde ureteroscopic lithotripsy in cross-fused renal ectopia

Author (year)	Age(years), sex	Side	UAS	Stone location	Size(mm)	Complication	Residual stone
Resorlu <sup>5</sup> (2015)	28, male	R to L	9.5/12Fr	Middle pole	15	No	N.S.
Ugurlu <sup>6</sup> (2015)	22, female	R to L	No	Upper calix	(85 mm <sup>2</sup> )	No	Yes
Singh <sup>4</sup> (2017)	N.S.	L to R	Yes	N.S.	N.S.	N.S.	No
Huang <sup>2</sup> (2018)	51, female	L to R	No	UVJ	8	No	No
Huang <sup>2</sup> (2018)	62, female	L to R	No	Lower ureter	15	No	No
Toussi <sup>7</sup> (2018)	69, female	L to R	11/13Fr	Mid ureter	7	No	No
Current case	69, female	R to L	12/14Fr	Upper calix	14	No	5 mm

R, right; L, left.

**Fig. 3** Preoperative CT showing duplicated renal pelvis

searched preoperatively. What we should learn from this case is to carefully evaluate preoperative CT results and carefully examine the urinary tract, considering the possibility of this disease, especially in a patient with a history of unidentified solitary kidney.

## Conclusion

Although urolithiasis in patients with CFRE is a challenging condition for the urologist, URSL is a safe and effective

treatment method. URSL can be a treatment option and should be considered before making a surgical decision. It is necessary to carefully examine the urinary tract especially in a patient with a history of unidentified solitary kidney.

## Conflict of interest

The authors declare no conflict of interest.

## References

- Shapiro E, Bauer SB, Chow JS. Crossed Renal Ectopia with and without Fusion. In: Wein AJ, Kavoussi LR, Novick AC (eds). *Campbell Walsh Urology*, 10th edn. Elsevier Saunders, Philadelphia, 2012; 3140–5.
- Huang L, Lin Y, Tang Z *et al.* Management of upper urinary tract calculi in crossed fused renal ectopic anomaly. *Exp. Ther. Med.* 2018; **15**: 371–6.
- Cao Y, Zhang Y, Kang W *et al.* Crossed-fused renal ectopia with renal calculi: two case reports and a review of the literature. *Medicine* 2019; **98**: e18165.
- Singh AG, Chhabra JS, Sabnis R *et al.* Role of flexible uretero-renaloscopy in management of renal calculi in anomalous kidneys: single-center experience. *World J. Urol.* 2017; **35**: 319–24.
- Resorlu M, Kabar M, Resorlu B, Doluoglu OG, Kilinc MF, Karakan T. Retrograde intrarenal surgery in cross-fused ectopic kidney. *Urology* 2015; **85**: e5–6.
- Ugurlu İM, Akman T, Binbay M *et al.* Outcomes of retrograde flexible ureteroscopy and laser lithotripsy for stone disease in patients with anomalous kidneys. *Urolithiasis* 2015; **43**: 77–82.
- Toussi A, Boswell T, Potretzke A. Ureteroscopic stone extraction in cross-fused renal ectopia. *J. Endourol. Case Rep.* 2018; **4**: 195–7.