



## Review

# Surgical Indications and Techniques for Adrenalectomy

Mehmet Uludağ,<sup>1</sup> Nurcihan Aygün,<sup>1</sup> Adnan İşgör<sup>2</sup>

<sup>1</sup>Department of General Surgery, Sisli Hamidiye Etfal Training and Research Hospital, Istanbul, Turkey

<sup>2</sup>Department of General Surgery, Bahcesehir University Faculty of Medicine, Istanbul, Turkey

### Abstract

Indications for adrenalectomy are malignancy suspicion or malignant tumors, non-functional tumors with the risk of malignancy and functional adrenal tumors. Regardless of the size of functional tumors, they have surgical indications. The hormone-secreting adrenal tumors in which adrenalectomy is indicated are as follows: Cushing's syndrome, arises from hypersecretion of glucocorticoids produced in fasciculata adrenal cortex, Conn's syndrome, arises from an hypersecretion of aldosterone produced by glomerulosa adrenal cortex, and Pheochromocytomas that arise from adrenal medulla and produce catecholamines. Sometimes, bilateral adrenalectomy may be required in Cushing's disease due to pituitary or ectopic ACTH secretion. Adenomas arise from the reticularis layer of the adrenal cortex, which rarely releases too much adrenal androgen and estrogen, may also develop and have an indication for adrenalectomy. Adrenal surgery can be performed by laparoscopic or open technique. Today, laparoscopic adrenalectomy is the gold standard treatment in selected patients. Laparoscopic adrenalectomy can be performed transperitoneally or retroperitoneoscopically. Both approaches have their advantages and disadvantages. In the selection of the surgery type, the experience and habits of the surgeon are also important, along with the patient's characteristics. The most common type of surgery performed in the world is laparoscopic transabdominal lateral adrenalectomy, which most surgeons are more familiar with. The laparoscopic anterior transperitoneal approach is the least preferred laparoscopic method in adrenalectomy. Retroperitoneal laparoscopic adrenalectomy can be performed with a posterior or lateral approach. In addition to conventional laparoscopy, laparoscopic surgery is robot-assisted, which can be administered by transperitoneal or retroperitoneal approach. In addition, conventional or robot-assisted laparoscopic adrenalectomy can be performed transabdominally or retroperitoneally using the single-port method. Today, partial adrenalectomy can be performed using laparoscopic techniques in bilateral adrenal masses, hereditary diseases with the risk of developing multiple adrenal tumors, and solitary masses of the adrenal gland. Open surgery is indicated in the case of malignancy or suspected malignancy and large tumors when laparoscopic surgery is contraindicated. The risk of conversion to open surgery is low (approximately 5%). The open transperitoneal anterior approach is the most common open intervention, especially in large tumors with malignancy or suspected malignancy. This procedure can be performed using a midline incision, bilateral or unilateral subcostal incision, Makuuchi or modified Makuuchi incision. Thoracoabdominal incision may be required, especially in the removal of large malignant lesions as a block. The open retroperitoneal approach can be applied posteriorly or laterally.

**Keywords:** Adrenalectomy; laparoscopic adrenalectomy; laparoscopic single-port adrenalectomy; partial adrenalectomy; robot-assisted adrenalectomy.

Please cite this article as "Uludağ M, Aygün N, İşgör A. Surgical Indications and Techniques for Adrenalectomy. Med Bull Sisli Etfal Hosp 2020;54(1):8-22".

The adrenal glands were first described in 1552 by Bartholomaeus Eustachius in his *Opuscula Anatomica* as "glandulae renis incumbents" (glands lying on the kidney). In 1805, Cuvier described two anatomical parts of the ad-

renals as cortex and medulla without mentioning any functional role of the glands.<sup>[1]</sup> Its function was understood after it was first described 300 hundred years ago. In 1855, Thomas Addison published his clinicopathologic observa-

**Address for correspondence:** Nurcihan Aygün, MD. Sisli Hamidiye Etfal Egitim ve Arastirma Hastanesi, Genel Cerrahi Klinigi, Istanbul, Turkey

**Phone:** +90 553 277 95 78 **E-mail:** nurcihanaygun@hotmail.com

**Submitted Date:** December 31, 2019 **Accepted Date:** December 31, 2019 **Available Online Date:** March 24, 2020

©Copyright 2020 by The Medical Bulletin of Sisli Etfal Hospital - Available online at [www.sislietfaltip.org](http://www.sislietfaltip.org)

**OPEN ACCESS** This is an open access article under the CC BY-NC license (<http://creativecommons.org/licenses/by-nc/4.0/>).



tions of 11 patients with the destruction of both adrenal glands and described the eponymous clinical syndrome. After Addison's work, the necessity of the adrenal glands for life was understood, and after that, many researchers began to investigate its functions.

In 1995, the London physiologists George Oliver and Edward Sharpey-Schafer described the presence of a substance in the adrenal medulla that elevated the blood pressure in dogs and named it adrenaline, which has been a turning point in endocrinology, proving the effects of endocrine organ secretion.

Their observation was confirmed in 1897 by John Abel, professor of pharmacology at the Johns Hopkins University School of Medicine, who isolated the active compound and named it epinephrine. In 1901, epinephrine was purified from the adrenal gland; subsequently, epinephrine and norepinephrine were first synthesized in Germany in 1904. The clinical effects of adrenal tumors began to be recognized with the physiological studies conducted in these periods. In the physiological studies that were conducted in these periods, the clinical effects of adrenal tumors started to be recognized. In 1912, Harvey Cushing described the classic features of his eponymous syndrome, and in 1955, Conn reported the first patient with primary hyperaldosteronism.<sup>[1]</sup>

Surgery of the adrenal glands emerged as part of abdominal surgery at the end of the 19<sup>th</sup> century. In 1889, Knowsley-Thornton realised the removal of a large left adrenal tumor of a 36-year-old female patient.<sup>[1]</sup> In 1914, the first planned adrenalectomy was performed by the British surgeon Perry Sargent.<sup>[2]</sup> In 1926, Roux in Lausanne, Switzerland, and Charles Mayo in Rochester, Minnesota, removed a pheochromocytoma successfully.<sup>[1]</sup> The flank approach was described by Charles Mayo in 1926 when he resected a pheochromocytoma, while the posterior approach was described by Young from Johns Hopkins in 1936.<sup>[3]</sup> Gagner et al. first described trans-abdominal laparoscopic adrenalectomy via the flank approach in the lateral decubitus position in 1992, after the adrenal surgery had been performed 100 years ago.<sup>[4]</sup> In 1994, retroperitoneal adrenalectomy in humans has been described in different regions of the world.<sup>[5,6]</sup>

## Embryology

The adrenal glands are two endocrine organs in one; an outer cortex and an inner medulla, each with distinct embryologic, anatomic, histologic, and secretory features.<sup>[7]</sup>

The cortex originates from mesodermal tissue near the gonads on the adrenogenital ridge in the fifth week of gestation. Therefore, ectopic adrenocortical tissue may be found in the ovaries, spermatic cord, and testes.<sup>[7]</sup>

The cortex is divided into two parts as a thin, definitive cortex and a thicker, inner fetal cortex. The fetal cortex produces fetal adrenal steroids but undergoes involution after birth. The definitive cortex persists after birth and forms the adult cortex during the first three years of life.

The fascicular and reticular zone proliferated from the glomerular layer of the adult cortex fully differentiated by about the 12<sup>th</sup> year.<sup>[1,7]</sup>

The adrenal medulla is ectodermal in origin that arises from the neural crest. During the same time as cortical development, neural crest cells migrate to the paraaortic and paravertebral areas and toward the medial side of the adrenal cortex to form the medulla. Most extra-adrenal neural tissue regresses but may persist at several sites. The largest of these is located to the left of the aortic bifurcation near the inferior mesenteric artery origin and is designated as the organ of Zuckerkandl. Adrenal medullary tissue also may be found in the neck, urinary bladder, and para-aortic regions. Although extra-adrenal paraganglioma mostly develops from the Zuckerkandl organ, paragangliomas may be found in different anatomic regions due to this embryological development.<sup>[7]</sup>

At birth, the adrenal gland is about one third the size of the kidney, but it is only about one-thirtieth its size in the adult. This change is not only because of renal growth but also due to the involution of the fetal cortex after birth.<sup>[1,7]</sup>

The cortex of the adrenal glands is darker yellow and has a fine granular surface and firm consistency compared with the surrounding perirenal fat. These macroscopic characteristics are found in cases of small-sized tumors, allowing for visual and tactile identification during adrenalectomy.

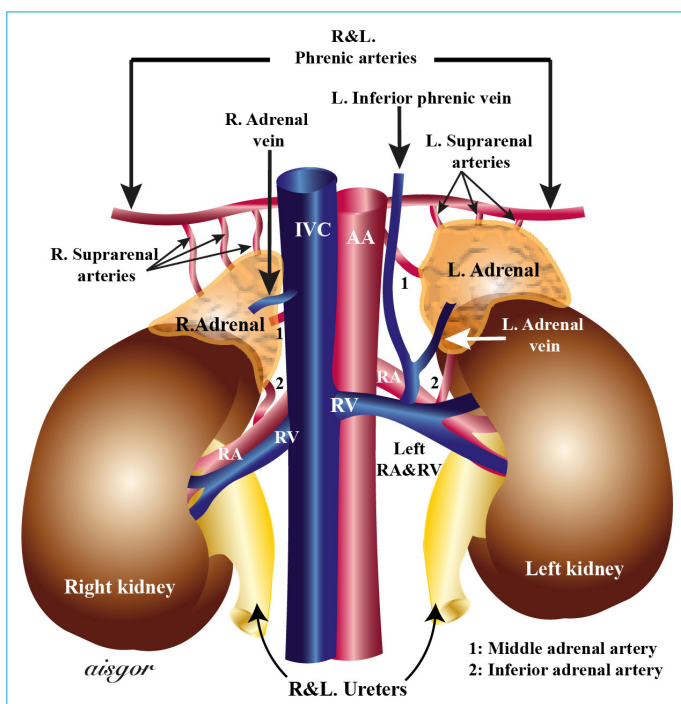
Each gland in the adult measures about 5 cm vertically, 3 cm transversely, and 1 cm in the anteroposterior plane. Each gland normally weights about 4-5 gr regardless of age, body weight, and gender but may weigh as much as 22 gr at autopsy, because of the stress of terminal illness.<sup>[1,7,8]</sup>

## Anatomy

### Adrenal and Kidney Relationship

The adrenal glands are in close contact with the kidneys. Right adrenal is mostly in suprarenal and left adrenal is in prerenal localization. Each adrenal gland-triangular on the right, crescent-shaped on the left caps the superomedial pole of each kidney. The right adrenal gland is mostly located suprarenally, while the left adrenal gland is located prerenally (Fig. 1).<sup>[8]</sup>

The adrenal glands are located in front of the 12<sup>th</sup> rib on the right, in front of the 11<sup>th</sup> and 12<sup>th</sup> ribs on the left, and on the lateral edge of the vertebral column.<sup>[8]</sup> The adrenal



**Figure 1.** Anatomy of the adrenal glands.

glands have a proper capsule investing them, which forms septa carrying vessels into the interior of the gland.<sup>[1]</sup> The adrenal glands are invested with a considerable amount of perirenal fat and enclosed by the renal fascia (Gerota fascia). The ventral and dorsal layers of the renal fascia extend upward surrounding the adrenal glands, and are attached to the diaphragm. They are held in position by the renal fascia attaching to the diaphragm, and by large renal veins and arteries. The adrenal glands are mobile, but they are fixed to the abdominal wall because they are attached to the diaphragm. They move with the diaphragm during respiration, explaining the difficulty encountered during hemostasis.<sup>[8]</sup>

### Topographic Anatomy

Topographic anatomy is important for radiological anatomy and adrenalectomy. Apart from the close relationship of the adrenal glands with the kidney, it also has close anatomy with other important anatomical structures. The topographic anatomy of the adrenals is examined as anterior, posterior surface and medial edge.

For each adrenal gland, the posterior and lateral approaches to adrenalectomy do not differ significantly.

**Posterior Relationship** Through the pararenal fat and the perirenal fascia, the adrenal glands are in contact with the superior part of the posterior abdominal wall. Each gland lies in close proximity to the diaphragmatic crus and the lateral arcuate ligament separating the adrenal glands

from the pleura; 11<sup>th</sup> and 12<sup>th</sup> ribs; and subcostal, sacrospinalis, and latissimus dorsi muscles.<sup>[8]</sup>

### Anterior and Medial Relationship

**Right Adrenal Gland:** The right adrenal gland is behind the inferior vena cava, and its medial side is 3 mm far from the lateral border of the cava and it is adjacent to the celiac ganglion. By its suprarenal location, the gland is not closely located to the renal arteries.

Vena cava separates the adrenal gland from Winslow foramen superiorly and duodenal loop and pancreas head inferiorly. The lateral upper part of the anterior face is in contact with the inferomedial bare area of the liver.<sup>[1]</sup>

The inferolateral of the anterior side is covered by the peritoneum between the liver, kidney and hepatic flexure. In laparoscopic or open adrenalectomy, after the mobilization of the organs, the peritoneum is opened and the right lobe of the liver and gallbladder are retracted upward while the colon is retracted downward.<sup>[8]</sup>

**Left Adrenal Gland:** The anterior side is covered with the periton of the omental bursa superiorly.<sup>[1]</sup> The inferior of the anterior face is not surrounded by the peritoneum, but adjacent to the medial edge of the spleen, the pancreas body and the splenic vein and splenic artery behind it. It is closely related to the transverse mesocolon at the inferior side of the pancreas. The pancreatic body separates the adrenal from the omental bursa and the stomach. The medial side of the adrenal gland is in front of the origin of the celiac truncus and is approximately 7 mm far from the aorta. Since the left adrenal gland is in prerenal localization, it is close to the left renal vein and renal sinus.

The retroperitoneal area can be entered by mobilising the left adrenal laterally via dividing the lateral connections of the spleen and the splenic flexure. In this region, dissection is made in the avascular plane and the spleen, pancreas body and veins in the front of the adrenal gland are mobilized and retracted to the right side. In another approach, especially in the condition of small adrenal glands after opening the gastrocolic ligament, the adrenal gland can be revealed by mobilizing the pancreas body via opening the peritoneum at the inferior and superior sides of the pancreas body in the bursa omentalis region.<sup>[8]</sup>

**Arterial Supply:** Each gland is supplied by three groups of vessels—the superior adrenal arteries derived from the inferior phrenic artery, the middle adrenal arteries derived from the aorta, and the inferior adrenal arteries derived from the renal artery. Other vessels originating from the intercostal and gonadal vessels may also supply the adrenals. These arteries branch into about 50 arterioles to form a rich plexus beneath the glandular capsule and require careful dissection and homeostasis control during adrenalectomy.<sup>[7,8]</sup>

## Venous Drainage

In contrast to the arterial supply, each adrenal usually is drained by a single adrenal vein. It is physiopathologically important to control this major vein, especially in tumors that secrete excess hormones. The right adrenal vein is usually short (5mm in length) and drains into the IVC, while the left adrenal vein is longer (30 mm in length) and empties into the left renal vein after joining the inferior phrenic vein (Fig. 1). Accessory veins occur in approximately 5% to 10% of the patients. On the right, these accessory vessels may drain into the right hepatic vein or the right renal vein; on the left; accessory veins may drain directly into the left renal vein.

These collateral vessels are a caval or portal shunt, and their significant development may occur in cases of large tumors.<sup>[7,8]</sup>

## Lymphatic Drainage

There are two lymphatic plexus in the adrenal, one lymphatic plexus is in the deep inside the capsule and the other lymphatic plexus is in the medulla. Many lymphatic vessels originate from the adrenal gland and these accompany large vessels. These lymphatic vessels end in the lateral aortic lymph nodes near the areas where the renal vein drains into the vena cava, paraaortic lymph nodes near the diaphragmatic crura and renal artery outlet. Some lymphatic vessels cross the diaphragm and drain into the ductus thoracicus or posterior mediastinum, which especially clarifies the development of local and distant metastases of adrenocortical cancers.<sup>[1,8]</sup>

## Nerve Distribution

The nerves are derived from the sympathetic visceral nervous system. The visceral afferent fibers arise from the sympathetic celiac ganglia. During adrenalectomy, nerves and vessels are ligated simultaneously.<sup>[8]</sup>

## Surgical Indications

Today, most of the adrenal masses are diagnosed incidentally due to the widespread use of ultrasonography and cross-sectional radiological imaging.

Autopsy studies suggest a prevalence of clinically unapparent adrenal masses of around 2%, which increases with age. Radiological studies report a frequency of 3% at the age of 50 years, which increases up to 10% in the elderly. Although most of these masses will be nonfunctional, approximately 71-84% in some series, there is a risk of functional adenoma (5%), pheochromocytoma (5%), adrenocortical cancer (<4%), and metastatic lesions (<2%).<sup>[9,10]</sup>

## Adrenalectomy indications are as follows:

**I. Functional adrenal tumors:** Regardless of the size of the hormone-producing tumors, they have surgical indications. The hormone-secreting adrenal tumors in which adrenalectomy is indicated are the followings: Cushing's syndrome, arises from hypersecretion of glucocorticoids produced in fasciculata adrenal cortex, Conn's syndrome, arises from an hypersecretion of aldosterone produced by glomerulosa adrenal cortex, and Pheochromocytomas that arise from adrenal medulla and produce catecholamines.<sup>[11]</sup> Sometimes, bilateral adrenalectomy may be required in Cushing's disease due to pituitary or ectopic ACTH secretion.<sup>[7]</sup> Rarely, adenomas arising from the reticularis layer of the adrenal cortex, hypersecreting androgen and estrogen, may require adrenalectomy.<sup>[7]</sup>

## II. Malignancy suspicion or malignant tumor:

**Adrenocortical cancer:** It is a rarely seen malignant tumor.

Approximately 50% of the adrenocortical cancers are non-functioning. The remaining secrete cortisol (15%), androgens (10%), estrogens (5%), aldosterone (1%), or multiple hormones (18%).<sup>[7]</sup>

**Malignant pheochromocytoma:** Approximately 12% to 29% of pheochromocytomas are malignant. It is not possible to diagnose malignancy with preoperative imaging methods. There are also no exact histological criteria for malignancy diagnose. Malignancy usually is diagnosed when there is evidence of invasion into surrounding structures or distant metastases by preoperative imaging methods and intraoperative exploration findings.

**Metastatic tumors:** The adrenal is a common site of metastases of lung and breast tumors, melanoma, renal cell cancer, and lymphoma. These patients may require adrenalectomy.<sup>[7]</sup>

**III: Non-functional tumors with malignancy risk:** For non-functional adrenal tumors, the indication for surgery is the risk of malignancy-related to the size of the lesion. If the lesions are smaller than 4 cm, the risk of malignancy is approximately 2%. For lesions of 4–6 cm, the risk of malignancy is 6%, while for lesions of 6 cm, the risk of malignancy is 25%.<sup>[11]</sup> 90% of adrenocortical tumors are larger than 4 cm in diameter at the time of diagnosis.<sup>[10]</sup> Especially, most of the adrenal masses detected incidentally are under 4 cm and are non-functional.<sup>[12]</sup> In patients with benign features in imaging methods, surgery is not required, and clinical and radiological follow-up is recommended. Since the risk of malignancy increases in masses over 4 cm, surgery should be considered individually in these lesions, even if the imaging features are benign.<sup>[7,9]</sup> However, some conditions, such as asymptomatic myelolipoma or simple cyst over 4 cm in diameter, may not need surgery.<sup>[12]</sup>

### Adrenalectomy Techniques

Adrenal surgery can be performed by laparoscopic or open technique. Both methods can be applied by transabdominal or retroperitoneal approach (Table 1).

Adrenalectomy may be performed using a laparoscopic or open approach. In either approach, the gland may be approached transabdominally or retroperitoneally.<sup>[7]</sup> Laparoscopic surgery can be applied conventionally or robotically (Table 1). Both methods can be applied with a single-port (Table 1).<sup>[13]</sup> The choice of surgical approach depends on the size and nature of the lesion, the patient’s general characteristics and the expertise of the surgeon.

Actually, laparoscopic adrenalectomy is considered as the gold standard treatment for the selected patients.<sup>[14]</sup> Laparoscopic transabdominal or retroperitoneoscopic operation, offer significant advantages over an open approach, including decreased hospital length of stay, postoperative pain, intraoperative blood loss, and overall 30-day postoperative complications, as well as mortality.<sup>[6,13]</sup>

### Laparoscopic Adrenalectomy

Laparoscopic adrenalectomy can be performed transabdominally or retroperitoneoscopically. The advantages and disadvantages of both approaches are described in Table 2. In the selection of the surgery type, the experience and habits of the surgeon are also important, along with the patient’s characteristics. The most common type of surgery

**Table 1.** Types of adrenalectomy

Open adrenalectomy	Transperitoneal	Anterior Toracoabdominal	
	Retroperitoneal		
Laparoscopic	Lateral		
	Posterior		
	Conventional	Transperitoneal	Lateral Anterior
		Retroperitoneal	Lateral Posterior
	Single port	Lateral transperitoneal Posterior transperitoneal	
	Robotic	Transperitoneal	Lateral Posterior Lateral
		Retroperitoneal	

**Table 2.** Advantages and disadvantages of transabdominal ve retroperitoneoscopic adrenalectomies<sup>[13,15]</sup>

	Laparoscopic Transabdominal	Retroperitoneoscopic
Avantages	Easier to learn The whole abdomen can be explored Can be combined with other abdominal operations Large workspace for large tumors More suitable in obese patients Conversion to open surgery is easier and faster	It is not necessary to mobilize other organs It is not affected by abdominal surgeries Does not require intraperitoneal insufflation (patients with cardiovascular or respiratory problems) In the same position for bilateral adrenalectomy Less pain Short surgery time Less complicated Increasing cosmesis
Disadvantages	Mobilizing other organs Risk of injury in intraperitoneal organs Long surgery time The need to re-position the patient for bilateral adrenalectomy Possible difficulty in those who have previously had abdominal surgery Postoperative adhesion risk Incisional hernia risk	More difficult to learn Not suitable for obese patients Not suitable for large tumors Limited workspace Increased risk of intraocular pressure in prolonged cases
Contraindications	Failure to tolerate pneumoperitoneum Suspected malignancy or high risk of malignancy (Adrenocortical cancer or pheochromocytoma) Invasion into neighboring organs	Inability to tolerate prone position Suspected malignancy or high risk of malignancy (Adrenocortical cancer or pheochromocytoma) Invasion into neighboring organs

performed in the world is laparoscopic transabdominal adrenalectomy, which most surgeons are more familiar with. Although transabdominal adrenalectomy is frequently performed with a lateral approach, it can also be performed with an anterior approach. Here, the transabdominal adrenalectomy with the laparoscopic lateral approach, which we also apply frequently, will be described in detail.

### Laparoscopic Transabdominal Lateral Adrenalectomy

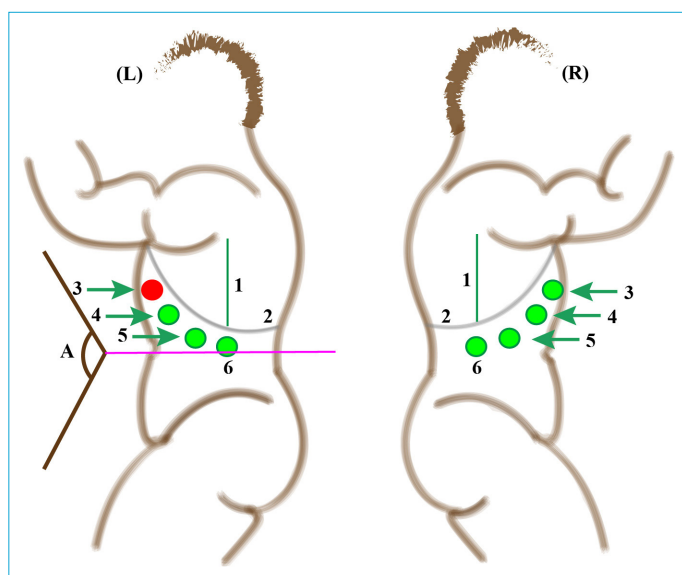
**Patient Position:** Patients should be placed in a supine position on the operating table.

After the induction of general anesthesia, a nasogastric tube and/or Foley catheter are usually placed. The patient is turned to a lateral decubitus position with the affected side up. An axillary pillow is placed, and the elevated arm is placed on an elevated arm board. The superior iliac spine should be positioned at the breakpoint of the operating table, and the bed is flexed to increase working space.

The table is flexed approximately 100-120° relative to the ground plane to maximize the distance between the iliac crest and the costal margin (Fig. 2L).

The surgeon and assistant both stand on the same side, facing the front of the patient and the monitor stands at the head side of the patient.<sup>[15]</sup>

**Port Placement:** Initial peritoneal access is achieved 2 cm inferior to the right/left costal margin in the midclavicular



**Figure 2.** Port placement on the left and right sides in Laparoscopic Transabdominal Lateral Adrenalectomy.

(L): left, (R): right, 1: middle axillary line, 2: rib edge, 3: assistant port (it may not be placed while performing left adrenalectomy) 4: laparoscopic port, 5 and 6: working ports. Pink line: The plane demonstrating where the table is flexed approximately 100-120° relative to the ground plane.

line, with either the blind (Verres Needle) access or with the optical access (Hasson) trocar and CO<sub>2</sub> insufflation is performed. Pneumoperitoneum is also induced by an open approach at the site of the first trocar. A pressure of 12–14 mmHg is generally used for CO<sub>2</sub> insufflation.<sup>[15]</sup>

In general, four 10-mm trocars are placed between the midclavicular line medially and anterior axillary line laterally, 2 cm below the costal margin. Additional ports may be placed, if needed.<sup>[7]</sup>

The first port is entered through the anterior axillary line, and usually, four ports on the right and three or four ports on the left can be used for adrenalectomy (Fig. 2). On the right side, the one on the anterior axillary line and the two ports placed medially can be used as a working port, and the third one can be used as a camera port (30° laparoscope). However, the instruments and ports may be changed to provide optimum exposure, as needed. The port on the midclavicular line is usually used as a liver retractor.<sup>[7]</sup>

The second port on the lateral side can be applied as 10 mm and the other three ports can be applied as 5 or 10 mm. In order for laparoscopic instruments to move easily, more than 5 cm distance should be left between the ports.<sup>[15]</sup>

For the liver retractor, the fourth port from the middle axillary line can be applied instead of the midclavicular port. Adrenalectomy can be performed through three ports placed 5 cm apart from the anterior axillary line on the left side. To retract the pancreas and spleen, the fourth port can be applied medially on the midclavicular line or laterally on the middle axillary line.<sup>[13]</sup>

Upon entry into the peritoneal space, the abdomen is inspected for any injuries due to port placement and any other pathology.

**Right Adrenalectomy:** Atraumatic grasper and L-hook cautery are entered through two working ports. A retractor is placed under the liver, the liver is retracted, and the right triangular ligament of the liver is firstly divided. The posterior peritoneum is opened, starting from the triangular ligament to the inferior vena cava medially with cautery, 1 cm away from the liver margin. The Gerota fascia is exposed and divided. It is important for the assistant to provide adequate retraction of the liver in a superomedial direction while the surgeon provides countertraction on the adrenal gland and kidney in an inferolateral direction to expose the plane adequately.

First, the superomedial side of the adrenal is dissected. Harmonic scalpel® (Ethicon Endo-Surgery INC- Johnson & Johnson Medical SPA, NJ, USA) or LigaSure™ (Medtronic, Minneapolis, MN, USA) can be used during this dissection.

The adrenal vein is revealed by retracting the adrenal laterally and carrying the dissection from the medial side of the adrenal to the lateral side of the vena cava. The right adrenal vein is typically encountered just inferior to where the IVC enters the liver. The adrenal vein is dissected circumferentially, and the vena cava side is clipped with two clips. The adrenal side is clipped with one clip and divided with endoscopic scissors.

In approximately 20% of cases, an accessory adrenal vein is encountered 2–3 cm above the main adrenal vein and, when present, should be dissected, clipped, and divided.<sup>[6]</sup> Alternatively, the adrenal vein can be divided with vascular staples. Then, the inferomedial side of the gland is dissected. The adrenal gland, with its periadrenal fat tissue, is divided from the upper pole of the kidney. As on the left side, it is important to identify and preserve any superior pole renal arteries that are present.<sup>[13]</sup>

Then, the adrenal is lifted up, and the dissection is completed at the posterior and lateral aspect of the gland and finally superiorly. The gland is placed in a retrieval bag and removed from the 12-mm port site. Trocar sites can be enlarged if needed. Port site closure is recommended in order to prevent incisional hernias.<sup>[6,13,15]</sup> Ligation of the adrenal vein is recommended by many authors as the first stage of adrenalectomy. However, in large adrenal masses, the appropriate dissection area may not be provided for the identification of the adrenal vein at the initial stage. Therefore, the dissection of the adrenal vein should be done when it is safe. Early ligation of the vein will make the dissection even more difficult due to venous congestion, and some authors suggest that adrenal vein should be dissected as late as possible.<sup>[7]</sup>

### Complications of Right Adrenalectomy

The general complications related to the laparoscopic approach may occur as bowel and vascular injuries, gas embolism, operative difficulties linked to adhesions, obesity. As a result of inappropriate port placement or inadequate mobilization, difficulties may arise due to the inappropriate surgical view. In the right adrenalectomy, there are some specific side-related problems as follows: liver injury, duodenum injury, vena cava injury, hepatic vein Injury, right adrenal vein Injury, kidney Injury, division of a polar renal artery, rupture of the adrenal capsule and injury of the diaphragm.<sup>[6,13]</sup>

**Left Adrenalectomy:** The first step of the procedures is the mobilization of the spleen, accomplished by dissecting the splenoparietal ligament. The lateral decubitus position allows for easy exposure of the splenoparietal ligament. The dissection of the splenoparietal ligament is starting at

the posterior and inferior edge of the spleen, taking care to left a margin of about 2 cm of peritoneum for an effective retraction of the spleen allowing the exposition of its posterior aspect. The splenoparietal ligament dissection is continued until the diaphragm, far enough to visualize the fundus of the stomach and the left crus of the diaphragm. The full dissection of the splenoparietal ligament allows a complete mobilization of the spleen. Then, the dissection proceeds with the dissection of the splenorenal ligament, starting from the posterior aspect of the spleen and continuing with the tail of the pancreas. The avascular plane between the tail of the pancreas and Gerota fascia is dissected.<sup>[6]</sup> Peripancreatic fat tissue is golden, and perirenal fat under Gerota's fascia is paler.<sup>[13]</sup> At this point, the splenopancreatic bloc is displaced medially, out of the operative field, with the aid of the gravity, and the kidney upper pole and the adrenal area are exposed.

If necessary, the pancreas tail and spleen are retracted with the retractor entered through the port placed medially or laterally. The Gerota fascia is divided through the diaphragm.

The dissection of the left adrenal should start on the medial aspect of the gland proceeding from upper to lower adrenal pole, keeping close to the posterior muscular plane. Small arteries encountered during this dissection are divided by energy devices. The region where the adrenal vein is located is revealed by retracting the adrenal laterally. Dissection is carried out until the left adrenal vein is exposed on the inferomedial side of the adrenal. During this dissection, left inferior diaphragmatic vein is frequently encountered in the medial side of the gland. Since the left inferior diaphragmatic vein runs along the medial side of the gland and joins the left adrenal vein, following the left inferior diaphragmatic vein contributes to the exposure of the adrenal vein. The left adrenal vein, which drains to the left renal vein and longer than the right adrenal vein is found and divided. Renal vein side can be clipped and divided with two clips, adrenal side with one clip or divided with energy device. The left inferior phrenic vein may also require clipping.<sup>[6,15]</sup>

The left adrenal gland often has a tail of tissue that extends toward the hilum of the kidney. This requires the gland to be dissected from the superior pole of the kidney at a location immediately adjacent to the capsule of the kidney by including all periadrenal fat with the specimen for an oncologically sound resection. Care should be taken at this stage to identify and protect any superior renal arteries. The adrenal upper pole is dissected lastly, allowing the 'hanging technique'. Dissection can be performed using a hook, coagulating scissors or energy devices. The adrenal

within the retrieval bag is removed through a 10–12 mm trocar.<sup>[13]</sup> The placement of a drain in the adrenal lodge is optional but rarely needed.<sup>[6,7]</sup> Some authors advise the placement of a drain.<sup>[6]</sup>

### **Complications of Left Adrenalectomy:**

Intra-abdominal organ injury may occur during port replacement. There may be intraabdominal organ injury when port is placed. As a result of inappropriate port placement or inadequate mobilization, difficulties may arise due to the inappropriate surgical view. Specific side-related problems that may be observed for left adrenalectomy are splenic artery and vein injury, spleen and pancreatic injury and gastric injury. Bleeding may occur due to dissection through the wrong plane. Left adrenal or left inferior phrenic veins may become injured. Especially in large tumors, the left renal vein might be divided by mistake, supposing it to be a wide adrenal vein. There may be left kidney upper pole artery injury, kidney parenchymal injury, capsular rupture of the gland, and rupture of the diaphragm.<sup>[6,13]</sup>

### **Laparoscopic Transabdominal Anterior Adrenalectomy**

Anterior laparoscopic approach is the least preferred technique employed for adrenalectomy. The patient is placed in a supine position, the first entry in the abdominal cavity is performed in the umbilicus, and three other additional trocars are placed in various configurations. Although it allows treating other abdominal pathologies simultaneously and also can be performed bilaterally without changing the patient's position, it requires a longer operative time and higher number of port placement due to the sub-mesocolic approach.<sup>[11]</sup>

### **Posterior Retroperitoneal Laparoscopic Adrenalectomy**

The patient is intubated in the supine position, the vascular access is performed, and a Foley catheter is inserted if necessary. The patient is turned to the prone position, and the table is flexed to maximize the distance between the posterior rib edge and the pelvis in the jackknife position. The surgeon stands on the adrenal side to be removed, the assistant on the opposite side. A 1.5-cm incision is placed 2 cm inferior and parallel to the twelfth rib, the subcutaneous and posterior muscle layers are crossed, and the retroperitoneal area is reached, and the surgeon can dissect the posterior of the Gerota fascia by finger.

A 12-mm trocar is then reinserted into this space, and CO<sub>2</sub> is insufflated to 12 to 15 mmHg pressure. The 0° laparoscope is replaced by a 45° laparoscope. Two additional 5- or 10-mm trocars are placed, one each on either side of the first port. The laparoscopic ultrasound is then used to help locate

the adrenal gland and vessels. The adrenal dissection is begun at the superior pole and then proceeds to the lateral and inferior aspect. The medial dissection usually is performed last, and the vessels are identified and divided, as described in the earlier "Lateral Transabdominal Approach" section.<sup>[7,13,15]</sup> Access to the correct space is confirmed by feeling the smooth internal surface of the twelfth rib.<sup>[13]</sup>

With the Hasson trocar, the retroperitoneal area can be reached under direct laparoscopic view. Retroperitoneum can be inserted with a finger, or with a balloon dissector. A 12-mm trocar is then reinserted into this space, and CO<sub>2</sub> is insufflated to 12 to 15 mmHg<sup>[7]</sup> or 20–25 mmHg CO<sub>2</sub>.<sup>[16]</sup> One 5 or 10 mm working port is entered laterally to the camera port, from the middle axillary line, and one port medially to the camera port, immediately from the lateral side of the paraspinous muscle. 30° or 45° camera is used.<sup>[13]</sup>

The major landmarks for this operation consist of the paraspinous muscle medially, the edge of the peritoneum laterally, the perirenal space, including kidney, adrenal gland, perirenal fat anteriorly, and the ribs, posteriorly. A high insufflation pressure provides adequate visualization and tamponades any small bleeding vessels. Hypercarbia and crepitus may develop and brief periods of desufflation or lower insufflation pressures may be required.<sup>[13]</sup>

Mobilization of the adrenal gland inferiorly by pushing down on the kidney allows the superior attachments of the adrenal lifting the gland superiorly. The adrenal vein should then be identified as dissected free and divided. The rest of the adrenal attachments are then ligated with energy-based devices.<sup>[15]</sup>

The adrenal vein to be identified and divided lastly as described in the earlier "Lateral Transabdominal Approach" section.

In this approach, the adrenal dissection is begun at the superior pole and then proceeds to the lateral and inferior aspect. The medial dissection usually is performed last, and the adrenal vein is exposed and divided.<sup>[7]</sup>

### **Lateral Retroperitoneal Laparoscopic Adrenalectomy**

In this type of surgery, the patient is placed in the position as in the lateral transabdominal method. Port locations are similar to the posterior retroperitoneal laparoscopic approach. The port at the anterior side of the camera port can also be placed on the anterior axillary line instead of the middle axillary line. If necessary, the fourth port can be inserted on the anterior axillary line, 5–7 cm inferiorly to the anterior port. Once pneumoretroperitoneum is established, identification of key landmarks helps to establish the orientation. The psoas muscle is usually easily seen and



establishes longitudinal orientation. By retracting the kidney upward and anteriorly, subsequent medial dissection eventually reveals the great vessels running parallel to the psoas muscle. The renal artery can be identified by identifying pulsations, although full mobilization of the renal hilar vessels is generally not necessary during adrenalectomy. Unlike transperitoneal laparoscopy, the dissection and identification of the left adrenal vein must be done from a posterior approach.<sup>[16]</sup>

### Single-incision or Single-port Laparoscopic Adrenalectomy

Laparoscopic adrenalectomy can be performed transabdominally or retroperitoneally using the single-port method.<sup>[17,18]</sup>

Some studies compared the conventional laparoscopic approach with single-port adrenalectomy, demonstrating no significant differences in patient length of stay or morbidity and a small benefit in cosmesis and postoperative pain with single-port laparoscopy. Data on this approach remain limited, and further studies are necessary.<sup>[11]</sup>

### Robot-assisted Adrenalectomy

Although as compared to open adrenalectomy laparoscopic adrenalectomy involves lesser blood loss, pain, shorter hospital stay and better cosmesis, it is riddled with certain shortcomings, such as the need for dexterity, two-dimensional vision, dependence on an assistant for the camera. Robotic adrenalectomy overcomes the limitations of laparoscopic surgery by providing a three-dimensional magnified view, better ergonomics, control of the camera and multi-articulated instruments to the surgeons. Higher cost and longer operating times have although prevented, robotic adrenalectomy from gaining widespread acceptance. Depending upon the body habitus of the patient and experience of the surgeon, either the transperitoneal route or retroperitoneal approach can be safely used to perform robotic adrenalectomy. It is also reported to be a feasible method for performing partial adrenalectomy.<sup>[19]</sup>

### Partial Adrenalectomy

Partial (or sub-total) adrenalectomy or cortex preserving adrenalectomy was first proposed by Irvin et al.<sup>[20]</sup> in 1983 for the treatment of hereditary, bilateral pheochromocytoma to preserve adrenocortical function and avoid lifelong steroid replacement therapy. In 1996, partial adrenalectomy results using retroperitoneoscopic laparoscopic method were reported.<sup>[21]</sup>

Nowadays, in bilateral adrenal masses, as well as hereditary diseases with the risk of developing multiple adrenal

tumors, solitary masses in adrenal are also among the indications for partial adrenalectomy. Partial adrenalectomy should be performed, especially in hormone-active small tumors, to avoid the risk of malignancy. In nonfunctional cortical tumors, partial adrenalectomy should not be considered. In these cases, the surgical indication is represented by the diameter and tumor growth at the time of diagnosis related to suspicion of malignancy. In these cases, total adrenalectomy should be mandatory.

There is a trend towards the use of partial adrenalectomy in the treatment of small adrenal masses. Thus, minimally invasive partial adrenalectomy may become the recommended standard treatment of small benign and hormonal active adrenal tumours.<sup>[22]</sup>

**Surgical Principles:** Preservation of the vascular supply to the adrenal stump is a crucial issue in adrenal-sparing surgery

Minimal tissue dissection and manipulation are required in partial adrenalectomy.

The adrenal vein originates directly from the adrenal medulla. In peripheral functional cortical tumors, the main adrenal vein should be preserved, allowing the correct function of the adrenal medulla in these patients. In pheochromocytoma, the adrenal vein should be divided to prevent hypertensive crisis due to the discharge of catecholamines secreted from the medulla into the venous system. There are studies reporting that if the adrenal vein is divided on one side in bilateral patients, its protection on the other will result in better adrenal cortex function as a result of better venous drainage. However, there are studies reporting good adrenal cortex function in patients with adrenal vein divided into both sides. In fact, when the adrenal remnant is left in place without excessive and unnecessary mobilization, both diaphragmatic and retroperitoneal collateral arteries and veins can provide adequate vascular supply and drainage. In such cases, the use of intraoperative ultrasound can be helpful in localising tumors without unnecessary dissection.

For radical resection and remnant that will maintain adequate cortical function, it is recommended to leave at least a 3-5 mm thickness surgical margin on the tumor side.

Energy-based devices and staples can be used in the transaction of adrenal tissue. Furthermore, fibrin glue or other local hemostatic agents can be used. In this way, the incidence of acute and postoperative bleeding becomes very low, as observed after total adrenalectomy.<sup>[22,23]</sup> Partial adrenalectomy can be performed with conventional or single-port laparoscopic techniques, and also robot-assisted.

## Open Adrenalectomy

### Patient Selection

#### Malignancy or Suspicion of Malignancy

Open adrenalectomy is preferred in patients with suspected malignancy, ACC or malignant pheochromocytoma. In ACC, the risk of capsule rupture with manipulation is higher, and minimally invasive surgery may increase the risk of rupture.<sup>[13]</sup>

Disease recurrence in some studies was shown to occur earlier and more often in patients treated for ACC by minimally invasive approaches due to a higher rate of intraoperative tumor spillage and positive margins. Overall survival was also found to be shorter in Stage 1 and Stage 2 patients who underwent laparoscopic resection.<sup>[24]</sup> Open surgery should be preferred in patients requiring lymphatic dissection with adrenalectomy.<sup>[9]</sup> In particular, the open approach is the best choice for locally advanced tumors with invasion into adjacent organs or major vessels.<sup>[13]</sup> It is difficult to diagnose malignancy in pheochromocytoma preoperatively. Although large pheochromocytomas of up to 8–10 cm may still be approached laparoscopically by surgeons in high volume centers,<sup>[25]</sup> open resection is recommended for large (e.g., 6 cm) or invasive pheochromocytomas to ensure complete tumor resection, prevent tumor rupture and avoid local recurrence (Table 3).<sup>[26,27]</sup>

#### Tumor Diameter

One of the open surgical indications is tumor diameter. There is no precise threshold for the tumor diameter. Open surgery is recommended for tumors over 6 cm without malignancy or suspicion of malignancy with no local invasion.<sup>[9,28]</sup>

Some studies report that laparoscopic resection of ACC or potentially malignant tumors, including removal of surrounding periadrenal fat and results in an R0 resection without tumor capsule rupture, may be performed for pre- and intraoperative stage 1–2 ACC and tumors with diameter <10 cm.<sup>[29]</sup> Although there is no defined size threshold, larger tumors (especially >10 cm) have a higher risk of malignancy.<sup>[14]</sup> Although there is no sign of malignancy in preoperative imaging, open surgical intervention is recommended for masses over 12 cm (Table 3).<sup>[11,13]</sup>

#### Relative contraindications of laparoscopic surgery:

Although previous abdominal surgery and obesity have been reported as relative contraindications for laparoscopic surgery, laparoscopic surgery can be performed in many of these patients (Table 3).

#### Contraindication of Laparoscopic Surgery

Open surgery may be required in high-risk patients with

coagulopathy and cardiopulmonary disease. Although previous abdominal surgery and obesity have been reported as relative contraindications for laparoscopic surgery, laparoscopic surgery can be performed in many of these patients (Table 3).

#### Conversion to Open Surgery in Laparoscopic Surgery

The risk of conversion to open surgery is low (approximately 5%).<sup>[29]</sup> Laparoscopic adrenalectomy should be converted to open operation in case there is macroscopic appearance suspicious of malignancy (invasion in surrounding structures, presence of regional lymphadenopathy) if the surgeon is concerned that the tumour could not be removed without avoiding tumor spillage, intraoperative incidents like uncontrolled bleeding that cannot be managed laparoscopically (Table 3).<sup>[25]</sup>

#### Techniques of Open Surgery

Open surgery is usually performed using a transperitoneal anterior approach. The lateral extraperitoneal approach is a good choice for obese patients. The posterior approach avoids the morbidity of a laparotomy incision, especially in patients with cardiopulmonary disease and patients who are prone to wound complications (Cushing's syndrome) and avoids abdominal adhesions in patients who have un-

**Table 3.** Indications for open adrenalectomy

Malignancy or suspicion of malignancy
Adrenocortical cancer
Locally invasive tumor
Regional lymph node metastasis
Malignant pheochromocytoma
Locally invasive tumor
Regional lymph node metastasis
Tumor having malignancy potential
Tumor diameter
>6 cm ACC with no local invasion
> 6cm pheochromocytoma
>12 cm adrenal mass
Laparoscopy is contraindicated
coagulopathy
High risky patients with cardiopulmonary disease
Relative contraindications for laparoscopy
Obesity
Previous abdominal surgery
Conversion to open surgery
Detected intraoperative local invasion
Detected regional lymph node metastasis
Unable to remove the tumor completely (without spillage)
Unable to control the laparoscopic intraoperative complication

dergone previous abdominal surgery. However, retroperitoneal exposure is difficult, particularly in obese patients. The small working space makes it unsuitable for tumors >6 cm in diameter. The open transperitoneal anterior approach will be described in detail.<sup>[7]</sup>

### Transperitoneal Anterior Approach

Today, open surgery is performed, especially in large tumors with malignancy or suspicion of malignancy, and the anterior approach is the most common open intervention.

### Incision Selection

In the anterior approach, four incisions are frequently used as follows: midline incision, subcostal (bilateral (Chevron incision) or unilateral) incision, Makuuchi ("J") or modified Makuuchi incision, the thoracoabdominal incision (Fig. 3).<sup>[7,13,30]</sup>

Several factors should be considered when deciding the optimal incision:

- Size of tumor and need for any concomitant resection (e.g., nephrectomy, nonanatomic or anatomic hepatectomy), or vascular reconstruction;
- Location of the mass and direction of invasion;
- The position of the patient during conversion from a laparoscopic procedure.<sup>[13]</sup>

### Open Right Adrenalectomy

In particular, open surgery in malignant tumors is described here.

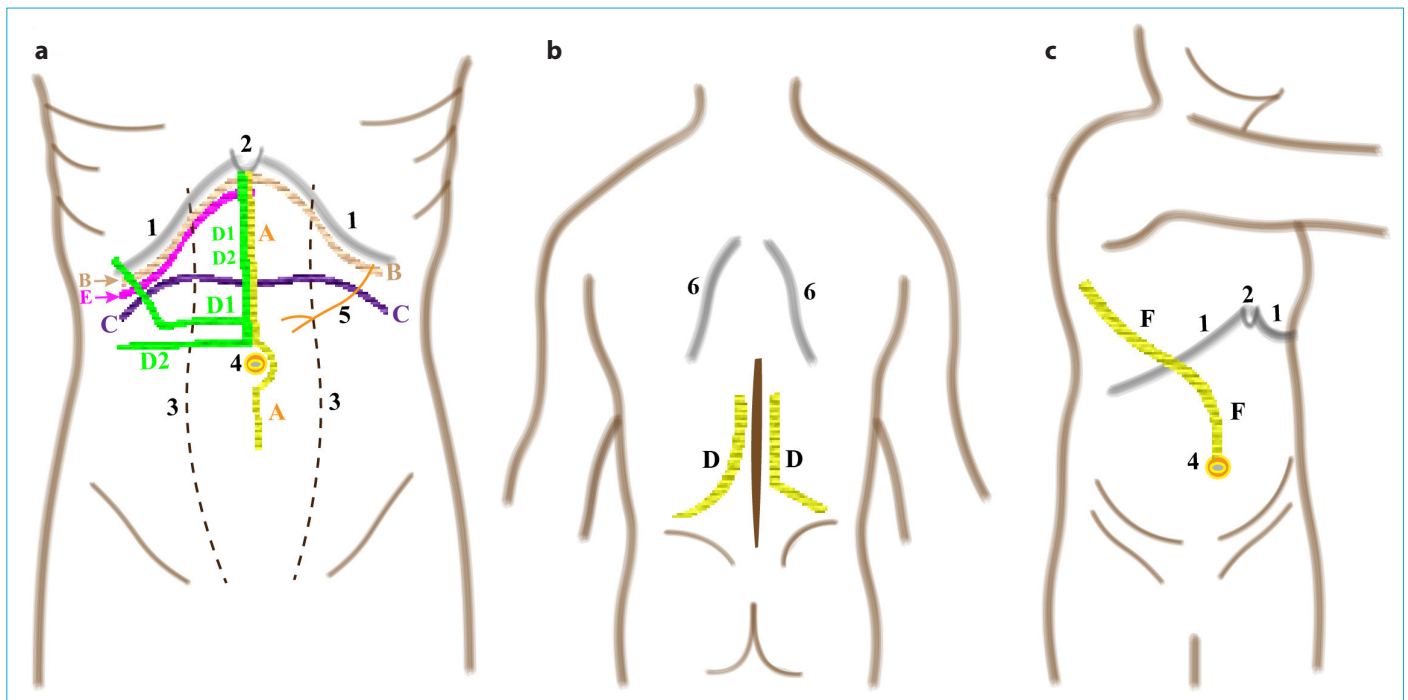
After the initial general inspection of the abdominal cavity, the operation starts by mobilising the colonic hepatic flexure by dividing the lateral part of the gastrocolic ligament and the peritoneal reflection over the ascending colon. To achieve full access to inferior vena cava, the duodenum is Kocherised (Fig. 4A red arrow).<sup>[25]</sup>

### Mobilisation of the Liver

Thompson retractor is placed (self-retaining Thompson retractor) for the retraction of the ribs. The 'mobility' of the liver has to be increased by dividing the falciform ligament and the lateral triangular ligament, and if needed, coronary ligament is divided. The full mobilization of the liver and its superomedial retraction provide complete access to the right adrenal gland, inferior vena cava and kidney (Fig. 4A green arrow).<sup>[13,25]</sup> If the tumor is found to be invading the posterior aspect of the liver, a thin rim of the liver can be resected. In general, the posterior peritoneal lining should be considered as the tumor's anterior margin.<sup>[24]</sup>

### Mobilisation of the Kidney

In small, non-invasive tumors, dissection is sufficient up to the upper half of kidney  $\frac{1}{2}$ . The Gerota fascia is inserted, the



**Figure 3.** Incision options in Open Adrenalectomy (A: Transperitoneal approach, B: Retroperitoneal approach, C: Toracoabdominal approach). 1: rib edge, 2: inferior end of the sternum, 3: Lateral sides of the rectus muscle, 4: umbilicus, 5:9. Intercostal nerve, 6: medial sides of the scapula, (a) midline incision, (b) bilateral subcostal incision, (c) bilateral transverse incision, D1-2: makuuchi incision, (d) posterior approach incision, (e) right subcostal incision, (f) thoracoabdominal incision.

perinephric fat tissue on the upper pole is dissected, and dissection is continued to the plane between the adrenal gland and the kidney. This tissue forms the inferior surgical margin of the specimen.<sup>[24]</sup>

The posterior and lateral sides of the mass are dissected together with the fatty tissue around the tumor. Lastly, the medial dissection is performed, starting over the anterior aspect of the vena cava. The medial aspect of the dissection is an area at high risk for microscopic residual disease due to a little intervening fat between tumor and vena cava. Then, the short, right adrenal vein is dissected, ligated, and divided, taking care not to injure the hepatic veins and IVC.<sup>[7,24]</sup>

### Resection in Locally Advanced Tumors

In locally advanced tumors, R0 resection should be achieved by also resection of the surrounding organs. With a right ACC, the vena cava is also inspected for either obvious invasion or intracaval tumor thrombus.

If adherence to or invasion of the adrenal vein or vena cava is identified, primary resection and closure if the vena cava is not narrowed higher than 50% can be performed to obtain a negative margin. If the defect after resection is big, resection and replacement of the vena cava with a bovine pericardial or vein patch or polytetrafluoroethylene graft can be performed.<sup>[24]</sup>

If the tumor cannot be safely exposed due to intense adhesion or invasion, the vena cava may require subdiaphragmatic control for bleeding control. The liver is fully mobilised off the diaphragm until the suprahepatic veins are demonstrated. The left triangular ligament is divided and the crus of the diaphragm are dissected in order to be ready for clamping IVC if needed. The distal control is provided via dissecting IVC under the right renal vein and suspending it.<sup>[25]</sup>

One out of three patients with adrenocortical carcinoma presents with the involvement of the venous system and IVC thrombus. Tumours of the right adrenal gland frequently involve the IVC due to the right adrenal vein directly draining into it.<sup>[31]</sup>

In the presence of tumor thrombus in the inferior vena cava, it has to be removed with the tumor. The technique used for intra-operative venous control depends on the location and extension of the tumour/thrombus in the venous circulation; the extension of the thrombus should be detected with the preoperative imaging studies.<sup>[31]</sup>

Cross clamping of the IVC is sufficient if the upper limit of the tumour/thrombus is below the hepatic veins. Hepatic vascular exclusion (HVE) is needed if the tumour/thrombus extends into the hepatic veins or into the retro- or supra-

hepatic IVC. In case of subdiaphragmatic tumor thrombus, venous control is provided by cardiopulmonary bypass and hypothermic circulatory arrest (HCA).<sup>[31]</sup> If there is any question of local invasion into the kidney parenchyma or renal hilar vessels, partial nephrectomy or total nephrectomy should be performed to ensure an R0 resection. In some cases, the kidney may be able to be spared if the renal hilar vasculature is not involved, and the renal capsule can be included as part of the inferior margin.

If the tumor is found to be invading the posterior aspect of the liver, a thin rim of the liver can be resected as part of the anterior margin.<sup>[24]</sup>

When there is a direct involvement in the liver, anatomical or nonanatomic hepatectomy should be added to the surgery with the support of hepatobiliary surgeon. If the tumor seems to involve the diaphragm, a portion of the diaphragm can be excised and closed primarily or with mesh.<sup>[24]</sup>

### Open Left Adrenalectomy

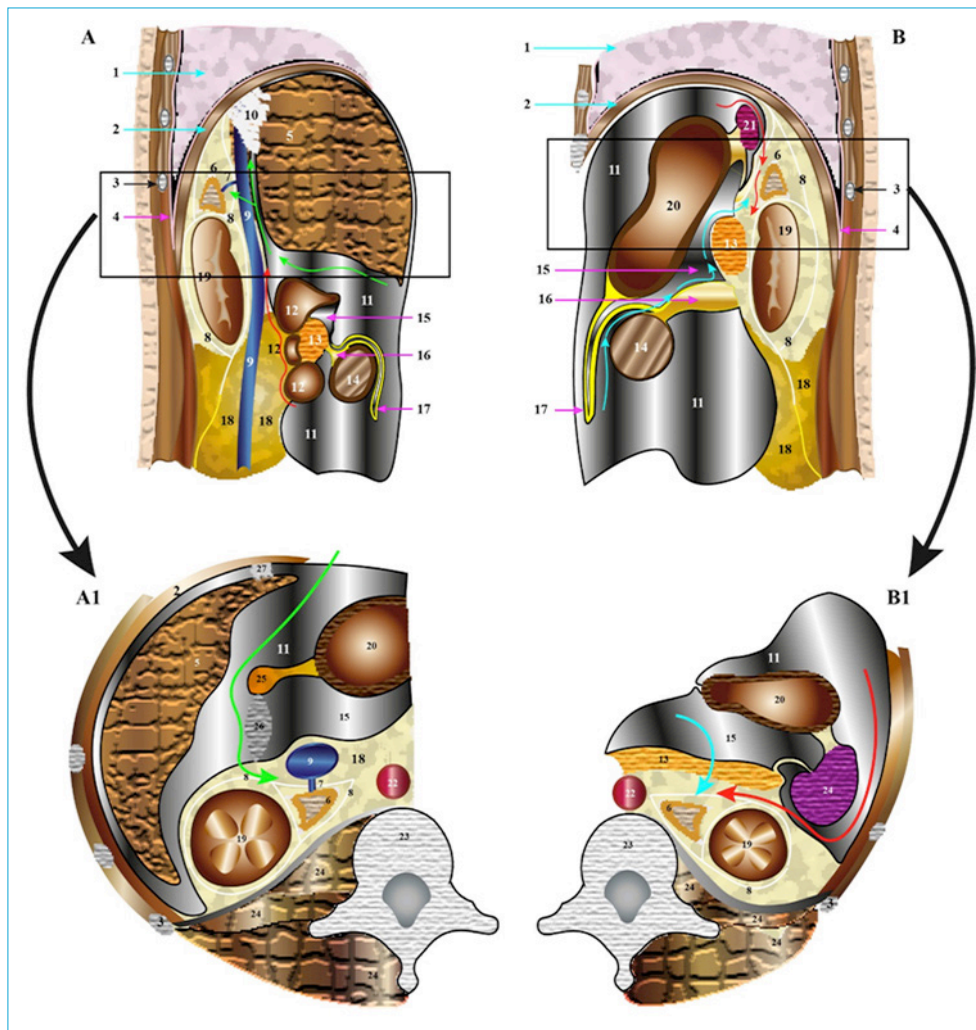
Firstly, the splenic flexure is mobilised by dividing the gastrotocolic ligament and the peritoneal reflection along the descending colon so that the left colon mobilised distally and towards the midline until the fourth part of duodenum becomes visible (Fig. 4B green arrow). In large tumors with no definite invasion in the neighboring organs, the dissection is continued superiorly and the spleen is then released from its attachments to the level of the esophageal hiatus. The stomach, spleen, pancreas, and colon are all retracted medially to visualize the kidney, left adrenal gland, and aorta (Fig. 4B red arrow).<sup>[24,25]</sup>

The remainder of the operation is carried out similarly to the right side. The left adrenal vein is typically identified inferomedially near the 7 or 8 o'clock position on the gland and is ligated and divided at its insertion into the left renal vein. Careful assessment of the left adrenal vein and its junction with the left renal vein is necessary to ensure no intravenous thrombus remains.

### Resection in Locally Advanced Tumors

If there is an involvement of the spleen, it is resected. Identifying the splenic artery at the upper border of the pancreas early during the dissection minimizes the blood loss during en bloc resection.<sup>[25]</sup> Partial or total nephrectomy may be performed if the kidney is involved. In total, nephrectomy and retroperitoneal dissection are performed from lateral to medial, starting at the lower pole of the kidney.<sup>[25]</sup>

In large tumors, the pancreas tail can be stretched over the tumor. Pancreas invasion is rare. It can be performed if distal pancreatectomy is required for safe surgical margins. Since the postoperative pancreatic leak is common, drains



**Figure 4.** (a) Sagittal view of the area between the sagittal planes passing through the Duodenum-Kidney-Adrenal and one third lateral of IVC. (a1) Transverse cross section of the area marked with rectangle in Figure 4A. (b): Sagittal view of the area between the sagittal planes passing through the left side of aorta and left kidney-adrenal. (b1) Transverse cross section of the area marked with rectangle in Figure 4A. Green, Red and Cyan colored arrows Show the way to reach the adrenal glands.

1: Lung, 2: Diaphragm, 3: ribs, 4: Parietal pleura, 5: Liver, 6: Adrenal, 7: right adrenal vein, 8: Gerota fascia, 9: Vena cana inferior, 10: right Triangular ligament, 11: peritoneal cavity, 12: Duodenum (1-2-3 parts), 13: pancreas, 14: transverse colon, 15: Small peritoneal cavity (lesser sac), 16: transverse mesocolon, 17: omentum major, 18: retroperitoneal area, 19: Kidney, 20: Stomach, 21: Spleen, 22: Aorta, 23: Vertebra, 24: posterior muscles, 25: hepato-duodenal ligament, 26: foramen winslow, 27: Falsiform ligament.

should be placed in the surgical area.<sup>[25]</sup>

### The Role of Lymphadenectomy

Currently, lymph node dissection has not been a formal component of radical adrenalectomy. If the patient has highly suspect or diagnosed adrenocortical cancer, locoregional lymphadenectomy is recommended. Lymphadenectomy should include periadrenal and renal hilar nodes.<sup>[9]</sup>

### Open Extraperitoneal Posterior Adrenalectomy (Fig. 3B)

The posterior approach avoids the morbidity of a laparotomy incision, especially in patients with cardiopulmonary

disease and the patients who are prone to wound complications (Cushing's syndrome) and avoids abdominal adhesions in patients who have undergone previous abdominal surgery.

Recovery time is also quicker and hospitalization shorter. However, the retroperitoneal exposure is difficult, particularly in obese patients, and the small working space makes it unsuitable for tumors >6 cm in diameter.

The patient is placed in prone position on the operating table. The patient is entubated, vascular access is provided and Foley catheter is placed if needed. A hockey stick

incision may be used. The twelfth rib generally is excised, and the eleventh rib is retracted superiorly. The pleura is revealed and mobilized cephalad. The adrenal and kidney are identified.<sup>[7]</sup>

**Open Extraperitoneal Lateral Adrenalectomy** The lateral approach is best for obese patients and also for large tumors because it provides a larger working space. The patient is placed in a lateral position with the table flexed. Extraperitoneal area is reached using a subcostal incision or an incision between the eleventh and twelfth ribs. The dissection then is performed as indicated previously in "Anterior Approach."<sup>[7]</sup>

Open extraperitoneal adrenalectomy decreases the rate of postoperative ileus; however, it is associated with high rates of chronic pain, laxity in flank muscles, and flank numbness.<sup>[11]</sup>

### Open Adrenalectomy with Toracoabdominal Approach (Fig. 3C)

The thoracoabdominal approach is most useful for en bloc resection of large (>10 cm), malignant lesions. However, it is associated with significant morbidity and should be used in selected patients.<sup>[7]</sup>

#### Disclosures

**Peer-review:** Externally peer-reviewed.

**Conflict of Interest:** None declared.

**Authorship Contributions:** Concept – M.U., A.İ.; Design – M.U., A.İ.; Supervision – M.U., A.İ.; Materials – M.U., N.A., A.İ.; Data collection &/or processing – M.U., N.A.; Analysis and/or interpretation – M.U., A.İ.; Literature search – M.U., N.A.; Writing – M.U.; Critical review – A.İ.

#### References

- Maccara D, Mihai R. Surgical embryology and anatomy of the adrenal glands. In: Clark OH, Duh QY, Kebebew E, editors. *Textbook of Endocrine Surgery*. 3rd ed. Jaypee Brothers Medical Publishers; 2016. p. 957–72.
- Prager G, Heinz-Peer G, Passler C, Kaczirek K, Schindl M, Scheuba C, et al. Surgical strategy in adrenal masses. *Eur J Radiol* 2002;41:70–7.
- Prinz RA, Madorin K. Open operative Approaches to the adrenal gland. In: Clark OH, Duh QY, Kebebew E, editors. *Textbook of Endocrine Surgery*. 3rd ed. Jaypee Brothers Medical Publishers; 2016. p. 1081–8.
- Gagner M, Lacroix A, Bolté E. Laparoscopic adrenalectomy in Cushing's syndrome and pheochromocytoma. *N Engl J Med* 1992;327:1033.
- Alesina PF. Retroperitoneal adrenalectomy-learning curve, practical tips and tricks, what limits its wider uptake. *Gland Surg* 2019;8:S36–40.
- Raffaelli M, De Crea C, Bellantone R. Laparoscopic adrenalectomy. *Gland Surg* 2019;8(Suppl 1):S41–S52.
- Lal G, Clark OH. Thyroid, parathyroid and adrenal. In: Brunucardi FC, Andersen DK, Billiar TR, Dunn DL, Hunter JG, Matthews JB, et al, editors. *Schwartz's Principles of Surgery*. 11th ed. New York: McGraw Hill; 2019. p. 1625–704.
- Avisse C, Marcus C, Patey M, Ladam-Marcus V, Delattre JF, Flament JB. Surgical anatomy and embryology of the adrenal glands. *Surg Clin North Am* 2000;80:403–15.
- Fassnacht M, Arlt W, Bancos I, Dralle H, Newell-Price J, Sahdev A, et al. Management of adrenal incidentalomas: European Society of Endocrinology Clinical Practice Guideline in collaboration with the European Network for the Study of Adrenal Tumors. *Eur J Endocrinol* 2016;175:G1–34.
- Jason DS, Oltmann SC. Evaluation of an Adrenal Incidentaloma. *Surg Clin North Am* 2019;99:721–9.
- Alemanno G, Bergamini C, Prosperi P, Valeri A. Adrenalectomy: indications and options for treatment. *Updates Surg* 2017;69:119–25.
- Gimm O, Duh QY. Challenges of training in adrenal surgery. *Gland Surg* 2019;8:S3–9.
- Madani A, Lee JA. Surgical Approaches to the Adrenal Gland. *Surg Clin North Am* 2019;99:773–91.
- Smith CD, Weber CJ, Amerson JR. Laparoscopic adrenalectomy: new gold standard. *World J Surg* 1999;23:389–96.
- Carr AA, Wang TS. Minimally Invasive Adrenalectomy. *Surg Oncol Clin N Am* 2016;25:139–52.
- Wang DS, Terashi T. Laparoscopic adrenalectomy. *Urol Clin North Am* 2008;35:351–vii.
- Tunca F, Senyurek YG, Terzioglu T, Iscan Y, Tezelman S. Single-incision laparoscopic adrenalectomy. *Surg Endosc* 2012;26:36–40.
- Machado MT, Nunes-Silva I, da Costa EF, Hidaka AK, Faria EF, Zampolli H, et al. Laparoendoscopic single-site retroperitoneoscopic adrenalectomy: bilateral step-by-step technique. *Surg Endosc* 2017;31:3351–2.
- Pahwa M. Robot-assisted adrenalectomy: current perspectives. *Robot Surg* 2017;4:1–6.
- Irvin GL 3rd, Fishman LM, Sher JA. Familial pheochromocytoma. *Surgery* 1983;94:938–40.
- Walz MK, Peitgen K, Hoermann R, Giebler RM, Mann K, Eigler FW. Posterior retroperitoneoscopy as a new minimally invasive approach for adrenalectomy: results of 30 adrenalectomies in 27 patients. *World J Surg*. 1996;20(7):769–774.
- Colleselli D, Janetschek G. Current trends in partial adrenalectomy. *Curr Opin Urol* 2015;25:89–94.
- Cavallaro G, Polistena A, D'Ermo G, Letizia C, De Toma G. Partial adrenalectomy: when, where, and how? Considerations on technical aspect and indications to surgery. *Eur Surg* 2012;44:150–4.
- Long SE, Miller BS. Adrenocortical Cancer Treatment. *Surg Clin North Am* 2019;99:759–71.
- Mihai R. Open adrenalectomy. *Gland Surg* 2019;8:S28–35.

26. Lenders JW, Duh QY, Eisenhofer G, Gimenez-Roqueplo AP, Grebe SK, Murad MH, et al; Endocrine Society. Pheochromocytoma and paraganglioma: an endocrine society clinical practice guideline. *J Clin Endocrinol Metab* 2014;99:1915–42.
27. Henry JF, Peix JL, Kraimps JL. Positional statement of the European Society of Endocrine Surgeons (ESES) on malignant adrenal tumors. *Langenbecks Arch Surg* 2012;397:145–6.
28. Gaujoux S, Mihai R; joint working group of ESES and ENSAT. European Society of Endocrine Surgeons (ESES) and European Network for the Study of Adrenal Tumours (ENSAT) recommendations for the surgical management of adrenocortical carcinoma. *Br J Surg* 2017;104:358–76.
29. Thompson LH, Nordenström E, Almquist M, Jacobsson H, Bergenfz A. Risk factors for complications after adrenalectomy: results from a comprehensive national database. *Langenbecks Arch Surg* 2017;402:315–22.
30. Ruffolo LI, Nessen MF, Probst CP, Jackson KM, Ruan DT, Schoeniger LO, et al. Open adrenalectomy through a makuuchi incision: A single institution's experience. *Surgery* 2018;164:1372–6.
31. Greco R, Tsappa I, Mihai R, Petrou M. Surgical management of adrenal tumours extending into the right atrium. *Gland Surg* 2019;8:S53–9.