

# A Case of DEB-TACE Combined with Anlotinib for Treatment of Liver Metastasis from Retroperitoneal Leiomyosarcoma

Huiying Cui, Qiang Xu, Zhezhu Han, Songnan Zhang

Department of Oncology, Yanbian University Hospital, Yanji, 133000, People's Republic of China

Correspondence: Songnan Zhang, Department of Oncology, The Affiliated Hospital of Yanbian University, No. 1327 Juzi Street, Yanji City, Jilin Province, 133000, People's Republic of China, Email zhangsn21@163.com

**Background:** Retroperitoneal soft tissue sarcomas are characterized by a high rate of local recurrence and distal metastases. The optimal treatment for prolonged survival remains unknown.

**Case Presentation:** This study reports a patient with leiomyosarcoma (LMS) diagnosed through postoperative recurrence with failed systemic chemotherapy. The patient underwent retroperitoneal tumor resection and surgical pathology showed LMS. A CT scan of the abdomen was performed one year after the surgical procedure, which revealed the presence of multiple intrahepatic metastases. Two cycles of systemic chemotherapy with a combination of doxorubicin and ifosfamide were performed, after which imaging assessment showed the intrahepatic lesions were significantly enlarged compared to prior ones. Considering the failure of systemic chemotherapy, the patient was treated with drug-eluting bead transarterial chemoembolization (DEB-TACE) eight times with simultaneous targeted therapy with anlotinib, and the disease control time reached 29 months.

**Conclusion:** This case provides a new treatment option for patients with multiple liver metastases from retroperitoneal leiomyosarcoma, which is discussed in the context of this case.

**Keywords:** DEB-TACE, retroperitoneal soft tissue sarcoma, leiomyosarcoma, targeted therapy

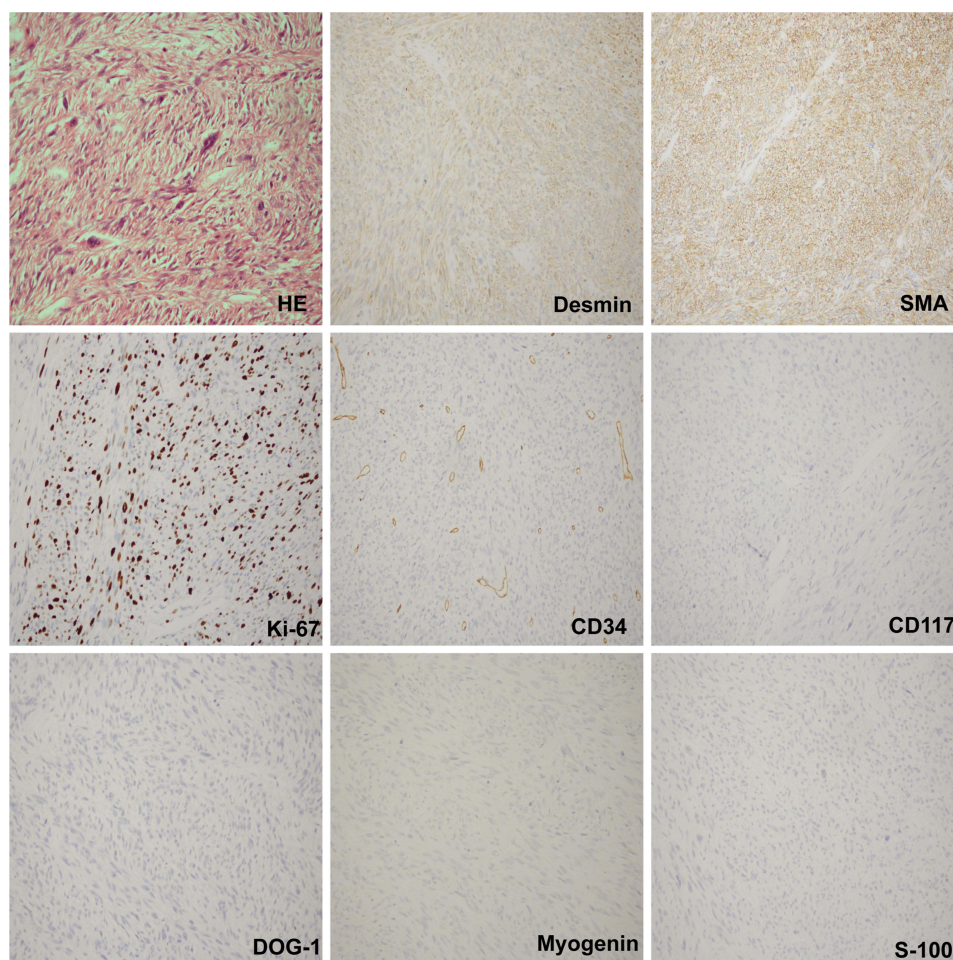
## Introduction

Leiomyosarcoma (LMS) is a malignant mesenchymal tumor originating from smooth muscle tissue. LMS is relatively rare, accounting for approximately 10–20% of soft tissue sarcomas, and is prone to distant metastasis (5-year distant recurrence rate of 50%).<sup>1–4</sup> The clinical symptoms are nonspecific, abdominal masses are mostly found on physical examination owing to epigastric discomfort, and the prognosis is poor, with metastasis to the lungs and liver. The 5-year overall survival rate is 20% to 30%, despite attempts at aggressive treatment such as a combination of surgery, radiotherapy, and chemotherapy. Nearly 50% of patients will relapse after local therapy, and the average overall survival for stage IV disease is approximately 11–15 months.<sup>5</sup> ALBI grading makes it easier to detect negatively correlated changes in hepatic reserve function during repeat TACE procedures.<sup>6</sup> Drug-carrying microspheres transhepatic arterial chemoembolization (DEB-TACE) is a new TACE modality that utilizes drug-carrying microspheres loaded with highly concentrated chemotherapeutic agents to embolize the tumor while slowing down the process within the lesion while slowly releasing the chemotherapeutic agents to treat liver tumors.<sup>7</sup> Previous studies have confirmed the efficacy of DEB-TACE in the treatment of primary hepatocellular carcinoma and liver metastases, but fewer studies have focused on liver metastases from leiomyosarcoma. This study reports a patient with LMS diagnosed by postoperative pathology. Subsequent imaging showed that the patient developed multiple intrahepatic metastases. This study reports on a patient diagnosed with LMS by postoperative pathology. Subsequent imaging showed multiple metastases within the patient's liver. The patient was treated with transarterial chemoembolisation (TACE) in combination with anlotinib,

which is a treatment for multiple metastases in the liver. The condition was assessed as partial response (PR) according to RECIST 1.1 criteria and the patient achieved progression-free survival (PFS) of 29 months.

## Case Presentation

In 2020, a 69-year-old woman experienced intermittent abdominal pain and a palpable mass the size of an egg in the left abdomen. She visited our hospital's general surgery department, where imaging studies of the chest and abdomen suggested a mass in the left mid-abdomen, considered malignant, invading the local ureter, and associated with hydronephrosis. After a multidisciplinary consultation with the hospital's general surgery, oncology and urology departments, laparoscopic retroperitoneal tumour resection was performed by the general surgery and urology departments. Postoperative pathology indicated a retroperitoneal leiomyosarcoma (Size 9×4.5×4.5cm) (Figure 1). According to the CSCO guidelines, the AJCC stage was IIIB, and the MSTS stage was also IIIB. One month after surgery, due to the patient's poor physical condition and significant resistance to chemotherapy, she received adjuvant radiotherapy of 50 Gy to the surgical area and concurrently took oral herbal medicine (cinobufagin). One year after the operation, she presented again at our hospital because of abdominal pain. A CT scan of the abdomen revealed multiple liver metastases. A liver puncture biopsy confirmed the diagnosis of liver metastases from retroperitoneal leiomyosarcoma. She underwent two cycles of systemic chemotherapy with a combination of doxorubicin and ifosfamide. Two months later, imaging evaluations showed a significant increase in intrahepatic lesions, suggesting disease progression (PD). We performed genetic testing on the patient, which showed negative microsatellite instability (MSI), low tumor mutation burden

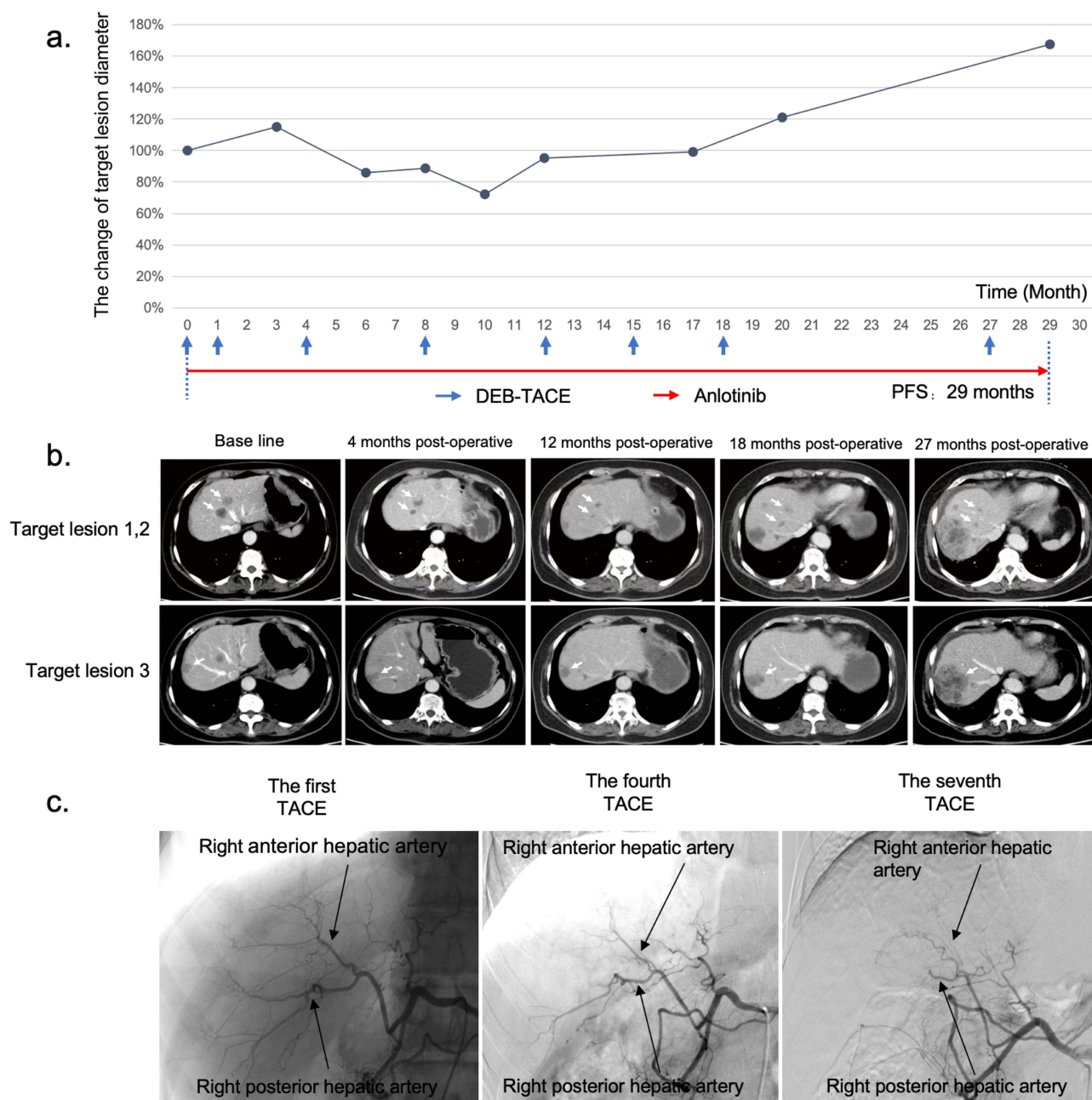


**Figure 1** The postoperative pathological results of a left retroperitoneal mass, combined with immunohistochemical staining results, consistent with leiomyosarcoma. The immunohistochemical findings are as follows (Scale bar, 200  $\mu$ m): HE; Desmin (+); SMA (+); Ki-67 (index 50%+); CD34 (-); CD117 (-); DOG-1 (-); Myogenin (-); S-100 (-).

(TMB), and only TP53 gene mutation detected. Because no specific target was identified, we switched to a treatment regimen of DEB-TACE in combination with anlotinib.

## Treatment and Follow-up

On December 3, 2021, we performed the first DEB-TACE treatment with a mixture of CareSphere (Hengrui, 100–300  $\mu$ m) and epirubicin (50 mg) for embolization (Figure 2c). Oral anlotinib (8 mg once daily, the medication regimen is to take the drug continuously for two weeks, followed by a one - week drug - free period. The drug should be



**Figure 2** (a) The change chart of the target lesion diameter. (b) The changes of target lesions 1, 2, and 3 in the portal venous phase of the whole abdomen enhanced CT at the first, third, fifth, seventh, and last times. (White arrows point to target lesions). (c) The first TACE imaging from December 3, 2021, with DSA clearly depicting the right posterior and anterior hepatic arteries and their branches. The fourth TACE imaging from August 24, 2022, where DSA reveals noticeable atrophy and narrowing of the right posterior and anterior hepatic arteries compared to the previous image. The seventh TACE imaging from June 21, 2023, with DSA showing significant atrophy and narrowing of the right posterior and anterior hepatic arteries, with no obvious staining observed in their branches.

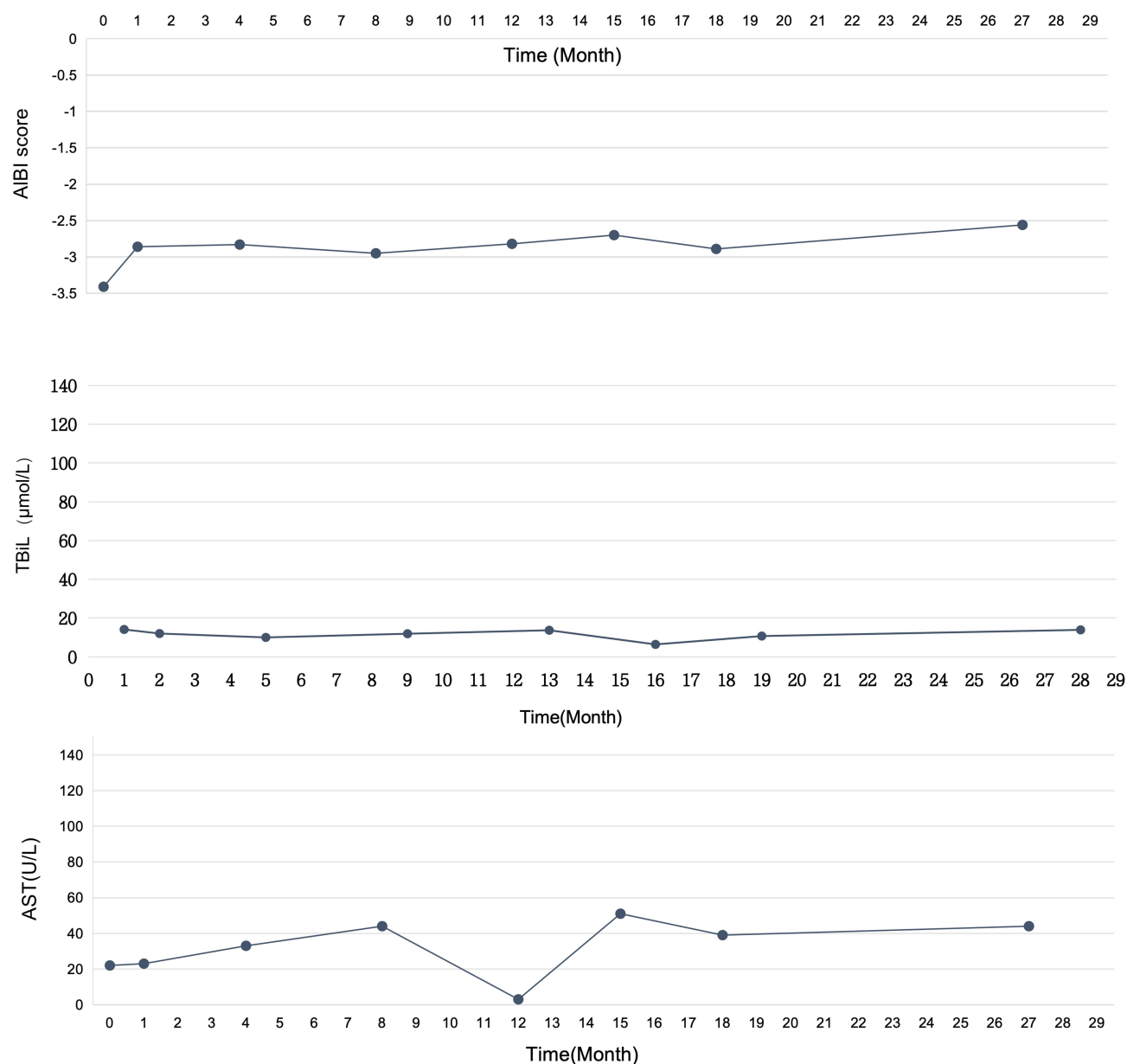


discontinued before, after, and on the day of the interventional treatment). was started on the third postoperative day. An abdominal CT scan was performed on January 19, 2022, for efficacy assessment against the three intrahepatic lesions according to RECIST 1.1 criteria. It was found that target lesion 3 showed PD), whereas target lesions 1 and 2 were stable disease (SD) (Figure 2a and b), and thus we performed a second DEB-TACE. An enhanced CT was reviewed on April 10, 2022. The efficacy assessment results showed PR. Subsequently, four DEB-TACEs were performed on April 13, August 24, December 16, 2022, and March 23, 2023 (again using a mixture of CareSphere (Hengrui, 100–300 µm) and epirubicin (50 mg) for embolization). During treatment, we periodically reviewed the abdominal CT to assess the efficacy of the intrahepatic target lesions, which were considered stable (Figure 2a and b). In the enhanced CT evaluation of the upper abdomen on June 13, 2023, target lesions 1 and 2 showed SD, whereas target lesion 3 was in PR. Therefore, we planned to perform hepatic arteriography, which showed significant atrophy and thinning of the main trunk of the hepatic artery, slow blood flow velocity, and no significant staining of its branches, with poor visualization of the intrahepatic lesions (Figure 2c). Considering the effects of multiple interventional embolizations and long-term oral anlotinib, the operator judged that no further embolization was appropriate, and recommended that the patient continue to take oral anlotinib. In the abdominal CT review on March 19, 2024, target lesions 1 and 2 were well controlled, but target lesion 3 was poorly controlled, and thus we performed TACE again. The results of hepatic arteriography were similar to those of the prior TACE, and no further embolization was performed. We also evaluated the patient's liver function before eight TACE sessions, and no liver injury as assessed with glutamic transaminase and ALBI scores was observed (Figure 3). Two months later, the patient underwent a repeat abdominal CT scan, and it was determined that the patient had progressed based on the efficacy assessment. So pembrolizumab was added to the treatment regimen. Subsequent imaging at an outside institution showed pulmonary metastases and multiple intra-abdominal lymph node metastases. The patient died on 5 October 2024 with an overall survival time of 34 months.

## Discussion

For patients with unresectable liver metastases from leiomyosarcoma, although a few studies have reported the use of TACE, the overall effectiveness is generally limited. Liver-directed therapies are emerging new technologies to treat these patients. Hailey Krzyston et al<sup>8</sup> reported survival benefit of liver-directed therapy in the treatment of hepatic metastatic smooth muscle sarcoma. Percutaneous ablation was primary liver-directed therapy choice, since ablation can provide the best local tumor control eliminating the entire metastasis. In this study only 5 out of 24 patients received ablation since patients needed to have limited disease (1–3 lesions) and lesions <3 cm to qualify for ablation. The present case exhibits multiple intrahepatic metastases, thus rendering it unsuitable for ablation therapy. Isolated hepatic arterial chemotherapy has limited effects on metastatic leiomyosarcoma, whereas local embolization can improve survival to some extent.<sup>9</sup> The reason is that, although liver metastases from leiomyosarcoma typically have a rich blood supply, their sensitivity to chemotherapy drugs is low. Short-term arterial chemotherapy may only increase adverse reactions, and the efficacy of TACE primarily stems from the embolic effect rather than the action of the chemotherapy drugs. In a study involving 28 patients with sarcoma liver metastases who underwent embolization, 12 patients received bland embolization, 6 underwent radioembolization, 8 received transcatheter arterial chemoembolization (TACE), and 2 received a combination of liver - directed treatments. Pierce et al reported a median overall survival (OS) of 26.7 months and a median progression - free survival (PFS) of 14.2 months from the start of treatment. Among these 28 patients, 11 had leiomyosarcoma.<sup>10</sup> Meanwhile, in another larger study including 30 patients with sarcoma hepatic metastases treated with TACE, Chapiro et al<sup>11</sup> reported a median OS from first treatment of 21.2 months and a median PFS of 6.3 months. Out of the 30 patients, 25 had leiomyosarcoma. Overall, TACE has some therapeutic effect on liver metastases from leiomyosarcoma, but the efficacy remains suboptimal.<sup>9,12</sup>

In recent years, the use of drug-eluting beads (DEB) in the treatment of liver cancer has shown several advantages over conventional iodinated oil transarterial chemoembolization (cTACE).<sup>12</sup> DEBs are non-absorbable embolic microspheres capable of releasing cytotoxic drugs, allowing for sustained targeted delivery to tumors. For hypervascular tumors such as leiomyosarcoma, DEB exhibit superior suspension properties, biocompatibility, and deformability, enabling more effective embolization of the tumor's blood supply arteries compared to traditional iodinated oil embolization. This helps to block or reduce the primary blood supply to the tumor, promoting tumor necrosis, shrinkage,



**Figure 3** The changes in liver function before each intervention.

or even complete disappearance. The sustained drug release characteristic of DEBs allows for high local concentrations of chemotherapy drugs, maximizing their cytotoxic effects. Considering the properties of drug-eluting beads and the patient's clinical condition, we opted for the DEB-TACE surgical approach.

In this case, after the seventh DEB treatment, imaging studies showed no abnormal vascular staining, and the hepatic artery and its branches were significantly atrophied and narrowed (Figure 2c). Although no abnormal vascular staining was observed, the changes in the tumor's blood supply remained unclear, and whether this resulted from increased portal venous supply requires further investigation.

With the increasing number of TACE procedures, changes in the blood supply to the tumor area may occur. These changes could result from the occlusion of tumor vessels, leading to a reduced blood supply to the tumor, or may result from the tumor gradually invading the branches of the portal vein, creating a hepatic artery-portal vein fistula. When embolization causes a decrease in hepatic artery pressure, the portal vein may participate in supplying blood to the tumor. Anatomical studies by Michels have identified multiple potential collateral vessels in the liver. These collateral pathways

may open when the hepatic artery is occluded or when the tumor is large and highly vascularized. Although TACE has shown certain efficacy and safety in treating liver tumors, the hypoxic environment of tumor vasculature may promote angiogenesis, which can sometimes lead to disease progression and impact survival outcomes.<sup>13–15</sup>

Currently, anlotinib is the only drug approved in China for the treatment of sarcomas. Anlotinib, whether used as a monotherapy or in combination with other drugs, demonstrates better efficacy and safety for certain advanced sarcomas, with prolonged maintenance of effect and manageable side effects.<sup>16</sup> Notably, the combination of anlotinib with chemotherapy has shown significant therapeutic effects in synovial sarcoma, leiomyosarcoma, fibrosarcoma, and rhabdomyosarcoma.<sup>17</sup>

There are no studies indicating that DEB-TACE combined with anlotinib provides better treatment outcomes for liver metastases of leiomyosarcoma. Considering that anlotinib has a dual-targeting effect of inhibiting tumor angiogenesis and suppressing tumor growth, it was added after the first DEB-TACE procedure. Based on the RECIST 1.1 criteria, the assessment indicated a PR. The patient in this case experienced clinical benefits from the combination treatment of DEB-TACE and anlotinib.

## Conclusion

In summary, we report a case of a patient with multiple liver metastases from retroperitoneal leiomyosarcoma, confirmed by postoperative pathology, who failed systemic chemotherapy. After multiple interventions, this case provides a promising treatment approach for patients with multiple liver metastases from leiomyosarcoma, but more high-quality data are needed for validation.

## Ethics Statement

Details of the case reported in the article were approved by the central institution, The Affiliated Hospital of Yanbian University.

## Consent for Publication

This report and any attendant pictures were revealed with the patients' written consent.

## Acknowledgments

We give thanks to the patients and everyone involved in this study.

## Funding

This research was supported by the National Natural Science Foundation of China (Nos.82460527), Natural Science Foundation of Jilin Province(Nos.YDZJ202401136ZYTS).

## Disclosure

The authors report no conflicts of interest in this work.

## References

1. Gronchi A, Strauss DC, Miceli R. Variability in patterns of recurrence after resection of primary retroperitoneal sarcoma (RPS): a report on 1007 patients from the multi-institutional collaborative RPS working group. *Ann Surg.* 2016;263:1002–1009. doi:10.1097/SLA.0000000000001447
2. Tan MCB, Brennan MF, Kuk D. Histology-based classification predicts pattern of recurrence and improves risk stratification in primary retroperitoneal sarcoma. *Ann Surg.* 2016;263:593–600. doi:10.1097/SLA.0000000000001149
3. Bonvalot S, Roland C, Raut C. Histology-tailored multidisciplinary management of primary retroperitoneal sarcomas. *Eur J Surg Oncol.* 2023;49:1061–1067. doi:10.1016/j.ejso.2022.05.010
4. Dalal KM, Kattan MW, Antonescu CR, Brennan MF, Singer S. Subtype specific prognostic nomogram for patients with primary liposarcoma of the retroperitoneum, extremity, or trunk. *Ann Surg.* 2006;244:381–391. doi:10.1097/01.sla.0000234795.98607.00
5. Wang Z, Shi N, Naing A, et al. Survival of patients with metastatic leiomyosarcoma: the MD Anderson Clinical Center for targeted therapy experience. *Cancer Med.* 5;2016.
6. Hiraoka A, Kumada T, Kudo M, et al. Hepatic function during repeated TACE procedures and prognosis after introducing sorafenib in patients with unresectable hepatocellular carcinoma: multicenter analysis. *Dig Dis Basel Switz.* 35;2017.
7. Melchiorre F, Patella F, Pescatori L, et al. DEB-TACE: a standard review. *Future Oncol Lond Engl.* 14;2018:2969–2984.

8. Krzyston H, Morse B, Deperalta D, Department of Diagnostic Imaging and Interventional Radiology, Moffitt Cancer Center, et al. Liver-directed treatments of liver-dominant metastatic leiomyosarcoma. *Diagn Interv Radiol.* 26;2020:449–455. doi:10.5152/dir.2020.19405
9. Melichar B, Vobořil Z, Nožička J. Hepatic arterial infusion chemotherapy in sarcoma liver metastases: a report of 6 cases. *Tumori J.* 2005;91:19–23. doi:10.1177/030089160509100105
10. Pierce DB, Johnson GE, Monroe E, et al. Safety and efficacy outcomes of embolization in hepatic sarcomas. *Am J Roentgenol.* 2018;210:175–182. doi:10.2214/AJR.16.17573
11. Chapiro J, Duran R, Lin M, et al. Transarterial chemoembolization in soft-tissue sarcoma metastases to the liver – the use of imaging biomarkers as predictors of patient survival. *Eur J Radiol.* 2015;84:424–430. doi:10.1016/j.ejrad.2014.11.034
12. Maluccio MA, Covey AM, Schubert J, et al. Treatment of metastatic sarcoma to the liver with bland embolization. *Cancer.* 2006;107:1617–1623. doi:10.1002/cncr.22191
13. Namur J, Citron SJ, Sellers MT, et al. Embolization of hepatocellular carcinoma with drug-eluting beads: doxorubicin tissue concentration and distribution in patient liver explants. *J Hepatol.* 55;2011.
14. Xue T, Le F, Chen R, et al. Transarterial chemoembolization for huge hepatocellular carcinoma with diameter over ten centimeters: a large cohort study. *Med Oncol Northwood Lond Engl.* 32;2015.
15. Miyayama S, Kikuchi Y, Yoshida M, et al. Outcomes of conventional transarterial chemoembolization for hepatocellular carcinoma  $\geq 10$  cm. *Hepatol Res off J Jpn Soc Hepatol.* 49;2019.
16. Yao W, Du X, Wang J, et al. Long-Term Efficacy and Safety of Anlotinib as a Monotherapy and Combined Therapy for Advanced Sarcoma. *Oncol Targets Ther.* 2022;15:669–679. doi:10.2147/OTT.S365506
17. Petrillo M, Patella F, Pesapane F, et al. Hypoxia and tumor angiogenesis in the era of hepatocellular carcinoma transarterial loco-regional treatments. *Future Oncol.* 2018;14:2957–2967. doi:10.2217/fon-2017-0739

## Journal of Hepatocellular Carcinoma

### Publish your work in this journal

The Journal of Hepatocellular Carcinoma is an international, peer-reviewed, open access journal that offers a platform for the dissemination and study of clinical, translational and basic research findings in this rapidly developing field. Development in areas including, but not limited to, epidemiology, vaccination, hepatitis therapy, pathology and molecular tumor classification and prognostication are all considered for publication. The manuscript management system is completely online and includes a very quick and fair peer-review system, which is all easy to use. Visit <http://www.dovepress.com/testimonials.php> to read real quotes from published authors.

Submit your manuscript here: <https://www.dovepress.com/journal-of-hepatocellular-carcinoma-journal>

**Dovepress**  
Taylor & Francis Group