


CASE IMAGE

Median nerve instability in the wrist: Ultrasound diagnosis

Ferdinando Draghi^{1,2} | Guia Ferrozzi^{3,4} | Mara Bonardi⁵ | Matteo Precerutti¹ ¹Diagnostic Imaging Department, IRCCS Maugeri Montescano, Montescano (PV), Italy²Diagnostic Imaging Department, Centro Medico Clastmed, Codevilla, Italy³Diagnostic Imaging Department, Centro Medico Inacqua, Piacenza, Italy⁴Diagnostic Imaging Department, Centro Medico Riabilitativo Rocca, Piacenza, Italy⁵Radiodiagnostica IRCCS Policlinico san Matteo, Pavia, Italy

Correspondence

Matteo Precerutti, Diagnostic Imaging Department, IRCCS Maugeri Montescano, Montescano (PV), Italy.

Email: matteo.precerutti@icsmaugeri.it

KEYWORDS: carpal tunnel, median nerve, nerve instability

The median nerve, in the carpal tunnel, runs between the tendons for the second and third fingers of the flexor digitorum superficialis and the tendon for the second finger of the flexor digitorum profundus, and it is surrounded by a synovial sheath or bursa on the ulnar side.¹

It runs immediately beneath the flexor retinaculum or transverse carpal ligament, and it is covered by a layer of celluloadipose tissue that adheres to the adjacent ulnar bursa.²

The flexor retinaculum is located between the distal radius to the base of the third metacarpal; it is inserted medially on the pisiform

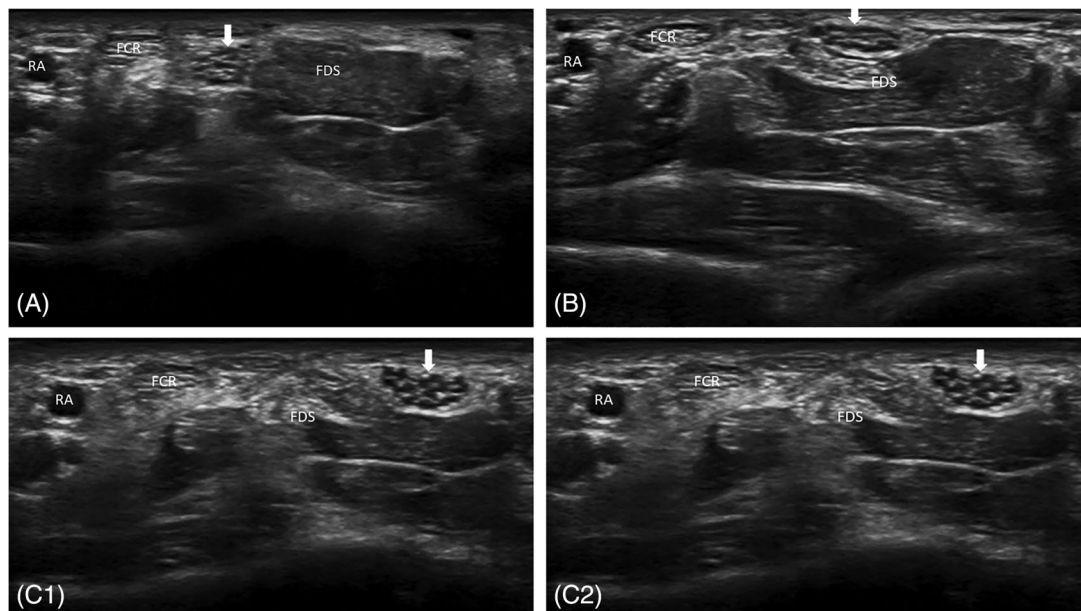


FIGURE 1 Axial sonograms show, during wrist flexion, the median nerve (arrow) dislocates, radial to ulnar, with respect to the flexor digitorum superficialis muscle and tendons (FDS) (A–C). FCR, flexor carpi radialis; RA, radial artery

This is an open access article under the terms of the [Creative Commons Attribution-NonCommercial-NoDerivs](https://creativecommons.org/licenses/by-nc-nd/4.0/) License, which permits use and distribution in any medium, provided the original work is properly cited, the use is non-commercial and no modifications or adaptations are made.

© 2022 The Authors. *Journal of Clinical Ultrasound* published by Wiley Periodicals LLC.

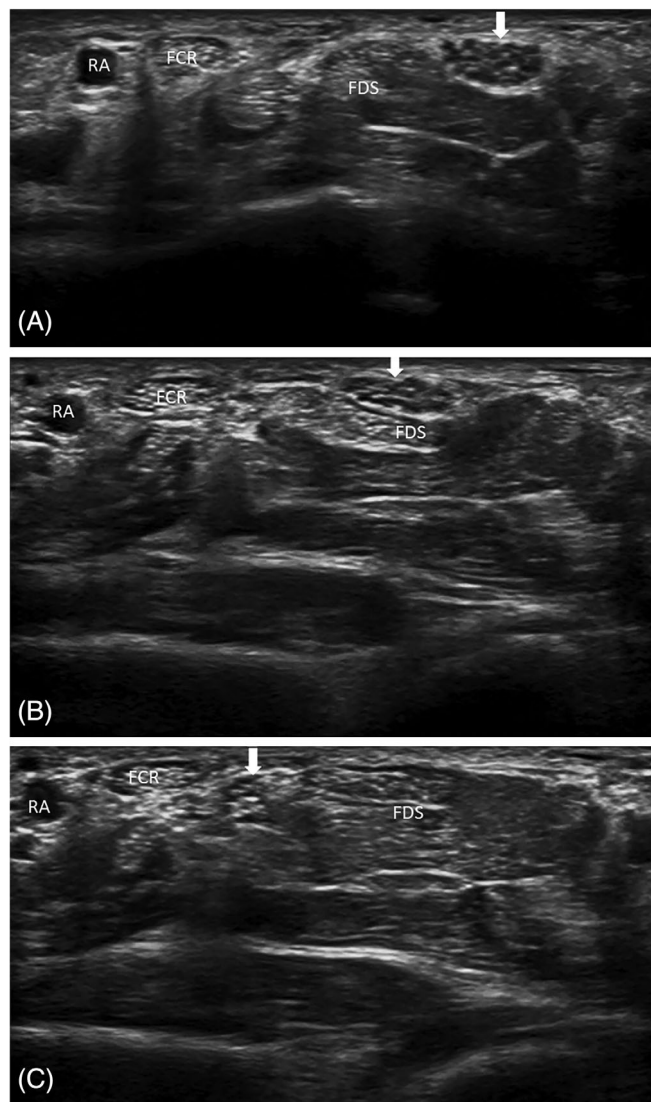


FIGURE 2 Axial sonograms show, during wrist extension, the median nerve (arrow) returns to its natural location (A–C). FCR, flexor carpi radialis; FDS, flexor digitorum superficialis; RA: radial artery

and the hamate and laterally on the tuberosity of the scaphoid and on the os trapezium.

The flexor retinaculum has three sections: the proximal (thin and continuous with the deep investing forearm fascia), the midportion or transverse carpal ligament proper (thickest) and the distal (composed of an aponeurosis between the thenar and hypothenar muscles, which is thin again).³

Despite its high intrinsic stiffness and strength, the flexor retinaculum is not a major factor in the maintenance of the stability of the carpal arch, which is contrary to the intercarpal ligaments that form the carpal tunnel floor and are essential for the stability of the carpal tunnel.

Instability of the nerves, which does not follow traumatic injury, is relatively rare and almost exclusively affects the ulnar nerve in the cubital tunnel; ulnar nerve instability is often asymptomatic.

In our case image, during wrist flexion, the median nerve (arrow) dislocates, radial to ulnar, with respect to the flexor digitorum

superficialis muscle and tendons, particularly in respect to those for the second and third fingers (Figure 1), to return to its natural location with the subsequent extension (Figure 2) (Supporting Information Video S1). The probe was placed at the proximal carpal tunnel parallel to the flexor retinaculum. The wrist was examined following a clinical diagnosis of carpal tunnel syndrome (pain in the first three fingers and ulnar side of the fourth, exacerbated by movement); however, the median nerve did not appear enlarged, there were no macroscopic alterations, and the normal fasciculated aspect was maintained, relatively common ultrasound appearance in carpal tunnel syndrome. To our knowledge, the instability of the median nerve in the wrist has never been described previously.

The etiology is unknown, but it is logical to think that it is due to an insufficiency of celluloadipose tissue that adheres the median nerve to the adjacent ulnar bursa, rather than an insufficiency of the transverse carpal ligament.

If the changes in median nerve mobility in carpal tunnel syndrome are well described in the medical literature, it is possible that median nerve hypermobility can cause carpal tunnel syndrome.

Therefore the instability of the median nerve in the wrist could be a cause of carpal tunnel syndrome, but surely the identification of instability of the median nerve in the wrist is definitely an indication for ultrasound examination before carpal tunnel release.⁴

CONFLICT OF INTEREST

No conflict of interest to be disclosed.

DATA AVAILABILITY STATEMENT

Research data are not shared.

ORCID

Matteo Precerutti  <https://orcid.org/0000-0001-7294-0884>

REFERENCES

1. Gitto S, Draghi AG, Draghi F. Sonography of non-neoplastic disorders of the hand and wrist tendons. *J Ultrasound Med*. 2018 Jan;37(1):51-68.
2. Rotman MB, Donovan JP. Practical anatomy of the carpal tunnel. *Hand Clin*. 2002 May;18(2):219-230.
3. Cobb TK, Dalley BK, Posteraro RH, Lewis RC. Anatomy of the flexor retinaculum. *J Hand Surg Am*. 1993 Jan;18(1):91-99.
4. Draghi F, Ferrozzi G, Bortolotto C, Ballerini D, Fiorina I, Preda L. Sonography before and after carpal tunnel release: video article. *J Ultrasound*. 2020 Sep;23(3):363-364.

SUPPORTING INFORMATION

Additional supporting information may be found in the online version of the article at the publisher's website.

How to cite this article: Draghi F, Ferrozzi G, Bonardi M, Precerutti M. Median nerve instability in the wrist: Ultrasound diagnosis. *J Clin Ultrasound*. 2022;50(5):719-720. doi:10.1002/jcu.23222