

Case Report

A Patient with Hemoptysis and Renal Failure

**Pranavkumar Dalal,¹ Gautam Phadke,¹ Amandeep Gill,¹ Kurtis Tarwater,¹
Madhukar Misra,¹ Nicole Pele,² and Brian Odum²**

¹ *Division of Nephrology, Department of Internal Medicine, University of Missouri, Columbia, MO 65201, USA*

² *Department of Pathology and Anatomical Sciences, University of Missouri, Columbia, MO 65201, USA*

Correspondence should be addressed to Gautam Phadke, drgmphadke@gmail.com

Received 4 March 2011; Accepted 24 March 2011

Academic Editor: Samy I. McFarlane

Copyright © 2011 Pranavkumar Dalal et al. This is an open access article distributed under the Creative Commons Attribution License, which permits unrestricted use, distribution, and reproduction in any medium, provided the original work is properly cited.

Pulmonary-renal syndrome is a medical emergency; etiology of which has broad differential diagnosis. Delay in both diagnosis and initiation of management may result in end-organ damage. Management decisions may have to be empiric till a rapid, definitive tissue diagnosis is established. We present such a case where prompt recognition and immediate treatment was initiated, although the patient sustained irreversible end-organ damage. The case also highlights the need to interpret the kidney biopsy data (namely, immunofluorescence findings) in the context of clinical presentation.

1. Case Presentation

A 26-year-old male presented to our hospital complaining of cough and hemoptysis for 7 days. A resident of Columbia, Mo, he had recently flown back home from vacation in California. He denied chest pain or fever. There was no significant past medical history, and the patient was not on any medications. He smoked 1-2 cigarettes per day, but denied alcohol intake or drug abuse. Family history was significant for hypertension in both parents.

On arrival to the hospital, the patient's pulse was 112/min and regular, and BP was 220/128 mm Hg, respiratory rate 38/min. He was hypoxic, saturating 88% on room air. The patient appeared ill and pale. Respiratory exam revealed bilateral coarse crackles. Neurological exam was normal. Bilateral optic disc margins were blurred, and retinal exudates and hemorrhages were noted. No skin rash was present. Patient was intubated for hypoxic respiratory failure and started on intravenous labetalol. Bronchoscopy revealed active lung hemorrhage (LH). Laboratory data showed anemia, thrombocytopenia, and renal failure (Table 1).

Presuming the diagnosis of a pulmonary renal syndrome, the patient was treated with 1-gram methylprednisolone and plasmapheresis pending results of serological investigations. Hemodialysis was initiated for anuric renal failure. A left

renal biopsy was performed. A total of 17 glomeruli were obtained. Changes secondary to malignant hypertension, (Figures 1(a) and 1(b)) and superimposed changes secondary to chronic hypertension (Figures 2(a) and 2(b)) were noted. Immunofluorescence showed peripheral C3 trapping and weak (1+) linear staining of glomerular basement membrane by IgG. After renal biopsy, patient had an episode of bleeding for which he underwent left renal arteriolar embolization.

A diagnosis of malignant hypertension (MHT) presenting with LH, with acute anuric renal failure from thrombotic microangiopathy and with underlying chronic kidney disease secondary to primary hypertension was made. Only few cases of malignant hypertension presenting as pulmonary renal syndrome have been reported [1-3].

2. Discussion

Patient's strong family history, negative past medical history, and relatively small kidneys with increased echogenicity on ultrasound suggest that our patient most likely had underlying CKD secondary to uncontrolled severe primary hypertension. The selective angiogram performed for post-biopsy complication did not reveal renal artery stenosis of the left (smaller) kidney. A hypothesis that extreme BP elevation

TABLE 1: Laboratory data.

| | | | | | | | |
|----------------|--|-----------------------|----------------------|------------------|--------------------|-----------------|----------|
| CBC | Hb | WBC | Platelets | PT | aPTT | | |
| | 8.5 g/dL | 5.1×10^3 mcL | 94×10^3 mcL | 17.7 sec | 35.3 sec | | |
| BMP | Na | K | Cl | HCO ₃ | BUN | Creatinine | |
| | 141 mmol/L | 4.1 mmol/L | 104 mmol/L | 14 mmol/L | 108 mg/dL | 13.34 mg/dL | |
| UA | Large blood | 6–10 rbc/hpf | >300 mg/dL | No casts | Myoglobin negative | | |
| Serology | p-ANCA | c-ANCA | Anti MPO | Anti PR3 | SSA/SSB/SCL-70 | ANA/anti-ds DNA | Anti-GBM |
| | Neg | Neg | Neg | Neg | Neg | Neg | Neg |
| Miscellaneous | Influenza | Blood culture | Sputum cultures | | | | |
| | A/B Neg | Neg | Neg | | | | |
| Chest Xray | Bilateral pulmonary infiltrates. No cavity lesions noted. | | | | | | |
| CT Chest | No pulmonary embolism. | | | | | | |
| Ultrasound | Increased bilateral echogenicity. Rt kidney 10 cm, Lt kidney 9.0 cm. | | | | | | |
| Echocardiogram | Left ventricular hypertrophy. | | | | | | |

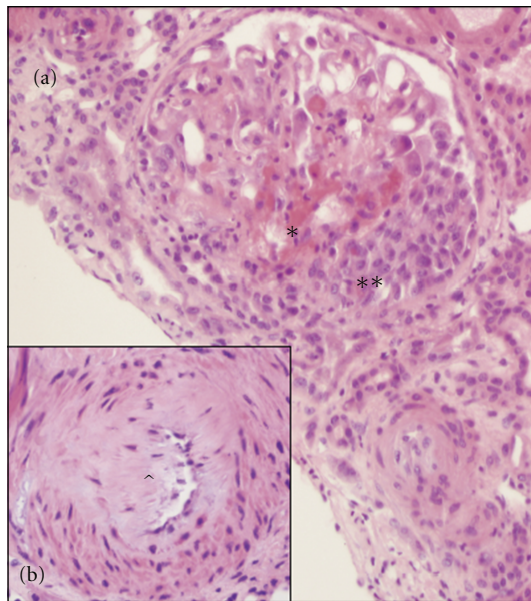


FIGURE 1: (a) Glomerular fibrinoid necrosis (*) and a crescent (**). (b) Arteriole with fibrinoid necrosis (∧) with luminal narrowing.

leads to vascular endothelial damage or hormonal changes (namely renin-angiotensin-aldosterone system activation) may explain why some people progress to MHT phase [4]. In MHT, narrowed arteriolar lumen (due to myointimal hyperplasia and fibrinoid necrosis) and endothelial damage leading to thrombotic lesions in the arterioles result in shear stress on passing blood stream. The mechanical destruction of red blood cells leads to microangiopathic hemolytic anemia. Clinical differentiation between TTP and malignant hypertension can be difficult, but normal mental status and normal ADAMTS-13 helped rule out TTP in our case.

The mechanism of pulmonary hemorrhage remains unclear in our case. Smoking, platelet dysfunction due to underlying uremia, and thrombocytopenia due to MAHA may have predisposed our patient to pulmonary hemorrhage. Pulmonary hemorrhage during air travel has been

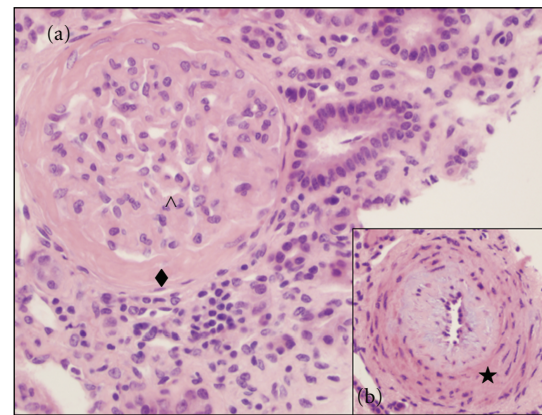


FIGURE 2: Changes due to chronic hypertension. (a) Periglomerular fibrosis (◆), thick capillary walls (∧). (b) Arteriole with myointimal hyperplasia (★).

reported, but those patients had underlying chronic lung conditions [5], which were not found in our patient.

In absence of serum antibodies to the GBM, we interpreted the low-intensity linear IgG staining of the GBM as false positive. Biopsies from patients with diabetic glomerulosclerosis, hypertensive vascular disease, renal transplant, myeloma, SLE, deceased donor kidneys after perfusion, and normal autopsy kidneys may have less intense linear IgG deposits.

Our patient remains dialysis dependant and is currently on the transplant list. Serum creatinine at presentation remains a significant prognostic factor for renal recovery in patients with malignant hypertension [6].

Physicians should be aware of MHT as a presentation of pulmonary-renal syndrome.

Conflict of Interests

The authors mentioned in the paper confirm that all the authors have contributed towards the preparation of the paper. They also confirm that they had no conflict of interests

during the preparation of this paper and they have no disclosures to make.

References

- [1] S. Aithal, N. Marley, and G. Venkat-Raman, "An unusual non-immunological cause of renal pulmonary syndrome," *Clinical Nephrology*, vol. 72, no. 4, pp. 322–325, 2009.
- [2] Y. Sato, S. Hara, K. Yamada, and S. Fujimoto, "A rare case of alveolar haemorrhage due to malignant hypertension," *Nephrology Dialysis Transplantation*, vol. 20, no. 10, pp. 2289–2290, 2005.
- [3] K. Hida, J. Wada, M. Odawara et al., "Malignant hypertension with a rare complication of pulmonary alveolar hemorrhage," *American Journal of Nephrology*, vol. 20, no. 1, pp. 64–67, 2000.
- [4] J. H. Laragh and B. M. Brenner, *Hypertension: Pathophysiology, Diagnosis, and Management*, Raven Press, New York, NY, USA, 1990.
- [5] C. W. Chen, W. C. Perng, M. H. Li, H. C. Yan, and C. P. Wu, "Hemorrhage from an enlarged emphysematous bulla during commercial air travel," *Aviation Space and Environmental Medicine*, vol. 77, no. 12, pp. 1275–1277, 2006.
- [6] R. Gonzalez, E. Morales, J. Segura, L. M. Ruilope, and M. Praga, "Long-term renal survival in malignant hypertension," *Nephrology Dialysis Transplantation*, vol. 25, no. 10, pp. 3266–3272, 2010.