



Ewing's sarcoma / Primitive Neuro-Ectodermic Tumor in the kidney. A case report

Brenda Rodríguez Bustos^{a,*}, Israel Uberetagoyna Tello de Meneses^b,
José Ricardo Herrera Hernández^a, Rodrigo Escárzaga Herrasti^a,
Fernando Daniel Argueta-Muñoz^c

^a Hospital Español de México, Urology Resident, Mexico

^b Hospital Español de México, Department of Urology, Mexico

^c Faculty of Medicine, Universidad Nacional Autónoma de México, Mexico

ARTICLE INFO

Keywords:

Ewing's sarcoma
Kidney
Primitive tumor
Robotic-assisted

ABSTRACT

Ewing's sarcoma/Primitive Neuro-Ectodermic Tumor of the kidney accounts for less than 1% of all kidney tumors. We present the case of a 37-year-old male with abdominal pain secondary to a right renal tumor of $7 \times 7 \times 5$ cm. A robotic right radical nephrectomy was performed. In the histopathological and immunohistochemistry was reported NKX2.2(+), CD99(+), synaptophysin(+), and FLI-1(+). Extraosseous Ewing's Sarcoma was diagnosed. The patient was treated with: Doxorubicin, Vincristine, Mesna, and Isophosphamide.

1. Introduction

Ewing's sarcoma/Primitive Neuro Ectodermic Tumor (ES/PNET) is a primary malignant tumor Seemayer first reported in 1975.¹ This malignant tumor affects soft tissues and bones of the axial skeleton. It has a higher incidence in adolescents and young adults with an average age of 28 years; it predominantly affects men with a ratio of 3:1.² Between 25 and 50% of patients present metastasis at the diagnosis³; lung, liver, and bone are the most commonly affected organs. The localization in the genitourinary system such as kidney, bladder, and prostate are extremely rare.⁴ There are less than 100 cases reported in the literature of ES/PNET with renal condition.⁵ We present a case of an ES/PNET with renal presentation and treatment after its diagnosis.

2. Clinical case

A 37-year-old Mexican male with cryptorchidism in 1982 with no surgical treatment and vasectomy in 2012 suffered two weeks before his assessment abdominal pain type colic in the right flank, intensity 8/10, accompanied by abdominal distention and nausea without vomiting. The medical practitioner prescribed antispasmodics and analgesics at that moment.

One week later, he went to the emergency room of our institution due to the persistence of the symptoms, and the urology service

evaluated him. We found abdominal pain in the right flank during the physical examination, with no signs of urinary infection. Imagenology service performed abdominal ultrasound reporting right kidney with anechoic ovoid image well delimited, with echoes inside, measuring $63 \times 69 \times 66$ mm and a 150 cc volume, diagnosed as a probable hemorrhagic cyst. Blood tests with no pathological findings. They also reported a urotomography with hypodense images measuring $1.4 \times 1.6 \times 2$ cm in segment IV of the liver. Right kidney with an increase of transverse diameter with the persistence of concentration and delay in the elimination of contrast medium; on the medial face, we found an image of 7 cm and nodules with an enhancement of 71 HU and slow washing 58 HU (mixed component), extravasation of perirenal contrast medium that generates compression of the ureter and renal pelvis. The report of the renal angioresonance (Fig. 1): Hepatic lesions with incomplete filling corresponding to atypical hemangiomas, dependent right kidney tumor with cystic appearance with a solid nodular portion near the renal pelvis.

We schedule a robotic-assisted surgery for right radical nephrectomy with a diagnosis of right renal tumor T2aN0M0 ECII, ECOG:0, Karnofsky: 100. We performed an uncomplicated surgical procedure with 180 min duration and bleeding of 200 cc. The histopathological report indicated a low pole right kidney tumor of $7 \times 7 \times 5$ cm, with a grayish-white appearance. Microscopy shows small cell clusters with a round nucleus and no cytoplasmic limits (Fig. 2). Ureteral marginal resection

* Corresponding author. Ejercito Nacional 613, Colonia Granada, CP, 11520, Mexico.

E-mail address: brendaz_777@hotmail.com (B. Rodríguez Bustos).

<https://doi.org/10.1016/j.eucr.2021.101898>

Received 21 September 2021; Received in revised form 11 October 2021; Accepted 13 October 2021

Available online 14 October 2021

2214-4420/© 2021 Published by Elsevier Inc. This is an open access article under the CC BY-NC-ND license (<http://creativecommons.org/licenses/by-nc-nd/4.0/>).

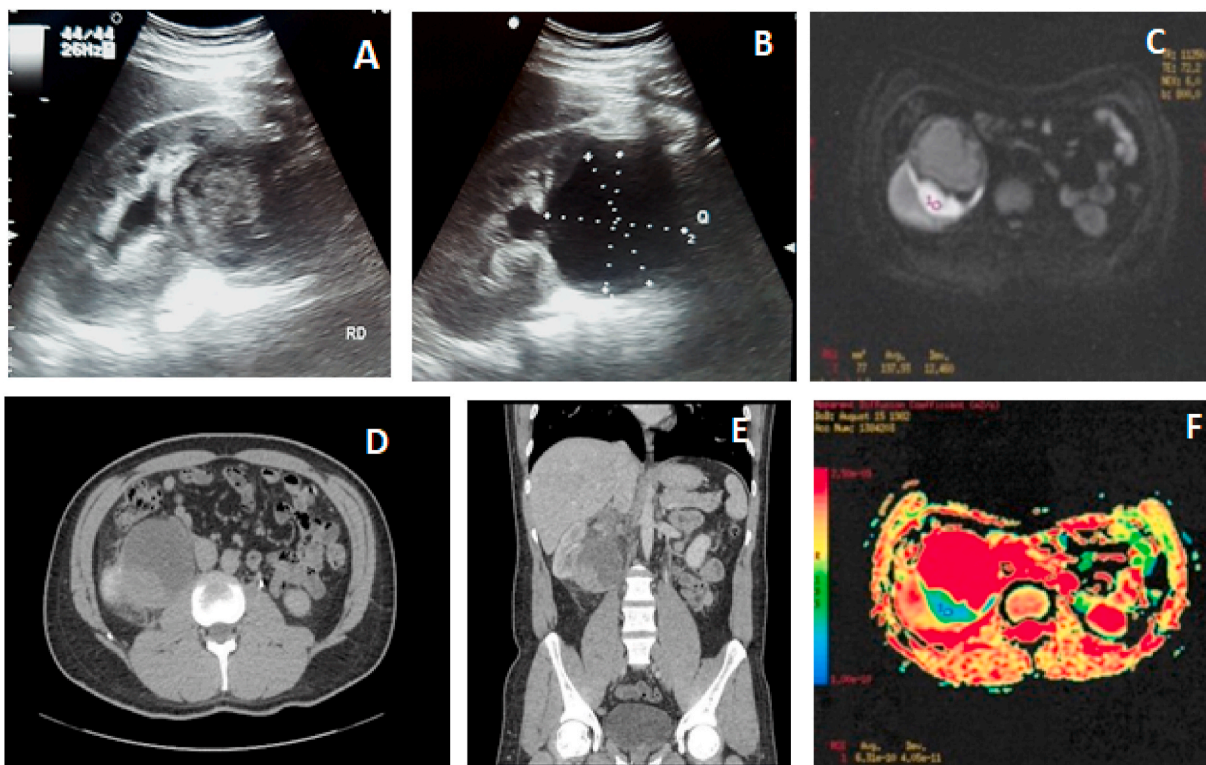


Fig. 1. Image studies.

A, B: USS showing right kidney with a 150 cc volume anechoic ovoid image with well delimited with echoes inside.
 C, D, E: Urotomography showing a 7 cm tumor in the right kidney image with nodules and an enhancement of 71 HU with slow washing 58 HU.
 F: Renal resonance with a cystic like right kidney tumor with a solid nodular portion near the renal pelvis.

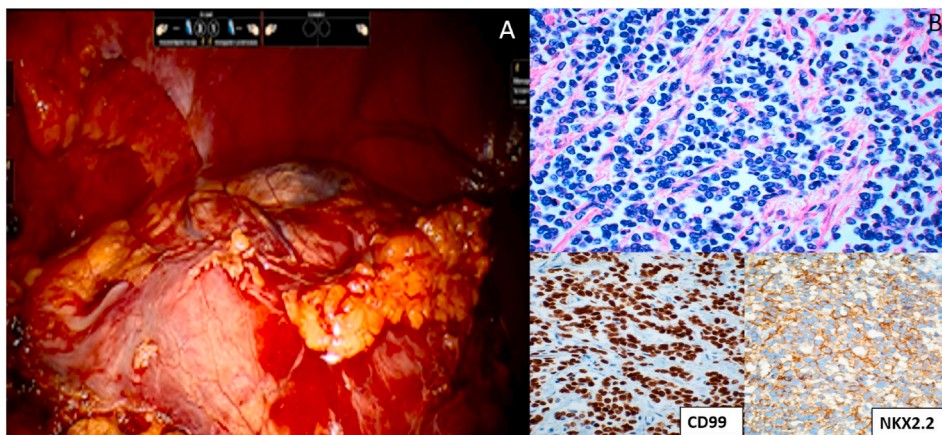


Fig. 2. Surgical view and histological slides.

A: Right renal tumor shown by robotic-assisted surgery.
 B: Histological sections of the tumor. Hematoxylin-Eosin 40X. A blue small cell neoplasm. The nuclei are hyperchromatic and monotonous. The cytoplasm is scanty and clear. Immunostains for CD99 and NKX2.2. CD99, 40x. Cytoplasmic membrane expression. NKX2.2, 40x. Strong nuclear expression. (For interpretation of the references to colour in this figure legend, the reader is referred to the Web version of this article.)

Table 1
 Immunohistochemistry test results.

Marker	Result	Marker	Result
NKX2.2	+	FLI-1	+ weak
CD56	+	CD99	+
Synaptophysin	+	Ki67	40%
Chromogranin	-	WT-1	-
CKAE1/be3	-		

and perirenal fat with no neoplasia. Renal vein with tumor thrombosis and neoplastic infiltration into perivascular adipose tissue. The adrenal gland was free of neoplasms. Positive permeation in lymphatic and venous vascular. Proliferation rate: 40%, necrosis extension was 80% of

the tumor. An immunohistochemistry test reported Extrasosseous Ewing Sarcoma, T3aN0M0 (Table 1).

One month later, an ultrasound-guided percutaneous biopsy was performed of hepatic lesions in segment IV with negative results to neoplasia. PET-CT scan with 18FDG reported hypermetabolism in the surgical bed with a maximum SUV 4.2. Bone marrow biopsy reported: normocellular in 70%. Mild erythroid hyperplasia, granulopoiesis, and megakaryopoiesis. Without infiltrative or metastatic neoplastic processes. We initiated treatment of six cycles of doxorubicin, vincristine, mesna, isophosphamide, and etoposide.

3. Discussion

It is relevant to an intentional search for ES/PNET when evaluating a

malignant kidney tumor due to its high mortality. Karpate and collaborators identified a series of 34 pathology cases with ES/PNET confirming the aggressive tumor.³ Usually, the diagnosis of ES/PNET is done with abnormal abdominal TACS.^{1,2,4,5} 25–50% of pathological reports have metastasis when diagnosed.³ Overall recommendations are immunohistochemistry and histopathological diagnosis.^{1–5}

The clinical presentation and imaging characteristics of ES/PNET are unspecific and make the diagnosis approach complex.² This tumor might be confused with other round cell tumors that mainly affect the kidney like Wilms' Tumor, synovial sarcoma (SS), among others.³ In this case, the incidental finding of the tumor in the renal area and the patient's unspecific symptoms make it challenging to make a definitive diagnosis. Technetium-99 is useful for detecting bone metastases.² PET/CT with 18 FDG allows the evaluation of metastases and the response to treatment.⁴ Complementary imaging studies are necessary for the complete diagnosis of this entity, especially in an extraosseous presentation.

We identified MIC2 and FLI-1 immunohistochemical markers, which are the most representative for the ES/PNET. MIC2 (CD99: surface glycoprotein designated by p30/32MIC2 highly sensitive marker for the ES/PNET tumor family) and FLI-1 (distinguish ES/PNET from other tumors that are also MIC2 positive, such as SS). The FLI-1 is associated with translocation (11; 22), (q24;q12) with a sensitivity of 71% and specificity of 92% for ES/PNET.³ The treatment of renal PNET is multimodal, including surgery, adjuvant chemotherapy, and radiotherapy. Chemotherapy includes vincristine, doxorubicin, and cyclophosphamide, and another option is isophosphamide or etoposide. The sick-free period to 5 years is 45–55%.⁵ The patient follow-up is essential in the long term to prevent and detect the recidivism of this malignant tumor. More data is required in the study, following, and management of these patients.

4. Conclusions

Ewing's sarcoma/Primitive Neuro-Ectodermic Tumor is an infrequent entity with unspecific clinical presentation. Image studies support the diagnosis and surgical intervention but are unspecific. Immunohistochemistry and cytogenetic analyses are helpful to differentiate it from other tumors.

Confidentiality of data

The authors state that they have followed their workplace's protocols on the publication of patient data.

Declaration of competing interest

The authors report having no conflict of interest.

References

1. Maeda M, Tsuda A, Yamanishi S, et al. *Ewing Sarcoma, primitive Neuroectodermal Tumor of the Kidney in a Child* [Internet]. *Pediatr Blood Cancer*; 2006. <https://doi.org/10.1002/pbc.20831>. Disponible en.
2. Chakrabarti N, Dewasi N, Das S, Bandyopadhyay A. Primary Ewing's sarcoma/primitive neuroectodermal tumor of kidney - a diagnostic dilemma. *Iran J Cancer Prev*. 2015;8(2):5.
3. Karpate A, Menon S, Basak R, Yuvaraja TB, Tongaonkar HB, Desai SB. Ewing sarcoma/primitive neuroectodermal tumor of the kidney: clinicopathologic analysis of 34 cases. *Ann Diagn Pathol*. agosto de. 2012;16(4):267–274.
4. Doroudinia A, Ahmadi S, Mehrian P, Pourabdollah M. Primary Ewing sarcoma of the kidney. *BMJ Case Rep*. enero de. 2019;12(1). bcr-2018-227198.
5. Yang C, Xu H, Zhou J, et al. Renal primitive neuroectodermal tumor: a case report. *Medicine (Baltimore)*. diciembre de. 2015;94(49), e2304.