



Insufficiency Fracture of Ipsilateral Femur Neck in Patient Treated with Long Term Bisphosphonate Treatment - A Case Report -

Do-Hoon Kim, Eui-Chul Lee*, Seok-Kwon Kang

Department of Orthopaedic Surgery, Samsung Changwon Hospital, Sungkyunkwan University School of Medicine, Changwon, Korea

= Abstract =

Bisphosphonate is notable for the treatment of osteoporosis in the world. But recently if Bisphosphonate is taken for a long time, it causes an insufficiency fracture by suppression of bone turn-over and it is reported rarely on femur neck. Here we report a case of insufficiency fracture on ipsilateral femur neck in woman treated with long term Bisphosphonate therapy. [Journal of Bone Metabolism, 19(2): 159-162, 2012]

Key Words: Bisphosphonate, Femur neck, Insufficiency fracture, Osteoporosis

INTRODUCTION

Osteoporosis could occur to postmenopausal women or due to the use of medication such as steroids by increasing the risk of stress fracture by resulting reduced bone strength.[1] Bisphosphonate is a commonly used bone resorption inhibitor to reduce the risk of stress fracture.[1,2] However, recent studies have reported that the long-term use of bisphosphonate weakens the mechanical strength of bone by reducing bone turnover. The authors report a case of insufficiency fracture on ipsilateral femur neck in female patient with the long-term use of bisphosphonates.

CASE REPORT

A 78-year old female patient had a history of lumbar

compression fracture 6 years ago and was taking 91.37 mg of bisphosphonate-type sodium alendronate (alendronic acid 70 mg) every week without taking other medication. She had not been exposed to excessive bearing except the regular walking as a housewife. However, she visited our hospital due to gradually intensifying pain in the right inguinal area from three days before the admission. Before the manifestation of pain, she was not restricted in her daily activity and the pain only appeared during body weight loading. According to the physical findings, no specific findings were observed other than pain in the right inguinal area. The finding of stiffening was detected around partial fracture and the fractured area of the upper end of the femur in her radiograph (Fig. 1). T-score was -2.1 in the femoral region according to dual-energy X-ray absorptiometry (DXA). In addition, she exhibited the normal findings of a

Received: September 10, 2012, Revised: September 18, 2012, Accepted: October 17, 2012

*Address for Correspondence. Eui-Chul Lee, Department of Orthopedic Surgery, Samsung Changwon Hospital, Sungkyunkwan University School of Medicine, Changwon, Korea 50, Hapsung 2-Dong, Changwon-si, Gyeongsangnam-do., 630-723, Korea.

Tel: +82-10-4523-3803, Fax: +82-55-290-6888, e-mail: drlee337@naver.com

© This is an Open Access article distributed under the terms of the Creative Commons Attribution Non-Commercial License (<http://creativecommons.org/licenses/by-nc/3.0/>).

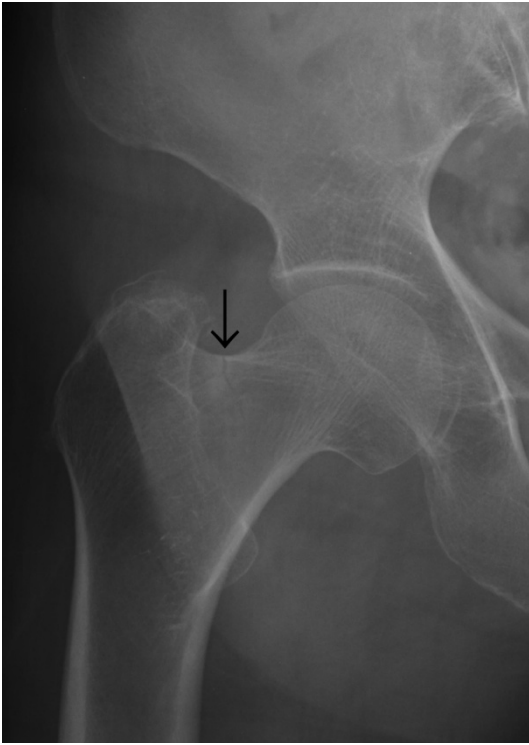

Fig. 1. Initial radiograph shows a right femoral neck fracture with sclerotic superior cortex and an undisplaced linear pattern.

9.0 (reference range: 8.4-10.5) mg/dL of serum calcium, a 4.0 (reference range: 2.5-4.5) mg/dL of phosphate, a 39 (reference range: 10-57) pg/mL of parathyroid hormone, and 72 (reference range: 30-120) IU/L of alkaline phosphatase along with a decrease at a 7.01 (reference range: 11-40) ng/mL of osteocalcin. In addition, C-telopeptide bone resorption marker was measured at 0.33 (reference range: 0.01-1.00) ng/mL of a normal finding. Based on the past medical history and other clinical findings, the patient was diagnosed as insufficiency fracture in the femoral neck which was thought to be resulted from the long-term use of bisphosphonate. Thus, multiple pin fixation was implemented (Fig. 2). The patient was postoperatively prohibited to take bisphosphonate and prescribed from taking calcium-vitamin D (calcium 600 mg + Vitamin D 400 IU) complex every day. She was allowed for partial weight bearing using a walking frame until the second postoperative month and for the entire weight bearing after the second postoperative month. In the 4th postoperative month of follow-up period,

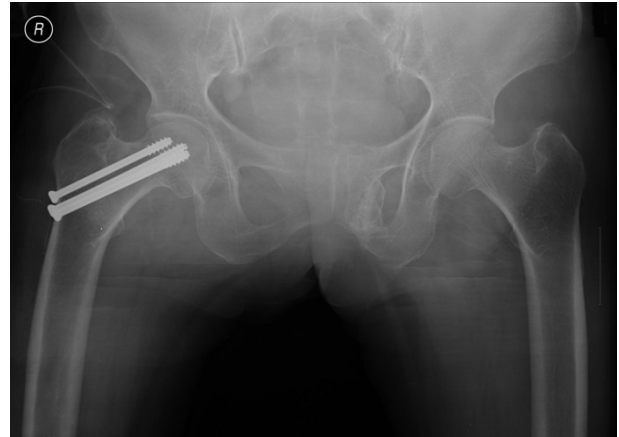

Fig. 2. Postoperative radiograph shows a well fixed 3 cannulated cancellous screws inside the femoral neck.

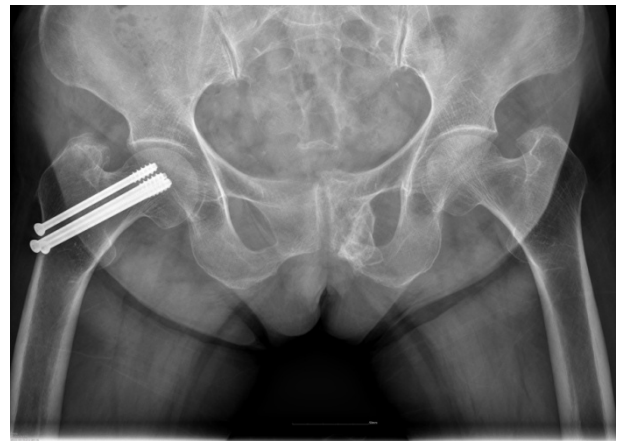


Fig. 3. Radiograph at 4 months after the operation shows union state without any complications.

the findings of bone reduction and pain loss were confirmed. Up to this time, physical examinations were regularly performed, including radiography and the presence of pain (Fig. 3).

DISCUSSION

Stress fractures can be classified into fatigue and insufficiency fractures. A fatigue fracture occurs when abnormal mechanical stress is continuously applied to a normal bone during everyday life. An insufficiency fracture, on the other hand, occurs when stress of normal activity is applied to a

bone that has decreased elastic resistance.[3-5] The fractures are commonly observed in the elderly according to the radiological findings. The patterns of fracture are mainly distinguished by transverse fractures occasionally associating transposition and appearing as a small radiolucent zone in the upper femur, and compression fractures mainly manifested in young people as grey-colored callus formation in the femoral neck.[5,6] Among these, the causes of insufficiency fractures are radioactivity, steroid treatment, rheumatoid arthritis, osteoporosis, hyperparathyroidism, and etc. Recently, the long-term use of bisphosphonate has been reported as one of the causes[3,4,7] and insufficiency fracture of ipsilateral femur neck most commonly occurs in the cervical region.[4]

Although definite mechanisms are unclear, insufficiency fractures mainly occur in the lower femur neck when the lower femur neck becomes the center of the loads in biomechanical loading of normal weight and the upper femur neck becomes the center as the external force is given.[5] Bisphosphonate is the most widely used medication for treating osteoporosis as one of the strong bone resorption inhibitors and reduces the risks of major fractures in females with osteoporosis.[2,6] However, many recent studies reported that the long-term use of bisphosphonate-type drugs induces femoral subtrochanteric and femoral shaft insufficiency fractures. Many recent studies verified that bisphosphonate causes femoral subtrochanteric and femoral shaft insufficiency fractures by continuously suppressing bone turn-over on femur neck when bisphosphonate is taken for a long time.[1,8] Moreover, Odvina et al.[7] reported that fracture fusion was incomplete even though patients stopped taking bisphosphonate after insufficiency fracture occurred, and acquired bone fusion by postoperatively suspending the prescription of bisphosphonate and recommending the patients to take parathyroid hormone or calcium-vitamin D complex.[6] Thorough history taking and physical examinations are crucial in order to diagnose the insufficiency fracture. Patients generally complain pain around the fractured area as a premonitory symptom. Since insufficiency fracture is often detected in a simple X-ray scan after 6-8 weeks later, the fracture needs to be suspected

in patients with long term bisphosphonate treatment. A simple X-ray scan of femoral subtrochanteric insufficiency fracture is characterized by thickened outer cortical bone, the findings of stiffening, transverse fractures, and inner cortical bone of the spike, and insufficiency fracture may not be detected in simple X-ray or computed tomography (CT) scans in the early stage.[3,8,9] Therefore, non-specific or precise bone scan and sensitivity or specificity need to be taken into consideration for insufficiency fracture to acquire desirable magnetic resonance imaging (MRI) scan imaging enabling swift diagnosis.[10] This case report is about insufficiency fracture on ipsilateral femur neck induced by the long-term use of bisphosphonate. It is a relatively unknown fracture compared to femoral subtrochanteric insufficiency fracture. Although premonitory symptoms were similar in both fractures, those fractures exhibited different radiological findings except for the hardening symptoms unlike typical insufficiency fracture. Some reports suggested that insufficiency fracture on ipsilateral femur neck mainly appeared in the form of compression fracture.[5] Although there are differences in the pattern of incomplete fracture in the upper femur, fatigue fractures commonly occur to athletes or soldiers who are generally exposed to the greater loads than ordinary individuals.[4,5] The patient in this case report were only given typical weights in daily activity and showed the findings of low bone formation markers and normal bone resorption markers according to osteopenia of femur neck and biochemical examination. For these reasons, she underwent a surgery due to the diagnosis of insufficiency fracture and in addition, she was postoperatively prohibited from taking bisphosphonate and prescribed to take calciumvitamin complex.

Insufficiency fractures need to be suspected and thoroughly examined when a patient with the long-term use of bisphosphonate complains the pain in the hip joint. Insufficiency fracture on ipsilateral femur neck as in this case report requires caution to the fact that the pattern of the fracture may differ from femoral subtrochanteric insufficiency fractures. Additional examinations such as bone scan and MRI are anticipated to be essential by taking into consideration the facts that the confirmation of fracture may

be difficult with a simple X-ray scan and fractures may occur bilaterally, although this case report did not carry out such procedures due to unclear finding of fracture. Moreover, it is thought to be crucial to conduct radiological and physical examinations on the regular basis for the postoperative assessment of surgery after effects including the degree of recovery in fractured area, delayed-union, non-union, avascular necrosis, and etc.

REFERENCES

1. Ing-Lorenzini K, Desmeules J, Plachta O, et al. Low-energy femoral fractures associated with the long-term use of bisphosphonates: a case series from a Swiss university hospital. *Drug Saf* 2009;32:775-85.
2. Lim YW, Kim YS. The medical treatment of osteoporosis. *J Korean Hip Soc* 2009;21:211-8.
3. Pearce DH, White LM, Bell RS. Musculoskeletal images. Bilateral insufficiency fracture of the femoral neck. *Can J Surg* 2001;44:11-2.
4. Gurdezi S, Trehan RK, Rickman M. Bilateral undisplaced insufficiency neck of femur fractures associated with short-term steroid use: a case report. *J Med Case Rep* 2008;2:79.
5. Iwamoto J, Takeda T. Insufficiency fracture of the femoral neck during osteoporosis treatment: a case report. *J Orthop Sci* 2002;7:707-12.
6. Kwek EB, Goh SK, Koh JS, et al. An emerging pattern of subtrochanteric stress fractures: a long-term complication of alendronate therapy? *Injury* 2008;39:224-31.
7. Odvina CV, Zerwekh JE, Rao DS, et al. Severely suppressed bone turnover: a potential complication of alendronate therapy. *J Clin Endocrinol Metab* 2005;90:1294-301.
8. Capeci CM, Tejwani NC. Bilateral low-energy simultaneous or sequential femoral fractures in patients on long-term alendronate therapy. *J Bone Joint Surg Am* 2009;91:2556-61.
9. Goh SK, Yang KY, Koh JS, et al. Subtrochanteric insufficiency fractures in patients on alendronate therapy: a caution. *J Bone Joint Surg Br* 2007;89:349-53.
10. El-Khoury GY, Wehbe MA, Bonfiglio M, et al. Stress fractures of the femoral neck: a scintigraphic sign for early diagnosis. *Skeletal Radiol* 1981;6:271-3.