

HOSTED BY



ELSEVIER

Contents lists available at ScienceDirect

Chinese Journal of Traumatology

journal homepage: <http://www.elsevier.com/locate/CJTEE>

Original article

Treatment of pediatric femoral shaft fractures by stainless steel and titanium elastic nail system: A randomized comparative trial

Tank Gyaneshwar, Rustagi Nitesh, Tomar Sagar, Kothiyal Pranav, Nitesh Rustagi*

Department of Orthopaedics, LLRM Medical College, Meerut, UP, India

ARTICLE INFO

Article history:

Received 11 August 2015

Received in revised form

11 December 2015

Accepted 1 February 2016

Available online 16 March 2016

Keywords:

Pediatrics

Femoral shaft fractures

Titanium

Stainless steel

ABSTRACT

Purpose: Literature suggests that the lower modulus of elasticity of titanium makes it ideal for use in children compared with stainless steel. Better fracture stability was observed in association with titanium nails on torsional and axial compression testing. However, stainless steel nails are stiffer than titanium counterparts, which may provide a rigid construct when fixing paediatric femoral shaft fractures. Complications have been observed more frequently by various researchers when titanium nails are used for fracture fixation in patients with increasing age or weight. The concept of this study was to compare the functional outcome after internal fixation with titanium elastic nail system and stainless steel elastic nail system in paediatric femoral shaft fractures.

Methods: The study was conducted on 34 patients admitted in the department of orthopaedics, LLRM Medical College & SVBP Hospital, Meerut, India from January 2013 to August 2014. We included patients aged 5–12 years with fracture of the femoral shaft, excluding compound fractures, pathological fractures and other lower limb fractures. Patients were treated by titanium ($n = 17$) or stainless steel ($n = 17$) elastic nail system and followed up for one year. The clinical parameters like range of motion at hip and knee joints, time to full weight bearing on the operated limb and radiological parameters like time to union were compared between two groups. A special note was made of intra- and post-operative complications. Functional outcomes were analysed according to Flynn criteria.

Results: Based on the Flynn criteria, 59% of patients had excellent results, 41% had satisfactory results, and no one showed poor results. There was no clinically significant difference between the two groups with respect to time to union and full weight bearing. But the incidence of puncture of the opposite cortex while inserting the nail and trying to advance it through the diaphysis during operation is greatly different. Only one such case was observed in titanium group but five in stainless steel group.

Conclusion: Majority of paediatric femoral shaft fractures are now treated operatively by elastic stable intramedullary nails. Operative intervention results in a shorter hospital stay and has economic and social benefits over conservative treatment. The cost of stainless steel nail is one third the cost of titanium nail. However, the clinico-radiological results are not significantly different between titanium and stainless steel nails at one year follow-up as observed by our study.

© 2016 Daping Hospital and the Research Institute of Surgery of the Third Military Medical University.

Production and hosting by Elsevier B.V. This is an open access article under the CC BY-NC-ND license (<http://creativecommons.org/licenses/by-nc-nd/4.0/>).

Introduction

Studies have shown equal or superior stability of titanium nails over stainless steel nails.^{1,2} Titanium V alloy has lower modulus of elasticity, higher yield strength, almost equal tensile strength, and

better biocompatibility and MRI compatibility as compared to 316L stainless steel. Literature suggests that the lower modulus of elasticity of titanium compared with stainless steel makes it more ideal for use in children.^{3,4} Better fracture stability was observed in association with titanium nails on torsional and axial compression testing by Mahar et al.¹ Titanium intramedullary nails are associated with a lower rate of infection as shown by various animal studies.

Stainless steel nails are stiffer than their titanium counterparts which may provide a rigid construct when fixing paediatric femoral

* Corresponding author. Tel.: +91 7895824814.

E-mail address: nitesh.rustagi@gmail.com (N. Rustagi).

Peer review under responsibility of Daping Hospital and the Research Institute of Surgery of the Third Military Medical University.

shaft fractures.⁵ The use of stainless steel nails for adolescent and obese children was suggested. Titanium nails have more chances of deformity due to their increased flexibility.⁵ More frequent complications have been observed by various researchers when titanium nails are used for fracture fixation in patients with increasing age or weight.⁶

This study aims to compare the functional outcome after internal fixation with titanium elastic nail system and stainless steel elastic nail system of paediatric femoral shaft fractures.

Materials and methods

A total of 40 patients between the age of 5–12 years and with closed fractures of the femoral shaft presenting to emergency and orthopaedics were included in this study. Out of them 34 patients successfully completed one-year follow-up and were included in the analysis. Seventeen patients were managed with titanium nails (Group 1) and the same number of patients was managed with stainless steel nails (Group 2) according to randomisation table. Patients with compound fractures, pathological fractures, other lower limb fractures, or presence of any comorbid illness were excluded.

Preoperatively patients were placed in Thomas Knee splint with below knee skin traction. They were randomly assigned into Group 1 or 2 based on a randomization table. Elastic nails of standard length i.e. 440 mm and 2.0–4.0 mm in diameters were used. The diameter of the individual nail was selected based on Flynn et al's formula⁷ (Diameter of nail = Width of the narrowest point of the medullary canal on AP and lateral views \times 0.4 mm). The length of the nail was determined intraoperatively by fluoroscopy. Two nails of the same diameter were used.

The patients were placed on an orthopaedic fracture table and a reduction of the fracture by traction guided by fluoroscopy was done. Pre-angled nails which were angled at 45° about 2 cm from one end were used. An entry point was made with the help of bone awl approximately 2 cm above the physis on lateral side. A nail loaded onto a T handle was then inserted through the entry point into the medullary canal by rotator movements of the wrist and advanced upto fracture site. Another nail was introduced using the same technique from the medial side and advanced upto fracture site. The nails were then crossed across the already reduced fracture site one by one. It was ensured that both nails were in the canal across the fracture site by fluoroscopy. Traction was released when the nails crossed the fracture site and then they were advanced further. Medial nail was advanced till it was within 2 cm of

proximal femoral capital physis whereas lateral nail was inserted till it was about 1 cm from greater trochanteric physis. Nails were left protruding about 0.5–1.0 cm at the distal end for easy removal later on.⁸

In the postoperative period limbs were simply rested on the pillow or placed in a T-K splint based on postoperative reduction and preoperative fracture pattern. Sutures were removed on the 12th postoperative day. Patients were taught isometric straight leg raises, quadriceps and hamstrings strengthening exercises with active, active-assisted and passive knee range of motion. Non-weight bearing with axillary crutches was started immediately after operation when tolerated. Weight bearing status depends on fracture configuration after reduction but in general partial weight bearing was started at around 4 weeks and progressed to full weight bearing when bridging callus appeared and fracture line was not visible on X-rays. Patients were followed up at regular intervals of one month, three months and six months post-operatively. At each follow-up patients were assessed clinically, radiologically and the complications were noted. The nails were removed when complete healing of the fracture occurred (usually between 10 and 12 months). The final results were evaluated using the criteria of Flynn et al. A typical case is presented in Fig. 1.

Results

The average age of patients in this study was 8.6 years in Group 1 and 8.2 years in Group 2, including more males. The left side was involved in 70.59% and 82.35% of cases respectively (Table 1). As for the fracture location, the middle third femoral shaft was mostly involved, accounting for 58.82% in both groups. Transverse fracture was the most common fracture type in Group 1 (52.94%) while spiral pattern the most common in Group 2 (52.94%). Most fractures were Winquist type 1 comminution (Table 2). The mean time interval between trauma and surgery in Group 1 was 4.24 days and Group 2 was 5.35 days. Majority of the patients were immobilized in the postoperative period for about 4 weeks (64.71% and 70.59%).

Table 1
Demographic data of patients (n, %). In each group, the total number of patients is 17.

Group	Age (yr)	Gender		Involved side	
		Male	Female	Right	Left
Titanium	8.6	10 (58.82)	7 (41.18)	5 (29.41)	12 (70.59)
Stainless steel	8.2	11 (64.70)	6 (35.30)	3 (17.65)	14 (82.35)

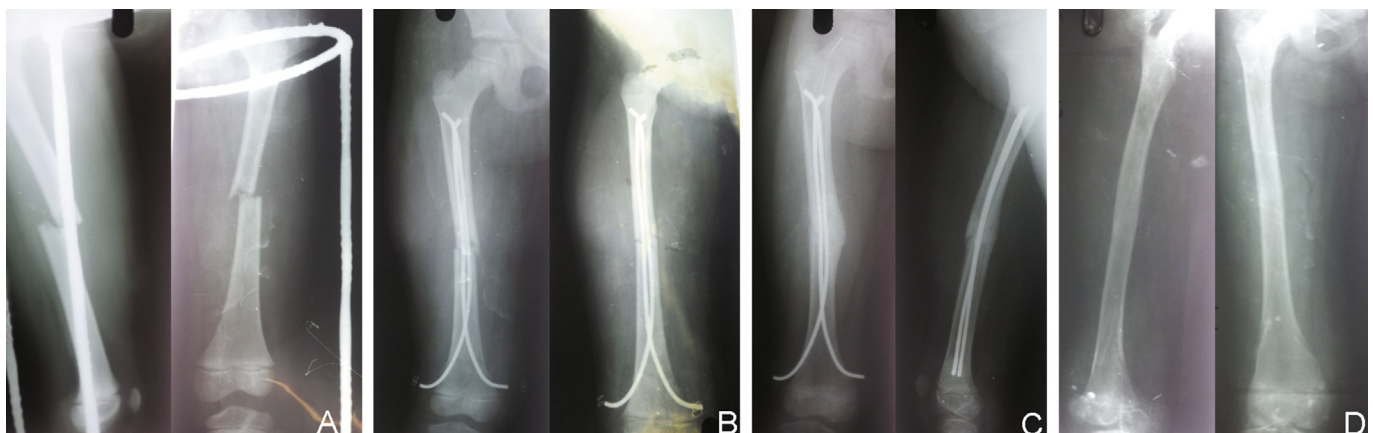


Fig. 1. A 7-year-old female child with transverse fracture of the middle third femoral shaft, Winquist type 1. A: Preoperative; B: Immediate postoperative; C: Three months after operation; D: After the removal of hardware.

Table 2

Fracture characteristics (n, %). In each group, the total number of patients is 17.

Group	Fracture location			Fracture type			Winquist comminution		
	Upper third	Mid third	Distal third	Transverse	Short oblique	Spiral	Type 1	Type 2	Type 3
Titanium	5 (29.41)	10 (58.82)	2 (11.77)	9 (52.94)	3 (17.65)	5 (29.41)	9 (52.94)	7 (41.17)	1 (5.89)
Stainless steel	7 (41.18)	10 (58.82)	0 (0)	4 (23.53)	4 (23.53)	9 (52.94)	15 (88.24)	2 (11.76)	0 (0)

There was no clinico-radiological difference in terms of time to full weight bearing and fracture site union between two groups (Table 3). Minor complications were observed in 47.06% of patients in Group 1 and 35.29% of patients in Group 2 with no major complications (Table 4). Seven patients in Group 1 and five patients in Group 2 reported pains at the site of nail insertion and both groups have three patients reported inflammatory bursa at the site of nail insertion. These problems resulted from surgical technique errors due to prominent hardware at the nail insertion site and did not produce long-term sequelae. Both pain and inflammatory bursa resolved within few weeks by giving oral antibiotics and analgesics. Range of motion at hip and knee was normal in all the patients except for one patient in Group 1, which also improved after the removal of hardware. There was no significant difference in malunion rate in both groups in sagittal as well as in coronal plane ($p = 1.00$). There was one patient with minor coronal plane angulation in Group 1 which was varus with no sagittal plane deformities.

The most significant complication between two groups was puncture of the opposite cortex intraoperatively, which occurred while inserting the nail and trying to advance it through the diaphysis. It was observed in only one patient in Group 1 (5.89%) and in five patients in Group 2 (29.41%).

Discussion

Femoral shaft fractures in children have been treated conservatively in the past based on the presumption that complication if any arises will be compensated by excellent remodelling potential of the children bone. However over the recent years surgeons are becoming more and more familiar with the operative techniques and excellent results have been obtained. Therefore majority of the paediatric femoral shaft fractures are now treated operatively. Operative intervention results in shorter hospital stay and has economic and social benefits over conservative treatment.

There is no study in the past that compares titanium with stainless steel as nail material. However, few studies do compare

titanium plates with stainless steel plates which show that the titanium plates led to the appearance of a small amount of periosteal callus without any histological evidence of fracture instability, thus allowing the radiological assessment of fracture union. Titanium plates also produced less bone loss during the remodelling phase and less soft-tissue reaction than stainless steel plates.

In our study the number of patients with normal range of motion at hip and knee in Group 1 was 16 (94.12%), while in Group 2 the number was 17 (100%). Similar results were obtained by the studies of Khazzam et al⁹ and Lohiya et al¹⁰ where clinical evaluation revealed full range of motion of the hip and knee in all patients at final follow-up. The average duration of progressing to full weight bearing in our study was 11.6 weeks. In the study by Lohiya et al¹⁰ the mean duration of full weight bearing was 10.5 weeks. Khazzam et al⁹ in their study recorded a mean of 8.7 weeks (range, 3–22 weeks), for walking without assistive devices. The number of patients in Group 1 with union occurring across fracture site within 12 weeks was 14 (82.35%), While in Group 2 it was 12 (70.59%), The average duration was 11.8 weeks. El-Adl et al¹¹ in their study recorded a mean of 12 weeks for union across fracture site.

In this study, minor complications were observed in 47.06% of patients in titanium group and 35.29% of patients in stainless steel group with no major complications. There was no significant difference in malunion rate in both groups in sagittal as well as in coronal plane ($p = 1.00$). Contrary to our study, Wall et al³ reported that the malunion rate was significantly higher in the titanium group (23.2%; 13/56) than in the stainless steel group (6.3%; 3/48, $p = 0.017$). The risk of malunion was nearly four times higher in the titanium group than in the stainless steel group (odds ratio = 4.535; 95% confidence interval, 1.208–17.029). This difference may be due to the reason that their study was not randomized. However, similar results between two implants were seen in the study by Rios et al,¹² consistent with our study.

In the present study, the total outcome according to Flynn's criteria⁷ was excellent in 58.82% of patients and satisfactory in 41.18% with no poor results. The difference in the puncture of the opposite cortex in two groups was significant, which might be due to the increased stiffness of stainless steel (Young's modulus = 196 GPa) as compared to titanium (Young's modulus = 115 GPa). Young's modulus of normal bone is 7–25 GPa.

The average time range from implantation to extraction was 10–12 months, and we did not face difficulty in any case in both groups while removing the hardware. Some limitations of the study were that we did not take into account of the length of nail left outside the distal cortex (whether it was bent or kept straight), which is an important cause of insertion site pain and skin irritation. Another major limitation was that the exact biochemical properties and composition of the titanium and stainless steel implant used in the study, which differs from manufacturer to manufacturer, was also not taken into consideration.

The cost of stainless steel nail is one third the cost of titanium elastic nail system. However, the clinico-radiological results are not significantly different between the two groups at one year follow-up.

Table 3

Time of full weight bearing and union (n, %). In each group, the total number of patients is 17.

Group	Time to full weight bearing		Time to union	
	≤12 weeks	>12 weeks	≤12 weeks	>12 weeks
Titanium	14 (82.35)	3 (17.65)	14 (82.35)	3 (17.65)
Stainless steel	13 (76.47)	4 (23.53)	12 (70.59)	5 (29.41)

Table 4

Complications (n, %). In each group, the total number of patients is 17.

Group	Complications				
	Pain at the site of insertion	Minor angulation	Minor LLD	Inflammatory bursa	Puncture of the opposite cortex
Titanium	7 (41.18)	1 (5.89)	1 (5.89)	3 (17.65)	1 (5.89)
Stainless steel	5 (29.41)	0 (0)	1 (5.89)	3 (17.65)	5 (29.41)

References

1. Mahar AT, Lee SS, Lalonde FD, et al. Biomechanical comparison of stainless steel and titanium nails for fixation of simulated femoral fractures. *J Pediatr Orthop*. 2004;24:638–641.
2. Mani US, Sabatino CT, Sabharwal S, et al. Biomechanical comparison of flexible stainless steel and titanium nails with external fixation using a femur fracture model. *J Pediatr Orthop*. 2006;26:182–187.
3. Wall EJ, Jain V, Vora V, et al. Complications of titanium and stainless steel elastic nail fixation of pediatric femoral fractures. *J Bone Jt Surg Am*. 2008;90:1305–1313.
4. Salem KH, Keppler P. Limb geometry after elastic stable nailing for paediatric femoral fractures. *J Bone Jt Surg Am*. 2010;92:1409–1417.
5. Kanlic EM, Anglen JO, Smith DG, et al. Advantages of submuscular bridge plating for complex paediatric femur fractures. *Clin Orthop Relat Res*. 2004;426:244–251.
6. Beaty JH, Kasser JR. *Rockwood and Wilkins' Fractures in Children*. 6th ed. Philadelphia, PA: LWW; 2006.
7. Flynn JM, Hresko T, Reynolds RA, et al. Titanium elastic nails for pediatric femur fractures: a multicenter study of early results with analysis of complications. *J Pediatr Orthop*. 2001;21:4–8.
8. Lee YH, Lim KB, Gao GX, et al. Traction and spica casting for closed femoral shaft fractures in children. *J Orthop Surg (Hong Kong)*. 2007;15:37–40.
9. Khazzam M, Tassone C, Liu XC, et al. Use of flexible intramedullary nail fixation in treating femur fractures in children. *Am J Orthop (Belle Mead NJ)*. 2009;38:E49–E55.
10. Lohiya R, Bachhal V, Khan U. Flexible intramedullary nailing in paediatric femoral fractures. A report of 73 cases. *J Ortho Surg Res*. 2011;6:64.
11. El-Adl G, Mostafa MF, Khalil MA, et al. Titanium elastic nail fixation for paediatric femoral and tibial fractures. *Acta Orthop Belg*. 2009;75:512–520.
12. Ríos AU, Arango DF, Molina CO, et al. Femoral shaft fractures treated with stainless steel flexible nails in children aged between 5 and 12 years at the HUSVP: a two-year follow-up. *J Child Orthop*. 2009;3:129–135.