

Spontaneous rupture of giant hepatic hemangioma: misdiagnosis as gastrointestinal perforation

Journal of International Medical Research

2019, Vol. 47(9) 4514–4521

© The Author(s) 2019

Article reuse guidelines:

sagepub.com/journals-permissions

DOI: 10.1177/0300060519866624

journals.sagepub.com/home/imr

Lu-Lu Zhai^{1,2} , Tong-Fa Ju^{1,2},
Chun-Hua Zhou^{1,2} and Qi Xie^{1,2}

Abstract

Hepatic hemangioma is a frequent nonmalignant tumor in the human liver. Although rupture of hepatic hemangioma is a rare complication, it may have serious consequences. In this report, we describe a 56-year-old woman who underwent laparoscopic surgery and open surgery for sudden abdominal pain and peritonitis. Gastrointestinal perforation was prioritized before surgery according to the patient's symptoms, signs, and radiological report. A giant dark red mass connected to the left liver by a pedicle was unexpectedly found during intraoperative exploration. Hemoperitoneum was also found. Conversely, no gastrointestinal perforation was found during intraoperative exploration. The mass was successfully removed, and the hemoperitoneum was resolved. Postoperative pathological examination showed that the mass was a hepatic hemangioma. Ultimately, the patient was diagnosed with spontaneous rupture of a giant hepatic hemangioma.

Keywords

Hepatic hemangioma, spontaneous rupture, laparoscopic surgery, open surgery, peritonitis, hemoperitoneum

Date received: 27 January 2019; accepted: 9 July 2019

Introduction

Hepatic hemangioma is a frequent nonmalignant (benign) tumor in the human liver. This tumor is also known as cavernous hemangioma because of its histologically visible cavernous vascular space. Hepatic hemangioma usually causes no symptoms or signs because of its slow growth.¹ Nevertheless,

¹Department of General Surgery, Affiliated Hangzhou First People's Hospital, Zhejiang University School of Medicine, Hangzhou, People's Republic of China

²Department of General Surgery, Hangzhou First People's Hospital, Nanjing Medical University, Hangzhou, People's Republic of China

Corresponding author:

Qi Xie, Department of General Surgery, Affiliated Hangzhou First People's Hospital, Zhejiang University School of Medicine, 261 Huansha Road, Hangzhou 310006, People's Republic of China.

Email: havy001@126.com



a small number of patients with hepatic hemangioma may develop nonspecific symptoms or signs when the tumor grows to a considerable volume; such symptoms and signs include right upper abdominal pain, abdominal fullness after eating a small amount of food, and nausea and vomiting.² Well-defined and generally accepted diagnostic criteria and an effective therapeutic method for this disease are lacking. Most surgeons agree that the surgical treatment of hepatic hemangioma is only suitable in specific situations.^{3,4} Although the majority of patients with hepatic hemangioma do not require therapy, some special circumstances necessitate surgical treatment, such as a large hemangioma, severe symptoms, or hemangioma rupture.^{3,4} Liver hemangiomas are considered giant when they exceed 50 mm in diameter.⁵⁻⁸ Rupture of a hepatic hemangioma is a rare event with a risk of death, and only a few cases have been reported.⁹⁻¹¹ We herein report a special case of spontaneous rupture of a giant liver hemangioma that was misdiagnosed as a gastrointestinal perforation. This case is being reported to provide a new understanding about the diagnosis and treatment of spontaneous hepatic hemangioma.

Case report

A 56-year-old woman was admitted to the Hangzhou First People's Hospital because of a 1-day history of sudden upper abdominal pain that radiated to the shoulder. She had no history of blunt abdominal injury. On physical examination, her vital signs were stable, body temperature was 37.8°C, pulse rate was 69 beats/minute, blood pressure was 105/59 mmHg, and respiratory rate was 20 breaths/minute. Abdominal physical examination showed signs of peritonitis with upper abdominal muscular defense, mild tenderness, and rebound tenderness. Laboratory tests showed a white blood cell count of $16.7 \times 10^9/L$ (reference range,

$3.5-9.5 \times 10^9/L$), neutrophil ratio of 84.6% (reference range, 40.0%–75.0%), neutrophil count of $14.2 \times 10^9/L$ (reference range, $1.8-6.3 \times 10^9/L$), hemoglobin level of 84 g/L (reference range, 115–150 g/L), red blood cell count of $2.79 \times 10^{12}/L$ (reference range, $3.80-5.10 \times 10^{12}/L$), hematocrit of 0.253 (reference range, 0.350–0.450), alanine aminotransferase level of 72 U/L (reference range, 7–40 U/L), aspartate aminotransferase level of 135 U/L (reference range, 13–35 U/L), gamma-glutamyl transferase level of 15 U/L (reference range, 7–45 U/L), alkaline phosphatase level of 54 U/L (reference range, 50–135 U/L), and albumin level of 28.1 g/L (reference range, 40.0–55.0 g/L). Plain abdominal computed tomography (CT) revealed a huge mass shadow under the left phrenic region next to the fundus of the stomach, bowel wall thickening in the hepatic flexure of the colon, and pelvic fluid (Figure 1(a) and (b)). Gastrointestinal perforation was considered prior to surgery in accordance with the patient's symptoms, signs, and radiological report.

Emergency laparoscopic exploration was performed to investigate the peritonitis. A giant dark red mass (approximately $10 \times 6 \times 5$ cm, smooth, oval) connected to the left liver by a pedicle was unexpectedly found during the intraoperative exploration (Figure 2). The surface of the mass was bleeding. Hemoperitoneum was also found. Therefore, this mass lesion in the left lobe of the liver was considered to be a ruptured hemangioma. We continued to explore the entire gastrointestinal tract, and no gastrointestinal perforation was found. Because of the large volume of the mass, we performed open surgery with an approximately 10-cm-long incision in the right upper abdomen. The dark red mass was successfully removed after ligation of the pedicle, and the hemoperitoneum was resolved. The operation was successfully completed after about 2 hours, and the patient's vital signs were stable. Postoperative gross pathological

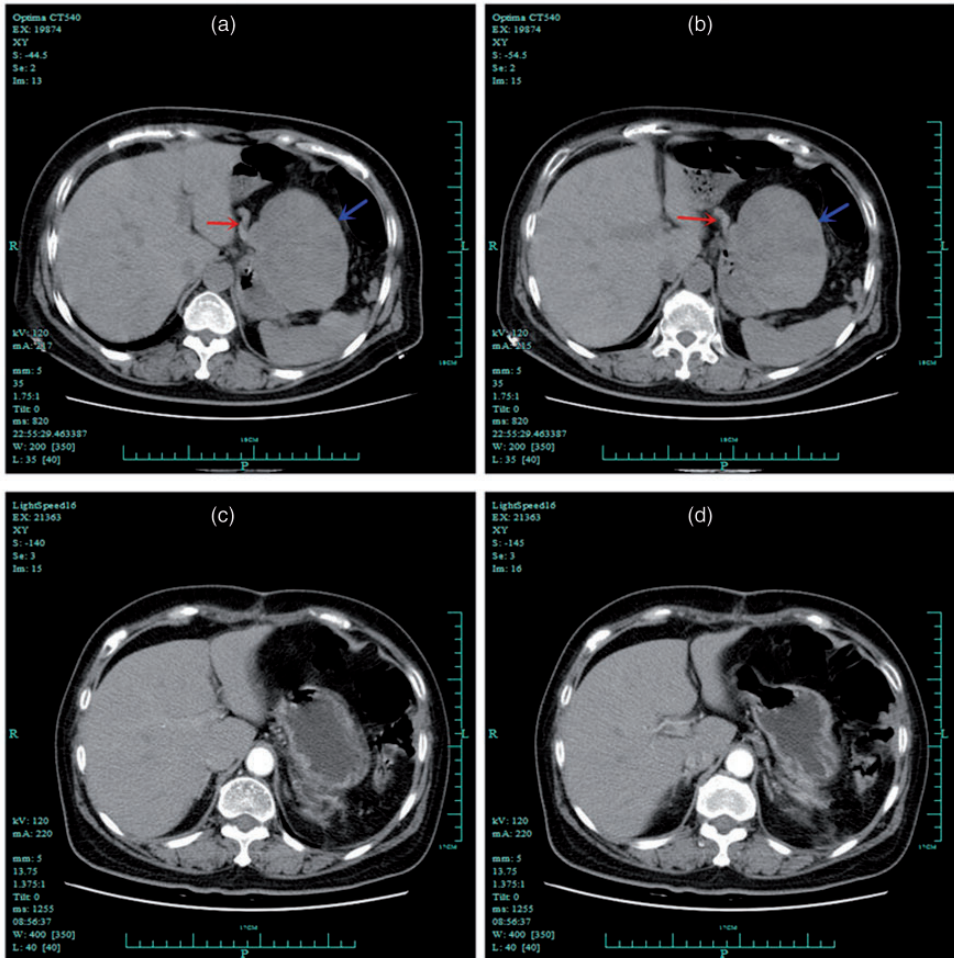


Figure 1. Plain abdominal computed tomography (CT). (a, b) Preoperative CT showed a huge mass shadow (blue arrow) under the left phrenic region next to the fundus of the stomach, connected to the left liver by a pedicle (red arrow). (c, d) Postoperative CT showed that the mass had disappeared.

examination showed that the cut surface of the mass was honeycomb-shaped with a small blood clot on the surface. Microscopic examination revealed a hepatic lobular structure, irregular blood vessel hyperplasia, and a large number of red blood cells (Figure 3(a) and (b)). Immunohistochemical staining revealed a large number of vascular structures marked by CD31 (Figure 3(c) and (d)).

Five days after surgery, plain abdominal CT showed a small amount of encapsulated effusion in the left upper abdomen, edema and thickening of the wall of the ascending colon, and disappearance of the mass (Figure 1(c) and (d)). Ultimately, the patient was diagnosed with spontaneous rupture of a giant hepatic hemangioma. The patient recovered well and was discharged from our hospital. Her postoperative course

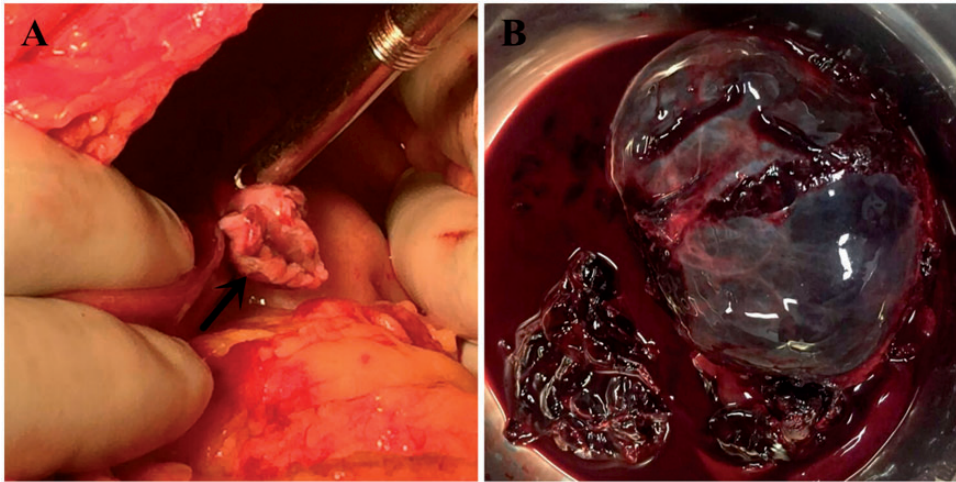


Figure 2. Giant mass after removal from the left liver. (a) The pedicle that connected the mass to the left liver (black arrow). (b) The giant mass was dark red, smooth, and oval.

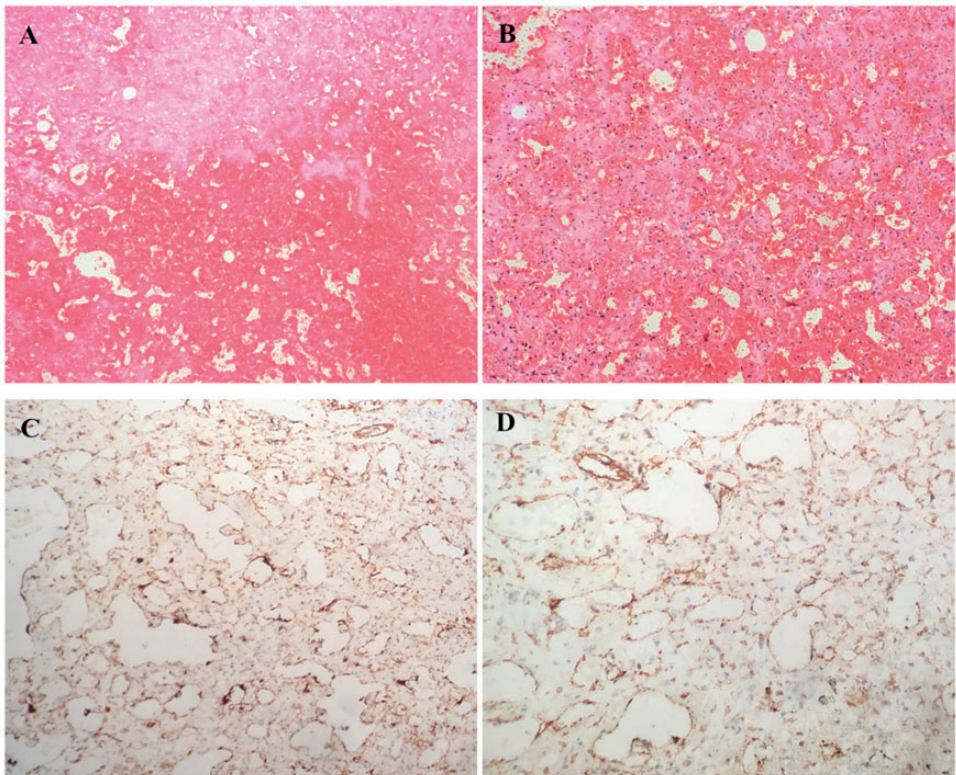


Figure 3. Pathological examination showed that the mass was a hepatic hemangioma with intratumoral hemorrhage. (a, b) Microscopic examination with hematoxylin and eosin staining showed a hepatic lobular structure, irregular blood vessel hyperplasia, and a large number of red blood cells (a, $\times 40$; b, $\times 100$). (c, d) Immunohistochemistry revealed a large number of vascular structures marked by CD31 (c, $\times 40$; d, $\times 100$).

remained uneventful at the 12-month follow-up. Written informed consent was obtained from the patient. This case report did not require ethics committee approval because it did not involve animal or human studies.

Discussion

Most patients with hepatic hemangioma are asymptomatic. Symptomatic hepatic hemangiomas usually present with abdominal distention and abdominal pain.⁹ Additionally, in a few cases, when the tumor size is so large that the bile duct is compressed, the patient will develop jaundice.⁹ Despite the lack of consensus on the definition of giant hepatic hemangioma, a liver hemangioma with a length (diameter) of >5 cm is generally described as a giant hepatic hemangioma.⁵⁻⁸ Most patients with small and asymptomatic hepatic hemangiomas do not require special treatment. The clinical therapy of larger hepatic hemangiomas has long been controversial. Additionally, hepatic hemangioma has no established diagnostic criteria, making it easy to misdiagnose as other diseases. At present, the diagnosis of hepatic hemangioma mainly depends on imaging methods, including ultrasonography, CT, magnetic resonance imaging (MRI), nuclear medicine, and hepatic arteriography.^{8,12,13} Among these techniques, ultrasound, CT, and MRI are the most commonly used noninvasive methods, and most hepatic hemangiomas can be found by them.⁸ In particular, dynamic contrast-enhanced CT or MRI provides important evidence for establishing a definitive diagnosis of hepatic hemangioma.¹³ When hemangiomas rupture, radiological findings reveal hemoperitoneum and a heterogeneous hepatic mass.¹² Rupture of a hepatic hemangioma is usually associated with abdominal trauma; spontaneous rupture is an extremely rare event. Spontaneous rupture of a

hepatic hemangioma usually occurs in lesions with a diameter of ≥ 4 cm that are near the surface of the liver or show exophytic growth.^{2,13} The risk of spontaneous rupture is higher if a patient with a hepatic hemangioma is receiving steroid therapy.^{2,13} In addition, patients with endometrial cancer have an increased risk of spontaneous rupture because the elevated estrogen level in the body promotes the growth of hepatic hemangioma.⁵

Spontaneous rupture of hepatic hemangioma is often very challenging to manage because it is considered a life-threatening emergency. Because of the critical condition of the patient, achieving a definitive diagnosis in a short time is difficult. When the hepatic hemangioma spontaneously ruptures, it can be easily misdiagnosed because a gastrointestinal perforation is also associated with severe abdominal pain, peritonitis, and shock. In this report, we have presented a special case of a huge liver hemangioma with spontaneous rupture. A gastrointestinal perforation was prioritized in this case, preventing preoperative diagnosis of the spontaneous rupture of the hepatic hemangioma, for the following reasons. First, the patient's symptoms and signs were very similar to those of peritonitis caused by perforation of cavitated viscera. Second, the hepatic hemangioma had not been found before the patient was admitted to our hospital. Third, the patient had neither a history of abdominal trauma nor a history of receiving steroid therapy. Finally, because this was a night emergency case, the patient only underwent plain abdominal CT without contrast enhancement.

This special case warns us that we should pay close attention to the possible misdiagnosis of hepatic hemangioma in the clinical setting. Enhanced abdominal CT or MRI should be performed for patients with peritonitis, even when they present on an emergency basis at night. Additionally, this case reminds surgeons to reconsider

Table 1. Other case reports of spontaneous rupture of giant hepatic hemangioma.

Authors	Title	Journal	Year
Scribano et al. ¹⁴	Spontaneous hemoperitoneum from a giant multicystic hemangioma of the liver: a case report	<i>Abdom Imaging</i>	1996
Cappellani et al. ¹⁵	Spontaneous rupture of a giant hemangioma of the liver	<i>Ann Ital Chir</i>	2000
Corigliano et al. ¹⁶	Hemoperitoneum from a spontaneous rupture of a giant hemangioma of the liver: report of a case	<i>Surg Today</i>	2003
Santos Rodrigues et al. ⁹	Spontaneous rupture of giant hepatic hemangioma: a rare source of hemoperitoneum. Case report	<i>G Chir</i>	2010
Jain et al. ¹⁷	Spontaneous rupture of a giant hepatic hemangioma - sequential management with transcatheter arterial embolization and resection	<i>Saudi J Gastroenterol</i>	2010
Lupinacci et al. ¹⁸	Spontaneous rupture of a giant hepatic hemangioma. Sequential treatment with preoperative transcatheter arterial embolization and conservative hepatectomy	<i>G Chir</i>	2011
Gupta et al. ¹⁹	Spontaneous rupture of a giant hepatic hemangioma - report of a case	<i>Indian J Surg</i>	2012
Zhao et al. ¹³	Spontaneous rupture of hepatic hemangioma: a case report and literature review	<i>Int J Clin Exp Pathol</i>	2015
Doklestić et al. ¹⁰	Spontaneous rupture of giant liver hemangioma: case report	<i>Srp Arh Celok Lek</i>	2013
Hao et al. ²⁰	Spontaneous internal hemorrhage of a giant hepatic hemangioma: a case report	<i>Medicine (Baltimore)</i>	2017

the surgical indications for hepatic hemangioma, especially giant hepatic hemangioma. Early aggressive therapeutic measures should be taken to avoid fatal spontaneous rupture when a hemangioma is located close to the edge of the liver and has a large volume, even if the patient has no clinical symptoms or signs.

Several reports have described the spontaneous rupture of giant hepatic hemangiomas. To more comprehensively understand this disease, we searched the Web of Science, PubMed, and Medline databases for similar cases. After carefully reading the content of these reports, 10 articles on this disease were screened^{9,10,13–20} (Table 1). These previous reports combined with our current case report will significantly

contribute to the diagnosis and treatment of spontaneous rupture of giant hepatic hemangioma.

Acknowledgements

The authors thank the patient, who agreed to the publication of this case report. The authors thank pathologists Ling-ling Wang and Xiao-Lan Qian for establishing the pathological diagnosis. The authors thank all of the anonymous reviewers and editors for their helpful suggestions regarding improvement in the quality of this article.

Declaration of conflicting interests

The authors declare that there is no conflict of interest.

Funding

This report was supported by the Zhejiang Provincial Natural Science Foundation of China (No. LGF19H290004), the Science and Technology Development Foundation of Nanjing Medical University (No. 2017NJMU084), and the Medicine and Health Foundation of Zhejiang Province (No. 2018259744).

Authors' contributions

Lu-Lu Zhai performed the surgery, collected the clinical data, and wrote and revised the article. Tong-Fa Ju and Chun-Hua Zhou modified and edited the article. Qi Xie performed the surgery, designed the article, and reviewed and revised the article.

ORCID iD

Lu-Lu Zhai  <https://orcid.org/0000-0003-0839-7316>

References

1. Donati M, Stavrou GA, Donati A, et al. The risk of spontaneous rupture of liver hemangiomas: a critical review of the literature. *J Hepatobiliary Pancreat Sci* 2011; 18: 797–805.
2. Aiura K, Ohshima R, Matsumoto K, et al. Spontaneous rupture of liver hemangioma: risk factors for rupture. *J Hep Bil Pancr Surg* 1996; 3: 308–312.
3. Miura JT, Amini A, Schmocker R, et al. Surgical management of hepatic hemangiomas: a multi-institutional experience. *HPB (Oxford)* 2014; 16: 924–928.
4. Zhang W, Huang ZY, Ke CS, et al. Surgical treatment of giant liver hemangioma larger than 10 cm: a single center's experience with 86 patients. *Medicine (Baltimore)* 2015; 94: e1420.
5. Bara T Jr, Gurzu S, Jung I, et al. Giant cavernous hepatic hemangioma diagnosed incidentally in a perimenopausal obese female with endometrial adenocarcinoma: a case report. *Anticancer Res* 2016; 36: 769–772.
6. Akbulut S, Yilmaz M, Kahraman A, et al. Bilateral lower limb edema caused by compression of the retrohepatic inferior vena cava by a giant hepatic hemangioma. *Int Surg* 2013; 98: 229–233.
7. Aydin C, Akbulut S, Kutluturk K, et al. Giant hepatic hemangioma presenting as gastric outlet obstruction. *Int Surg* 2013; 98: 19–23.
8. Hoekstra LT, Bieze M, Erdogan D, et al. Management of giant liver hemangiomas: an update. *Expert Rev Gastroenterol Hepatol* 2013; 7: 263–268.
9. Santos Rodrigues AL, Silva Santana AC, Carvalho Araújo K, et al. Spontaneous rupture of giant hepatic hemangioma: a rare source of hemoperitoneum. Case report. *G Chir* 2010; 31: 83–85.
10. Doklestić K, Stefanović B, Karamarković A, et al. Spontaneous rupture of giant liver hemangioma: case report. *Srp Arh Celok Lek* 2013; 141: 95–99.
11. Goidescu OC and Patrascu T. Ruptured liver cavernous hemangioma - rare cause of hemoperitoneum. *J Med Life* 2015; 8: 73–74.
12. Ribeiro MA Jr, Papaiordanou F, Gonçalves JM, et al. Spontaneous rupture of hepatic hemangiomas: a review of the literature. *World J Hepatol* 2010; 2: 428–433.
13. Zhao W, Guo X and Dong J. Spontaneous rupture of hepatic hemangioma: a case report and literature review. *Int J Clin Exp Pathol* 2015; 8: 13426–13428.
14. Scribano E, Loria G, Ascenti G, et al. Spontaneous hemoperitoneum from a giant multicystic hemangioma of the liver: a case report. *Abdom Imaging* 1996; 21: 418–419.
15. Cappellani A, Zanghi A, Di Vita M, et al. Spontaneous rupture of a giant hemangioma of the liver. *Ann Ital Chir* 2000; 71: 379–383.
16. Corigliano N, Mercantini P, Amodio PM, et al. Hemoperitoneum from a spontaneous rupture of a giant hemangioma of the liver: report of a case. *Surg Today* 2003; 33: 459–463.
17. Jain V, Ramachandran V, Garg R, et al. Spontaneous rupture of a giant hepatic hemangioma - sequential management with transcatheter arterial embolization and

- resection. *Saudi J Gastroenterol* 2010; 16: 116–119.
18. Lupinacci RM, Szejnfeld D and Farah JF. Spontaneous rupture of a giant hepatic hemangioma. Sequential treatment with preoperative transcatheter arterial embolization and conservative hepatectomy. *G Chir* 2011; 32: 469–472.
 19. Gupta S, Agarwal V and Acharya AN. Spontaneous rupture of a giant hepatic hemangioma-report of a case. *Indian J Surg* 2012; 74: 434–436.
 20. Hao F, Yang X, Tian Y, et al. Spontaneous internal hemorrhage of a giant hepatic hemangioma: a case report. *Medicine (Baltimore)* 2017; 96: e8702.