



## Research Article

# Radiofrequency ablation in experimental bone metastases using a controlled and navigated ablation device



D. Proschek<sup>a,\*</sup>, M. Tonak<sup>a</sup>, S. Zangos<sup>b</sup>, M.G. Mack<sup>b</sup>, A.A. Kurth<sup>a,b</sup>

<sup>a</sup> Center for Musculoskeletal Surgery, Department of Orthopaedic Surgery, University Medical Center Mainz, Germany

<sup>b</sup> Department of Diagnostic and Interventional Radiology, University Hospital, Frankfurt, Germany

## ARTICLE INFO

## Article history:

Received 17 April 2012

Received in revised form

21 June 2012

Accepted 4 July 2012

Available online 9 August 2012

## Keywords:

Radiofrequency ablation

Bone tumor

Animal model

Rabbit

VX-2

Tumor therapy

## ABSTRACT

**Background:** Radiofrequency ablation is a minimal invasive therapy in the treatment of bone metastases. In this study we present a new ablation system enabling an ablation in multiple directions and with an adaptable size and shape.

**Material and methods:** VX-2 tumor was used for the induction of experimental bone metastases in the femur of six New Zealand white rabbits. X-ray imaging as well as CT and MRI scans before and after treatment was carried out. After detecting bone tumor, radiofrequency ablation was performed. The ablation instrument contained a 10 g bipolar, articulated extendable electrode and a proprietary generator with an impedance controlled algorithm. All bones and the soft tissue were examined histologically.

**Results:** All animals developed local bone tumor. Mean duration until first osteolytic lesions on CT-scans was  $48 \pm 14$  days. The mean lesion area was  $26 \text{ mm}^2$ . No systemic tumor spread was seen. 6 radiofrequency procedures were carried out with a mean application time of  $6 \text{ min} \pm 2:30$  and an average temperature in the region of effect of  $55 \text{ }^\circ\text{C} \pm 4$ . MRI imaging demonstrated an ablation zone of  $23 \pm 6 \text{ mm}$  around the electrode. Histopathology showed an extensive heat necrosis with no remaining tumor cells in the ablation area.

**Conclusion:** Radiofrequency ablation is a quickly developing treatment option on the field of minimal invasive bone tumor therapy. The electrode enables an ablation adapted to size and shape of the metastases. Further clinical studies are necessary to test and enhance this radiofrequency system.

© 2012 Elsevier GmbH. This is an open access article under the CC BY-NC-ND license (<http://creativecommons.org/licenses/by-nc-nd/4.0/>).

## 1. Introduction

Bone metastases are one of the most frequent complications of malignant tumors and they are a relevant source of morbidity. Up to 70% of all tumor patients develop bone metastases [1]. Most of the patients suffer from pain with a reduction of mobility and life quality and therefore have a high risk of concomitant complications [2].

Therapy of bone metastases follows three strategies: pain relief, improvement of mobility and quality of life, and improvement of life expectancy. Therapeutic possibilities comprise local strategies like radiation, surgical therapy and systemic therapy. Surgical therapy needs large approaches and the rate of complications as well as the comorbidity and length of hospital stay are not negligible. Minimal invasive therapy of bone tumor is getting more important [3]. The advantages are obvious. The size of the surgical approach as well as operation time and complication rate are reduced. Comorbidity, quality of life and the time as an inpatient are improved [4]. Therefore further developments in the field of minimal invasive tumor therapy are necessary.

Radiofrequency ablation in bone tumor is an upcoming technique which was first described by Rosenthal et al. [5]. It is used to treat multiple benign and malignant diseases. Liver, lung and bone have become the primary target tissue in the thermal ablation therapy [6]. Due to its high efficacy and safety, radiofrequency ablation has become one of the most accepted techniques in hyperthermal ablation therapy [7]. The radiofrequency system consists of a generator and an electrode system. While the generators are highly developed, the electrodes for bone ablation are still the weak point of this technology. They are rigid and ablate in a predefined and mainly oval shaped zone only. Further developments are necessary to develop new ablation system with which a multidirectional ablation is necessary.

In this study we present a new ablation system with which an ablation in multiple directions and with an adaptable size and shape of the heat zone is possible.

## 2. Material and Methods

### 2.1. Animal model

Six female New Zealand white rabbits were used in this trial. All animals were kept in single cages, had free access to tap water

\* Correspondence to: Center for Musculoskeletal Surgery, Department of Orthopaedic Surgery, University Medical Center, Langenbeckstrasse 1, 55131 Mainz.

Tel.: +49 6131 17 7180; fax: +49 6131 17 3416.

E-mail address: [proschek@arcor.de](mailto:proschek@arcor.de) (D. Proschek).

and were fed with a standard chow. After arriving in our laboratory, the animals were examined and adapted to the laboratory conditions for one week before entering the study. All experiments were approved by the governmental Animal Ethics Committee.

A VX-2 tumor suspension (Cell Line Service, Eppelheim, Germany) as well as a three-dimensional matrix carrying the suspension were used in this trial. The matrix consists of alginate. For preparation of the spheroids an alginate solution was mixed by solving 1% of alginate powder (Roth, Germany) in DMEM high glucose (BD, Germany) under stirring for 30 min. After finishing, the alginate solution was mixed in ratio 1:1 with 500  $\mu$ l of VX-2 tumor suspension. Tumor cell spheroids were created by dropping 1 ml of this mixture in a 10% calcium chloride solution (Braun, Germany). 25 spheroids were produced out of 1 ml of the mixture. 5 of these spheroids were implanted into the left distal femoral metaphysis of the rabbits by a minimal invasive approach.

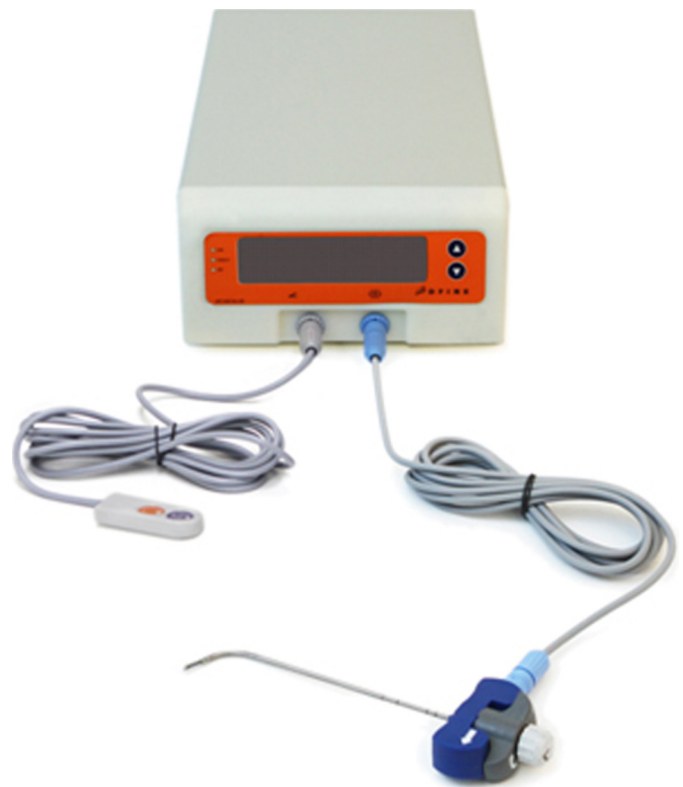All procedures were performed under general anesthesia using 50 mg/kg body weight of ketamine hydrochloride s.c. (Parker-Davis, Berlin, Germany) and 25 mg/kg body weight of 2% xylazine hydrochloride (Bayer, Leverkusen, Germany). After careful disinfection and preparation of the knee- and leg-area, a small longitudinal medial and infrapatellar skin incision was carried out. The patellar tendon was splitted longitudinally. Under fluoroscopy guidance a cannula was introduced into the left metaphysis of the femoral leg. After preparing the femoral bone, the implantation of the tumor cells was carried out, using 5 alginate spheroids for each animal. The spheroids were introduced through the cannula using a blunt trocar. After this procedure, the cannula was pulled back and bone wax was introduced in order to seal the drill hole and to prevent a leakage of tumor cells into the soft tissue. After finishing the implantation the soft tissue was reconstructed surgically.

## 2.2. Radiofrequency ablation

Radiofrequency ablation was carried out in all animals. The STAR-system (Spinal Tumor Ablation with Radiofrequency; Dfine, San Jose, CA, U.S.) was used in this trial. The STAR-system contains a generator and a bipolar navigational ablation instrument (Fig. 1). The ablation generator has a bipolar design with temperature sensing and controlled energy delivery. The ablation electrode has a new navigational concept and enables a multi-directional positioning of the tip of the electrode. This provides a site specific access to the bone. All animals were screened for metastases using CT- and MRI-scans. The changes in the perimeter (mm) and the area of osteolytic bone ( $\text{mm}^2$ ) were evaluated subsequently. Radiofrequency ablation was carried out after detecting bone metastases with a tumor size bigger than 10 mm in diameter. The knee joint was opened using the same surgical approach as for the implantation of the tumor cells. The radiofrequency electrode (10 G) was positioned under CT-guidance. The handgrip consists of three separate grips for the positioning of the electrode. The rotatable blue handgrip turns the whole instrument with a range of rotation of up to 360°. The rotatable gray grip enables a bending of the electrode of up to 90° while the white grip changes the active length of the tip of the electrode. Radiofrequency ablation was carried out using the bipolar radiofrequency generator (Fig. 1).

## 2.3. Postinterventional assessments

All animals were examined before and after radiofrequency ablation using CT- (Siemens Somatom, Germany, UHR-spine program) and MRI scans (Siemens Symphony, Germany, hand



**Fig. 1.** STAR-system containing the generator and the bipolar navigational ablation instrument.

wrist coil, T1/ T2 weighted and fat suppressed imaging, contrast enhanced sequences). Tumor size as well as shape and size of the ablation necrosis was measured. Before finishing the trial, all animals were scanned for a systemic tumor spread using CT. After finishing the ablation procedure and the imaging all animals were sacrificed. Both the femora were collected for histopathological examination.

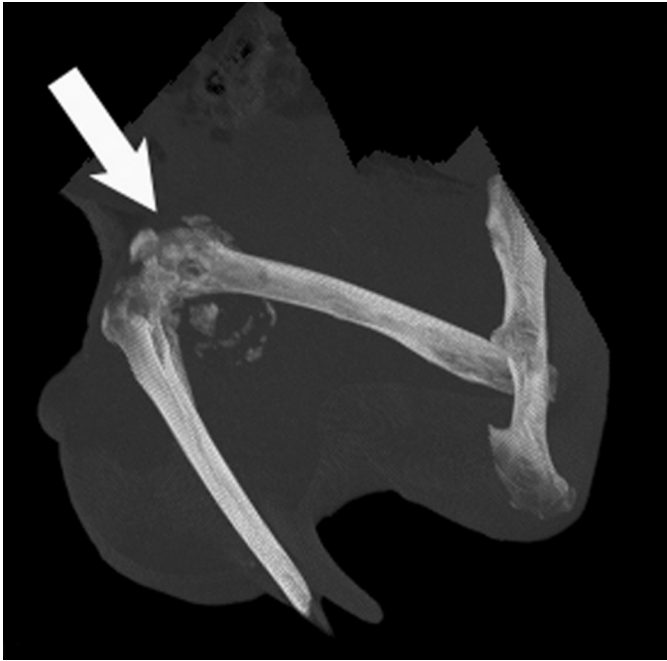## 3. Results

### 3.1. Experimental bone tumor

6 animals were treated. Inoculation of tumor cells was well tolerated as animals recovered quickly from the surgical procedure. General anesthesia was carried out without any side effects. There were no restrictions in the mobility of the operated knee in all animals. The mean time of the surgical procedure was 6 min. 5 spheroids were implanted in the distal femur of each animal. The drill hole was sealed using bone wax. There were no technical and post procedural complications. All animals developed local bone tumor. Lytic lesions were detected by X-ray in some animals as early as 4 weeks after tumor cell implantation. Mean duration until first osteolytic lesions on CT-scans was  $48 \pm 14$  day. The mean lesion area on first detection was  $26 \text{ mm}^2$ . No systemic tumor spread was seen in all animals.

### 3.2. Radiological examination

CT and MRI scans were carried out in general anesthesia before and after the ablation procedure (Fig. 2). Radiofrequency ablation was carried out CT-guided. MRI imaging demonstrated a well confined ablation zone of  $23 \pm 6$  mm around the active length of



**Fig. 2.** Sagittal CT reconstruction of the femur of a rabbit. See the tumor with a local destruction in the distal femur marked with an arrow.

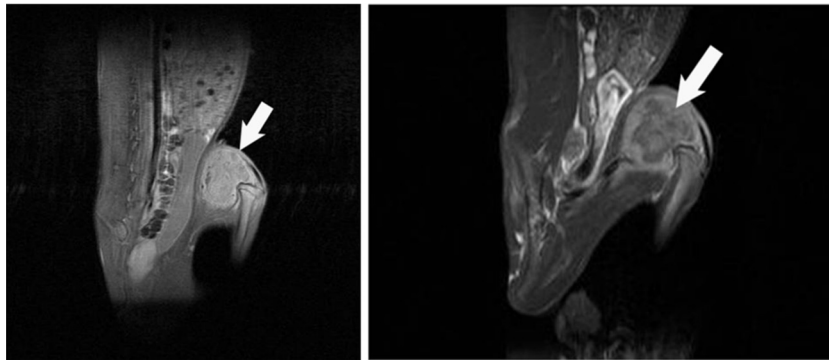
the electrode. **Fig. 3** demonstrates the changes in MRI imaging before and after the ablation.

### 3.3. Radiofrequency ablation

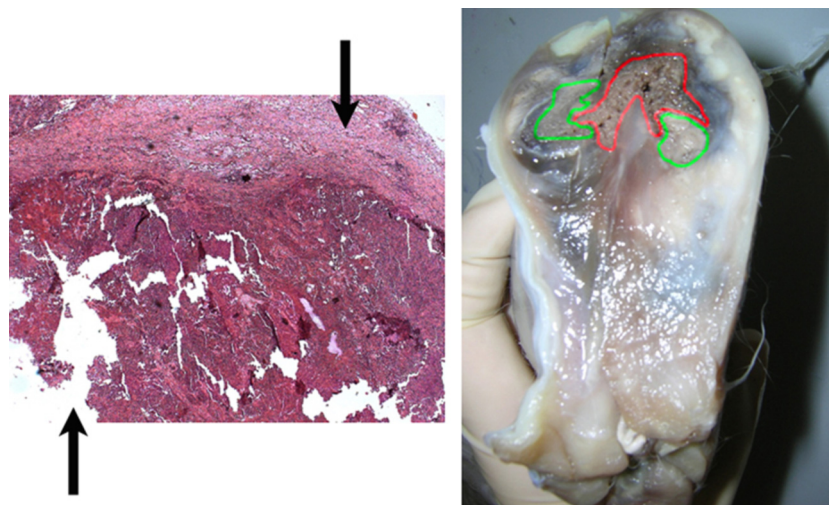
Tumors > 1 cm in diameter received CT guided radiofrequency ablation using the STAR System. The ablation instrument contained a 10 g bipolar, articulated extendable electrode containing multiple thermocouples and a proprietary generator with impedance and temperature controlled algorithm. 6 procedures were carried out with a mean application time of 6 min  $\pm$  2:30 and an average temperature in the region of effect (distal thermocouple) of 55 °C  $\pm$  4. Tumor coagulation was finished when the continuing energy-flow was stopped due to an arising of the impedance or reaching a temperature of more than 45 °C in the proximal thermocouple. The proximal thermocouple is an important safety marker that the treatment is confined within the targeted area. Radiofrequency ablation was carried successfully and without complications in all animals.

### 3.4. Histology

The femora were collected for histopathological examination. All animals developed local bone metastases in the distal femur. The area around the former drill hole showed an extensive tumor infiltration with a circular necrosis after thermal ablation. In the



**Fig. 3.** Sagittal MRI scans of the femoral bone with a tumor growth distally, on the left side before and on the right side after the ablation procedure. Note the tumor growth on the left side (arrow) as well as the extensive necrosis and the remaining tumor tissue around the ablation zone on the right side (arrow).



**Fig. 4.** Histopathological examination. Left side: hematoxylin-eosin stain, light microscopy. Circular heat necrosis around the insertion channel of the electrode (lower arrow). Remaining tumor tissue with tumor cells at the edge of the necrosis (upper arrow) Right side: Cutted preparation of a rabbit leg. Heat necrosis around the insertion channel (red marked). Remaining tumor tissue (green marked). (For interpretation of the references to color in this figure legend, the reader is referred to the web version of this article.)

area of the necrosis no tumor cells were detected. Remaining tumor cells were found at the edge of the coagulation zone (Fig. 4).

#### 4. Discussion

Radiofrequency ablation has a long history of use. It has been used especially in the neurosurgical field [8,9]. Rosenthal described the first ablations in bone 20 years ago [5]. Technically the radiofrequency generator forms an electric current leading to an ionic agitation in the tissue creating heat. The energy leads to cell death and coagulation necrosis. Radiofrequency ablation has several advantages: it is a minimal invasive therapy, major complications are unknown [6]. The energy application can be controlled by the applicator and generator design. Impedance measurements allow an exact thermal ablation of pathologic tissue. However radiofrequency ablation is used as a palliative therapy in bone metastases/ bone tumor patients [6,10]. Actually osteoid osteoma is the only bone tumor which can be treated by ablation following a curative approach [11,12].

Another limitation of radiofrequency therapy is that available electrodes are rigid and unidirectional. This reduces the size and shape of a possible ablation zone significantly. Bone metastases have a variable shape and to treat the metastases completely would presume to completely destroy tumor tissue without interfering with healthy tissue. The available electrodes only provide a limited ablation with predefined size and shape of the ablation zone. This is the main reason why radiofrequency ablation does not follow a curative approach in the treatment of bone metastases. A change in design and functionality of the electrodes could help to change this approach. A possible way is to use a multidimensional ablating RF-electrode which is presented here.

The ablation instrument which was used in this study contained a bipolar, articulated extendable electrode with multiple thermocouples and a proprietary generator (Fig. 1). The electrode provides a site specific and controllable ablation. The possibility to articulate and extend the electrode enables to follow a preoperatively planned ablation scheme. In this study all ablation procedures were carried out sufficiently and without complications. The electrodes were positioned CT-guided. After introducing into the bone, the active length of the electrode was positioned in the center of the tumor tissue using articulation and extension of the instrument.

A possible disadvantage of the electrode is that there is no feedback regarding the extent and the shape of the heat necrosis. In the CT or X-ray scan during the intervention the change of the heat reaction cannot be displayed [13]. Therefore the precision of the electrode is not sufficient to enable a curative treatment of the metastases. The setup of the procedure with the preoperative planning and the intraoperative guided positioning of the electrode is complex. But the design of the instrument is a step in the right direction offering variable opportunities in the treatment of bone metastases. Especially automation might be possible with this electrode using a CT data set for planning and enabling a complete ablation of the metastases.

The animal model used in this trial enabled a reproducible induction of local bone tumor. The spheroids were stable and big enough to be inserted in the rabbit femur. They additionally prevented the tumor cells from being washed out into the body inducing a systemic tumor spread. All procedures were carried out without complications. A CT scan of the whole body showed no systemic spread. The mean tumor size was 26 mm<sup>2</sup> and big enough for testing radiofrequency ablation sufficiently. MRI scans before and after the radiofrequency ablation are essential to evaluate tissue changes of the thermal ablation before and after the intervention. In this study MRI after the ablation showed a heat necrosis of 23 ± 6 mm in size with

remaining tumor tissue around the necrosis. MRI during the intervention is not possible due to the design of the RF system. Changes of the tissue cannot be displayed during the ablation.

The study presented here has two disadvantages: the results of this animal trial cannot be transferred to clinical conditions readily and the animals were sacrificed after the radiofrequency ablation. Data would have been more detailed if the animals would have survived the procedure and another MRI scan would have been taken e.g. 1 week after the ablation. This was not possible due to the standards of our Ethical Committee. Rabbits were used in this study because the bone composition and density is nearly similar to human bone [14]. They are the most commonly used animals for medical research [15]. Bones of small animals like rats or mice are not optimal to sufficiently evaluate surgical techniques due to limited size and different microstructure [16]. VX-2 carcinoma was used in this trial because it is the only bone tumor available for rabbits.

The small sample size is a limitation of this study and further examinations are necessary. The results of this animal trial are promising and a clinical multicenter trial is planned based on the preclinical data.

#### 5. Conclusions

Radiofrequency ablation is a quickly developing treatment option on the field of minimal invasive bone tumor therapy. With the articulated extendable electrode presented here it is possible to carry out radiofrequency ablation in multiple directions. The electrode enables an ablation adapted to size and shape of the metastases. Further clinical studies are necessary to test and enhance this radiofrequency system.

#### References

- [1] Layer G. Skelettm metastasen. Springer; 2005.
- [2] Deschamps M, Band PR, Coldman AJ. Assessment of adult cancer pain: shortcomings of current methods. *Pain* 1988;32:133–9.
- [3] Crocetti L, de Baere T, Lencioni R. Quality Improvement Guidelines for Radiofrequency Ablation of Liver Tumours. *Cardiovascular and Interventional Radiology* 2009.
- [4] Rybak LD. Fire and ice: thermal ablation of musculoskeletal tumors. *Radiologic Clinics of North America* 2009;47:455–69.
- [5] Rosenthal DI, Alexander A, Rosenberg AE, Springfield D. Ablation of osteoid osteomas with a percutaneously placed electrode: a new procedure. *Radiology* 1992;183:29–33.
- [6] Rosenthal D, Callstrom MR. Critical review and state of the art in interventional oncology: benign and metastatic disease involving bone. *Radiology* 2012;262:765–80.
- [7] Proschek D, Kurth A, Proschek P, Vogl TJ, Mack MG. Prospective pilot-study of combined bipolar radiofrequency ablation and application of bone cement in bone metastases. *Anticancer Research* 2009;29:2787–92.
- [8] Sweet WH. HH: RF lesions in the central nervous system of man and cat. *Journal of Neurosurgery* 1960;17:213–25.
- [9] Hitchcock E. A comparison of results from center-median and basal thalamotomies for pain. *Surgical Neurology* 1981;15:341–51.
- [10] Gillams A. Tumour ablation: current role in the kidney, lung and bone. *Cancer Imaging: The Official Publication of the International Cancer Imaging Society* 2009;S68–70 [9 Spec no A].
- [11] Rimondi E, Mavrogenis AF, Rossi G, Ciminari R, Malaguti C, Tranfaglia C, et al. Radiofrequency ablation for non-spinal osteoid osteomas in 557 patients. *European Radiology* 2012;22:181–8.
- [12] Papatthaniou ZG, Petsas T, Papachristou D, Megas P. Radiofrequency ablation of osteoid osteomas: five years experience. *Acta Orthopaedica Belgica* 2011;77:827–33.
- [13] Barei DP, Moreau G, Scarborough MT, Neel MD. Percutaneous radiofrequency ablation of osteoid osteoma. *Clinical Orthopaedics and Related Research* 2000;115–24.
- [14] Enneking WF, Flynn L. Effects of VX-2 carcinoma implanted in bone in rabbits. *Cancer Research* 1968;28:1007–13.
- [15] Pearce AI, Richards RG, Milz S, Schneider E, Pearce SG. Animal models for implant biomaterial research in bone: a review. *European Cells and Materials* 2007;13:1–10.
- [16] Rosol TJ, Tannehill-Gregg SH, LeRoy BE, Mandl S, Contag CH. Animal models of bone metastasis. *Cancer* 2003;97:748–57.