

# Singular observation of a desirable change after bronchial artery embolization for hemoptysis in intracavitary aspergilloma

B P K Prasad, Brijesh Ray<sup>1</sup>

Department of Interventional Radiology, Rajagiri Hospital, <sup>1</sup>Department of Imaging and Interventional Radiology, Aster Medcity Hospital, Kochi, Kerala, India

**Correspondence:** Dr. B P K Prasad, Department of Interventional Radiology, Rajagiri Hospital, Aluva Munnaar Road, Chunangamvely, Aluva, Kochi - 683 112, Kerala, India. E-mail: krishnaprasadir@gmail.com

## Abstract

Aspergillomas are fungal balls developing in pre-existing lung cavities, which are most commonly secondary to tuberculosis. Aspergillomas can cause hemoptysis due to erosion of the blood vessels in cavity walls, which can often be recurrent, massive, and life-threatening. Bronchial artery embolization is considered to be the treatment of choice for short-term control of hemoptysis, and lobectomy as the definitive treatment for aspergilloma. We present a unique observation in two cases of aspergilloma where the fungal balls disappeared radiologically after bronchial artery embolization performed for massive hemoptysis.

**Key words:** Aspergilloma; bronchial artery embolization; hemoptysis

## Introduction

Aspergillomas are balls of *Aspergillus fumigatus*, a saprophytic fungus, which in the lung, colonizes pre-existing cavities.<sup>[1-3]</sup> Healed tubercular cavities are the most common nidus for aspergilloma. These fungal balls can erode blood vessels in the cavity walls causing hemoptysis, which is the main symptom. Antifungal agents have poor penetration into the cavity and are ineffective against fungal balls. Surgery in the form of lobectomy is considered to be the definitive treatment of aspergilloma. Bronchial artery embolization has been widely utilized and is considered the treatment of choice for short-term control of hemoptysis.<sup>[4-8]</sup> *Aspergilloma* are known to disappear spontaneously by being coughed out as black material or after topical administration of

antifungals. We present two cases with long-standing aspergilloma presenting with massive hemoptysis where the fungal balls radiologically disappeared promptly after bronchial artery embolization without recurrence during a follow-up period of 6 months; such an event is undescribed as yet.

## Case Reports

### Case report 1

A 53-year-old male patient presented to the casualty department with massive hemoptysis (approximately 1 liter over a period of 36 hours). He had tachycardia (132 bpm) and his blood pressure was 90/50 mmHg. He had history of tuberculosis and had undergone complete

### Access this article online

#### Quick Response Code:



Website:  
www.ijri.org

DOI:  
10.4103/ijri.IJRI\_335\_16

This is an open access article distributed under the terms of the Creative Commons Attribution-NonCommercial-ShareAlike 3.0 License, which allows others to remix, tweak, and build upon the work non-commercially, as long as the author is credited and the new creations are licensed under the identical terms.

**For reprints contact:** reprints@medknow.com

**Cite this article as:** Prasad B, Ray B. Singular observation of a desirable change after bronchial artery embolization for hemoptysis in intracavitary aspergilloma. Indian J Radiol Imaging 2017;27:225-8.

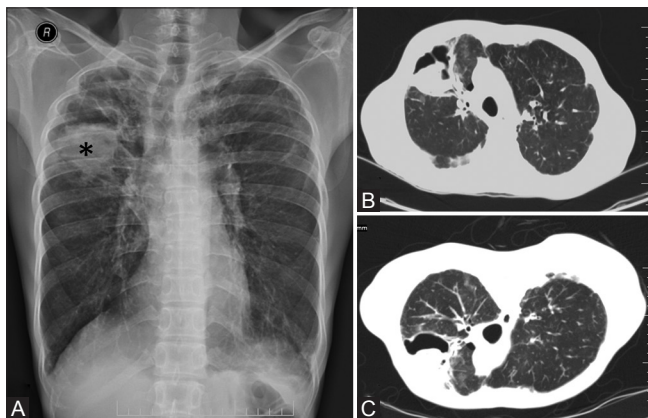
treatment 28 years back, which left him with a cavity in the right upper lobe. He had been having multiple episodes of hemoptysis in the last 5 years, and was radiographically diagnosed to have aspergilloma 4.5 years back. He had been admitted six times in the last 5 years for life-threatening hemoptysis, and was managed conservatively with anti-thrombolytic medication and blood transfusion. Serial radiographs taken over the period had documented persisting aspergilloma in the cavity.

A radiograph showed a cavity in the right upper lobe with a fungal ball [Figure 1A]. Contrast-enhanced computed tomography (CT) was performed in view of mapping bronchial vessels contemplating embolization, which confirmed the presence of fungal ball [Figure 1B and C], and showed two large right bronchial vessels leading to the right upper lobe. Both these vessels were angiographically assessed [Figure 2] and uneventfully embolized to stasis using 355–500- $\mu$  sized polyvinyl alcohol particles (Contour® PVA Embolization Particles, Boston Scientific, Natick, MA) injected through a securely placed 4F Cobra catheter (Cook Medical Inc., Bloomington, USA) within these vessels, following which hemoptysis ceased within 4 hours. A radiograph performed before discharge and the day after embolization showed persistent fungal ball in the cavity and the patient was asked to revisit after 2 weeks.

The patient became completely asymptomatic and a radiograph taken during the follow-up visit showed disappearance of aspergilloma [Figure 3]. There had been no recurrence of symptoms over a follow-up period of 6 months.

### Case report 2

A 32-year-old male patient was referred from an adjacent hospital presenting with severe hemoptysis amounting to approximately 500 ml per day for the last 3 days. Conservative management with an anti-thrombolytic had



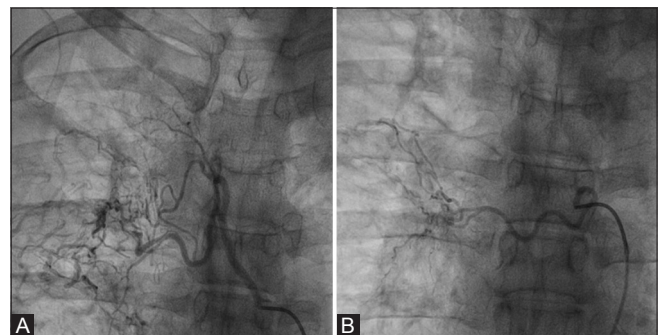
**Figure 1 (A-C):** Radiograph (A) of the chest showing fibrosis in the right upper lobe with a cavity harboring a fungal ball (\*). Supine (B) and prone (C) computed tomography images through the cavity confirming the diagnosis of the fungal ball by demonstrating its mobility within the cavity

failed to control hemoptysis and the patient had received two units of packed cells. On examination, he was pale, had mild tachycardia (120 bpm), and his blood pressure was 110/60 mmHg. He had history of tuberculosis 10 years back and had undergone complete treatment. He had been having recurrent episodes of haemoptysis over the last three years and previous radiographs taken over the period had documented a small cavity in the left upper lobe with a persisting fungal ball.

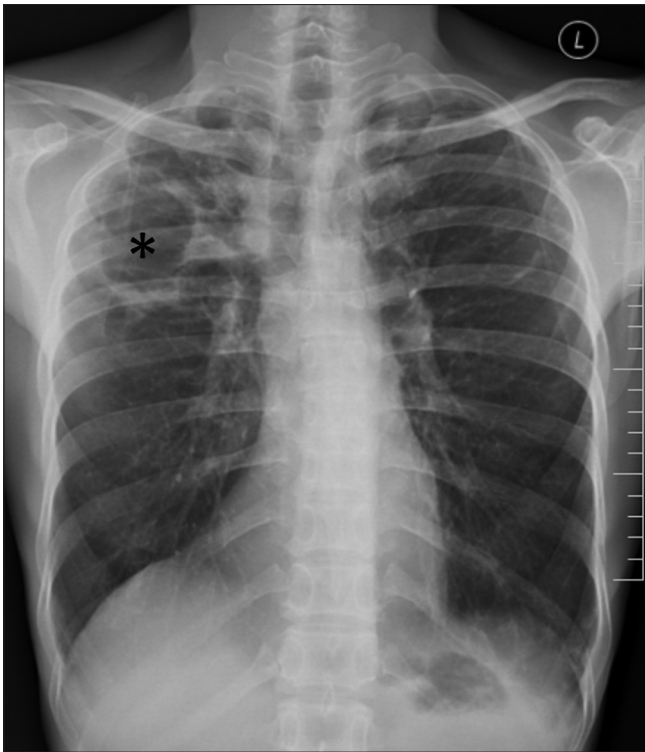
A radiograph showed a cavity with fungal ball in the left upper lobe [Figure 4A]. Contrast enhanced CT performed to map bronchial vessels showed a cavity with a fungal ball in the left upper lobe [Figure 4B], and a single enlarged left bronchial vessel. A sputum sample of this patient was sent for culture, which later grew *Aspergillus fumigatus*. The enlarged vessel [Figure 5A] was uneventfully embolized to stasis using 355–500- $\mu$  sized polyvinyl alcohol particles (Contour® PVA Embolization Particles, Boston Scientific, Natick, MA) injected through a securely placed 4F Judkin's left coronary catheter (Cordis Corp., Johnson and Johnson, New Jersey, USA) within the artery. Hemoptysis stopped completely within 6 hours after embolization. Radiograph taken before discharge showed the persisting fungal ball, which had disappeared as seen in a radiograph and limited non-contrast CT sections taken on follow-up after 2 weeks [Figure 5B]. The patient was completely asymptomatic with no recurrence of symptoms or fungal ball over a follow-up period of 6 months.

### Discussion

Fungi of the *Aspergillus* species and their spores are found in the environment ubiquitously throughout the world.<sup>[1-3]</sup> Healthy population do not develop infection because of the presence of normal mucociliary clearance and alveolar macrophages. In the presence of a locally immunodeficient pre-existing lung cavity due to tuberculosis, bronchiectasis, sarcoidosis, interstitial pneumonia, etc., *Aspergillus* can colonize and form a ball of mycelium, debris, and



**Figure 2 (A and B):** (A and B) Cine angiography pictures showing two tortuous and hypertrophied right bronchial vessels arising from the proximal descending aorta supplying an abnormal hypervascular bed in the right upper lobe

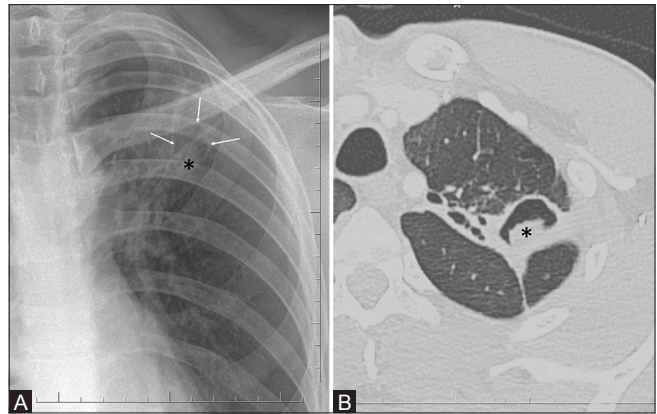


**Figure 3:** Radiograph of the chest taken 2 weeks after embolization showing clear cavity devoid of aspergilloma (\*)

altered blood elements called aspergilloma.<sup>[2]</sup> This derives nutrition from the walls of the cavity which are fed by inflammation-induced angiogenesis from the bronchial circulation. Erosion of such collateral vessels can result in hemoptysis, which is the most common presentation of aspergilloma. Rarely, fungal mycelium can invade the adjacent lung tissue causing necrotizing pulmonary aspergillosis.<sup>[2]</sup>

Spontaneous radiological resolution of almost approximately 10% of asymptomatic aspergillomas has been documented previously in two major studies, however, some of those patients persistently showed *Aspergillus* in sputum and precipitins to *Aspergillus* in serum, suggesting residual disease in cavity walls.<sup>[9,10]</sup> Aspergillomas have also been observed to radiologically resolve by either being coughed out as black material in sputum or during an episode of pyogenic infection of the cavity, the incidence of which is yet undocumented.<sup>[9,10]</sup>

Antifungal agents are not effective for treating aspergilloma because contact of the fungus with systemic circulation or adequate antifungal penetration into the cavity do not occur.<sup>[9]</sup> Surgery in the form of lobectomy is considered the primary treatment for aspergilloma, however, it is fraught with risks because of poor lung reserves of the patients, inflammatory adhesions, and increased chance of intraoperative hemorrhage.<sup>[1,11]</sup> Alternate forms of treatment that has been tried for patients unsuitable for surgery



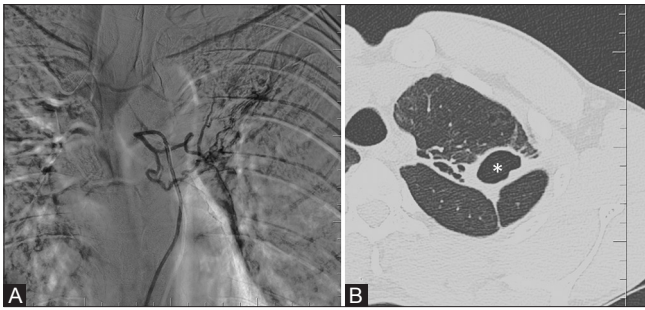**Figure 4 (A and B):** (A) Radiograph of chest showing a cavity (arrows) in the left upper lobe demonstrating a fungal ball (\*) and an air-menisiscus. Computed tomography image (B) through the cavity confirming the presence of a fungal ball (\*)

include topical antifungal instillation percutaneously or transbronchially and have shown variable results.<sup>[2]</sup> These methods are not free of complications as antifungals can cause chemical-induced bronchitis and flare up a background pulmonary fibrosis; there can also be procedure-related complications such as pneumothorax.<sup>[2]</sup>

Massive (defined as blood loss of >300 ml in a day or >100 ml per day for 3 consecutive days), recurrent, or persistent hemoptysis is the major indication for the treatment of aspergilloma. Less popular forms of hemoptysis control, including intracavitary antifungal instillation and hemostatic radiotherapy, are yet to be standardized and completely evaluated.<sup>[12,13]</sup> Bronchial artery embolization has been evaluated for control of hemoptysis in aspergilloma in various studies and is considered to be the first line therapy, and as a method of hemodynamic stabilization before more definitive therapies such as surgery can be undertaken.<sup>[4-8]</sup> All studies indicate effective immediate control of hemoptysis and a higher chance of re-bleed after bronchial artery embolization with aspergilloma compared to other benign pathologies.<sup>[4-7]</sup> There has been no documented disappearance of fungal ball after BAE in any of these studies.

In the present reported two cases, aspergilloma disappeared radiologically promptly in 2 weeks after BAE. It could be argued that fungal balls could have been coughed out during the episodes of massive hemoptysis; however, their presence hours after cessation of hemoptysis and their disappearance after an asymptomatic cough-free period of 2 weeks implies otherwise. Furthermore, prolonged symptom and fungal ball free period following BAE after as long as 6 months indicate that embolization might have a causative role in fungal ball disappearance. Such an event appears plausible theoretically because embolization cuts off nutrition to the fungal ball, which feeds out of the cavity walls it dwells in; however, it does not concur with the known





**Figure 5 (A and B):** Digital subtraction angiography picture (A) showing the hypertrophied tortuous left bronchial artery arising from the arch of aorta that was embolized. Computed tomography image (B) taken on 2 weeks follow-up demonstrating a clear cavity devoid of the fungal ball (\*)

pathophysiology of fungal ball that they occur because of absent intact clearing and phagocytosing mechanism within the cavities.

This report of singular observation of fungal ball disappearance, however, is of two isolated events, and embolization as a method of treating aspergilloma cannot be generalized. In fact, such an observation was not made in another case of recurrent hemoptysis with aspergilloma treated with BAE recently in our institution. Further large-scale studies of BAE on aspergilloma are required to substantiate and quantitate such therapeutic effect.

#### Financial support and sponsorship

Nil.

#### Conflict of interest

There are no conflict of interest.

#### References

1. Mohapatra B, Sivakumar P, Bhattacharya S, Dutta S. Surgical

treatment of pulmonary aspergillosis: A single center experience. *Lung India* 2016;33:9-13.

2. Takeda T, Itano H, Kakehashi R, Fukita S, Saitoh M, Takeda S. Direct transbronchial administration of liposomal amphotericin B into a pulmonary aspergilloma. *Respir Med Case Rep* 2014;11:7-11.
3. Rafferty P, Biggs BA, Crompton GK, Grant IW. What happens to patients with pulmonary aspergilloma? Analysis of 23 cases. *Thorax* 1983;38:579-83.
4. Hwang HG, Lee HS, Choi JS, Seo KH, Kim YH, Na JO. Risk factors influencing rebleeding after bronchial artery embolization on the management of hemoptysis associated with pulmonary tuberculosis. *Tuberc Respir Dis* 2013;74:111-9.
5. Chen J, Chen LA, Liang ZX, Li CS, Tian Q, Yang Z, *et al*. Immediate and long-term results of bronchial artery embolization for hemoptysis due to benign versus malignant pulmonary diseases. *Am J Med Sci* 2014;348:204-9.
6. Kato A, Kudo S, Matsumoto K, Fukahori T, Shimizu T, Uchino A, *et al*. Bronchial artery embolization for hemoptysis due to benign diseases: Immediate and long-term results. *Cardiovasc Intervent Radiol* 2000;23:351-7.
7. Mal H, Rullon I, Mellot F, Brugière O, Sleiman C, Menu Y, *et al*. Immediate and long-term results of bronchial artery embolization for life-threatening hemoptysis. *Chest* 1999;115:996-1001.
8. Yoon W, Kim JK, Kim YH, Chung TW, Kang HK. Bronchial and nonbronchial systemic artery embolization for life-threatening hemoptysis: A comprehensive review. *Radiographics* 2002;22:1395-409.
9. Hammerman KJ, Christianson CS, Huntington I, Hurst GA, Zelman M, Tosh FE. Spontaneous lysis of aspergillomata. *Chest* 1973;64:679-9.
10. Aspergilloma and residual tuberculous cavities - The results of a resurvey. *Tubercle* 1970;51:227-45.
11. El Hammoumi MM, Slaoui O, El Oueriachi F, Kabiri el H. Lung resection in pulmonary aspergilloma: Experience of a Moroccan center. *BMC Surg* 2015;15:114.
12. Kravitz JN, Berry MW, Schabel SI, Judson MA. A modern series of percutaneous intracavitary instillation of amphotericin B for the treatment of severe hemoptysis from pulmonary aspergilloma. *Chest* 2013;143:1414-21.
13. Sapienza LG, Gomes MJ, Maliska C, Norberg AN. Hemoptysis due to fungus ball after tuberculosis: A series of 21 cases treated with hemostatic radiotherapy. *BMC Infect Dis* 2015;15:546.