

ORIGINAL ARTICLE

Comparative study on the microbiological features of angular cheilitis in HIV seropositive and HIV seronegative patients from South India

P Anitha Krishnan, Ranganathan Kannan¹

Department of Oral and Maxillofacial Pathology, College of Dentistry, Salman Bin Abdulaziz University, Al-Kharj, Kingdom of Saudi Arabia,

¹Oral and Maxillofacial Pathology, Ragas Dental College and Hospital, Chennai, India

Address for correspondence:

Dr. P Anitha Krishnan,
Department of Oral and Maxillofacial Pathology,
College of Dentistry, Salman Bin Abdulaziz
University, P. O. Box. No: 153, Al-Kharj 11942,
Kingdom of Saudi Arabia.
E-mail: anithakrishnan@mail.com

ABSTRACT

Objective: This study was designed to compare the microbiological features of angular cheilitis (AC) in human immunodeficiency virus (HIV) seropositive and HIV seronegative individuals, in a group of south Indians. **Materials and Methods:** Swabs from oral commissures of 46 patients were obtained and inoculated on to Sabouraud's dextrose agar (SDA) supplemented with chloramphenicol, blood agar (BA) and MacConkey's agar (MCA) plates and cultured. α -hemolytic Streptococci, *Staphylococcus albus*, *Staphylococcus aureus*, *Candida* species, *Klebsiella* species and *Pseudomonas* species were cultured. Candidal colonies were further speciated by the conventional biotyping technique. **Results:** In AC of HIV seropositive patients *Candida albicans* and *Staphylococcus aureus* were more prevalent than that in HIV seronegative patients. Incidentally in patients with CD4 cell count less than 200 there was an increase in the incidence of Candidal and *Staphylococcus aureus* colonization when compared to patients with CD4 cell count higher than 200. **Conclusion:** The present study suggests a definite difference in the microbial flora of AC in HIV seropositive patients than that of HIV seronegative population.

Key words: Angular cheilitis, candida, HIV infection, pseudomonas, South India

INTRODUCTION

Angular cheilitis (AC) also known as angular stomatitis, perlèche (from the French term poulèche (to lick one's lips)) is a relatively common lesion characterized by erythema, maceration, ulceration and crusting at the commissures of the mouth. Factors that create a chronic, conducive, moist environment for microbial growth at the oral commissures such as habitual lip licking, thumb sucking or biting the corners of the mouth and sagging of tissues at the angles of the mouth contribute to the development of AC.^[1] Iron and vitamin deficiencies, consumption of carbohydrate-rich diets, long-term drug therapy such as

immunosuppressants and antibiotics, gastrointestinal disorders, immunodeficiency status such as human immunodeficiency virus (HIV) infection are a few among a plethora of factors that predispose to the lesion.^[2] AC has been included in the classification and diagnostic criteria for oral lesions in HIV infection.^[3] Although AC may not be observed very frequently during HIV disease, it is somewhat strongly associated with HIV infection.^[4] Despite AC being a part of numerous studies on oral manifestations/oral lesions of HIV infection, there are limited studies that probed exclusively into the infective cause of AC in the HIV seropositive individuals and compared the same with that of the HIV seronegative population.

This study was designed with the objective of investigating the infective etiology of AC in HIV seropositive patients and make comparisons with that of HIV seronegative patients. Parameters such as CD4 cell count and serum hemoglobin (Hb) level were also taken into account to gather if low CD4 cell count or low serum Hb level predisposed to the differences in the microbial flora of AC.

Access this article online

Quick Response Code:



Website:

www.jomfp.in

DOI:

10.4103/0973-029X.125183

MATERIALS AND METHODS

A total of 46 patients who participated in the study were examined clinically and microbiologically and were categorized into three groups.

Group 1: Comprised of 20 HIV seropositive patients with AC. None of them wore any dentures. The patients from this group were brought in from a HIV/AIDS Research Center in Chennai, South India. The seropositive status of HIV was confirmed by enzyme-linked immunosorbent assay (ELISA) and Western blot tests. A seropositive Western blot was defined by the presence of at least one band corresponding to gag, env and pol gene translates of HIV.

Group 2: Consisted of 16 HIV seronegative patients with clinical AC. None of these patients were denture wearers.

Group 3: Acted as the control group and included 10 HIV seronegative patients with no clinical evidence of AC.

The diagnosis of AC in Groups 1 and 2 was done by clinical examination and the diagnostic criterion of AC was taken as an eroded and/or erythematous nonvesicular lesion radiating from the angle of the mouth^[5] [Figure 1]. The patients belonging to Groups 2 and 3 were selected from those who visited a reputed dental college in Chennai, South India, for routine dental treatment. Consents were taken from the patients prior to the study. The seronegative status of these patients was based purely on exposure history. The patients had no significant medical history.

Swabs from oral commissures were obtained with a sterile cotton wool moistened with sterile distilled water. The swabs were at once inoculated on to Sabouraud's dextrose agar (SDA) supplemented with chloramphenicol, blood agar (BA) and MacConkey's agar (MCA) plates and transferred for culture. The microorganisms cultured in the study were α -hemolytic streptococci, *Staphylococcus albus*, *Staphylococcus aureus*, Candida species, Klebsiella species and Pseudomonas species. SDA supplemented with chloramphenicol was used for the culture of Candida species, BA and MCA for bacterial growth. The inoculated SDA was incubated at 37°C for 48 h, whereas MAC and BA were incubated for 18 h at 37°C. The presence or absence of bacteria and Candida was confirmed by the growth of colonies on the respective agar plates [Figures 2 and 3]. Bacterial colonies of *Staphylococcus aureus* had a characteristic "oil-paint" appearance on BA and small, pink, circular appearance on MCA. Biochemically, *Staphylococcus aureus* showed catalase and coagulase positive characteristics. Streptococcus formed small, circular, semitransparent colonies with a zone of clear hemolysis around them and fermented sugars like sorbitol, lactose, maltose, mannitol and trehalose with production of acid but no gas and biochemically were catalase negative. Candida showed characteristic creamy white colonies on SDA which was further speciated by conventional

biotyping. Biotyping is the identification of candida species based on their biochemical abilities to ferment and assimilate sugars, produce germ tubes and form chlamydospores.

In addition, the HIV seropositive patients were serologically tested for CD4 cell counts and serum Hb levels and HIV seronegative patients for serum Hb levels. Chi-square test was used to arrive at statistical significance, if any. A $P < 0.05$ was considered statistically significant.

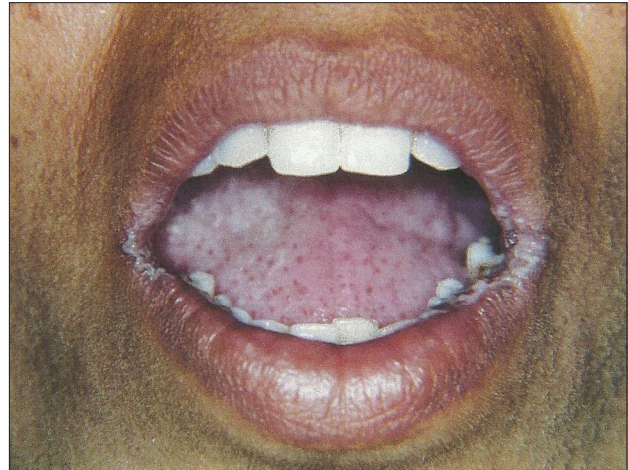


Figure 1: Bilateral angular cheilitis

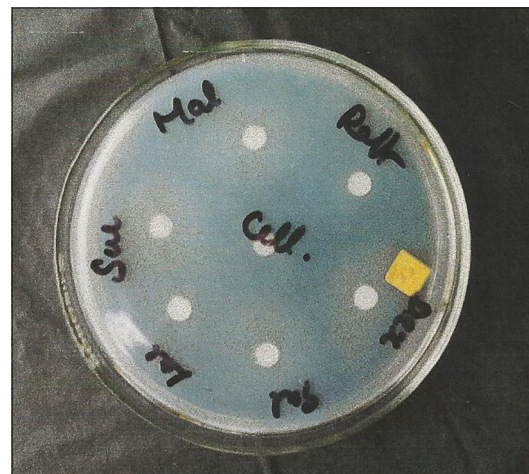


Figure 2: Candidal colonies on Sabouraud's dextrose agar

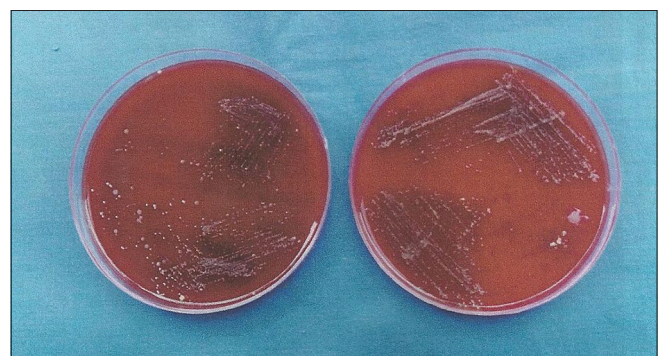

Figure 3: Aerobic colonies on MacConkey's and blood agar plates

RESULTS

The α -hemolytic Streptococcus was isolated from all the 46 patients of the study (100%), regardless of their HIV status/presence or absence of AC.

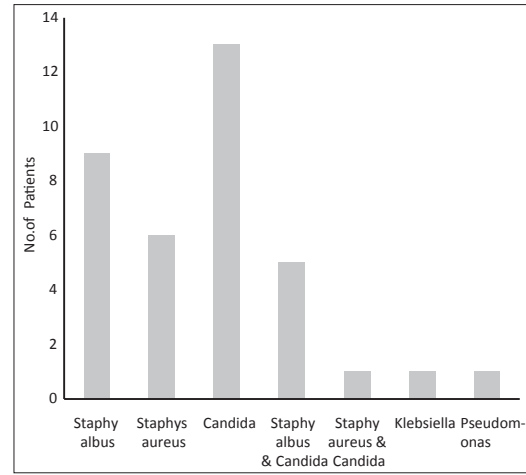
Group 1

The male:female ratio of this group was 7:3. The age group of these patients ranged from 16 to 55 years. *Staphylococcus albus* was isolated from 45% of the patients. *Staphylococcus aureus* was isolated from 30% of the patients. Candida species was isolated from 65% of patients. Twenty-five percent of the patients showed mixed infection with *Staphylococcus albus* and Candida species. Mixed flora of *Staphylococcus aureus* and Candida species was seen in 5% of the patients [Graph 1]. Among the nine HIV seropositive patients who had CD4 cell count ≤ 200 , *Staphylococcus albus* was isolated from 56% and *Staphylococcus aureus* was isolated from 45% of them. Candida species was isolated from 67% of the patients. About 45% of the patients showed mixed flora of *Staphylococcus albus* and Candida species. Eleven percent of the patients showed mixed flora of *Staphylococcus aureus* and Candida species. Three patients had mixed flora of *Staphylococcus albus* and *Staphylococcus aureus*. One patient with CD4 cell count of 84 showed colonization of *Staphylococcus albus*, *Staphylococcus aureus* and Candida species. Klebsiella species was isolated from a patient with CD4 cell count of 111 and Pseudomonas species colonies was found in one with CD4 cell count of 132. In patients with CD4 cell count of more than 200, *Staphylococcus albus* was isolated from 36%, *Staphylococcus aureus* was isolated from only 9%, while Candida species was isolated from 55% of them. Mixed infection of *Staphylococcus albus* and Candida species was found in 9% of the patients. None of them showed mixed flora of *Staphylococcus aureus* and Candida species [Graph 2].

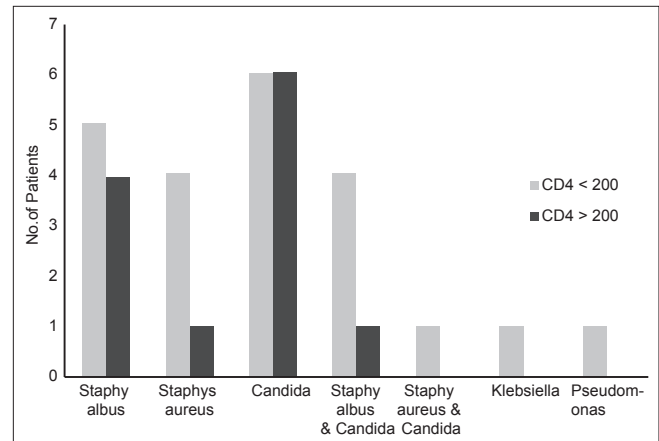
Also from this group, in patients with Hb less than 14 g/dL, *Staphylococcus albus* was isolated from 43%, *Staphylococcus aureus* from 29% and Candida species from 64% of the patients. Mixed flora of *Staphylococcus albus* and Candida species was seen in 29% of the patients. Mixed flora of *Staphylococcus aureus* and Candida species was seen in 7% of the patients. In patients with Hb more than 14 g/dL, *Staphylococcus albus* was isolated from 33%, *Staphylococcus aureus* from 17% and Candida species from 67% of the patients. Mixed flora of *Staphylococcus albus* and Candida species was seen in 17% of the patients. Mixed flora of *Staphylococcus aureus* and Candida species was not observed in these patients [Graph 3].

Group 2

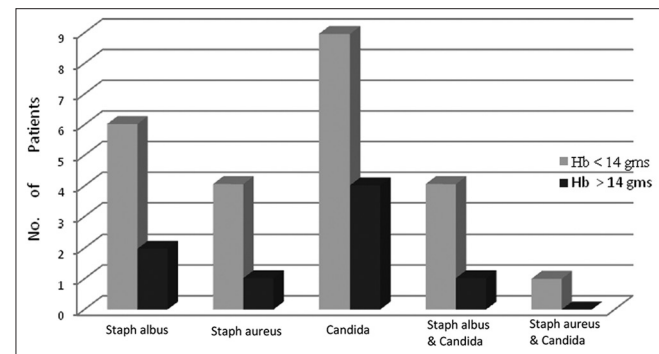
The male:female ratio of this group was 5:3. The age group of these patients ranged from 18 to 50 years. *Staphylococcus albus* was isolated from 69%, *Staphylococcus aureus* from 13% and



Graph 1: Microbiology of angular cheilitis in 20 HIV seropositive patients. Staph albus: *Staphylococcus albus*, Staph aureus: *Staphylococcus aureus*, HIV: human immunodeficiency virus



Graph 2: Comparative microbiology of angular cheilitis in nine HIV seropositive patients with CD4 ≤ 200 and 11 HIV seropositive patients with CD4 > 200 . Staph albus: *Staphylococcus albus*, Staph aureus: *Staphylococcus aureus*, CD4: CD4 cell count, HIV: human immunodeficiency virus



Graph 3: Comparative microbiology of angular cheilitis in 14 HIV seropositive patients with hemoglobin ≤ 14 g/dL and six HIV seropositive patients with hemoglobin > 14 g/dL. Staph albus: *Staphylococcus albus*, Staph aureus: *Staphylococcus aureus*, Hb: hemoglobin, HIV: human immunodeficiency virus

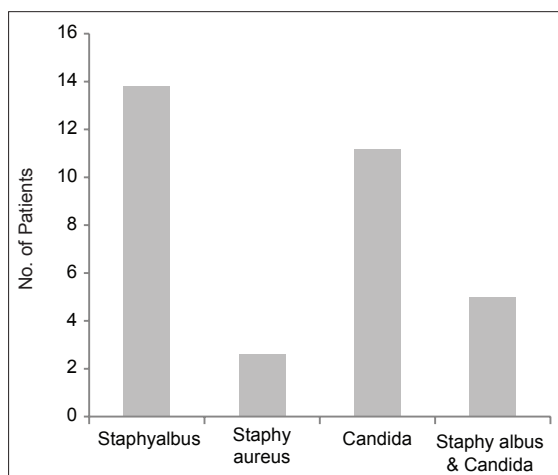
Candida species from 56% of the patients. Twenty-five percent of the patients showed mixed flora of *Staphylococcus albus* and *Candida* species. None of the patients showed mixed flora with *Staphylococcus aureus* and *Candida* species. In this group, patients with Hb less than 14 g/dL, *Staphylococcus albus* was isolated from 70%, *Staphylococcus aureus* from 20% and *Candida* species from 60% of the patients. Mixed flora of *Staphylococcus albus* and *Candida* species were seen in 30% of the patients. In patients with Hb more than 14 g/dL, *Staphylococcus albus* was isolated from 50% and *Candida* species was from 50% of the patients. *Staphylococcus aureus* was not isolated from any of the patients. Mixed flora of *Staphylococcus albus* and *Candida* species was seen in 17% of the patients [Graph 4].

Group 3

Staphylococcus albus was isolated from 70% of the patients in this group. No other microorganisms were isolated from the oral commissures of this group and hence there was no mixed flora found. However, in those with Hb less than 14 g/dL, *Staphylococcus albus* was isolated from 71% of the patients; while in patients with Hb more than 14 g/dL, *Staphylococcus albus* was isolated from 67% of the patients.

DISCUSSION

AC has been investigated predominantly in the western world, with a few exceptions in the Asian continent.^[6,7] In HIV infection, the importance of oral lesions has been widely studied and all HIV seropositive patients are susceptible to oral lesions at some point of their illness.^[8] Oral lesions occur in about 64% cases of HIV/acquired immunodeficiency syndrome (AIDS) in India^[9,10] and have a prevalence of 56% in the West.^[11] Some opportunistic oral infections can not only be indicators of the onset of HIV infection and present as early clinical features, but also as progressive markers of HIV infection to full blown AIDS.^[12] The most common HIV-related



Graph 4: Microbiology of angular cheilitis in 16 HIV seronegative patients. Staph albus: *Staphylococcus albus*, Staph aureus: *Staphylococcus aureus*, HIV: human immunodeficiency virus

oral disorder reported so far is oral candidiasis which occurs in 17-43% cases with HIV infection and in more than 90% of cases with AIDS.^[13] The classification and diagnostic criteria for oral lesions in HIV infection proposed in 1993 stated that AC can be associated with *Candida albicans* and may be seen in dentate patients with HIV infection.^[3] Studies have shown that AC can be caused by *Candida albicans* alone (20%), mixed infection with *Candida* and *Staphylococcus aureus* (60%) and *Staphylococcus aureus* alone (20%).^[14]

From our present study we found that in HIV seropositive patients with AC (Group 1) *Candida albicans* (65%) and *Staphylococcus aureus* (30%) were more prevalent. Incidentally when the CD4 cell count dropped below 200, there was an increase in the incidence of mixed flora of *Candida* and *Staphylococcus aureus* when compared to patients with CD4 cell count of higher than 200. Those with Hb value of less than 14 g/dL showed an increase in the candidal and staphylococcal colonization. Group 1 patients also had 24% less incidence of *Staphylococcus albus* and 17% more incidence of *Staphylococcus aureus* colonization when compared with that of group 2 population.

On the other hand, in HIV seronegative patients with AC (Group 2) there was a prevalence of *Staphylococcus albus* (86%) in the lesions, followed by *Candida albicans* (70%). *Staphylococcus aureus* was found only in 16% of the cases. Also those with Hb value of less than 14 g/dL showed an increase in the incidence of *Candida albicans* and *Staphylococcus aureus* when compared to patients with Hb value of more than 14 g/dL.

In Group 3 patients, *Candida* species and *Staphylococcus aureus* were not isolated from the oral commissures regardless of their Hb status. This is concomitant with earlier studies which have suggested that the isolation of *Staphylococcus aureus* and *Candida* species from the oral commissures may be of pathogenic significance.^[7]

There was a general trend of increase in the incidence of *Candida albicans* and *Staphylococcus aureus* colonization in patients with Hb value less of than 14 g/dL albeit the HIV status. This suggests that a reduced Hb level could predispose to candidal and pathogenic bacterial colonization in AC irrespective of the HIV status.

The data from our study points to a distinctive microbial flora in AC, which, in the HIV seropositive patients is probably influenced by their immunosuppression (as ascertained by the CD4 cell count) and Hb level in both HIV seropositive and HIV seronegative population.

CONCLUSION

AC can be painful and can persist sometimes for years in some individuals. This can be frustrating especially for the

immunocompromised patients. The clinical implication and objective of identifying the precise infective etiology through microbiological analyses would be to employ appropriate antimicrobial therapy tailored to its causative agent which would help in hastening the healing process. Angular stomatitic lesions that are refractory to treatment or chronically recurring in non-denture wearers should prompt evaluation for HIV infection or other immunocompromised conditions. From our study we conclude that there is a distinctive difference in the microbial flora of AC in HIV seropositive patients when compared with that in HIV seronegative population. There have not been studies with similar designs from south India so far. However, to confirm these differences statistically, a study with a larger cohort and analysis of the colony forming units (CFU) need to be carried out.

ACKNOWLEDGMENT

We sincerely wish to thank Dr. Thangam Menon, PhD and Dr. Uma Maheshwari, PhD, Department of Microbiology, PG Institute of Basic Medical Sciences, University of Madras, for their assistance in culturing and identifying the isolates reported in this paper.

REFERENCES

1. Appleton SS. Candidiasis: Pathogenesis, clinical characteristics and treatment. *J Calif Dent Assoc* 2000;28:942-8.
2. Samaranayake LP, Cheung KL, Samaranayake YH. Candidiasis and other fungal diseases of the mouth. *Dermatol Ther* 2002;15:251-69.
3. Williams DM. Classification and diagnostic criteria for oral lesions in HIV infection-EC clearing house and WHO collaborating center in oral manifestation of human immunodeficiency virus (HIV) infection, Copenhagen Denmark. *J Oral Pathol Med* 1993;22:289-91.
4. Pindborg JJ. Classification of oral lesions associated with HIV infection. *Oral Surg Oral Med Oral Pathol* 1989;67:292-5.
5. MacFarlane TW, Helnarska SJ. The microbiology of angular cheilitis. *Br Dent J* 1976;140:403-6.
6. Warnakulasuriya KA, Samaranayake LP, Peiris JS. Angular cheilitis in a group of Sri Lankan adults: A clinical and microbiologic study. *J Oral Pathol Med* 1991;20:172-5.
7. Dias AP, Samaranayake LP. Clinical, microbiological and ultrastructural features of angular cheilitis lesions in Southern Chinese. *Oral Dis* 1995;1:43-8.
8. Arendorf T, Holmes H. Oral manifestations associated with human immunodeficiency virus (HIV) infection in developing countries-are there differences from developed countries? *Oral Dis* 2000;6:133-5.
9. Anil S, Challacombe SJ. Oral lesions of HIV and AIDS in Asia: An overview. *Oral Diseases* 1997;3:S36-40.
10. Ranganathan K, Reddy BV, Kumarasamy N, Solomon S, Viswanathan R, Johnson NW. Oral lesions and conditions associated with human immunodeficiency virus infection in 300 south Indian patients. *Oral Dis* 2000;6:152-7.
11. Schmidt-Westhausen A, Grünwald T, Reichart PA, Pohle HD. Oral manifestations in 70 German HIV-infected women. *Oral Dis* 1997;3:S28-30.
12. Coogan MM, Greenspan J, Challacombe SJ. Oral lesions in infection with human immunodeficiency virus. *Bull World Health Organ* 2005;83:700-6.
13. Lamster IB, Begg MD, Mitchell-Lewis D, Fine JB, Grbic JT, Todak GG, *et al.* Oral manifestations of HIV infection in homosexual men and intravenous drug users. Study design and relationship of epidemiologic, clinical and immunologic parameters to oral lesions. *Oral Surg Oral Med Oral Pathol* 1994;78:163-74.
14. Neville BW, Damm DD, Allen CM, Bouquot JE. Fungal and protozoal diseases. In: *Oral and Maxillofacial Pathology*. 3rd ed. Philadelphia: WB Saunders; 2009. p. 192.

How to cite this article: Krishnan PA, Kannan R. Comparative study on the microbiological features of angular cheilitis in HIV seropositive and HIV seronegative patients from South India. *J Oral Maxillofac Pathol* 2013;17:346-50.

Source of Support: Nil. **Conflict of Interest:** None declared.

Staying in touch with the journal

1) Table of Contents (TOC) email alert

Receive an email alert containing the TOC when a new complete issue of the journal is made available online. To register for TOC alerts go to www.jomfp.in/signup.asp.

2) RSS feeds

Really Simple Syndication (RSS) helps you to get alerts on new publication right on your desktop without going to the journal's website. You need a software (e.g. RSSReader, Feed Demon, FeedReader, My Yahoo!, NewsGator and NewzCrawler) to get advantage of this tool. RSS feeds can also be read through FireFox or Microsoft Outlook 2007. Once any of these small (and mostly free) software is installed, add www.jomfp.in/rssfeed.asp as one of the feeds.