

CASE REPORT

Local recurrence of pheochromocytoma in multiple endocrine neoplasia type 2A: a diagnostic and therapeutic challenge

Blandine Tramunt¹, Alexandre Buffet¹, Solange Grunenwald¹, Delphine Vezzosi¹, Antoine Bennet¹, Eric Huyghe², Slimane Zerdoud³ & Philippe Caron¹

¹Service d'Endocrinologie et Maladies Métaboliques, Pôle Cardio-Vasculaire et Métabolique, CHU Larrey, Toulouse, France

²Service d'Urologie, Andrologie et Transplantation Rénale, CHU Rangueil, Toulouse, France

³Service de Médecine Nucléaire, Institut Universitaire du Cancer, Oncopole, Toulouse, France

Correspondence

Philippe Caron, Service d'Endocrinologie et Maladies Métaboliques, CHU Rangueil-Larrey, 24 chemin de Pouvoirville, TSA 30030, 31059 Toulouse Cedex 9, France.
Tel: +33 5 67 77 17 01;
Fax: +33 5 67 77 16 72;
E-mail: caron.p@chu-toulouse.fr

Funding Information

No sources of funding were declared for this study.

Received: 11 August 2015; Revised: 1 November 2015; Accepted: 30 December 2015

Clinical Case Reports 2016; 4(3): 298–300

doi: 10.1002/ccr3.498

Multiple endocrine neoplasia type 2A (MEN2A) is an autosomal dominant syndrome with a strong genotype–phenotype relationship, caused by *RET* oncogene mutations. This syndrome comprises medullary thyroid carcinoma (MTC), unilateral or bilateral benign epinephrine-secreting pheochromocytoma, and primary hyperparathyroidism.

Local recurrence of benign pheochromocytoma after adrenalectomy is rare (about 4%) [1] and can be complicated by diffuse dissemination in the adrenal bed with infiltration of adjacent tissues, called pheochromocytomatosis. However, local recurrence is not a well-known phenomenon, and no predictive criteria of recurrence have been identified.

We report local recurrences of pheochromocytoma, consistent with pheochromocytomatosis, in a MEN2A patient who was effectively treated with ¹³¹I MIBG, and in which recurrences could be detected early by an inverted normetanephrine/metanephrine ratio.

Key Clinical Message

In a patient with multiple endocrine neoplasia type 2A (MEN2A), an inverted physiological ratio between urinary normetanephrines and metanephrines is an early marker of recurrence in epinephrine-secreting pheochromocytoma, and ¹³¹I MIBG treatment appears to be a useful therapeutic option in order to avoid multiple invasive surgical procedures in pheochromocytomatosis.

Keywords

¹³¹I-MIBG therapy, MEN2A, pheochromocytoma, recurrence, surgery.

Case

A 33-year-old man was diagnosed with multiple endocrine neoplasia type 2A at the age of 18 in 1999 during a family survey. A p.Cys634Arg mutation on the *RET* gene was identified.

The patient complained of headaches and palpitations but did not have hypertension. The initial assessment showed a calcitonin level of 26 pg/mL (normal <8) and a positive pentagastrin calcitonin stimulation test (peak at 5 min, 291 pg/mL). Urinary normetanephrine (4325 µg/day, normal <600) and metanephrine levels were increased (4011 µg/day, normal <350). An adrenal MRI scan revealed a 6-cm heterogenous left adrenal mass (Fig. 1). The right adrenal gland was normal. The patient underwent left total adrenalectomy by retroperitoneal laparoscopy. No complication occurred during or after the procedure and in particular no peroperative tumor

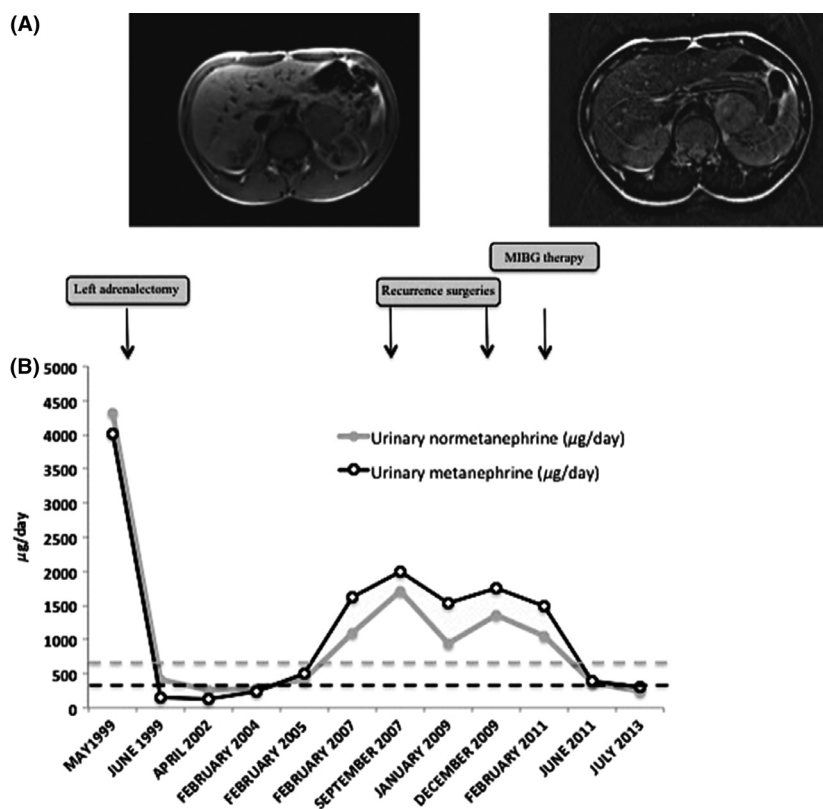


Figure 1. A: Abdominal MRI on T1 (left) and T2 (right) sequence of the initial pheochromocytoma. B: 24-hour urinary metanephrine and normetanephrine levels during follow-up of the MEN 2A patient; upper limits of the normal range of metanephrine and normetanephrine levels are in dotted lines.

fragmentation. Histology confirmed a 6.5-cm pheochromocytoma with numerous hemorrhagic fields without any necrosis. The MIB-1 (nuclear proliferation) was <2%, and resection was R0. After left adrenalectomy, total thyroidectomy and lymph node dissection were performed. Two bilateral micro-MTC without metastatic lymph nodes were found.

Between 1999 and 2004, no clinical, biochemical, or radiological evidence of recurrent pheochromocytoma or MTC was observed. In 2004, urinary metanephrine levels increased but remained in the normal range, whereas urinary normetanephrine levels remained identical (Fig. 1). In 2005, urinary metanephrine and normetanephrine levels increased and metanephrine levels exceeded at that time the normal range (498 µg/day, normal <350), whereas the patient was asymptomatic and his abdominal CT scan was normal.

In 2007, urinary metanephrine and normetanephrine levels increased significantly to 1588 µg/day and 1140 µg/day, respectively. Abdominal CT and MRI scans showed a homogenous mass of 26 mm in the left adrenalectomy bed. Scintigraphy showed MIBG uptake only in the left adrenal bed.

The patient underwent a second surgical procedure in October 2007. The procedure was initiated as retroperitoneal laparoscopy and then converted to laparotomy. After dissection, a multinodular tumor (5 × 3 × 1 cm) was removed and histological analysis showed multiple clusters of pheochromocytoma cells which infiltrated sympathetic nodes and adipose tissue.

A new assessment 2 years later revealed a persistent increase in urinary metanephrine and normetanephrine levels and MIBG uptake in the left adrenalectomy bed. It was noteworthy that the patient was asymptomatic and no abnormal image was found on MRI. At that time, the patient declined further surgery.

Finally, the patient had a third surgical procedure in 2011. Laparotomy with large excision of all tissues which appeared to be invaded on intraoperative macroscopic examination by pheochromocytomatosis was performed. Microscopic examination showed pheochromocytomatosis with infiltration of all tissues by pheochromocytoma cells. After this surgery, urinary normetanephrine level became normal. The metanephrine level was at the upper limit of the normal range.

Three months later, because of persistent increased urinary metanephrine level and persistent abnormal MIBG uptake, the patient was given MIBG treatment. He received three doses of 150 mCi of ^{131}I MIBG between August 2011 and March 2012. Since the last administration and during these last 3 years, all investigations have shown normal urinary metanephrine levels, absence of abnormal MIBG uptake, and no radiological recurrence on CT scan.

Discussion

The biochemical diagnosis of pheochromocytoma is based on plasma-free metanephrines or urinary fractionated metanephrines. Physiologically, normetanephrine levels are more elevated than metanephrine levels. In MEN2 patients with pheochromocytomas, there is a mixed excretion of metanephrine and normetanephrine with higher excretion of metanephrine [2]. Furthermore, Amar *et al.* reported that increased urinary metanephrine levels above the limit of the normal is the earliest marker of pheochromocytoma recurrence. According to these authors, all recurrences could be detected before occurrence of the first symptoms on the basis of an increase in metanephrine levels [3]. This observation could suggest a larger gap between normetanephrine and metanephrine levels after adrenalectomy, increasing the physiological ratio. Our patient presented with an inverted ratio between normetanephrines and metanephrines (higher metanephrines than normetanephrines) at the time of recurrence. This inverted ratio preceded the morphological diagnosis of recurrence. This observation suggests that an inverted normetanephrine/metanephrine ratio could thus be the earliest marker of recurrence in MEN2 pheochromocytoma. This inverted ratio has to be validated on a larger cohort of patients.

On the other hand, ^{131}I -MIBG therapy was administered after three unsuccessful surgical procedures. In the literature, few patients with pheochromocytomatosis had MIBG therapy. Recently, five cases of peritoneal implantation of pheochromocytoma after tumor spillage during the first operation were reported [4]. In three cases, the recurrences were treated by the combination of surgical debulking and MIBG therapy: disease stability was obtained in one case and two other patients died from tumor progression after 9 and 10 years. Moreover, grades 3–4 renal and hematological toxicities of this

treatment are estimated at <5% and 10%, respectively. However, long-term follow-up revealed leukemia in about 5% of patients [5]. In our patient, MIBG therapy led to recurrence-free follow-up without short-term or long-term side effects. In MEN2A patients with pheochromocytomatosis, the combination of surgical debulking and MIBG therapy could thus be a strategy to avoid multiple invasive surgeries.

Conclusion

We report a case of pheochromocytomatosis in a MEN2A patient after laparoscopic adrenalectomy without capsular disruption. An inverted ratio between metanephrine and normetanephrine levels preceded morphological recurrence, and follow-up was disease free after surgical debulking and ^{131}I MIBG therapy.

Conflict of Interest

None declared.

References

1. Castinetti, F., X. P. Qi, M. K. Walz, A. L. Maia, G. Sansó, M. Peczkowska, *et al.* 2014. Outcomes of adrenal-sparing surgery or total adrenalectomy in pheochromocytoma associated with multiple endocrine neoplasia type 2: an international retrospective population-based study. *Lancet Oncol.* 15:648–655.
2. Eisenhofer, G., J. W. Lenders, H. Timmers, M. Manelli, S. K. Grebe, L. C. Hofbauer, *et al.* 2011. Measurements of plasma methoxytyramine, normetanephrine, and metanephrine as discriminators of different hereditary forms of pheochromocytoma. *Clin. Chem.* 57:411–420.
3. Amar, L., S. Peyrard, P. Rossignol, F. Zinzindohoue, A. P. Gimenez-Roqueplo, P. F. Plouin. 2006. Changes in urinary total metanephrine excretion in recurrent and malignant pheochromocytomas and secreting paragangliomas. *Ann. N. Y. Acad. Sci.* 1073:383–391.
4. Rafat, C., F. Zinzindohoue, A. Hernigou, C. Hignette, J. Favier, F. Tenenbaum, *et al.* 2014. Peritoneal implantation of pheochromocytoma following tumor capsule rupture during surgery. *J. Clin. Endocrinol. Metab.* 99:2681–2685.
5. Sze, W. C., A. B. Grossman, I. Goddard, D. Amendra, S. C. Shieh, P. N. Plowman, *et al.* 2013. Sequelae and survivorship in patients treated with (131)I-MIBG therapy. *Br. J. Cancer* 109:565–572.