

Neurosurgical Management of Childhood Spasticity: Functional Posterior Rhizotomy and Intrathecal Baclofen Infusion Therapy

Nobuhito MOROTA,¹ Satoshi IHARA,¹ and Hideki OGIWARA²

¹*Division of Neurosurgery, Tokyo Metropolitan Children's Medical Center, Tokyo;*

²*Division of Neurosurgery, National Medical Center for Children and Mothers, National Center for Child Health and Development, Tokyo*

Abstract

A paradigm shift is currently ongoing in the treatment of spasticity in childhood in Japan. Functional posterior rhizotomy (FPR), which was first introduced to Japan in 1996, is best indicated for children with spastic cerebral palsy, regardless of the clinical severity of spasticity. Surgery is generally carried out in the cauda equina, where the posterior root is separated from the anterior one, and neurophysiological procedures are used to judge which nerve root/rootlet should be cut. The outcome of FPR is favorable for reducing spasticity in the long-term follow-up. Intrathecal baclofen (ITB) treatment for childhood spasticity was approved in 2007 in Japan and the number of children undergoing ITB pump implantation has been gradually increasing. ITB treatment is best indicated for children with severe spasticity, especially those with dystonia, regardless of the pathological background. Since it is a surgery performed to implant foreign bodies, special attention should be paid to avoid perioperative complications such as CSF leakage, meningitis, and mechanical failure. Severely disabled children with spasticity would benefit most from ITB treatment. We would especially like to emphasize the importance of a strategic approach to the treatment of childhood spasticity. The first step is to reduce spasticity by FPR, ITB, and botulinum toxin injection. The second step is to aim for functional improvement after controlling spasticity. Traditional orthopedic surgery and neuro-rehabilitation form the second step of treatment. The combination of these treatments that allows them to complement each other is the key to a successful treatment of childhood spasticity.

Key words: rhizotomy, baclofen, spasticity, cerebral palsy, surgery

Introduction

The management of spasticity plays an important role for children who have suffered damage to the central nervous system (CNS) early in life. Various conditions and pathophysiologies contribute to the development of spasticity, which greatly impacts the daily life of patients and requires family support.¹⁾ Spasticity causes a negative cycle of pain, which in turn worsens the spasticity. The treatment of spasticity can bring great benefits to children, since spasticity is a secondary pathology based on an irreversibly damaged CNS.^{2–4)}

In Japan, the treatment of spasticity has shown dynamic changes during the last 10 years. Spasticity itself had long been regarded as an incurable condition, and only neuro-rehabilitation and orthopedic surgery were performed for the secondary motor

disability caused by spasticity. The introduction of functional posterior rhizotomy (FPR) in 1996, intrathecal baclofen (ITB) infusion treatment for children in 2007, and botulinum toxin (BTX) injection for leg spasticity in 2010 helped to bring about global standards for the treatment of spasticity.^{5–7)} On the other hand, there seems to be some confusion regarding which treatment should be selected or how to combine these treatments.^{8–11)}

In this review, we describe the surgical procedure of FPR and implantation of an ITB pump and discuss the comprehensive management of spasticity in childhood.

FPR

FPR is a surgery performed to reduce spasticity, predominantly for children with spastic cerebral palsy. The history of FPR for the treatment of spasticity dates to the early 20th century, when a German

neurologist first applied it to reduce hypertonia.¹²⁾ FPR in its modern form, comprising the cutting of rootlets under intraoperative neurophysiological monitoring, was first introduced to Japan in 1996.¹³⁾

The surgical procedure for FPR is divided into two stages. The original surgical procedure in the modern era was advocated by Fasano, who carried out lesioning at the level of the conus medullaris^{14,15)} (Fig. 1). Park et al. built on Fasano's procedure with more sophistication using intraoperative ultrasonography.^{16,17)} Peacock et al. proposed performing the surgery at the cauda equina in the 1980s.^{18,19)} A shift of the surgical field made the procedure safer and more reliable, since identification of the level of each root became more precise. The standard Peacock's procedure consists of L1–L5 laminotomy and laminectomy below S1, down to the caudal end of the dural sac. If the spasticity is predominantly localized in the ankle joint, the standard Peacock's procedure is modified to shorten the skin incision.²⁰⁾ Namely, in this limited procedure, the skin is opened from the L3 to L5 laminae and below. We adopted Peacock's procedure, because precise localization of the nerve root and precise intraoperative neurophysiology were regarded to be essential for functional surgery to obtain a better surgical outcome.⁵⁾

I. Goal of surgery

It is essential to share the goal(s) of surgery with the family before surgery.^{3,21)} In general, the goal of surgery for severely disabled children with spasticity

is to relieve pain, make daily support easier, and decrease the physical and psychological burden on the family.²²⁾ For children who can walk with or without support, the goal of surgery is improved motor function and a better quality of joint motion.

It should be kept in mind that FPR may decrease spasticity, but it does not necessarily lead to improved motor function. In order to achieve motor development, multiple factors, such as orthopedic complications, the intelligence of the child, the child's age, and the intensity of physical exercise can all affect the outcome. A reduction of spasticity is the first step to reach the goal of surgery.⁵⁾

II. Surgical indications

Children with spastic para- or quadriparesis are candidates for FPR.^{3,5,21)} Any level of spasticity [Gross Motor Function Classification Scale (GMFCS) level 1 to 5] can be treated by FPR. The lower limit of age is 30 months, and there is no definite upper limit of age, but an age younger than 10 years is considered to be more favorable for surgery. Associated dystonia in highly disabled children can be managed by FPR.²²⁾ However, if the dystonia is severe and in an advanced stage, ITB therapy should be selected.²³⁾ Patients with athetotic cerebral palsy are excluded from FPR, because reduced spasticity can aggravate involuntary movements due to the athetosis. Older children who can walk need careful evaluation to determine whether FPR is indicated,

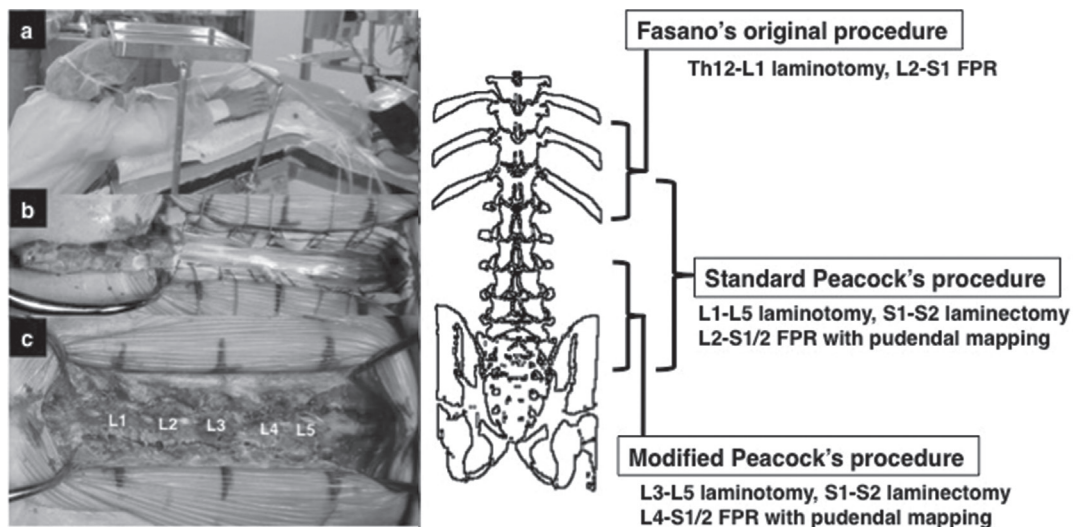


Fig. 1 FPR. a: Position of the patient. A physical therapist simulates the intraoperative position to detect muscle contraction before the preparation of the patient. b: Osteoplastic laminotomy. The lamina flap is flipped to the rostral side. c: Laminoplasty after FPR. The L1–L5 laminae are placed back at their original positions. **Right:** Surgical procedures for FPR. Among 181 FPR cases, Fasano's original procedure was performed in 1 case, the standard Peacock's procedure was performed in 138 cases, and the modified Peacock's procedure was performed in 42 cases. FPR: functional posterior rhizotomy.

because a reduction of the spasticity may lead to a deterioration of the motor function.²⁴⁾

Preoperative Evaluation

Precise functional and surgical evaluations are required before surgery.

1. Functional evaluation

Functional classification: GMFCS²⁵⁾

Motor function: Gross Motor Function Measurement (GMFM)²⁶⁾

ADL evaluation: WeeFIM (Functional Independence Measure for Children)²⁷⁾

Degree of spasticity: (modified) Ashworth scale^{28,29)}

2. Surgical evaluation

Computed tomography (CT) to confirm the ossification of the lumbo-sacral laminae. Physiological spina bifida, developmental process common for young children, can be confirmed.

Magnetic resonance imaging (MRI) can predict the adhesion of the cauda equina, which makes surgery difficult because it is tough to isolate each spinal nerve root. The adhesion tends to be present most often in severely disabled children who suffered intracranial hemorrhage during the early neonatal period.⁹⁾

3. Others

We also recommend performing a preoperative neurophysiological evaluation (evoked potentials, F waves, H waves), and an evaluation of the urinary function is also recommended.

Surgical Procedures

As indicated above, the standard surgical procedure for FPR that we have adopted is the Peacock's procedure.^{18,19)} We describe it briefly below⁵⁾:

1. Preparation

A short-acting muscle relaxant is used during intubation. During the surgery, anesthesia is maintained by total intravenous anesthesia (TIVA) so that the anesthetic agents do not disturb the intraoperative neurophysiology. Following the induction of anesthesia, the patient is placed in the prone position with the lumbo-sacral region extended maximally.

2. Skin incision—dural opening

The skin incision is made from the Th12 spinous process to S3. The L1–S2 laminae are exposed in

a subperiosteal fashion. The L1–L5 osteoplastic laminotomy is then carried out. In cases being treated with a limited procedure, the laminotomy is carried out from L3 to L5.²⁰⁾ The lamina flap is removed or inverted to the rostral side, and an S1–S2 laminectomy is added. Hemostasis of the epidural space and the bone edge is performed before dural opening (Fig. 1).

3. Intradural procedure

The dura is opened in the epiarachnoid space. This helps to prevent the nerve root from coming out of the dural opening. The dorsal arachnoid membrane is cut open. The L2–S3 (S3 contains the S3–S5 roots) roots are dissected from others. It should be noted that the arachnoid membrane is thicker at the root exit zone, and sharp dissection is often required. The posterior root is separated from the anterior one at the level from L2 to S2. The S3–S5 roots were left as a bundle (Figs. 2, 3).

4. Intraoperative neurophysiology

Pudendal/anal mapping^{30,31)}: The intraoperative neurophysiological session starts after the root separation. The pudendal/anal mapping is performed first. Each posterior root from S1 to S3(–S5) is mapped for sensory action potentials by a hand-held bipolar recording electrode while the pudendal/anal nerve is stimulated peripherally. The highest pudendal action potential is usually recorded from the S2 posterior root followed by the S3(–S5) root. The parameters for the pudendal/anal mapping are shown in Fig. 4.

Posterior root/rootlet stimulation: The range of lesioning is determined according to the findings of pudendal/anal mapping. The spinal root involving the pudendal afferent fiber is excluded from lesioning. Usually, the L2–S1 posterior roots are tested for FPR. Each root is held by a pair of dissector electrodes. Electrical stimulation of 10 Hz is delivered for 1 second. The muscle contraction is recorded by electromyogram (EMG), as well as reported by palpitation by a physical therapist. When the muscle response is judged to be highly abnormal, the root is further divided into three to six rootlets. The same electrical stimulation is delivered to each rootlet, and the one showing highly abnormal muscle contraction is cut after coagulation. The parameters for the stimulation are shown in Fig. 5.

Decision-making about cutting the rootlet(s): The criteria used for judging the abnormal muscle response are multifactorial. Two major principles are used. The first is the extent of muscle contraction.^{3,15,32–34)} When muscle contraction outside the segmental innervation of the stimulated nerve root/rootlet is

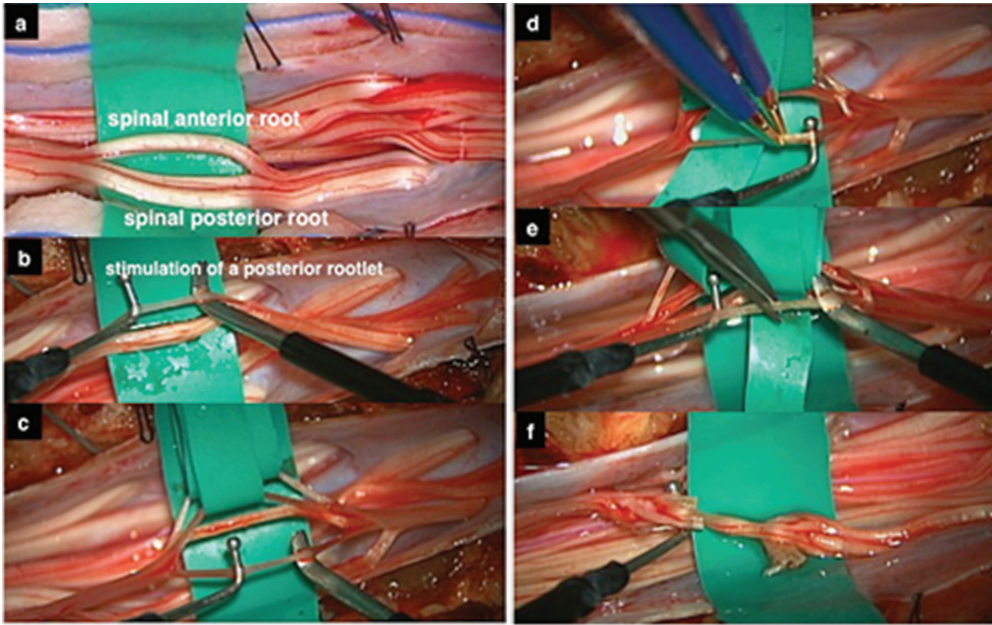


Fig. 2 Functional posterior rhizotomy: The surgical procedures are as follows: a: A spinal posterior root is separated from the anterior root. Note the different color and caliber of each root. b: A posterior root is divided into several rootlets. c: Electrical stimulation of the rootlet. The stimulated rootlet is tentatively wrapped with a rubber sheet. d: When muscle contraction is judged to be highly abnormal after testing all rootlets, the rootlet is coagulated. e: The rootlet is cut. f: The surgical view of the lesioned posterior root.

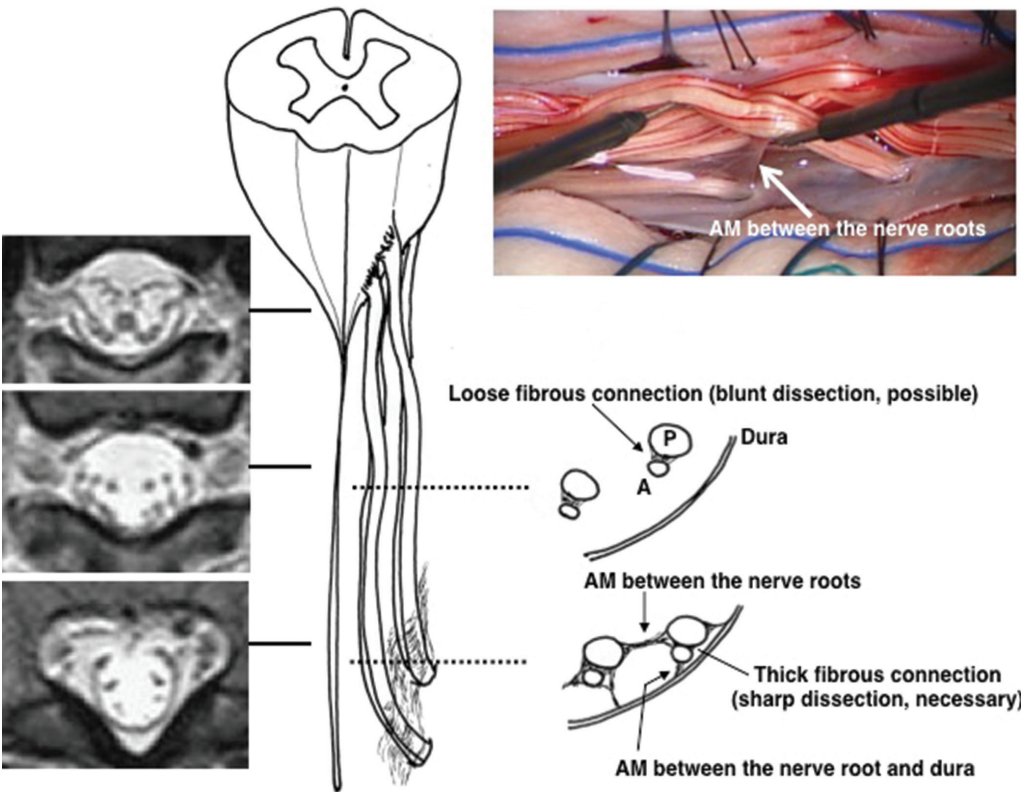


Fig. 3 Relationship of the nerve root with the spinal arachnoid membrane. The spinal anterior root was located on the ventral side of the posterior root. Both roots were connected loosely by fibrous tissue at the mid-portion of the cauda equina. The fibrous connection became thicker and tighter as it approached the root exit/entrance zone. A thick arachnoid membrane had developed between the roots, and between the root and dura. Sharp dissection of the arachnoid membrane at this region was necessary to obtain mobility of the root. A: spinal anterior root, AM: arachnoid membrane, P: spinal posterior root.

present, it is judged to be abnormal. Another criterion measures the loss of central inhibition to judge the abnormality.^{35,36} When the EMG amplitude of the muscle contraction shows no reduction during the 10 Hz stimulation or show increased contraction, it is judged to be abnormal.

Special criteria should be considered prior to reach final decision regarding whether the rootlet should be cut or not,^{3,33,37} as follows:

1. No more than three successive segments are cut 100%. The third segment can be cut up to 50% to prevent sensory loss.




Fig. 4 The posterior root/rootlet stimulation. *Upper:* A photograph showing the electrical stimulation of the left S1 posterior rootlet. *Middle:* The parameters for the posterior root/rootlet stimulation are shown. *Lower:* EMG responses of the root/rootlet stimulation. *a:* Left L4 root stimulation with 1.0 mA. Tiny responses were recorded from the tibialis anterior muscle, and it was judged to be normal. The root was not divided for cutting. *b:* Left L5 root stimulation with 0.4 mA. A robust, but fluctuating, response was recorded from the gastrocnemius muscle. Sustained, but not restricted, responses were recorded from the hamstrings and tibialis anterior muscles. Small responses were also recorded from the quadriceps femoris and adductors muscles, which are not innervated by the L5 root. The response was judged to be highly abnormal, and the root was further divided into rootlets. *c:* A left L5 rootlet stimulation with 0.4 mA. Nearly the same responses were recorded as noted above. The rootlet was judged to be highly abnormal and was cut. Add: adductors, Gas: gastrocnemius, Ham: hamstrings, Quad: quadriceps femoris, TA: tibialis anterior.

2. Total cutting of the S1 posterior root in ambulatory children should be avoided. The maximum cutting rate of S1 in these children should be less than 80%.
3. It is recommended that the L3 and L4 roots be preserved more than 50% for ambulatory children to prevent overstretching of the knee joint.
4. If the patient is an older ambulatory child, the root cutting should be more restricted than that in young children.

Detailed rootlet cuttings of representative cases are shown in Fig. 6.

S1 with pudendal action potentials: Special attention is necessary if the S1 posterior root shows relatively high pudendal afferent action potential.⁶⁾ Because electrical stimulation of the S1 posterior

root often evokes highly abnormal muscle contraction from the gastrocnemius and tibialis anterior muscles, the S1 cutting rate influences the postoperative spasticity of the ankle joint. When the S1 shows a relatively high pudendal potential, the pudendal mapping is repeated for each rootlet, in addition to standard rootlet stimulation. The rootlet that shows a relatively high pudendal action potential is preserved regardless of the results of the electrical stimulation. A representative case is described in Fig. 7.

Closure and postoperative management: Finally, immaculate hemostasis is accomplished, and the dura is closed to ensure that it is water-tight. The muscle is closed in two layers, and the fascia is approximated using a "figure of eight" procedure. The skin is closed layer-by-layer.

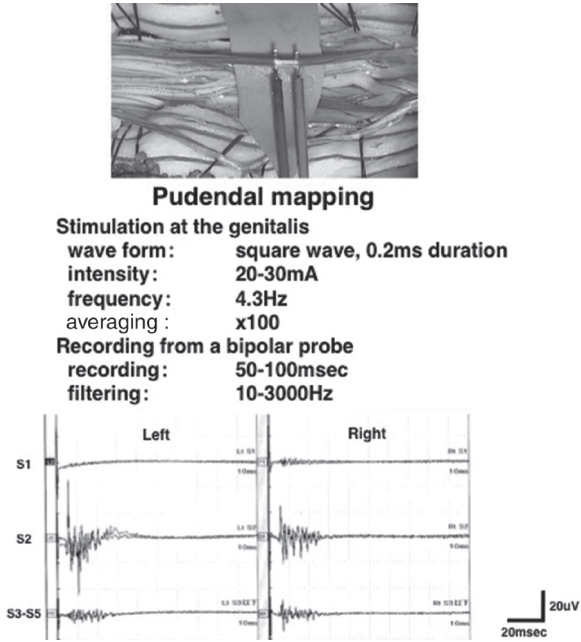


Fig. 5 Pudendal mapping. *Upper:* A photograph showing the recording of the pudendal afferent potential using a hand-held bipolar probe. *Middle:* Parameters for pudendal mapping are shown. *Lower:* The results of the pudendal mapping demonstrated that the highest compound afferent action potential was at the left S2, followed by the right S2. The bilateral S3–S5 nerve bundles demonstrated a pudendal response smaller than that of S2. Tiny potentials were recorded from the right S1, which could be ignored and sacrificed without urinary complications.

Postoperatively, the patient is placed flat in the supine position. The patient is kept intubated overnight with respiratory assistance to prevent respiratory complications and for postoperative pain control. Bedside rehabilitation starts 4 days after surgery, and the patient goes to the rehabilitation room for exercise beginning 1 week after surgery.

Surgical outcomes

The efficacy of FPR was reported in the late 1990s in three consecutive randomized controlled trials.^{38–40} One study demonstrated the efficacy of FPR regarding the reduction of spasticity and improvement of motor function.⁴¹ Steinbok analyzed the surgical outcomes of FPR from the data collected from 63 papers published before 2001.⁴² The expected functional outcome was classified into three groups in that paper:

1. High degree of certainty
 Reduction of spasticity in the lower extremities (LEs)
 Increased range of motion of the LEs without decreased muscle strength
 Improved GMFM score
2. Moderate degree of certainty
 Efficacy of surgery for more than 5 years
 Improved gait
 Improved ADL
 Functional improvement of the upper extremities (UEs)

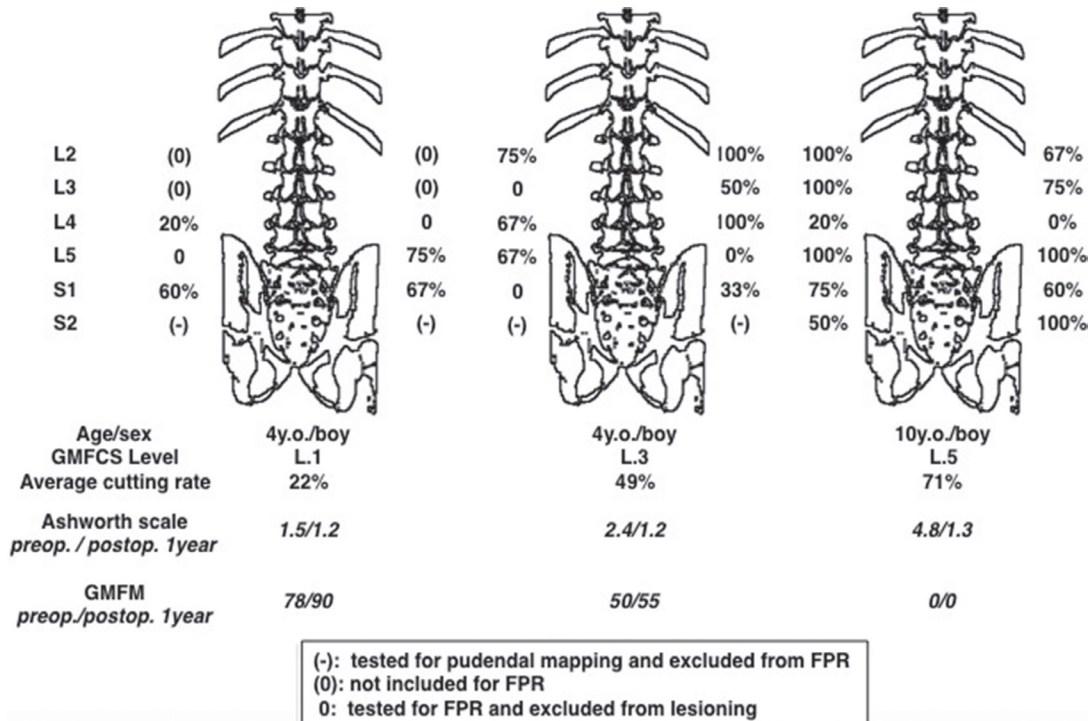


Fig. 6 Root cutting during functional posterior rhizotomy. Three representative cases are shown. The cutting rate of each segmental posterior root is shown. The average cutting rate, pre- and postoperative Ashworth scale, and Gross Motor Function (GMFM) score are shown below in the figure.

Pudendal mapping

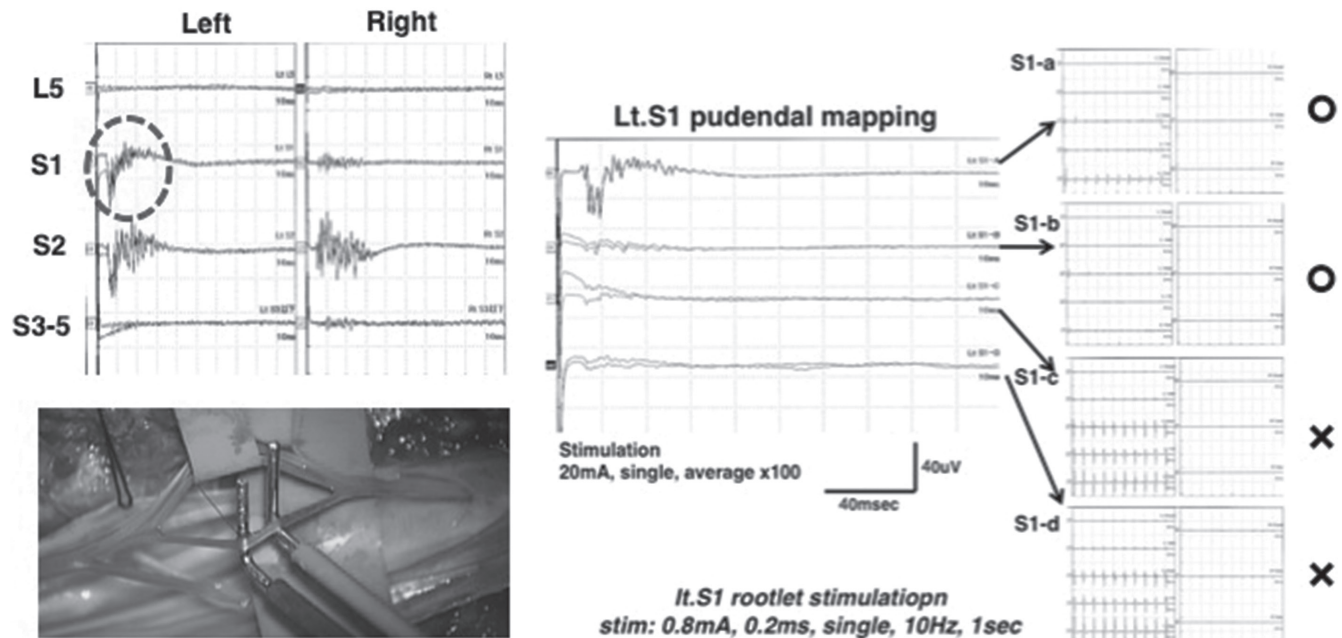


Fig. 7 Pudendal mapping of S1 rootlets. The S1 rootlets can be subjected to pudendal mapping in an unusual situation. *Left:* Pudendal mapping in this 4-year-old male showed relatively high action potentials (*dotted circle*) from the left S1 root, which needed to be cut to reduce spasticity, but preservation of the urinary function had to be considered. *Center and right:* The root was divided into four rootlets. Pudendal mapping and electrical stimulation were carried out for each rootlet. Rootlet S1-a showed high pudendal action potentials, but normal muscle responses, and was thus preserved. Rootlet S1-b showed small action potentials with normal muscle responses, and was preserved. Rootlets S1-c and d demonstrated highly abnormal muscle responses with small pudendal action potentials, and these were cut. The patient had no urological complications after surgery, and gained excellent control of his spasticity at the ankle joint. O: preserved rootlet, X: lesioned rootlet. (Modified from reference 6, with permission.)

3. Low degree of certainty

Decreased number of orthopedic surgeries
Functional improvement of recognition

He added that the influence of the dislocation of the hip joint was unclear, and that medico-economic issues should be considered in the future.

Another paper analyzed the above-mentioned three randomized controlled trials and summarized the efficacy of FPR as follows⁴¹⁾:

1. When FPR with intensive physical therapy was compared to intensive physical therapy alone, the former showed better functional improvement and was more effective to reduce spasticity.
2. FPR can improve the motor function, but the degree of improvement did not match that of the reduction of spasticity.

It is important to understand that a reduction of spasticity does not necessarily correlate with

improved motor function. In other words, the functional disturbance in children with cerebral palsy reflects not only spasticity, but also other complex factors, such as mental development, associated joint deformation, and the extent of original brain damage.

The incidence of neurological complications following FPR is generally low. Temporary sensory loss and urinary dysfunction can develop around 2% of cases, but permanent disability is quite rare.^{43,44)} Respiratory and wound complications occur more frequently, in about 3–5% of cases, and postoperative management for preventing general complications is important.

It has been reported that a long-lasting effect of FPR can be expected when routine physical therapy and appropriate orthopedic surgery are added in the follow-up.^{5,45–51)} Functional improvement of the gait after FPR, the effects of FPR for dislocated hip joints, and the “remote effect” for fine movement of the UEs have also been reported.^{52–55)} Mechanism

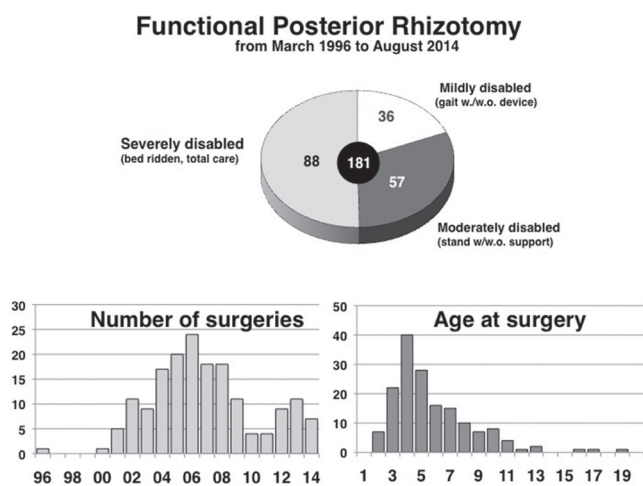


Fig. 8 Children who underwent functional posterior rhizotomy. *Upper*: Number of children who underwent the procedure, classified based on their handicap. *Lower left*: Annual number of surgeries. The number decreased in the late 2010s with ITB infusion therapy, then BTX injection therapy was introduced in Japan. The number of surgeries has been slowly increasing again. *Lower right*: Age distribution of patients.

of the “remote effect” has been attributed for a decreased conduction of the primitive spinal reflex circuit such as the propriospinal reflex to the UEs. A long-term follow-up of more than 20 years confirmed that there was no functional deterioration in most of the patients who underwent FPR.⁵⁶⁾ It should be noted that, in general, papers from neurosurgical journals conclude that there is a favorable outcome for FPR, while those from pediatric and orthopedic journals tend to take a more critical standpoint.^{24,57,58)}

We performed 181 FPRs from March 1996 to August 2014. The annual number of surgeries reflects the history of FPR in Japan (Fig. 8). At the beginning, there was strong opposition from orthopedic surgeons, who had been the main medical caregivers for children with spastic cerebral palsy.⁵⁾ Following the introduction of the BTX therapy for childhood spasticity, the number of FPR rapidly decreased, then gradually began increasing again. It seems that advantages and limitations of each treatment have been learnt and the role of FPR was re-evaluated by physicians who treated spastic children.

The age of the patients ranged from 2 years to 19 years (average: 5 years old, median: 4 years old). Thirty-six (20%) patients were able to walk with or without a device (GMFCS level 1–2), 57 (31%) were able to stand with assistance (GMFCS level 3), and

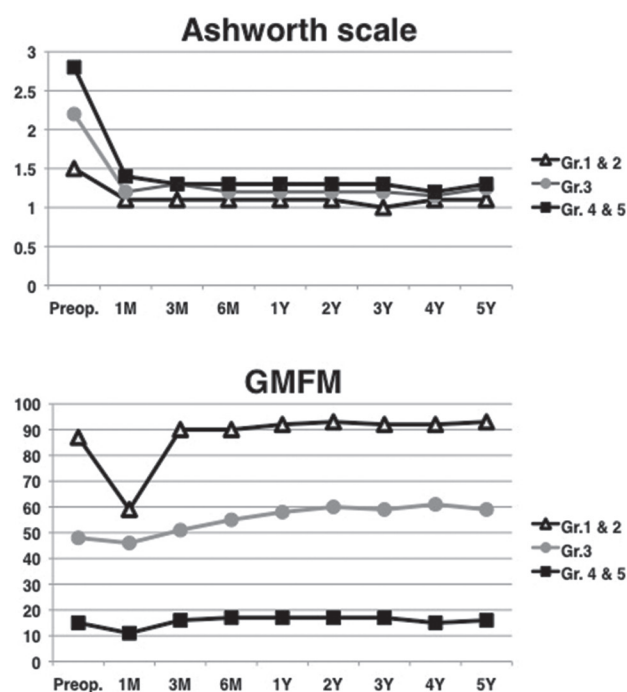


Fig. 9 Chronological changes in the Ashworth scale and GMFM. Spasticity, represented by the Ashworth scale, decreased immediately after surgery and remained stable with some fluctuation. The GMFM score was reduced temporarily after surgery in group 1 and 2 (those walking with or without a device) children because of the reduced spasticity, but improved 3 months after surgery and thereafter. The GMFM score increased gradually over time in group 3 (those who could stand with or without support) children, and it remains unchanged in group 4 and 5 (bedridden, total care) children whose goal of surgery was pain relief and a reduced burden for caregivers. GMFM: Gross Motor Function Measurement. (Modified from reference 6, with permission.)

88 (49%) were bedridden with full support (GMFCS level 4–5) prior to surgery. The outcome of FPR in our series has been published⁵⁾ (Fig. 9). In brief, we confirmed that there was an immediate reduction of spasticity, regardless of the preoperative condition, and there was improved motor function, as evaluated by GMFM, in ambulatory children. Children with severe disabilities showed no direct change in the GMFM, but the decreased family burden and relief from spastic pain were highly appreciated by the families and daily caregivers.⁶⁾

From our view point, FPR is associated with the following advantages:

1. It provides a more direct approach to spasticity, and a long-lasting effect can be expected after a single surgery.

2. It is useful to reduce spasticity in the LEs, and a remote effect on the UEs can be expected.
3. There is no need to worry about side effects or medical tolerance, which are observed for other medical treatments. This can be counted as another advantage of FPR from the medico-economic standpoint.
4. The motor organs, such as muscles and tendons, are kept intact, while reducing the spasticity.

On the other hand, the procedure is irreversible and it should be emphasized that hypotonia caused by overcutting of the root/rootlet must be avoided. Minimal cutting of the root/rootlet while providing a maximal reduction of spasticity is the ideal concept of FPR.

ITB Infusion Treatment

ITB infusion treatment is a relatively new therapy introduced to control spasticity in Japan.^{7,59–61} Since the introduction of ITB for adults in 2006, followed by pediatric use in 2007, the total number of ITB pump implantations has reached more than 1,100. However, only a limited number (~130) of pediatric patients had received the benefit of ITB treatment (11% of all ITB implantations) by September 2014.

The guidelines for rehabilitation in children with cerebral palsy published by the Japanese Association of Rehabilitation Medicine recommended ITB infusion treatment for children with severe spasticity. On the other hand, it mentioned that its use for children with dystonia can be considered, but

there is insufficient evidence of its effectiveness in such cases.

We consider that ITB treatment is indicated for severely disabled children with spasticity, regardless of the background pathology. Currently, children with dystonic posture tend to be selected for ITB infusion treatment as the initial surgery.^(9–11,62–65) The child's age does not limit the indication, but a body weight more than 15 kg is preferred for safe implantation.^{66,67} Children who are considered to be candidates for ITB infusion treatment undergo a test injection of baclofen prior to surgery. When the test injection shows the efficacy of baclofen in terms of reducing spasticity, and the family agrees to pump implantation, then the surgery is scheduled.

Surgical Procedure for ITB Pump Implantation

The details of the standard surgical procedure are shown in Figs. 10 and 11.⁶⁸ In brief, the procedure includes the following steps:

1. The child is placed in the lateral position, and a fluoroscope is prepared for intraoperative use. The ITB pump should be placed in the right abdominal wall, because affected children often need a gastrostomy or already have one on the left side.
2. A midline skin incision is made on the lumbar region, and a Toffy needle is inserted intrathecally from the paramedian region. We recommend inserting a 22 gauge needle beforehand to confirm the direction of the lumbar puncture.

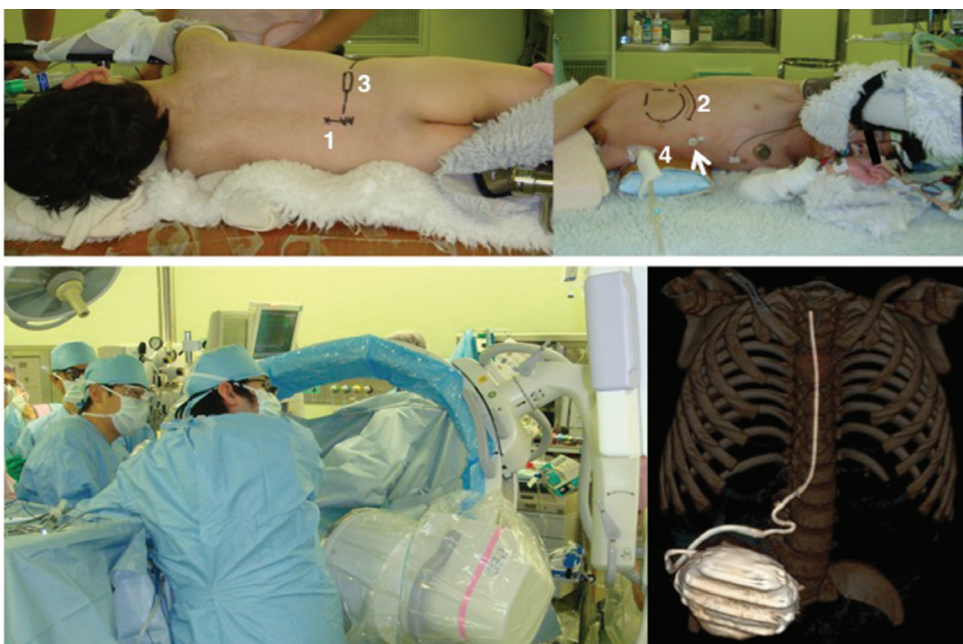

Fig. 10 ITB pump implantation. *Upper:* Position of the child is shown. The pump is placed in the right abdominal wall so that the wound and the pump can be placed away from the gastrostomy port (*arrow*). *Lower left:* An intraoperative photograph of the insertion of a spinal catheter under fluorescent guidance. *Lower right:* A postoperative three-dimensional reconstructed computed tomography image demonstrating an ITB unit from the pump to the spinal catheter. 1: Back skin incision, 2: abdominal skin incision, 3: connector, 4: ITB pump, ITB: intrathecal baclofen.

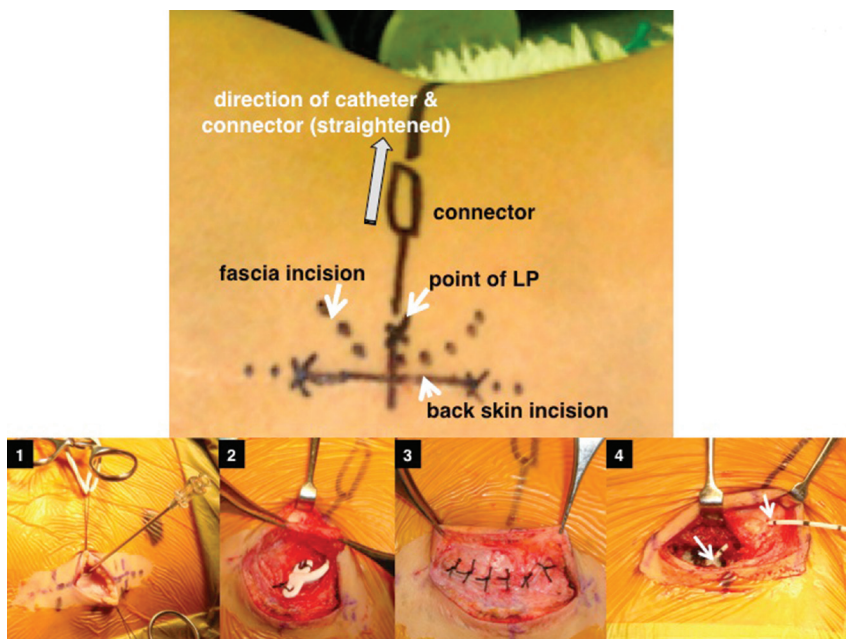


Fig. 11 Insertion of a spinal catheter. *Upper:* A back skin incision and the subfascial placement of a catheter connector is shown. Note that the skin and fascial incisions were made at different planes, and the lumbar puncture (LP) was carried out using para-median technique. Because the connector is placed in the subfascial space, the direction of the catheter becomes straight, and there is no need to fix it on the soft tissue. *Lower:* 1. Para-median lumbar puncture. 2. The spinal catheter is fixed on the muscle using a butterfly-shaped device. 3. The spinal catheter is passed in the subfascial space and is connected to the abdominal catheter using a connector. The fascia is re-sutured to cover the butterfly device. 4. When laminectomy is necessary to insert a spinal catheter (arrows), the catheter is passed through the paravertebral muscle, not through the incision for laminectomy.

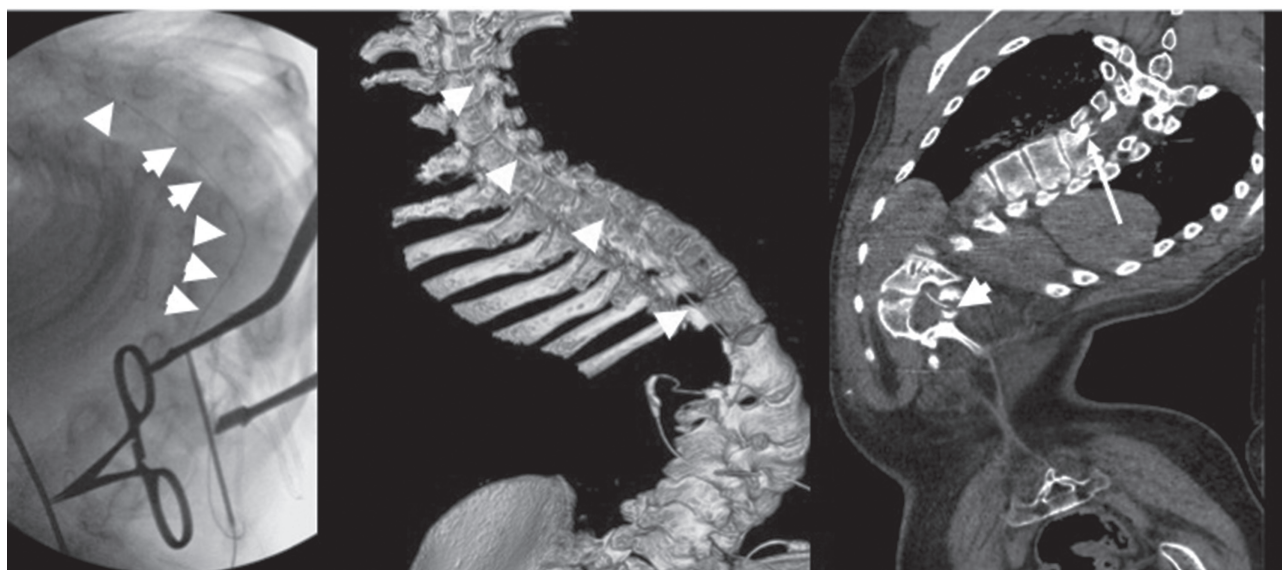


Fig. 12 Direct insertion of a spinal catheter by laminectomy. In cases with severe spinal deformity in which the percutaneous insertion of a spinal catheter is impossible, direct insertion by laminectomy is generally selected. *Left:* A spinal catheter (arrowheads) under fluorescent monitoring during the surgery. *Center:* A 3D reconstructed postoperative CT scan showed the catheter (arrowheads) in the spinal canal. *Right:* A coronal CT scan showing the spinal catheter inserted through a laminectomy (small arrow) in the deformed spine and the catheter tip (long arrow) at the thoracic level. CT: computed tomography, 3D: three-dimensional.

3. In cases where the patient has severe scoliosis or a spinal deformity, direct exposure of the dura by partial laminectomy may be required (Fig. 12).
4. Once the needle is placed intrathecally, the spinal catheter is inserted under fluoroscopic guidance. The level of the catheter tip should be decided

- before surgery based on the distribution of the spasticity of the patient.⁶⁹⁾
5. A linear or curved skin incision is made on the right upper abdomen. The fascia of the abdominal rectal and oblique muscles is cut, and the space between the fascia and muscle is dissected.⁷⁰⁾ Placing the skin and fascia incisions at different

levels is recommended to prevent infections and other complications (Fig. 13).

6. A passer is inserted from the subfascial layer from the back to the abdominal side.⁷¹⁾ The abdominal catheter is then passed and connected with the spinal catheter. The connector is set in the subfascial space, and thus needs no fixation. Care should be taken to avoid any bending or kinking of the catheter.
7. The natural flow of CSF from the catheter should be confirmed at every step of the surgery.
8. Finally, the abdominal catheter is connected to the ITB pump, which is then placed and fixed in the subfascial space in the abdominal wall.
9. In cases where the child is very small in size, dissection under the umbilicus may be necessary to secure sufficient space to place the ITB pump.
10. The insertion point of the spinal catheter is covered with pedicled soft tissue. Both the spinal and abdominal wounds are closed layer-by-layer.

Management of Baclofen Dosage

ITB infusion treatment starts with the same amount of baclofen dosage at the test injection. The amount of daily baclofen dosage is decided based on the degree of spasticity. According to the instruction for ITB in children, the amount of baclofen can be changed up to 15% or down to 20% of the original one every day at the time of introduction soon after the surgery. The maximum daily dosage is 400 µg. During the maintenance period more than 2 months after the surgery, the amount of baclofen can be increased or decreased up to 20% of the previous one and the maximum daily dosage is the same 400 µg in pediatric cases.

Results of ITB Infusion Treatment in Japan

A favorable outcome for controlling spasticity after the introduction of ITB infusion treatment has been reported repeatedly.^{62,72,73)} In Japan, a nationwide analysis of the initial outcome of ITB infusion treatment for children was conducted in 2012.⁷⁾ Among 71 children who were tested for ITB implantation, 62 (87%) showed effectiveness in terms of reducing the spasticity. An ITB pump was implanted in 43 children. Because most of the patients had undergone ITB pump implantation recently, only 35 had been followed for more than a year. The spasticity measured by the Ashworth scale demonstrated a satisfactory reduction of spasticity in the UEs and LEs, with statistical significance. At the most recent follow-up, the Ashworth scale of the UEs had decreased from 3.30 ± 1.02 (before surgery) to 2.04 ± 0.95 , and that of LEs from 3.04 ± 0.99 to 1.91 ± 0.78 (Fig. 14).

Side effects such as upper respiratory infections, hypertonia, and liver dysfunction, observed in the first year after the ITB infusion treatment, were reported as 19 incidents in 12 children. The incidence of side effects was approximately the same as that in adults. Considering the fact that most children who underwent ITB pump implantation in Japan were more severely disabled than those in the previous reports, these findings indicate that ITB infusion treatment can be safely performed for the pediatric population.

Surgery-related complications (meningitis, CSF leakage, wound complications) occurred in fewer than 10% of cases, and the frequency was much lower than those reported previously.^{7,66,67,72,74,75)}



Fig. 13 Placement of a baclofen pump. *Left:* The subcostal skin incision and fascial incision should be placed in different planes. The ITB abdominal catheter runs in the subfascial layer without crossing either incision. *Center:* Subfascial placement of the ITB pump. *Right:* Closure of the fascial layer. ITB: intrathecal baclofen.

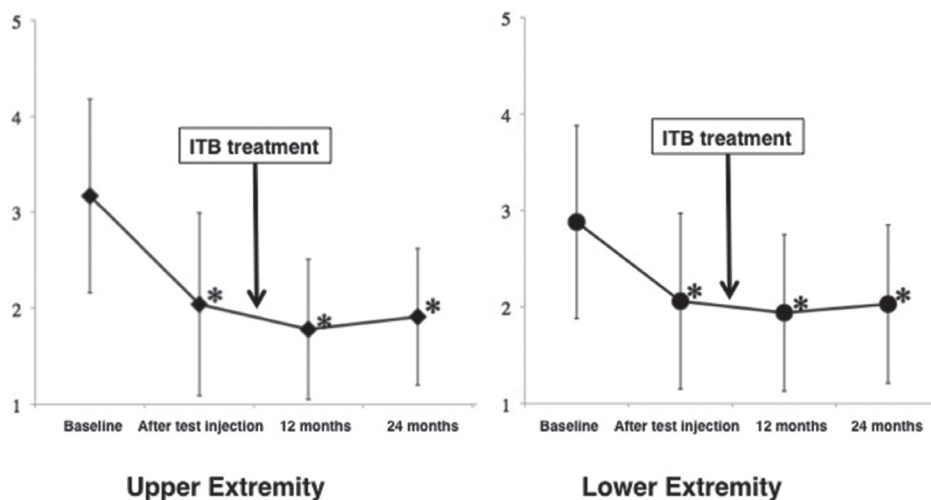


Fig. 14 Impact of ITB treatment for reducing spasticity. A test injection of baclofen followed by ITB treatment showed a stable reduction of the spasticity, as measured by the Ashworth scale, with statistical significance (*: $P < 0.05$) for both the upper and lower extremities (modified from reference 7, with permission). ITB: intrathecal baclofen.

In general, an average Ashworth score > 3 , younger age (less than 8–10 years old) and the presence of a gastrostomy are regarded as risk factors in terms of surgical complications associated with ITB pump implantation.^{67,66,74} Improved surgical techniques, such as subfascial placement of both the ITB pump and catheter can play a critical role to avoid surgical complications due to ITB pump implantation.^{70,71} Because ITB for the standard treatment of spasticity has only been performed for about 20 years at most, new types of complications, such as the development of scoliosis, may emerge in the future.⁷⁶ Careful long-term follow-up with consideration of a cost/benefit analysis of the treatment is needed prior to the further dissemination of the ITB infusion treatment.⁷⁷

A Comprehensive Approach to Childhood Spasticity

A paradigm shift is currently ongoing in the field of treatment for childhood spasticity in Japan.^{5,6} With the advent and introduction of FPR, ITB infusion treatment and local BTX injection, the role of each treatment modality should be understood more clearly. The first step of the treatment is to reduce spasticity. The second step is to improve the deteriorated motor function (Fig. 15).

FPR, ITB infusion treatment, and BTX injection can all be considered for the first step of treatment (Table 1). FPR is most effective for controlling spasticity in children with cerebral palsy, regardless of the disability. Mild to moderately disabled children (GMFCS level 1–3) are most favorable candidates for FPR.^{10,11} A long-lasting reduction of spasticity can be expected, but

since the procedure cuts the nerve root/rootlet, a high level of skills and experience is required for surgery. ITB infusion treatment requires the implantation of an ITB pump and catheter, and the avoidance of complications is important both during surgery and during the follow-up period. Because the dose of baclofen is adjustable, a wide range of spasticity can be treated, regardless of its background pathology (encephalitis, hypoxic encephalopathy, traumatic brain damage, etc.). Dystonic children with severe spasticity would be expected to receive the most benefit from the treatment, but may be resistant to the standard ITB infusion treatment.⁷⁸ BTX injection is less invasive compared with FPR and ITB infusion treatment. It can be practiced at outpatient clinics and is considered as the first choice of treatment for children with mild spasticity. It is also applied in combination with FPR or ITB infusion treatment for residual spasticity.

FPR is best indicated for spasticity of cerebral palsy origin. ITB is selected for children with severe spasticity, especially those with dystonia. BTX can be indicated for the initial treatment of mild-to-moderate spasticity or residual spasticity after FPR or ITB. The second step of treatment is composed of rehabilitation and orthopedic surgery. Thanks to the introduction of new treatments, functional improvement can be pursued after the reduction of spasticity.

The classification of the goal of treatment as a reduction of spasticity or functional improvement makes the treatment strategy easier.^{5,6} Cooperation among the various specialists including neurosurgeons, orthopedic surgeons, pediatric neurologists, physical therapists, and technicians for the

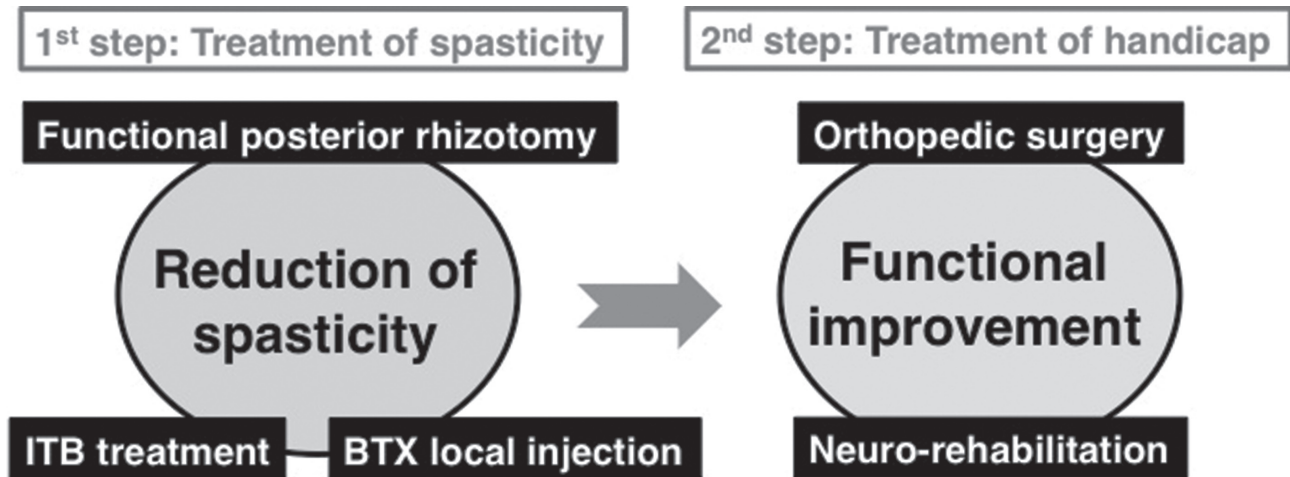


Fig. 15 The strategy and techniques used for the treatment of spasticity in children. The first step of treatment is to control spasticity. After reduction of the spasticity, the second step for a pre-existing handicap is intended to gain functional improvement. FPR, ITB, and BTX are the treatment options used in the first step. Orthopedic surgery and neuro-rehabilitation comprise the treatment options in the second step. Treatment with a single method or a combination of methods is selected on an individual basis, after considering the degree and type of spasticity. BTX: botulinum toxin injection, FPR: functional posterior rhizotomy, ITB: intrathecal baclofen infusion.

Table 1 A comparison of the treatments for spasticity

	FPR	ITB	BTX
Pathology	CP origin	Any origin	Any origin
Dystonia	+	+++	+ ~ ++
Distribution	Diffuse	Diffuse	Focal
GMFCS	Level 1 ~ 5	Level 4 ~ 5	Level 1 ~ 3 (~5)
Age	2.5 y.o. ~	3 y.o. ~ (15 kg ~)	(2 y.o. ~)

BTX: botulinum toxin, CP: cerebral palsy, FPR: functional posterior rhizotomy, GMFCS: Gross Motor Function Classification Scale, ITB: intrathecal baclofen, y.o.: years old.

intraoperative neurophysiology, is indispensable for the successful treatment of childhood spasticity. It is especially important in Japan where misunderstanding of the newly emerging surgical procedure still hampers to disseminate them for disabled children with spasticity. A comprehensive team approach to treat the spasticity will enhance the outcomes of each treatment, which will benefit the children with spasticity in the future.⁸⁾

Conflicts of Interest Disclosure

The authors have no personal, financial, or institutional interest in any of the drugs, materials, or devices used in the article. All authors who are members of The Japan Neurosurgical Society (JNS)

have registered online Self-reported COI Disclosure Statement Forms through the website for JNS members.

References

- 1) Sanger TD, Delgado MR, Gaebler-Spira D, Hallett M, Mink JW; Task Force on Childhood Motor Disorders: Classification and definition of disorders causing hypertonia in childhood. *Pediatrics* 118: 2159–2167, 2003
- 2) Gros C: Spasticity. Clinical classification and surgical treatment, in Krayenbuhl H (ed): *Advances and Technical Standards in Neurosurgery*, ed 6. Wien New York, Springer, 1979, pp 55–97
- 3) Abbott R, Forem SL, Johann M: Selective posterior rhizotomy for the treatment of spasticity: a review. *Childs Nerv Syst* 5: 337–346, 1989
- 4) Abbott R: Editorial on “The management of childhood hypertonia.” *Childs Nerv Syst* 23: 937–941, 2007
- 5) Morota N: Functional posterior rhizotomy: the Tokyo experience. *Childs Nerv Syst* 23: 1007–1014, 2007
- 6) Morota N: [Functional posterior rhizotomy for treatment of spasticity]. *No Shinkei Geka* 38: 209–228, 2010
- 7) Morota N, Kubota M, Nemoto A, Katayama Y: [Intrathecal baclofen treatment for spasticity in childhood. initial report of long-term follow up in Japan]. *No To Hattatsu* 46: 179–186, 2014
- 8) Flett PJ: Rehabilitation of spasticity and related problems in childhood cerebral palsy. *J Paediatr Child Health* 39: 6–14, 2003

- 9) Gormley ME Jr, Krach LE, Piccini L: Spasticity management in the child with spastic quadriplegia. *Eur J Neurol* 8 (Suppl 5): 127–135, 2001
- 10) von Koch CS, Park TS, Steinbok P, Smyth M, Peacock WJ: Selective posterior rhizotomy and intrathecal baclofen for the treatment of spasticity. *Pediatr Neurosurg* 35: 57–65, 2001
- 11) Dudley RWR, Parolin M, Gagnon B, Saluja R, Yap R, Montpetit K, Ruck J, Poulan C, Cantin MA, Benaroch TE, Farmer JP: Long-term functional benefits of selective dorsal rhizotomy for spastic cerebral palsy. *J Neurosurg Pediatr* 12: 142–150, 2013
- 12) Foerster O: On the indications and results of the excision of posterior spinal nerve roots in men. *Surg Gynecol Obstet* 16: 463–474, 1913
- 13) Morota N: [Functional posterior rhizotomy as a surgical treatment for spastic cerebral palsy in childhood]. *No To Hattatsu* 31: 359–365, 1999
- 14) Fasano VA, Broggi G, Barolat-Romana G, Squazzi A: Surgical treatment of spasticity in cerebral palsy. *Childs Brain* 4: 289–305, 1978
- 15) Fasano VA, Barolat-Romana G, Zeme S, Squazzi A: Electrophysiological assessment of spinal circuits in spasticity by direct dorsal root stimulation. *Neurosurgery* 4: 146–151, 1979
- 16) Park TS, Gaffney PE, Kaufman BA, Molleston MC: Selective lumbosacral dorsal rhizotomy immediately caudal to the conus medullaris for cerebral palsy spasticity. *Neurosurgery* 33: 929–933; discussion 933–934, 1993
- 17) Park TS, Johnston JM: Surgical techniques of selective dorsal rhizotomy for spastic cerebral palsy. Technical note. *Neurosurg Focus* 21: e7, 2006
- 18) Peacock WJ, Arens LJ: Selective posterior rhizotomy for the relief of spasticity in cerebral palsy. *S Afr Med J* 62: 119–124, 1982
- 19) Peacock WJ, Arens LJ, Berman B: Cerebral palsy spasticity. Selective posterior rhizotomy. *Pediatr Neurosci* 13: 61–66, 1987
- 20) Galarza M, Fowler EG, Chipps L, Padden TM, Lazareff JA: Functional assessment of children with cerebral palsy following limited (L4-S1) selective posterior rhizotomy—a preliminary report. *Acta Neurochir (Wien)* 143: 865–872, 2001
- 21) Steinbok P: Selective dorsal rhizotomy for spastic cerebral palsy: a review. *Childs Nerv Syst* 23: 981–990, 2007
- 22) Morota N, Kameyama S, Masuda M, Oishi M, Aguni A, Uehara T, Nagamine K: Functional posterior rhizotomy for severely disabled children with mixed type cerebral palsy. *Acta Neurochir Suppl* 87: 99–102, 2003
- 23) Albright AL, Barry MJ, Shafton DH, Ferson SS: Intrathecal baclofen for generalized dystonia. *Dev Med Child Neurol* 43: 652–657, 2001
- 24) MacWilliams BA, Johnson BA, Shuckra AL, D'Astous JL: Functional decline in children undergoing selective dorsal rhizotomy after age 10. *Dev Med Child Neurol* 53: 717–723, 2011
- 25) Wood E, Rosenbaum P: The gross motor function classification system for cerebral palsy: a study of reliability and stability over time. *Dev Med Child Neurol* 42: 292–296, 2000
- 26) Russell DJ, Rosenbaum PL, Cadman DT, Gowland C, Hardy S, Jarvis S: The gross motor function measure: a means to evaluate the effects of physical therapy. *Dev Med Child Neurol* 31: 341–352, 1989
- 27) Msall ME, DiGaudio K, Duffy LC, LaForest S, Braun S, Granger CV: WeeFIM. Normative sample of an instrument for tracking functional independence in children. *Clin Pediatr (Phila)* 33: 431–438, 1994
- 28) Ashworth B: Preliminary trial of carisoprodol in multiple sclerosis. *Practitioner* 192: 540–542, 1964
- 29) Bohannon RW, Smith MB: Interrater reliability of a modified Ashworth scale of muscle spasticity. *Phys Ther* 67: 206–207, 1987
- 30) Deletis V, Vodusek D, Abbott R, Epstein F, Turndorff H: Intraoperative monitoring of the dorsal roots: minimizing the risk of iatrogenic micturition disorders. *Neurosurgery* 30: 72–75, 1992
- 31) Ogiwara H, Morota N: Pudendal afferents mapping in posterior sacral rhizotomies. *Neurosurgery* 74: 171–175, 2014
- 32) Phillips LH, Park TS: Electrophysiologic studies of selective posterior rhizotomy patients, in Park TS (ed): *Neurosurgery: State of the Art Reviews. Management of Spasticity in Cerebral Palsy and Spinal Cord Injury*. Philadelphia, Hanley & Belfus, 1989, pp 459–469
- 33) Mittal S, Farmer JP, Poulin C, Silver K: Reliability of intraoperative electrophysiological monitoring in selective posterior rhizotomy. *J Neurosurg* 95: 67–75, 2001
- 34) Steinbok P, Keyes R, Langill L, Cochrane DD: The validity of electrophysiological criteria used in selective functional posterior rhizotomy for treatment of spastic cerebral palsy. *J Neurosurg* 81: 354–361, 1994
- 35) Futagi Y, Abe J: H-reflex study in normal children and patients with cerebral palsy. *Brain Dev* 7: 414–420, 1985
- 36) Storrs BB, Nishida T: Use of the 'H' reflex recovery curve in selective posterior rhizotomy. *Pediatr Neurosci* 14: 120–123, 1988
- 37) Fukuhara T, Najm IM, Levin KH, Luciano MG, Brant M S CL: Nerve rootlets to be sectioned for spasticity resolution in selective dorsal rhizotomy. *Surg Neurol* 54: 126–132; discussion 133, 2000
- 38) Steinbok P, Reiner AM, Beauchamp R, Armstrong RW, Cochrane DD, Kestle J: A randomized clinical trial to compare selective posterior rhizotomy plus physiotherapy with physiotherapy alone in children with spastic diplegic cerebral palsy. *Dev Med Child Neurol* 39: 178–184, 1997
- 39) McLaughlin JF, Bjornson KF, Astley SJ, Graubert C, Hays RM, Roberts TS, Price R, Temkin N: Selective dorsal rhizotomy: efficacy and safety in an investigator-masked randomized clinical trial. *Dev Med Child Neurol* 40: 220–232, 1998

- 40) Wright FV, Sheil EM, Drake JM, Wedge JH, Naumann S: Evaluation of selective dorsal rhizotomy for the reduction of spasticity in cerebral palsy: a randomized controlled trial. *Dev Med Child Neurol* 40: 239–247, 1998
- 41) McLaughlin J, Bjornson K, Temkin N, Steinbok P, Wright V, Reiner A, Roberts T, Drake J, O'Donnell M, Rosenbaum P, Barber J, Ferrel A: Selective dorsal rhizotomy: meta-analysis of three randomized controlled trials. *Dev Med Child Neurol* 44: 17–25, 2002
- 42) Steinbok P: Selective dorsal rhizotomy for spastic cerebral palsy: a review. *Childs Nerv Syst* 23: 981–990, 2007
- 43) Abbott R: Complications with selective posterior rhizotomy. *Pediatr Neurosurg* 18: 43–47, 1992
- 44) Steinbok P, Schrag C: Complications after selective posterior rhizotomy for spasticity in children with cerebral palsy. *Pediatr Neurosurg* 28: 300–313, 1998
- 45) Graubert C, Song KM, McLaughlin JF, Bjornson KF: Changes in gait at 1 year post-selective dorsal rhizotomy: results of a prospective randomized study. *J Pediatr Orthop* 20: 496–500, 2000
- 46) Mittal S, Farmer JP, Al-Atassi B, Montpetit K, Gervais N, Poulin C, Benaroch TE, Cantin MA: Functional performance following selective posterior rhizotomy: long-term results determined using a validated evaluative measure. *J Neurosurg* 97: 510–518, 2002
- 47) Steinbok P: Outcomes after selective dorsal rhizotomy for spastic cerebral palsy. *Childs Nerv Syst* 17: 1–18, 2001
- 48) Engsberg JR, Ross SA, Collins DR, Park TS: Effect of selective dorsal rhizotomy in the treatment of children with cerebral palsy. *J Neurosurg* 105(1 Suppl): 8–15, 2006
- 49) van Schie PE, Schothorst M, Dallmeijer AJ, Vermeulen RJ, van Ouwerkerk WJ, Strijers RL, Becher JG: Short- and long-term effects of selective dorsal rhizotomy on gross motor function in ambulatory children with spastic diplegia. *J Neurosurg Pediatr* 7: 557–562, 2011
- 50) Tedroff K, Löwing K, Jacobson DN, Åström E: Does loss of spasticity matter? A 10-year follow-up after selective dorsal rhizotomy in cerebral palsy. *Dev Med Child Neurol* 53: 724–729, 2011
- 51) Hurvitz EA, Marciniak CM, Daunter AK, Haapala HJ, Stibb SM, McCormick SF, Muraszko KM, Gaebler-Spira D: Functional outcomes of childhood dorsal rhizotomy in adults and adolescents with cerebral palsy. *J Neurosurg Pediatr* 11: 380–388, 2013
- 52) Abel MF, Damiano DL, Gilgannon M, Carmines D, Kang HG, Bennett BC, Laws ER Jr: Biomechanical changes in gait following selective dorsal rhizotomy. *J Neurosurg* 102(2 Suppl): 157–162, 2005
- 53) Heim RC, Park TS, Vogler GP, Kaufman BA, Noetzel MJ, Ortman MR: Changes in hip migration after selective dorsal rhizotomy for spastic quadriplegia in cerebral palsy. *J Neurosurg* 82: 567–571, 1995
- 54) Mittal S, Farmer JP, Al-Atassi B, Montpetit K, Gervais N, Poulin C, Cantin MA, Benaroch TE: Impact of selective posterior rhizotomy on fine motor skills. Long-term results using a validated evaluative measure. *Pediatr Neurosurg* 36: 133–141, 2002
- 55) Gigante P, McDowell MM, Bruce SS, Chirelstein G, Chiriboga CA, Dutkowsky J, Fontana E, Hyman J, Kim H, Morgan D, Pearson TS, Rove BD, Roye DP Jr, Ryan P, Vitale M, Anderson RCE: Reduction in upper-extremity tone after lumbar selective dorsal rhizotomy in children with spastic cerebral palsy. *J Neurosurg Pediatr* 12: 588–594, 2013
- 56) Lagerrak NG, Lamberts RP, Fiegggen AG, Peter JC, van der Merwe L, Peacock WJ, Vaughan CL: A prospective gait analysis study in patients with diplegic cerebral palsy 20 years after selective dorsal rhizotomy. *J Neurosurg Pediatr* 1: 180–186, 2008
- 57) Johnson MB, Goldstein L, Thomas SS, Piatt J, Aiona M, Sussman M: Spinal deformity after selective dorsal rhizotomy in ambulatory patients with cerebral palsy. *J Pediatr Orthop* 24: 529–536, 2004
- 58) Grunt S, Becher JG, Vermeulen RJ: Long-term outcome and adverse effects of selective dorsal rhizotomy in children with cerebral palsy: a systematic review. *Dev Med Child Neurol* 53: 490–498, 2011
- 59) Penn RD, Kroin JS: Long-term intrathecal baclofen infusion for treatment of spasticity. *J Neurosurg* 66: 181–185, 1987
- 60) Albright AL, Cervi A, Singletary J: Intrathecal baclofen for spasticity in cerebral palsy. *JAMA* 265: 1418–1422, 1991
- 61) Taira T, Ueta T, Katayama Y, Kimizuka M, Nemoto A, Mizusawa H, Liu M, Koito M, Hiro Y, Tanabe H: Rate of complications among the recipients of intrathecal baclofen pump in Japan: a multicenter study. *Neuromodulation* 16: 266–272; discussion 272, 2013
- 62) Albright AL, Barry MJ, Shafton DH, Ferson SS: Intrathecal baclofen for generalized dystonia. *Dev Med Child Neurol* 43: 652–657, 2001
- 63) Albright AL: Neurosurgical treatment of spasticity and other pediatric movement disorders. *J Child Neurol* 18(Suppl 1): S67–S78, 2003
- 64) Albright AL: Intraventricular baclofen infusion for dystonia. Report of two cases. *J Neurosurg* 105:(1 Suppl): 71–74, 2006
- 65) Kan P, Gooch J, Amini A, Ploeger D, Grams B, Oberg W, Simonsen S, Walker M, Kestle J: Surgical treatment of spasticity in children: comparison of selective dorsal rhizotomy and intrathecal baclofen pump implantation. *Childs Nerv Syst* 24: 239–243, 2008
- 66) Motta F, Buonaguro V, Stignani C: The use of intrathecal baclofen pump implants in children and adolescents: safety and complications in 200 consecutive cases. *J Neurosurg* 107(1 Suppl): 32–35, 2007
- 67) Fjelstad AB, Hommelstad J, Sorteberg A: Infections related to intrathecal baclofen therapy in children and adults: frequency and risk factors. *J Neurosurg Pediatr* 4: 487–493, 2009

- 68) Ammar A, Ughratdar I, Sivakumar G, Vloeberghs MH: Intrathecal baclofen therapy—how we do it. *J Neurosurg Pediatr* 10: 439–444, 2012
- 69) Albright AL, Turner M, Pattisapu JV: Best-practice surgical techniques for intrathecal baclofen therapy. *J Neurosurg* 104(4 Suppl): 233–239, 2006
- 70) Kopell BH, Sala D, Doyle WK, Feldman DS, Wisoff JH, Weiner HL: Subfascial implantation of intrathecal baclofen pumps in children: technical note. *Neurosurgery* 49: 753–756; discussion 756–757, 2001
- 71) Bassani L, Harter DH: Paraspinal subfascial placement of lumbar intrathecal baclofen catheters: short-term outcomes of a novel technique. *J Neurosurg Pediatr* 9: 93–98, 2012
- 72) Motta F, Antonello CE: Analysis of complications in 430 consecutive pediatric patients treated with intrathecal baclofen therapy: 14-year experience. *J Neurosurg Pediatr* 13: 301–306, 2014
- 73) Krach LE, Kriel RL, Gilmartin RC, Swift DM, Storrs BB, Abbott R, Ward JD, Bloom KK, Brooks WH, Madsen JR, McLaughlin JF, Nadell JM: GMFM 1 year after continuous intrathecal baclofen infusion. *Pediatr Rehabil* 8: 207–213, 2005
- 74) Albright AL, Awaad Y, Muhonen M, Boydston WR, Gilmartin R, Krach LE, Turner M, Zidek KA, Wright E, Swift D, Bloom K: Performance and complications associated with the synchroMed 10-ml infusion pump for intrathecal baclofen administration in children. *J Neurosurg* 101(1 Suppl): 64–68, 2004
- 75) Vender JR, Hester S, Waller JL, Rekito A, Lee MR: Identification and management of intrathecal baclofen pump complications: a comparison of pediatric and adult patients. *J Neurosurg* 104(1 Suppl): 9–15, 2006
- 76) Burn SC, Zeller R, Drake JM: Do baclofen pumps influence the development of scoliosis in children? *J Neurosurg Pediatr* 5: 195–199, 2010
- 77) Sampson FC, Hayward A, Evans G, Morton R, Collett B: Functional benefits and cost/benefit analysis of continuous intrathecal baclofen infusion for the management of severe spasticity. *J Neurosurg* 96: 1052–1057, 2002
- 78) Albright AL, Ferson SS: Intraventricular baclofen for dystonia: techniques and outcomes. Clinical article *J Neurosurg Pediatr* 3: 11–14, 2009

Address reprint requests to: Nobuhito Morota, MD, Division of Neurosurgery, Tokyo Metropolitan Children's Medical Center, 2-8-29 Musashi-dai, Fuchu, Tokyo 183-8561, Japan.
e-mail: nobuhito_morota@tmhp.jp