

Research Article

Effect of Vacuum Sealing Drainage on Soft Tissue Injury of Traumatic Fracture and Its Effect on Wound Recovery

Pengfei Nie ¹ and Canhong Zhang ²

¹Department of Orthopedics, Beilun District People's Hospital, Ningbo 315800, Zhejiang, China

²Department of Orthopaedics, Quanzhou First Hospital Affiliated to Fujian Medical University, Quanzhou 362000, Fujian, China

Correspondence should be addressed to Pengfei Nie; niepengfei188@163.com

Received 4 July 2022; Revised 29 August 2022; Accepted 9 September 2022; Published 28 September 2022

Academic Editor: Peng-Yue Zhang

Copyright © 2022 Pengfei Nie and Canhong Zhang. This is an open access article distributed under the Creative Commons Attribution License, which permits unrestricted use, distribution, and reproduction in any medium, provided the original work is properly cited.

Purpose. The current work is mainly to explore the effect of vacuum sealing drainage (VSD) on soft tissue injury (STI) caused by traumatic fractures (TFs) and its effect on wound recovery. **Methods.** We first selected 90 patients with TF STI from May 2019 to May 2021, of which 40 patients (control group) received routine treatment, and the other 50 patients (observation group) were treated with VSD. The curative effect, rehabilitation (changing dressing frequency, healing time, and hospitalization time), pain severity, patient comfort, and complications were evaluated and compared. **Results.** The observation group exhibited a higher total effective rate, lower dressing change frequency, complication rate, and shorter healing time and hospital stay than the control group, which are statistically significant. Statistically milder pain sensation and better patient comfort were also determined in the observation group. **Conclusions.** VSD is effective and safe in the treatment of TF-induced sexually transmitted infections, which can effectively accelerate wound recovery while reducing pain sensation and improving patient comfort, with clinical promotion value.

1. Introduction

All infections and injuries of soft tissues are no small challenge for patients and medical staff. Soft-tissue disorders are essentially a manifestation of systemic health that requires proper diagnosis, resuscitation, management, and support [1]. Traumatic fractures (TFs), often accompanied by open injuries, are prone to occur in all kinds of soft tissues in various sports [2–4]. These soft tissue injuries (STIs) can easily lead to the reduction of soft tissue coverage and the destruction of local blood supply that adversely affect fracture healing, resulting in some patients experiencing wound infection and necrosis due to wound contamination [5]. From an ergonomic point of view, the mechanical behavior of the whole tissue will change dramatically if the soft tissue is damaged, which in turn suggests that biomechanical changes caused by STIs can be used to detect the severity of the injury [6, 7]. In any event, all kinds of STIs

must be considered when detecting and treating TFs [8]. Hence, research on the treatment of STIs and wound recovery has important practical value for improving patient outcomes and avoiding wound infection and necrosis.

Vacuum sealing drainage (VSD) has a wide range of applications in wound care as well as clinical treatment at present [9]. In the management of various diseases, including open abdominal wounds, burns, pressure sores, sternal wounds, and obese patients after bariatric surgery, VSD is often used [10, 11]. This technique plays an important role in preventing wound infections of closed incisions as well as surgical site complications [12]. The treatment begins with the construction of a closed, sealing system that applies negative pressure (suction) to the wound surface. The wound is then covered or wrapped with an open-cell foam or gauze dressing and sealed with a sealing cover. And subsequently, intermittent or continuous suction is maintained by connecting a suction pipe from the wound

dressing to a vacuum pump and a waste liquid collector [13]. In this paper, we will explore the curative effect of VSD in treating STIs resulted from TFs and its impact on wound recovery.

2. Methods

2.1. General Information. We selected 90 patients with STIs attributed to TFs admitted from May 2019 to May 2021, 40 of whom received routine treatment and were included in the control group, and the other 50 cases were additionally treated with VSD and used as the observation group. The control and observation groups were not statistically different in general data ($P > 0.05$).

Inclusion criteria were as follows: (1) diagnosis of TFs by the presence of clinical presentations, medical history, computerized tomography (CT) or ultrasound examination, and surgical examination [14]; (2) Gustilo classification type II or III [15]; (3) mentally normal with no history of mental illness; (4) ability to clearly express the discomfort, without communication barrier. Exclusion criteria were as follows: (1) serious primary diseases of heart, liver, kidney, and other VITAL organs; (2) serious diseases of the blood system; (3) history of anti-infection, immunosuppressants, hormones, and other drugs within one month before treatment.

Informed consent was provided by patients or their families, and the study was conducted after obtaining approval from the Hospital Ethics Committee.

2.2. Therapies. The control group received routine treatment. In the emergency operating room, the wound was precleaned with clean water and the necrotic tissue was removed, followed by disinfection with iodophor and hydrogen peroxide. In the case of wound degloving, a sharp knife was used to puncture the mesh for cleaning and disinfection; any foreign bodies in the wound were removed before wound cleaning and disinfection. After debridement, one-stage fracture repair was performed, and an appropriate amount of wound secretions were collected for bacterial culture. Drug sensitivity tests were performed on infected patients, and anti-infection dressings were selected based on the results of bacteria and drug sensitivity culture. Then, appropriate saline and antibiotics mixed with wet gauze were cut, gently applied to the wound surface, and wrapped up with cotton bandages. Dressing change was conducted 1 day later. Thereafter, the dressing was changed every 1–3 days according to the healing condition of the wound until the wound could be closed by second-stage surgery (suturing or skin grafting, skin flap repair, etc.). On this basis, the observation group was treated with VSD. The preoperative treatment, operation, bacterial culture, and drug sensitivity test of patients with primary fracture repair were the same as those of the control group, followed by 75% ethanol disinfection. The VSD dressing was cut according to the size and shape of the wound, and the translucent membrane was pasted to seal the wound (3 cm longer than the VSD dressing). Then the two drainage tubes were connected, one of which maintained VSD negative pressure at

26.6–59.8 kPa, and the other was continuously irrigated with anti-infective drugs +500 mL normal saline according to the results of bacteria and drug sensitivity culture. The dressing was changed once every 5–7 days in patients with turbid drainage fluid and once every 7–10 days in those with clear drainage fluid. The duration of VSD was determined according to the patient's wound size and the infection situation until the second-stage operation can be performed to close the wound (suture or skin grafting, skin flap repair, etc.)

2.3. Measurement Indicators

2.3.1. Rehabilitation. The rehabilitation of the two cohorts of patients, evaluated from dressing change frequency, healing time, and length of hospital stay (LOS), was compared.

2.3.2. Pain Severity and Comfort Status. The pain severity and patient comfort, assessed by the Visual Analog Scale (VAS) and Kolcaba's General Comfort Questionnaire (GCQ) [16, 17], respectively, were counted in both cohorts.

2.3.3. Total Efficiency. The total effective rate was also statistically compared. Evaluation criteria [4] were as follows: cured: the wound healed and the epidermis survived well without the need for dressing changes; effective: obviously reduced wound area, with partially survived skin flap, reduced secretions, but the need for dressing changes; ineffective: little relief of symptoms and signs before and after treatment, with no obvious change in wound surface and secretions. The total effective rate = (cure + effective) cases / the total number of cases in this group $\times 100\%$.

2.3.4. Complication Rate. The incidence of complications (infection, skin necrosis, amyotrophy, and osteomyelitis) was statistically compared.

2.4. Statistics and Methods. SPSS22.0 (Asia Analytics Formerly SPSS China) was employed for synthetic data analysis. Categorical variables ($n(\%)$) were tested using the χ^2 test, and continuous variables ($X \pm S$) were compared by the t -test before and after surgery within the group. $P < 0.05$ was the significance threshold.

3. Results

3.1. General Data. As shown in Table 1, the two cohorts were comparable in gender, age, body mass index (BMI), and other general data ($P > 0.05$).

3.2. Rehabilitation. Comparing patients' postoperative rehabilitation (Figure 1), we can see that the dressing change frequency, healing time, and LOS were significantly less in the observation group than in the control group ($P < 0.05$).

TABLE 1: General data.

Classification	Observation group ($n = 50$)	Control group ($n = 40$)	t/χ^2	P
Sex			0.02	0.887
Male	27 (54.00)	21 (52.50)		
Female	23 (46.00)	19 (47.50)		
Age (years old)	40.12 \pm 5.75	39.08 \pm 6.85	0.78	0.436
BMI (kg/m ²)	20.62 \pm 3.26	20.42 \pm 4.19	0.25	0.800
Gustilo classification			0.24	0.627
II	30 (60.00)	26 (65.00)		
III	20 (40.00)	14 (35.00)		
Site of injury			0.03	0.985
Upper limbs	12 (24.00)	9 (22.50)		
Thigh	28 (56.00)	23 (57.50)		
Lower leg	10 (20.00)	8 (20.00)		
Smoking			0.38	0.538
Yes	40 (80.00)	34 (85.00)		
No	10 (20.00)	6 (15.00)		
Drinking			0.15	0.701
Yes	37 (74.00)	31 (77.50)		
No	13 (26.00)	9 (22.50)		

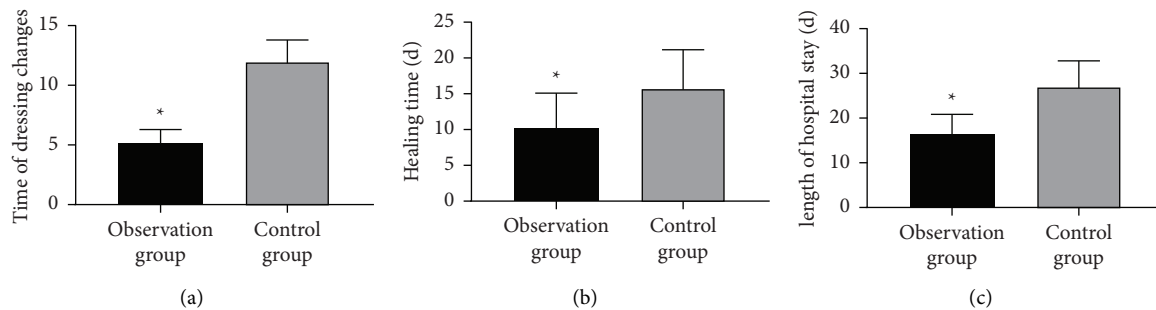


FIGURE 1: Comparison of rehabilitation: (a) times of dressing changes: the observation group had fewer times of dressing changes than the control group ($P < 0.05$); (b) healing time: the observation group had a shorter healing time than the control group ($P < 0.05$); (c) length of hospital stay: the observation group had less length of hospital stay than the control group ($P < 0.05$). Note * means that compared with the control group, $P < 0.05$.

3.3. Pain Severity and Comfort Status. The intergroup comparison (Figure 2) of postoperative pain severity and comfort status revealed obviously alleviated pain and improved patient comfort in both cohorts. And in comparison with controls, the observation group had a lower VAS score and a higher GCQ score ($P < 0.05$).

3.4. Total Effective Rate. Statistics on overall treatment efficacy (Table 2) revealed an evidently higher total effective rate in the observation group ($P < 0.001$).

3.5. Complication Rate. The statistics on postoperative complications (Table 3) identified a higher complication rate in the control group as compared to the observation group ($P < 0.05$).

4. Discussion and Conclusion

Fractures that occur after high-energy trauma are usually accompanied by various intra-articular lesions such as ligamentum teres injury, loose body, cartilage injury, and

trauma of soft tissue like the lip, which can cause ischemic necrosis, post-traumatic osteoarthritis, and even long-term disability in severe cases [18–20]. Therefore, for STIs of TFs, it is necessary to use the correct treatment. In this section, we will study the effectiveness of VSD on TF-induced STIs through various indicators.

This study found significant changes in the postoperative dressing change frequency, healing time, and LOS in both cohorts, with fewer times of dressing changes, and shorter healing time and LOS in the observation group using VSD. VSD has been proven to be effective in treating chronic and complex wounds, with the wound dehiscence rate approximately halved with this technology [21]. VSD renders benefits to various types of surgeries. In breast surgery with easy recurrence and multiple complications, for example, the use of VSD can reduce seroma and its sequelae [22, 23]. As an auxiliary treatment method for open wounds, VSD will apply controllable negative pressure to the wounds through various equipment and professional dressings, and transfer wound liquid to appropriate containers, which can create a wound environment conducive to healing by removing infected materials and exudates, reducing edema, and

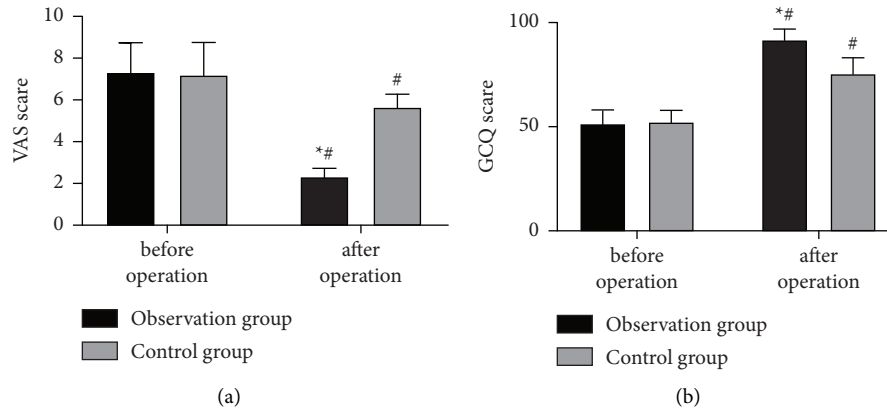


FIGURE 2: Comparison of rehabilitation: (a) VAS score: reduced postoperative VAS scores were observed in both cohorts, with a lower score in the observation group versus the control group ($P < 0.05$); (b) GCQ score: elevated postoperative GCQ scores were determined in both cohorts, with a more significant increase in the observation group compared with the control group ($P < 0.05$). Note * means $P < 0.05$ compared with the control group; # means $P < 0.05$ compared with the postoperative score within the group.

TABLE 2: Total effective rate of two groups of patients.

Classification	Observation group ($n = 50$)	Control group ($n = 40$)	χ^2	P
Cured	25 (50.00)	12 (30.00)	—	—
Effective	23 (46.00)	16 (40.00)	—	—
Ineffective	2 (4.00)	12 (30.00)	—	—
Total effective rate	48 (96.00)	28 (70.00)	11.44	<0.001

TABLE 3: Complications in two groups.

Classification	Observation group ($n = 50$)	Control group ($n = 40$)	χ^2	P
Infection	2 (4.00)	4 (10.00)	—	—
Skin necrosis	1 (2.00)	4 (10.00)	—	—
Amyotrophy	0 (0.00)	2 (5.00)	—	—
Osteomyelitis	0 (0.00)	4 (10.00)	—	—
Incidence of complications (%)	3 (6.00)	14 (35.00)	12.20	<0.001

promoting perfusion and granulation [24, 25]. Therefore, compared with the control group which only used conventional treatment, the wound healing of the observation group was far better with a higher total effective rate because of the use of VSD. Similarly, the complication rate in the observation group was not as high as that in the control group due to the effect of VSD in reducing inflammation and infection. From the above, it is clear that VSD, as an auxiliary treatment method, can greatly improve the wound healing effect and reduce the occurrence of various complications in patients. This has been confirmed in other researchers' analyses. For example, in the study of Cai et al. [26], VSD validly promoted postoperative wound healing in patients with closed calcaneal fractures, shortened the wound healing time, and lowered the incidence of wound complications, which is consistent with our findings. And as reported by Zhang et al. [27], compared with conventional dressing change intervention, orthopedic trauma patients treated with VSD had a higher total effective rate, lower dressing change frequency, and shorter wound healing time with certain security, which contributed to effectively reduced risk of adverse events such as postoperative infections and

lower extremity deep vein thrombosis, similar to the results of our study.

This study also found evidently changed VAS and GCQ scores in both cohorts, with a lower VAS score and a higher GCQ score in the observation group. Consistently, Jiao et al. [28] reported significantly reduced pain severity during dressing change by VSD technique in patients with sural neurocutaneous flap transplantation in the foot and ankle. This technique has also been applied to examine patients with nonspecific hip, knee, and low back pain. Studies have found that associated soft tissues are affected following similar fractures and a range of similar orthopedic diseases [29]. This type of soft tissue defect of the skin in various parts of the body caused by external trauma is very common in clinical treatment [30]. Since some parts of the body (forearm, hand, knee joint, skin, and soft tissue in front of tibia and foot) have thinner skin texture, less subcutaneous tissue, and are located in the exposed parts of the limbs, ineffective repair of any defect will predispose patients to long-lasting pain and abnormal discomfort, which will exert a great impact on patient's mobility and life quality [31–33]. Combined with the results of this study, we can draw

a conclusion that, for patients in the observation group who used VSD, there were faster recoveries and better curative effects, contributing to less pain and discomfort compared with the control group.

This study is unique in that it comprehensively analyzes the clinical efficacy and safety of the VSD technique from multiple aspects such as efficacy, rehabilitation, pain degree, patient comfort, and complications, and confirms its effectiveness in the treatment of patients with TFs and STIs, which provides a new choice for the management of such patients. But it still has room for improvement. This time, we failed to explore patients' postoperative life quality, nor have we investigated their degree of cooperation during the operation and the improvement of psychological state. These survey indicators will be taken into account in future studies to continuously improve the clinical treatment plan.

Taken together, VSD is effective in treating TF-induced STIs, contributing to effectively accelerated wound recovery while ensuring patient safety, which deserves clinical popularization.

Data Availability

The labeled dataset used to support the findings of this study is available from the corresponding author upon request.

Conflicts of Interest

The authors declare that they have no conflicts of interest.

Acknowledgments

The subject in Beilun District people's Hospital and A preliminary study on mechanical analysis of fracture around clavicular hook Ningbo Beilun People's Hospital Fund (2022YJJYB04).

References

- [1] E. J. Onufer, E. G. Andrade, A. DeClue et al., "COVER: a curriculum in the management of soft tissue injury and infection for junior surgery residents," *Journal of Graduate Medical Education*, vol. 13, no. 1, pp. 95–102, 2021.
- [2] S. L. Dalton, Z. Y. Kerr, and T. P. Dompier, "Epidemiology of hamstring strains in 25 NCAA sports in the 2009–2010 to 2013–2014 academic years," *The American Journal of Sports Medicine*, vol. 43, no. 11, pp. 2671–2679, 2015.
- [3] M. C. C. W. Elliott, B. Zarins, J. W. Powell, and C. D. Kenyon, "Hamstring muscle strains in professional football players a 10-year review," *The American Journal of Sports Medicine*, vol. 39, no. 4, pp. 843–850, 2011.
- [4] B. T. Feeley, S. Kennelly, R. P. Barnes et al., "Epidemiology of national football league training camp injuries from 1998 to 2007," *The American Journal of Sports Medicine*, vol. 36, no. 8, pp. 1597–1603, 2008.
- [5] R. T. Li, M. J. Salata, S. Rambhia, J. Sheehan, and J. E. Voos, "Does overexertion correlate with increased injury? The relationship between player workload and soft tissue injury in professional American football players using wearable technology," *Sport Health*, vol. 12, no. 1, pp. 66–73, 2020.
- [6] A. Gefen, N. Gefen, E. Linder-Ganz, and S. S. Margulies, "In vivo muscle stiffening under bone compression promotes deep pressure sores," *Journal of Biomechanical Engineering*, vol. 127, no. 3, pp. 512–524, 2005.
- [7] P. E. Chatzistergos and N. Chockalingam, "An in vivo model for overloading-induced soft tissue injury," *Scientific Reports*, vol. 12, no. 1, p. 6047, 2022.
- [8] N. Hayami, S. Omokawa, A. Iida et al., "Effect of soft tissue injury and ulnar angulation on radial head instability in a Bado type I Monteggia fracture model," *Medicine (Baltimore)*, vol. 98, no. 44, Article ID e17728, 2019.
- [9] Z. Liu, J. C. Dumville, R. J. Hinchliffe et al., "Negative pressure wound therapy for treating foot wounds in people with diabetes mellitus," *Cochrane Database of Systematic Reviews*, vol. 10, no. 10, Article ID CD010318, 2018.
- [10] J. Webster, Z. Liu, G. Norman et al., "Negative pressure wound therapy for surgical wounds healing by primary closure," *Cochrane Database of Systematic Reviews*, vol. 3, no. 3, Article ID CD009261, 2019.
- [11] E. Karabacak, M. Mutluoglu, A. Memis, and H. Ay, "Unexpected wound occurring following negative pressure wound therapy," *International Wound Journal*, vol. 13, no. 2, pp. 289–290, 2016.
- [12] F. E. De Vries, E. D. Wallert, J. S. Solomkin et al., "A systematic review and meta-analysis including GRADE qualification of the risk of surgical site infections after prophylactic negative pressure wound therapy compared with conventional dressings in clean and contaminated surgery," *Medicine*, vol. 95, no. 36, Article ID e4673, 2016.
- [13] A. H. El-Sabbagh, "Negative pressure wound therapy: an update," *Chinese Journal of Traumatology*, vol. 20, no. 2, pp. 103–107, 2017.
- [14] A. Pinto, D. Berritto, A. Russo et al., "Traumatic fractures in adults: missed diagnosis on plain radiographs in the emergency department," *Acta BioMedica*, vol. 89, no. 1–S, pp. 111–123, 2018.
- [15] C. D. Weber, R. Lefering, T. Dienstknecht et al., "Classification of soft-tissue injuries in open femur fractures: relevant for systemic complications?" *Journal of Trauma and Acute Care Surgery*, vol. 81, no. 5, pp. 824–833, 2016.
- [16] F. Jollant, G. Voegeli, N. C. Kordsmeier et al., "A visual analog scale to measure psychological and physical pain: a preliminary validation of the PPP-VAS in two independent samples of depressed patients," *Progress in Neuro-Psychopharmacology and Biological Psychiatry*, vol. 90, pp. 55–61, 2019.
- [17] A. Parseliunas, S. Paskauskas, V. Simatoniene, J. Vaitekunas, and D. Venskutonis, "Adaptation and validation of the carolinas comfort scale: a questionnaire-based cross-sectional study," *Hernia*, vol. 26, no. 3, pp. 735–744, 2022.
- [18] J. C. Mandell, R. A. Marshall, M. B. Banffy, B. Khurana, and M. J. Weaver, "Arthroscopy after traumatic hip dislocation: a systematic review of intra-articular findings, correlation with magnetic resonance imaging and computed tomography, treatments, and outcomes," *Arthroscopy: The Journal of Arthroscopic & Related Surgery*, vol. 34, no. 3, pp. 917–927, 2018.
- [19] A. C. Morris, J. C. Yu, and S. R. Gilbert, "Arthroscopic treatment of traumatic hip dislocations in children and adolescents: a preliminary study," *Journal of Pediatric Orthopaedics*, vol. 37, no. 7, pp. 435–439, 2017.
- [20] M. Zhong, H. Xie, Z. Fu, W. Lu, W. Zhu, and K. Ouyang, "Arthroscopic treatment of acetabular rim fracture after traumatic posterior hip dislocation: a case series study," *Orthopaedic Surgery*, vol. 13, no. 6, pp. 1828–1834, 2021.
- [21] N. N. Semsarzadeh, K. K. Tadisina, J. Maddox, K. Chopra, and D. P. Singh, "Closed incision negative-pressure therapy is

- associated with decreased surgical-site infections: a meta-analysis," *Plastic and Reconstructive Surgery*, vol. 136, no. 3, pp. 592–602, 2015.
- [22] D. Cagney, L. Simmons, D. P. O’Leary et al., “The efficacy of prophylactic negative pressure wound therapy for closed incisions in breast surgery: a systematic review and meta-analysis,” *World Journal of Surgery*, vol. 44, no. 5, pp. 1526–1537, 2020.
- [23] L. De Rooij, S. M. J. van Kuijk, E. R. M. van Haaren et al., “Negative pressure wound therapy does not decrease post-operative wound complications in patients undergoing mastectomy and flap fixation,” *Scientific Reports*, vol. 11, no. 1, p. 9620, 2021.
- [24] I. Chetter, C. Arundel, B. C. Martin et al., “Negative pressure wound therapy versus usual care for surgical wounds healing by secondary intention (SWHSI-2 trial): study protocol for a pragmatic, multicentre, cross surgical specialty, randomised controlled trial,” *Trials*, vol. 22, no. 1, p. 739, 2021.
- [25] J. C. Dumville, G. L. Owens, E. J. Crosbie, F. Peinemann, and Z. Liu, “Negative pressure wound therapy for treating surgical wounds healing by secondary intention,” *Cochrane Database of Systematic Reviews*, no. 6, Article ID CD011278, 2015.
- [26] L. Cai, Y. Mei, C. Chen, J. Wang, X. Wang, and W. Zheng, “Comparison of vacuum sealing drainage and conventional drainage for postoperative drainage in closed calcaneal fracture: a randomized controlled trial,” *Injury*, vol. 53, no. 2, pp. 777–783, 2022.
- [27] L. Zhang, Y. Zhao, Y. Lu et al., “Effects of vacuum sealing drainage to improve the therapeutic effect in patients with orthopedic trauma and to reduce post-operative infection and lower-limb deep venous thrombosis,” *Experimental and Therapeutic Medicine*, vol. 20, no. 3, pp. 2305–2310, 2020.
- [28] J. L. Jiao, E. L. Nu, T. J. Zha, L. H. Liu, Z. Z. Wang, and X. L. Liu, “Application effects of self-made simple vacuum sealing drainage device in postoperative treatment of sural neurocutaneous flap transplantation in the foot and ankle,” *Zhonghua Shao Shang Za Zhi = Zhonghua Shaoshang Zazhi = Chinese Journal of Burns*, vol. 36, no. 8, pp. 718–721, 2020.
- [29] A. P. Yoon, A. L. Mathews, H. E. Huetteman, B. F. Michelotti, and K. C. Chung, “Improving effective magnetic resonance imaging (MRI) application in soft tissue wrist injury,” *The Journal of the American Board of Family Medicine*, vol. 31, no. 5, pp. 795–804, 2018.
- [30] J. Tang, J. He, P. Wu et al., “Repair of skin and soft tissue defects in extremities with the superior lateral genicular artery perforator flap,” *Chinese Journal of Reparative and Reconstructive Surgery*, vol. 33, no. 4, pp. 467–470, 2019.
- [31] L. C. Mangum, G. R. Garcia, K. S. Akers, and J. C. Wenke, “Duration of extremity tourniquet application profoundly impacts soft-tissue antibiotic exposure in a rat model of ischemia-reperfusion injury,” *Injury*, vol. 50, no. 12, pp. 2203–2214, 2019.
- [32] N. van Dyk, F. P. Behan, and R. Whiteley, “Including the Nordic hamstring exercise in injury prevention programmes halves the rate of hamstring injuries: a systematic review and meta-analysis of 8459 athletes,” *British Journal of Sports Medicine*, vol. 53, no. 21, pp. 1362–1370, 2019.
- [33] Y. K. Song, S. H. Kim, and D. I. Jo, “Alcohol intoxication-related soft tissue injuries in patients with orbital wall fractures,” *Journal of Craniofacial Surgery*, vol. 30, no. 7, pp. e646–e649, 2019.