

Primary adrenal sarcomatoid carcinoma

Aftab S. Shaikh,¹ Girish D. Bakhshi,¹
Arshad S. Khan,¹ Nilofar M. Jamadar,²
Aravind Kotresh Nirmala,¹
Arif Ahmed Raza¹

¹Department of Surgery and ²Department of Radiology, Grant Medical College & Sir JJ Group of Hospitals, Mumbai, India

Abstract

Adrenal sarcomatoid carcinomas are extremely rare tumors presenting with extensive locoregional spread at the time of diagnosis. Patients succumb to metastases within a couple of months. As a result, very few cases are reported in the literature until now. We present a case of a 62-year old female with non-functional sarcomatoid carcinoma of the right adrenal gland. There was no radiological evidence of locoregional metastases. Patient underwent right adrenalectomy. Follow up after 3 months showed para-aortic lymphadenopathy and similar left adrenal mass on computed tomography. Patient refused further treatment and succumbed to the disease. A brief case report with review of literature is presented.

Introduction

Patients of sarcomatoid carcinomas of adrenal can present with non-functional adrenal swellings with pressure symptoms by themselves or the result of their metastatic damage to other organs. They can also present as functional adrenal swellings with corresponding endocrine disturbances. Diagnostic modalities include endocrine as well as radiological evaluation of the patient, but the definitive diagnosis is by histopathological and immunohistochemical examination postoperatively after excision.^{1,2} We present a case of sarcomatoid carcinoma of right adrenal gland for which open adrenalectomy was done. However, she succumbed after 4 months as she had developed similar swelling in left adrenal gland along with metastases to para aortic nodes.

Case Report

A 62-year old female presented with complaints of on and off episodes of pain in the right upper quadrant of abdomen since 4

months. It was associated with significant loss of weight and generalized weakness since one month. Clinical examination was unremarkable except for hypertension. Her baseline blood investigations were within normal limits. Ultrasonography of her abdomen suggested enlarged right adrenal gland measuring 4.9×3.3 cm. No obvious calcification was noted. Her urinary vanillyl mandelic acid levels and plasma steroid levels were within normal limits. Computed tomography (CT) scan of abdomen and pelvis suggested 4.3×2.5 cm well defined moderately enhancing right adrenal mass with central necrosis (Figure 1). No calcifications or fat components were seen within the lump. There was no free fluid and no appreciable abdominal lymphadenopathy. Patient underwent ultrasonography guided tissue biopsy of the right adrenal gland. Histopathology suggested it to be tumor composed of spindle cells and permeated by intense inflammatory infiltrate chiefly neutrophils. The tumor cells showed strong immunopositivity for vimentin and focal immunopositivity for epithelial membrane antigen. CT scan of pelvis and thorax was done to search for the primary focus of malignancy but both suggested no obvious focus except patient having a 60% thrombosis of distal arch of aorta. Hence decision was taken for right adrenalectomy. The surgery was completed uneventfully. On gross examination, specimen was brown and nodular measuring 6.5×5.5×3.5 cm and weighed 55 g. Its cut surface showed an unencapsulated firm greyish white tumor (Figure 2). On microscopy the tumor showed pleomorphic tumor cells with epithelial and spindle cell morphology with evidence of foci of necrosis and intense inflammatory infiltrate with neutrophils and lymphocytes (Figure 3). The tumor cells on immunohistochemistry showed strong positivity for vimentin (Figure 4). Focal immunopositivity for pancytokeratin (Figure 5) and Bcl-2. The tumor cells were immunonegative for synaptophysin, chromogranin, melan-A and inhibin and described as sarcomatoid carcinoma of right adrenal gland. Patient refused adjuvant therapy. Follow up after 3 months showed recurrence with involvement of left adrenal and para-aortic nodes on CT scan. Patient refused treatment and succumbed 4 months after the surgery due to metastatic complications.

Discussion

Adrenocortical carcinoma is a rare, heterogeneous malignancy with poor prognosis. It is broadly classified into: i) conventional adrenocortical carcinomas, and ii) adrenocortical carcinoma variants.

Variants of adrenocortical carcinomas

Correspondence: Aftab S. Shaikh, 5/4, Panchsheel, Sir JJ Hospital Campus, Byculla (East), Mumbai-400008, Maharashtra, India.
Tel.: +91.9702129955.
E-mail: docaftabs@gmail.com

Key words: sarcoma, carcinoma, adrenal.

Acknowledgements: our sincere thanks to Padmashree Dr. T.P. Lahane, Dean, Grant Medical College & Sir JJ Group of Hospitals for guiding and permitting us to publish this article.

Contributions: ASS, manuscript concept, draft preparation and revision; GDB, manuscript design and final approval; ASK, AKN, AAR, data acquisition and analysis; NMJ, data and images acquisition and analysis.

Conflict of interests: the authors declare no potential conflict of interests.

Received for publication: 3 September 2013.

Revision received: 31 January 2014.

Accepted for publication: 25 February 2014.

This work is licensed under a Creative Commons Attribution NonCommercial 3.0 License (CC BY-NC 3.0).

©Copyright A.S. Shaikh et al., 2014
Licensee PAGEPress, Italy
Clinics and Practice 2014; 4:604
doi:10.4081/cp.2014.604

include: i) oncocytic adrenocortical neoplasms; ii) myxoid adrenocortical neoplasms; iii) adrenocortical carcinomas with a sarcomatous or sarcoma-like component; iv) adrenocortical blastoma.³

Sarcomatoid carcinoma mainly occurs in men aged more than 60 years. The tumor has been reported in relatively common organs such as the respiratory tract, gastrointestinal tract, and mammary gland.⁴

Sarcomatoid carcinomas of the adrenal glands are extremely rare³ and extremely malignant tumors known with 1 year mortality of 100%. Patients usually present with complaints of vague abdominal pain, abdominal lump in the flanks, loss of weight and generalized weakness. If the tumor is functional patients may present with the corresponding endocrine abnormalities like hypercortisolism causing Cushing's syndrome, hyperaldosteronism causing severe hypertension, muscle cramps, testosterone secretion in women causing deepening of voice, acne, balding, hyperestrogenemia in males causing gynecomastia, impotence and in females causing irregular menses, menorrhagia.^{3,5} In the review of literature, six out of 9 patients diagnosed with sarcomatoid carcinoma of adrenal, presented with flank or abdominal pain or discomfort as in present study. Tumours tend to

be very large at the time of presentation (mean size 13 cm, weight 1113 g) (Table 1).^{3,6-13}

These tumors are notoriously known for their metastasis at the time of presentation and the routes of metastasis include hematogenous, lymphatic or transcoelomic spread.⁵

The tumor cells on microscopy show dual line of differentiation into mesenchymal (sarcomatous) and epithelial (carcinomatous) elements. The mesenchymal differentiation may be towards muscle (rhabdomyosarcoma), bone (osteosarcoma), fibrosarcoma etc. or just undifferentiated spindle cell type. Of these the differentiation towards rhabdomyosarcoma is common. There are many theories proposed to explain the dual line of differentiation of these tumors. They are: i) the composition tumor theory (paradoxically requiring a non-malignant non-epithelial component as a reactive proliferative response induced by the epithelial component via paracrine secretion); ii) the collision or bichloral tumor theory (a collision between two synchronous, histogenetically independent, bichloral tumors); iii) the conversion tumor theory (neoplastic transformation within a monoclonal tumor recapitulating the naturally occurring event of conversion of epithelial to mesenchymal cells during embryogenesis);⁵ and iv) the combination or divergent tumor theory (deriving from a common monoclonal stem cell precursor),^{14,15} molecular genetic evidence of monoclonality supports the single pluripotential stem-cell-divergence hypothesis and the epithelial-to-mesenchymal transition as well.¹⁵ Adrenal cortical carcinosarcomas tend to be aggressive tumours, with locoregional recurrence and rapid metastases from sarcomatoid component.¹⁶

Management includes early diagnosis as the tumor is 100% malignant. Endocrine assays and CT are the modalities available to diagnose as well as to rule out primary focus from elsewhere. CT is a reliable modality for detecting tumors in the adrenal gland. Dynamic enhanced scan with multi-detector row CT may show the compositions and the blood supply of a tumor.⁴ CT scan shows heterogenous enhancement which may raise the suspicion of sarcoma, however further studies are required to confirm. Definitive diagnosis rests with histopathology and immunohistochemistry. At present the best available treatment option is surgical excision of the tumor with clearance of metastasis. In radical resection, the tumour, surrounding adipose tissue and lymph nodes must be removed.¹⁷ Doxorubicin based chemotherapy has been used.^{3,4} However more studies are required to establish a definitive line of treatment. Adrenal sarcomatoid carcinoma

seems to be a highly malignant tumour and has very poor prognosis. Almost no patient survives more than a year. Most patients die of local recurrence or metastases.¹⁷

Conclusions

Adrenal sarcomatoid carcinomas even though are operable on early presentation, may present with metastases quite early and be fatal. Hence, regular follow up is required in postoperative course.

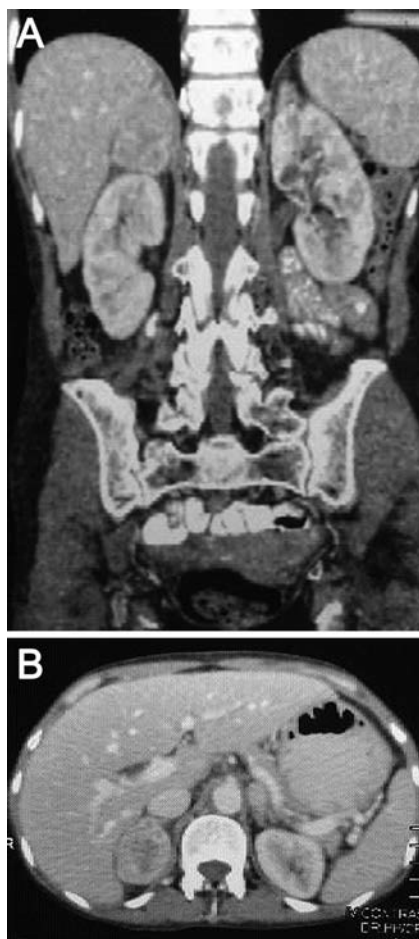


Figure 1. A and B) Computed tomographic images non-enhancing right adrenal gland abutting the inferior surface of the liver without calcification.

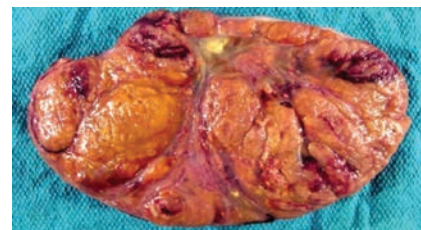


Figure 2. Gross appearance of the right adrenalectomy specimen showing nodularity.

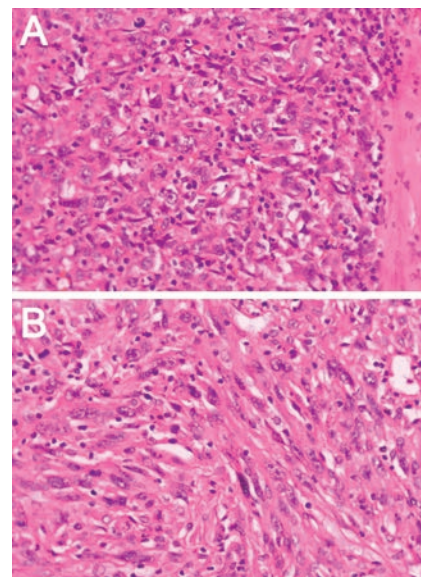


Figure 3. Histopathological pictures showing both epithelial and sarcomatous components. A) Hematoxylin and eosin stain (10x); B) hematoxylin and eosin stain (40x).

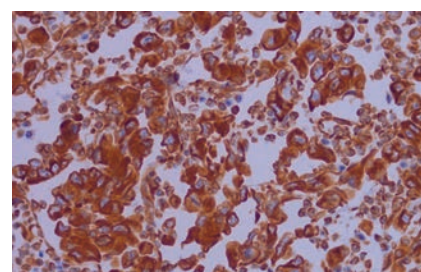


Figure 4. Immunohistochemistry showing positive for vimentin.

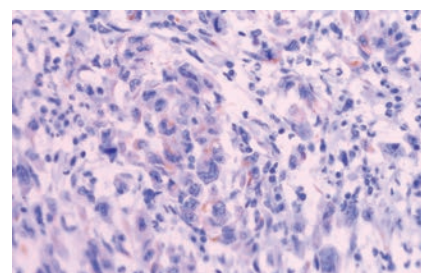


Figure 5. Immunohistochemistry showing positive for pancytokeratin.

Table 1. Comparison between the present study and nine patients diagnosed with sarcomatoid carcinoma of adrenal, presented in literature.

Author	Age	Sex	Clinical presentation	Endocrine dysfunction	Size (cm)	Sarcomatous component	Post-operative time of death
Okazumi <i>et al.</i> ⁶	46	M	Abdominal distention	No	14	Spindle	6 months
Collina <i>et al.</i> ³	68	F	Abdominal discomfort	No	11	Spindle	6 months
Decorato <i>et al.</i> ⁷	42	F	Abdominal pain	No	19	Rhabdomyosarcoma	7 months
Fischler <i>et al.</i> ⁸	29	F	Virilization, weight loss	Yes	12.5	Rhabdomyosarcoma	8 months
Barksdale <i>et al.</i> ⁹	79	F	Hypertension	Yes	5	Osteosarcomachondrosarcoma	NA
Lee <i>et al.</i> ¹⁰	61	M	Flank pain	No	12	Spindle	2 days
Sturm <i>et al.</i> ¹¹	31	M	Abdominal pain	No	12	Spindle	3 months
Coli <i>et al.</i> ¹²	75	F	Abdominal pain	No	15	Spindle	12 months
Sasaki <i>et al.</i> ¹³	45	M	Abdominal pain	No	17	Rhabdomyosarcoma	3 months
Present study	62	F	Abdominal pain	No	6.5	Spindle	3 months

NA, not available.

References

- de Krijger RR, Papathomas TG. Adrenocortical neoplasia: evolving concepts in tumorigenesis with an emphasis on adrenal cortical carcinoma variants. *Virchows Arch* 2012;460:9-18.
- Leventon GS, Evans HL. Sarcomatoid squamous cell carcinoma of the mucous membranes of the head and neck: a clinicopathologic study of 20 cases. *Cancer* 1981; 48:994-1003.
- Collina G, Maldarizzi F, Betts CM, Eusebi V. Primary sarcomatoid carcinoma of the adrenal gland. First case report. *Virchows Arch A Pathol Anat Histopathol* 1989;415:161-7.
- Thiery JP, Acloque H, Huang RY, Nieto MA. Epithelial-mesenchymal transitions in development and disease. *Cell* 2012;139; 3471-86.
- Jin Z, Ogata S, Tamura G, et al. Carcinosarcomas (malignant mullerian mixed tumors) of the uterus and ovary: a genetic study with special reference to histogenesis. *Int J Gynecol Pathol* 2003;22:368-73.
- Okazumi S, Asano T, Ryu M, et al. Surgical resection of adrenal carcinoma extending into the vena cava, right atrium and ventricle: case report and review of the literature. *Nippon Geka Gakkai Zasshi* 1987;88: 231-38.
- Decorato JW, Gruber H, Petti M, Levowitz BS. Adrenal carcinosarcoma. *J Surg Oncol* 1990;45:134-6.
- Fischler DF, Nunez C, Levin HS, et al. Adrenal carcinosarcoma presenting in a woman with clinical signs of virilization. A case report with immunohistochemical and ultrastructural findings. *Am J Surg Pathol* 1992;16:626-31.
- Barksdale SK, Marincola FM, Jaffe G. Carcinosarcoma of the adrenal cortex presenting with mineralocorticoid excess. *Am J Surg Pathol* 1993;17:941-5.
- Lee MS, Park IA, Chi JG, et al. Adrenal carcinosarcoma. A case report. *J Korean Med Sci* 1997;12:374-7.
- Sturm N, Moulai N, Laverrière M-H, et al. Primary adrenocortical sarcomatoid carcinoma: case report and review of literature. *Virchows Archiv* 2008;452:215-9.
- Coli A, Giorgio A, Castri F, et al. Sarcomatoid carcinoma of the adrenal gland: a case report and review of literature. *Pathol Res Pract* 2010;206:59-65.
- Sasaki K, Desimone M, Rao HR, et al. Adrenocortical carcinosarcoma a case report and review of literature. *Diagn Pathol* 2010;5:51.
- Thompson L, Chang B, Barsky SH. Monoclonal origins of malignant mixed tumors (carcinosarcoma). Evidence for a divergent histogenesis. *Am J Surg Pathol* 1996;20:277-85.
- Feng Y-C, Yang Z-G, Chen T-W, et al. Adrenal sarcomatoid carcinoma: a rare case depicted on multi-detector row computed tomography. *Indian J Med Sci* 2010; 64:37-40.
- Thway K, Olmos D, Shah C, et al. Oncocytic adrenal cortical carcinosarcoma with pleomorphic rhabdomyosarcomatous metastases. *Am J Surg Pathol* 2012;36:470-7.
- Yan JJ, Sun AJ, Ren Y, Hou C. Primary adrenocortical sarcomatoid carcinoma: report of a case. *Can Urol Assoc J* 2012;6: E189-91.