

# Endovascular stenting and coil embolization for management of radiation-induced pseudoaneurysms of the peripheral arteries

Hai-yang Chang<sup>1,2</sup>, Zhen-guo Liu<sup>3</sup>,  
Yu-Liang Li<sup>1,2</sup>, Bin Liu<sup>1,2</sup>, Wu-Jie Wang<sup>1,2</sup>,  
Wei Wang<sup>1,2</sup> and Yong-Zheng Wang<sup>1,2</sup> 

## Abstract

**Objective:** This study was performed to evaluate the safety and efficacy of endovascular stenting and embolization for the management of radiation-induced peripheral arterial pseudoaneurysms.

**Methods:** Twelve consecutive patients with radiation-induced peripheral arterial pseudoaneurysms (diameter of 10–30 mm and mean size of 20.42 mm) were admitted to our hospital from 1 January 2015 to 31 October 2019. The patients' baseline characteristics, perioperative parameters, device characteristics, and curative effects were systematically recorded and analyzed.

**Results:** The 12 patients comprised 3 men and 9 women with a mean age of  $62.90 \pm 13.97$  years. The iliac artery was the most commonly involved artery, followed by the subclavian artery. In all patients, the pseudoaneurysms were detected by enhanced computed tomography. Twelve covered stents were deployed (7 or 8 mm in diameter and 50 mm in length). Additional coil embolization was performed in three patients (Patients 8, 9, and 10). The primary and secondary technical success rate was 91.7% and 100%, respectively. Apart from one death caused by rebleeding, no patients developed rebleeding during follow-up.

**Conclusion:** Endovascular stenting and coil embolization are feasible and effective for the management of radiation-induced peripheral arterial pseudoaneurysms in highly selected patients.

<sup>1</sup>Department of Interventional Medicine, the Second Hospital, Cheeloo College of Medicine, Shandong University, Jinan, Shandong Province, People's Republic of China

<sup>2</sup>Interventional Oncology Institute of Shandong University, Jinan, Shandong Province, People's Republic of China

<sup>3</sup>Department of Oncology, Gaoqing People's Hospital, Gaoqing, Shandong Province, People's Republic of China

## Corresponding author:

Yongzheng Wang, Department of Interventional Medicine, the Second Hospital, Cheeloo College of Medicine, Shandong University, 247 Beiyuan Road, Jinan, Shandong Province 250033, China.

Email: wyzwx911@sohu.com



## Keywords

Endovascular therapy, stent graft, radiation-induced pseudoaneurysm, radiotherapy, coil embolization, efficacy, safety, rebleeding

Date received: 5 June 2020; accepted: 8 December 2020

## Introduction

Pseudoaneurysms are localized arterial lesions that communicate with the parent artery by external walls composed of perivascular tissue or blood clots rather than the three layers of the arterial wall.<sup>1</sup> According to previous literature, the most widely observed causes of pseudoaneurysms are intravenous drug abuse, trauma, intragenesis, tumors, infection, and atherosclerosis.<sup>2,3</sup> Most pseudoaneurysms involve the femoral arteries. Although many imaging modalities are employed for the diagnosis of pseudoaneurysms, duplex ultrasonography remains the most commonly used initial investigation because of its low cost, wide availability and accessibility, and reproducibility. Peripheral arterial pseudoaneurysms are usually managed through several complicated techniques, including ultrasound-guided compression, ultrasound-guided thrombin injection, surgery, and endovascular approaches.<sup>1</sup> The treatment strategy varies depending on the segment of the involved artery and the presence of infection. Endovascular therapy provides good control of bleeding and has become a preferred technique for preserving the patency of the involved artery.<sup>3</sup>

Radiotherapy has been considered an alternative to surgery and chemotherapy for the management of malignancies. A radiation-induced pseudoaneurysm is a rarer complication than stenosis or occlusion of the peripheral artery.<sup>4,5</sup> Throughout the history of surgery and radiotherapy, the performance of bypass

or ligation via open surgery in these patients has been unfavorable. In this regard, endovascular repair consisting of coil or glue embolization and deployment of covered stents was introduced to treat radiation-induced peripheral arterial pseudoaneurysms.<sup>2,5-8</sup> Lam et al.<sup>9</sup> reported that 23 patients with radiation-induced pseudoaneurysms of the internal carotid artery underwent endovascular therapy and that 20 of these patients achieved successful control of hemorrhage. Radiation-induced pseudoaneurysms of peripheral arteries are rare but life-threatening complications because of the high risk of massive bleeding and the extreme difficulty of open surgery. Therefore, endovascular repair with covered stents may serve as an alternative to open surgery. In this study, we evaluated the safety and efficacy of endovascular stenting and coil embolization for the management of radiation-induced pseudoaneurysms of the peripheral arteries.

## Methods

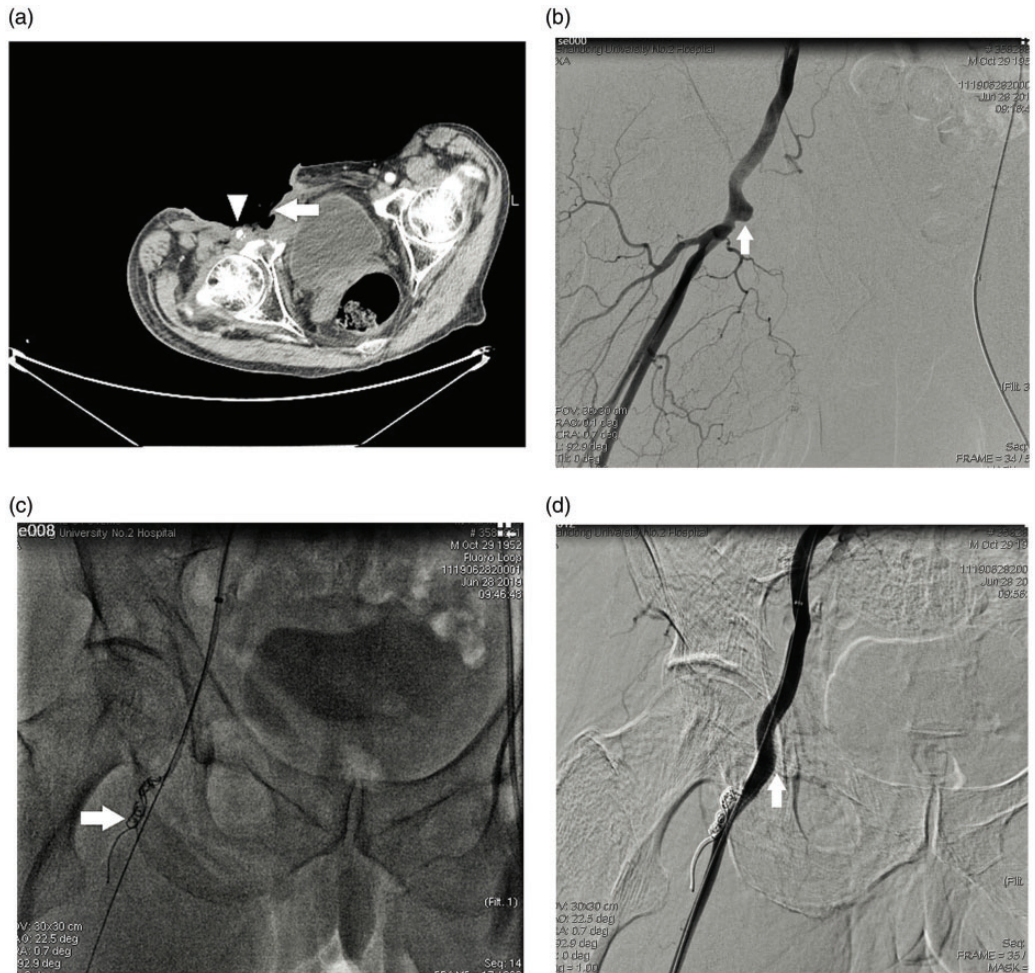
### *Patient enrollment and definitions*

The single-center retrospective study was approved by the ethics committee of our institution, and the requirement for written informed consent was waived. Twelve consecutive patients with radiation-induced pseudoaneurysms of the peripheral arteries and resultant massive bleeding were admitted to our hospital from 1 January 2015 to 31 October 2019. All patients had a history

of radiotherapy for treatment of malignancies. The iliac artery, including the external and internal branches, was the most commonly involved artery (50.0%), followed by the subclavian artery (41.7%); the common femoral artery was affected in one patient. Endovascular stenting and coil embolization were performed to manage life-threatening bleeding. The patients' medical

records and imaging findings were reviewed. The patients' baseline characteristics, perioperative parameters, device characteristics, and outcomes were examined in detail.

Patients with the following clinical and imaging characteristics (Figure 1(a)) were considered to have radiation-induced pseudoaneurysms of the peripheral arteries.



**Figure 1.** Images of a 66-year-old man with carcinoma of the penis. (a) Enhanced computed tomography revealed skin and tissue necrosis with the formation of an ulceration (arrow) involving the right common femoral artery (arrowhead). (b) Pre-stenting angiogram showed a saccular aneurysm of the right common femoral artery without extravasation of contrast material (arrow). (c) Embolization of the femoral profunda artery using coils was performed to prevent endoleakage (arrow). (d) Post-stenting angiogram showed complete exclusion of the pseudoaneurysm (arrow) with a patent common femoral artery.

Performance of endovascular therapy with a covered stent was taken into account.

- a. Diagnosis of a malignancy with a history of radiotherapy
- b. Symptoms consisting of pain, neuralgia, or edema caused by compression, distal embolization, skin or tissue necrosis, or artery rupture
- c. No recurrence of malignancies or infection
- d. A requirement to preserve the parent artery

Primary technical success was defined as complete exclusion of the pseudoaneurysm with the absence of extravasation of contrast agent on angiography and no development of severe complications. Secondary technical success was defined as reintervention with achievement of the criteria required for primary technical success. Follow-up of the patients, including clinical assessment, physical examination, laboratory testing, and imaging evaluation, was performed 1 month after the procedure and every 3 months thereafter.

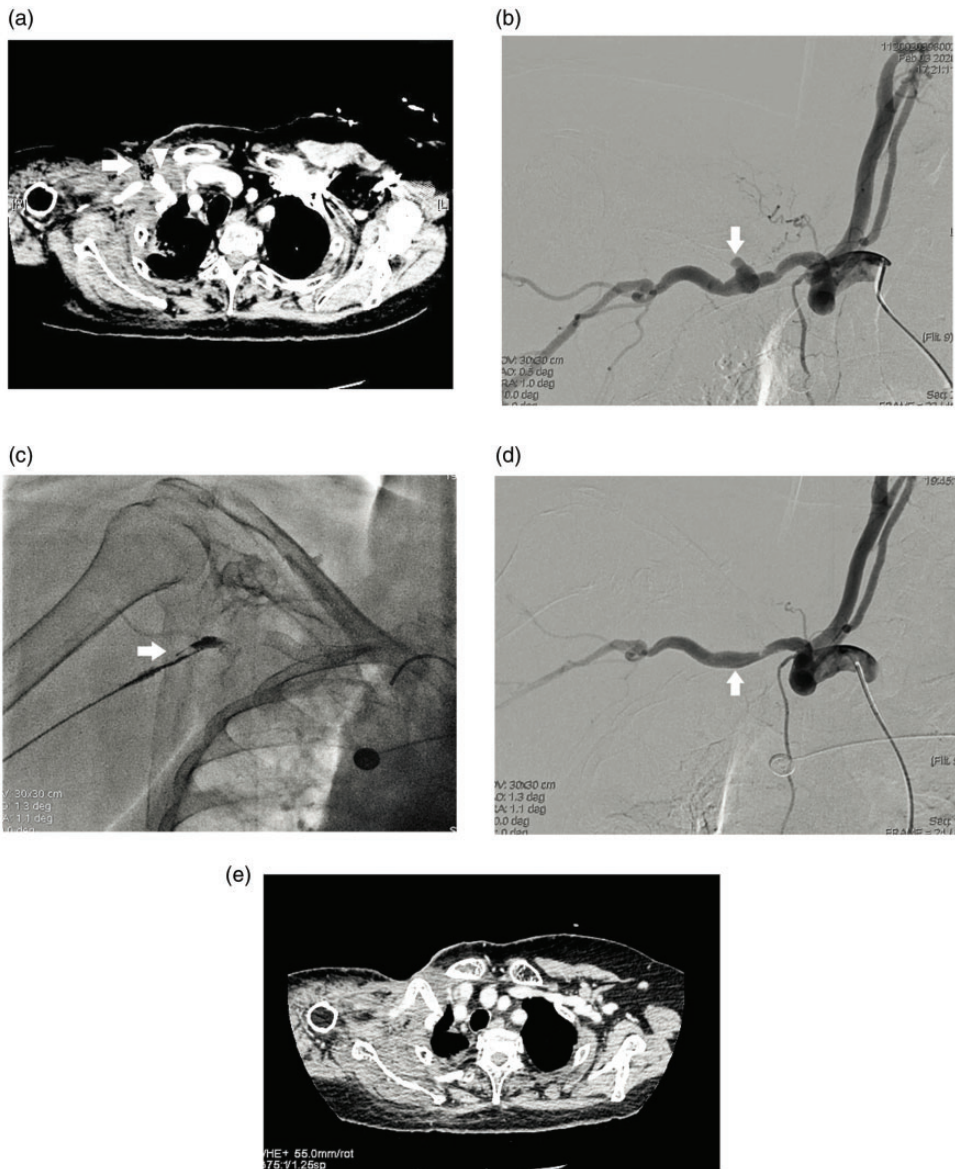
### *Endovascular procedure*

All procedures were performed in a hybrid unit under local anesthesia and fluoroscopic monitoring. To exclude the effects of fluctuation from operation-related factors, two operators with more than 20 years of extensive experience in the endovascular treatment of peripheral artery disorders carried out the procedures.

Typically, the common femoral artery was used as an access site for deployment of the stents. After intravenous administration of heparin (80 U/kg), a pigtail catheter (Cook Medical, Bloomington, IL, USA) was advanced into the aorta via a sheath (Terumo Corporation, Tokyo, Japan) positioned in the femoral artery. Aortography was then performed to confirm the ostium of the parent artery. Along with a

stiff-angled guidewire (Terumo Corporation), the parent artery was screened and selected via a VERT catheter (Cordis Corporation, Santa Clara, CA, USA). An angiogram with the indication of a swirl pattern in the pseudoaneurysm was obtained (Figure 1(b)). An 8-Fr sheath (Cook Medical) was exchanged and advanced immediately proximal to the pseudoaneurysm. With the assistance of a 5-Fr multipurpose catheter (Cordis Corporation), an 0.035-inch extra-stiff guidewire (Cook Medical) was advanced distal to the pseudoaneurysm in the parent artery. A Viabahn stent graft (5/7/8 mm in diameter, 50 mm in length; W.L. Gore, Flagstaff, AZ, USA) was introduced through the sheath and deployed to exclude the pseudoaneurysm sac. The sheath was withdrawn for precise deployment of the covered stent. Positive re-expansion of the stent was detected in all patients, and no further post-dilation was necessary. In addition, assistant techniques using coil (Cook Medical) embolization were performed in three patients (Figure 1(c)). Repeat angiography confirmed complete exclusion of the pseudoaneurysms and brisk perfusion to the ipsilateral upper or lower extremities (Figure 1(d)). The patients were observed in the intensive care unit overnight. Low-molecular-weight heparin (5000 U once daily) was administered for 3 days after the procedure, and clopidogrel (75 mg daily) was then used for the following 6 months. An angiogram after deployment of the covered stent showed distal embolization in one patient with a pseudoaneurysm involving the right subclavian artery (Figure 2(a)–(c)). Thrombus aspiration using a 6-Fr guiding catheter was performed, and a subsequent angiogram demonstrated brisk perfusion (Figure 2(d)). As shown in Figure 2(e), computed tomography angiography showed patency of the right subclavian artery and the covered stent 3 months after the procedure.





**Figure 2.** Images of a 71-year-old woman with breast cancer. (a) Computed tomography with enhancement showed skin ulceration (arrow) and a saccular aneurysm (arrowhead) involving the right subclavian artery. (b) Angiography revealed a pseudoaneurysm of the right subclavian artery (arrow). (c) Distal embolization was detected after deployment of a covered stent graft (arrow). (d) Post-stenting angiogram showed complete exclusion of the pseudoaneurysm sac (arrow) with a patent subclavian artery. (e) Repeat computed tomography angiography demonstrated patency of the covered stent 3 months after the procedure.

### Statistical analysis

Categorical variables are presented as number and proportion. Continuous variables are expressed as mean  $\pm$  standard deviation and were compared using Student's *t*-test. All statistical analyses were performed using IBM SPSS Statistics for Windows, Version 19.0 (IBM Corp., Armonk, NY, USA). A P-value of  $<0.05$  was considered statistically significant.

## Results

### Patients' baseline characteristics

Table 1 shows the baseline characteristics of the patients as abstracted from the medical records. This study involved 12 patients (3 men, 9 women; mean age,  $62.90 \pm 13.97$  years) with radiation-induced pseudoaneurysms (10–30 mm in diameter; mean diameter, 20.42 mm) of the peripheral arteries. Before admission to our hospital, all patients had developed active bleeding, and peripheral arterial pseudoaneurysms were detected by computed tomography angiography. For patients with suspected recurrence of malignancy, percutaneous biopsies were performed with negative results. No evidence of infection was detected in any patient. Therefore, all pseudoaneurysms of the peripheral arteries were considered to be radiation-induced. Moreover, three patients had a history of hypertension and two patients had coronary artery disease. The primary malignancies comprised uterine cervical cancer ( $n=4$ ), breast cancer ( $n=3$ ), rectal cancer ( $n=2$ ), non-small cell lung cancer ( $n=1$ ), invasive thymoma ( $n=1$ ), and carcinoma of the penis ( $n=1$ ). The iliac artery, including the external and internal branches, was the most commonly involved artery (50.0%), followed by the subclavian artery (41.7%). The mean duration from radiation

therapy to the onset of the pseudoaneurysm was  $32.75 \pm 9.14$  months.

### Perioperative parameters and device characteristics

The patients' perioperative parameters and device characteristics are listed in Table 2. All procedures were performed under local anesthesia and fluoroscopic monitoring in a hybrid unit. A saccular aneurysm was detected in all patients, and angiography showed massive extravasation of the contrast agent from the parent arteries in eight patients. Endovascular repair with an assistant technique tended to consume more time than endovascular repair with deployment of a covered stent only ( $108.75 \pm 16.52$  vs.  $98.13 \pm 19.07$  minutes, respectively). The duration of the procedure in patients with involvement of an artery of the upper extremity and lower extremity was not significantly different at  $105.00 \pm 12.75$  and  $99.29 \pm 22.07$  minutes, respectively. In total, 12 covered stents were deployed (7 or 8 mm in diameter, 50 mm in length). Coil embolization was further performed in three patients. Angiography after deployment of the covered stent showed distal embolization in one patient with a pseudoaneurysm involving the right subclavian artery. Thrombus aspiration using a 6-Fr guiding catheter was performed, and the subsequent angiogram demonstrated brisk perfusion.

### Efficacy and follow-up

As shown in Table 3, successful control of bleeding was achieved in 11 patients. One patient with a pseudoaneurysm of the right internal iliac artery, in whom transarterial embolization using coils had been preperformed, developed rebleeding 7 days after embolization. The ostium of the internal iliac artery was covered with a Viabahn stent graft during reintervention.

**Table 1.** Patients' baseline characteristics.

Patient No.	Age, years	Sex	Comorbidities	Primary tumor	Diameter, mm	Peripheral artery	Symptoms	Time to bleeding, months
1	66	M	HTN, CAD	Carcinoma of the penis	10 × 20	Rt CFA	Skin ulceration, bleeding	40
2	71	F	HTN	Breast cancer	15 × 25	Rt SA	Skin necrosis, bleeding, swelling	55
3	72	F	HTN	Uterine cervical cancer	15 × 30	Rt EIA	Active vaginal bleeding	20
4	32	F	-	Uterine cervical cancer	10 × 30	Rt IIA	Active vaginal bleeding	30
5	75	F	CAD	Breast cancer	10 × 15	Rt SA	Skin necrosis, bleeding, swelling	35
6	71	F	-	Breast cancer	15 × 20	Rt SA	Skin necrosis, bleeding, swelling	33
7	52	F	-	Adenocarcinoma of the uterine cervix	20 × 30	Rt EIA	Active vaginal bleeding	30
8	83	M	HTN	Rectal carcinoma	25 × 30	Lt IIA	Anemia, hematochezia	36
9	48	M	-	Rectal carcinoma	15 × 20	Rt IIA	Anemia, hematochezia	24
10	68	F	-	Invasive thymoma	25 × 25	Rt SA	Skin ulceration, bleeding, swelling	28
11	61	F	-	NSCLC	15 × 20	Lt SA	Skin ulceration, bleeding, swelling	37
12	56	F	-	Cervical squamous cell carcinoma	20 × 30	Rt IIA	Active vaginal bleeding	25

M, male; F, female; HTN, hypertension; CAD, coronary artery disease; DM, diabetes mellitus; NSCLC, non-small cell lung cancer; CFA, common femoral artery; SA, subclavian artery; EIA, external iliac artery; IIA, internal iliac artery; BA, brachiocephalic artery; Rt, right; Lt, left.

**Table 2.** Perioperative parameters and device characteristics.

Patient No.	Duration of procedure, min	Manifestation of angiography	Free from general anesthesia	Estimated blood loss, mL	Intraoperative adverse events	Parameters of device, mm
1	90	PSA	Yes	15	None	Viabahn, 8 mm × 50 mm, TAE (IMWCE, 5 mm × 50 mm/5 mm × 30 mm)
2	125	PSA,	Yes	500	Distal embolization	Viabahn, 7 mm × 50 mm
3	110	PSA, CE	Yes	500	None	Viabahn, 8 mm × 50 mm
4	125	PSA, CE	Yes	800	None	Viabahn, 8 mm × 50 mm, TAE (Interlock, 10 mm × 30 cm)
5	95	PSA, CE	Yes	600	None	Viabahn, 8 mm × 50 mm
6	100	PSA	Yes	20	None	Viabahn, 7 mm × 50 mm
7	90	PSA	Yes	30	None	Viabahn, 8 mm × 50 mm
8	120	PSA, CE	Yes	400	None	Viabahn, 8 mm × 50 mm, TAE (Interlock, 8 mm × 30 cm)
9	100	PSA, CE	Yes	300	None	TAE (Interlock, 8 mm × 30 cm/10 mm × 30 cm) Viabahn, 8 mm × 50 mm
10	95	PSA	Yes	20	None	Viabahn, 8 mm × 50 mm
11	110	PSA, CE	Yes	200	None	Viabahn, 8 mm × 50 mm
12	60	PSA, CE	Yes	500	None	Viabahn, 7 mm × 50 mm

PSA, pseudoaneurysm; CE, contrast extravasation; TAE, transarterial embolization.

No extravasation of contrast was revealed on the postprocedural angiogram. The primary and secondary technical success rate was 91.7% and 100%, respectively. Mild transient pelvic pain was encountered in one patient without the need for reintervention. Prophylactic antibiotics and low-molecular-weight heparin (5000 U once daily) were administered for 3 days after the procedure in all patients. Clopidogrel (75 mg daily) was subsequently used in nine patients. Antiplatelet therapy was not administered to Patients 5 and 8 because of their high risk of bleeding according to the CRUSADE model. During a mean follow-up of  $9.50 \pm 2.81$  months, sudden death unrelated to the pseudoaneurysm occurred in one patient (Patient 8). Another patient (Patient 2) died of rebleeding 3 months after the procedure, but none of the remaining patients developed rebleeding during follow-up. However, six patients (Patients

1, 4, 5, 7, 10, and 11) died of disease progression during follow-up.

## Discussion

In this study, 12 patients with radiation-induced peripheral arterial pseudoaneurysms underwent endovascular repair using covered stents, and 3 patients further underwent coil embolization as an assistant technique. A minor complication (distal embolization) occurred in one patient during this procedure and was resolved by transcatheter aspiration. Therefore, this technique has great potential to become a safe and effective treatment for controlling bleeding in this subgroup of patients with a primary technical success rate of 91.7% and a secondary technical success rate of 100%. Clinicians should be aware of the potential need for an assistant technique and reintervention during the procedure and follow-up. Involvement of large vessels surrounded



**Table 3.** Efficacy and outcomes.

Patient No.	Hospitalization duration, days	Complications within 30 days	Requirement for reintervention	Control of bleeding within 30 days	Medication during follow-up	Survival (months) / cause of death
1	24	None	None	Yes	Clopidogrel 75 mg/day	10/disease progression
2	9	Distal embolization	Thrombus aspiration	Yes	Clopidogrel 75 mg/day	3/rebleeding
3	20	None	None	Yes	Clopidogrel 75 mg/day	13/alive
4	17	None	None	Yes	Clopidogrel 75 mg/day	10/disease progression
5	15	None	None	Yes	None	7/disease progression
6	21	None	None	Yes	Clopidogrel 75 mg/day	10/alive
7	23	None	None	Yes	Clopidogrel 75 mg/day	10/disease progression
8	25	Mild pelvic pain	None	Yes	None	7/sudden death
9	30	Rebleeding	Deployment of Viabahn	No	Clopidogrel 75 mg/day	13/alive
10	25	None	None	Yes	Clopidogrel 75 mg/day	7/disease progression
11	18	None	None	Yes	Clopidogrel 75 mg/day	10/disease progression
12	21	None	None	Yes	Clopidogrel 75 mg/day	13/alive

by necrosis and fibrosis and patients' unstable condition due to active bleeding cause open surgery to have a limited role in the management of these patients.

Although the incidence of peripheral artery pseudoaneurysm is rare, the risk of mortality is remarkably high because of massive hemorrhage when these pseudoaneurysms rupture. In most patients, rupture is induced by trauma, iatrogenesis, arteriosclerosis, inflammation, and mycotic infection.<sup>1-3</sup> Luther et al.<sup>3</sup> reported that peripheral arterial aneurysms are common in Northern India and that the most common etiology is intravenous drug abuse, followed by trauma. The presentations include a pulsatile mass, pain, edema or neuralgia caused by compression, distal embolization, and active bleeding. For diagnosis of pseudoaneurysms, duplex ultrasonography is preferred with a sensitivity of 94% and specificity 97% for symptomatic patients.<sup>1</sup> Indications for management include rapid enlargement, pain, neuralgia or edema caused by compression, distal embolization, infection, skin or tissue necrosis, and artery rupture.<sup>2,6,9,10</sup> More aggressive surveillance and intervention should be considered for asymptomatic pseudoaneurysms of >2 cm.<sup>1</sup>

Hall et al.<sup>1</sup> indicated that surgical repair should be considered for patients with pseudoaneurysms caused by previous vascular interventions, infections, and no iatrogenesis. Urgent surgery should be performed in patients with ruptured pseudoaneurysms, an expanding mass, and compression of surrounding structures causing neuralgia and critical extremity ischemia.<sup>1</sup> In the above-mentioned study by Luther et al.,<sup>3</sup> 50 patients who had peripheral arterial pseudoaneurysms with various presentations and etiologies underwent surgical treatment, and uneventful recovery was achieved in 33 patients.<sup>3</sup> Furlough et al.<sup>11</sup> performed 57 peripheral reconstructions using cryopreserved arterial allografts

with a mortality of 8% within 30 days. The authors suggested that a cryopreserved arterial allograft might be a useful alternative conduit for peripheral arterial pseudoaneurysms.<sup>11</sup> In another study, ultrasound-guided compression repair was introduced as a less invasive approach to manage peripheral artery pseudoaneurysms in 21 patients, and successful thrombosis of the pseudoaneurysm sac was achieved in 19 of the patients.<sup>12</sup>

Radiotherapy causes DNA damage, which leads to growth inhibition followed by cellular death or apoptosis. This treatment is regularly performed as part of cancer management.<sup>13</sup> However, radiation can induce undesirable complications involving radiosensitive structures close to the malignancies. Radiation-induced vascular lesions tend to be characterized by either stenosis or occlusion; a pseudoaneurysm of the peripheral artery is a rare complication.<sup>7</sup> Such pseudoaneurysms can involve the internal or external carotid artery, brachiocephalic artery, hepatic artery, or internal or external iliac artery according to previous reports.<sup>2,7,8,14</sup>

To our knowledge, randomized data with which to guide the management of radiation-induced pseudoaneurysms of peripheral arteries are lacking; most data are derived from case series. According to published reports, endovascular repair of radiation-induced pseudoaneurysms using coil embolization or covered stents seemed to be a viable and less invasive alternative, especially in life-threatening cases.<sup>6,7,10,15</sup> Several case reports have confirmed the feasibility and efficacy of endovascular management to control bleeding caused by radiation-induced pseudoaneurysms.<sup>4,6,16,17</sup> Lam et al.<sup>9</sup> reported that among 23 patients with radiation-induced pseudoaneurysms of the internal carotid artery who underwent endovascular repair, the technical success rate was 87%, and 18 patients survived throughout follow-up. Chen et al.<sup>15</sup>

**Table 4.** Previous studies.

Authors	Patients, n	Primary tumor	Endovascular technique	Adverse events	Follow-up outcome
Huang et al. <sup>2</sup>	1	Cervical squamous cell carcinoma	SG	None	None
Salaskar et al. <sup>6</sup>	1	Rectal adenocarcinoma	Coil and Gelfoam embolization	None	Asymptomatic for 3 years
Chen et al. <sup>15</sup>	6	Cervical cancer	Coil/PVA/NBCA embolization in all patients; SG in Patients 5 and 6	Mild transient pelvic pain	Patient 1: 3.5 months/disease progression Patient 2: 10.5 months/disease progression Patient 3: 34 months/alive Patient 4: 5 months/disease progression Patient 5: 3 months/bleeding Patient 6: 2.5 months/disease progression
Watarida et al. <sup>18</sup>	1	Adenocarcinoma of the uterine cervix	Coil and Gelfoam embolization combined with FFB	None	None

SG, stent graft; PVA, polyvinyl alcohol; NBCA, N-butyl-2-cyanoacrylate; FFB, femorofemoral bypass

performed endovascular treatment for the control of active vaginal bleeding due to radiation-induced artery lesions in six patients with uterine cervical cancer. The primary and secondary technical success rate was 50% and 100%, respectively. Successful control of bleeding was achieved within 1 month in five patients, and only one minor complication occurred.<sup>15</sup>

Endovascular repair using coil embolization has been employed to treat life-threatening bleeding from radiation-induced pseudoaneurysms involving arteries of tiny caliber.<sup>6,15</sup> In addition to coil embolization, deployment of covered stents to preserve the patency of the parent artery has been verified to control bleeding.<sup>2,15</sup> Ligation of the parent artery combined with surgical bypass seems to be an effective alternative for patients in whom endovascular revascularization is not feasible.<sup>15,18</sup> To this end, Table 4 summarizes previously published studies of endovascular repair for radiation-induced pseudoaneurysms of peripheral arteries. The risk of stent graft infection is very low during endovascular repair of peripheral artery disorders, and antibiotic prophylaxis is therefore not widely performed in such cases.<sup>19,20</sup> In contrast, because of skin or mucosal necrosis with a high risk of infection, antibiotic prophylaxis was administered to all patients in our study. No patients developed stent graft infection during follow-up. Endovascular repair using a covered stent was performed in all patients, and three patients required an assistant technique using coil embolization. No hybrid procedure was performed. According to our experience, radiation-induced pseudoaneurysms of the peripheral arteries can be managed by endovascular repair in most patients.

### Conclusion

Radiation-induced pseudoaneurysms of the peripheral arteries are fatal for patients

with massive hemorrhage after radiotherapy. Our study showed that the formation of pseudoaneurysms was due to radiation. Endovascular repair can serve as the first-line treatment because both diagnosis and management can be performed in one session. According to our findings, deployment of a covered stent to preserve the perfusion of the parent artery and exclude the aneurysm sac is feasible to manage radiation-induced pseudoaneurysms of the peripheral arteries in highly selected patients. This study was mainly a retrospective data analysis, had a moderate sample size with mid-term follow-up, and did not directly compare patients selected for endovascular repair versus open surgery. Therefore, further clinical trials with long-term surveillance are mandatory to more fully evaluate the safety and efficacy of endovascular repair and recognize evolving complications.


### Declaration of conflicting interest

The authors declare that there is no conflict of interest.

### Funding

The author(s) disclosed receipt of the following financial support for the research, authorship, and/or publication of this article: This study was supported by the National Science and Technology Major Project of China (2018ZX10303502), the National Natural Science Foundation of China (11971269), and the Key Research and Development Program of Shandong Province (2019GSF108015).

### ORCID iD

Yong-Zheng Wang  <https://orcid.org/0000-0001-5889-2118>

### References

- Hall HA, Minc S and Babrowski T. Peripheral artery aneurysm. *Surg Clin North Am* 2013; 93: 911–923, ix.
- Huang WY, Huang CY, Chen CA, et al. Ruptured pseudoaneurysm of the external iliac artery in an advanced cervical cancer patient treated by endovascular covered stent placement. *J Formos Med Assoc* 2008; 107: 348–351.
- Luther A, Kumar A and Negi KN. Peripheral arterial pseudoaneurysms—a 10-year clinical study. *Indian J Surg* 2015; 77: 603–607.
- Ellens DJ, Hurley MC, Surdel D, et al. Radiotherapy-induced common carotid pseudoaneurysm presenting with initially occult upper airway hemorrhage and successfully treated by endovascular stent graft. *Am J Otolaryngol* 2010; 31: 195–198.
- Sadek M, Cayne NS, Shin HJ, et al. Safety and efficacy of carotid angioplasty and stenting for radiation-associated carotid artery stenosis. *J Vasc Surg* 2009; 50: 1308–1313.
- Salaskar A, Blumenfeld P, Calandra J, et al. Endovascular management of life threatening bleeding from a radiation induced internal iliac artery branch pseudoaneurysm. *CVIR Endovasc* 2019; 2: 30.
- Cenizo NM, Gonzalez Fajardo JA, Ibanez MA, et al. Endovascular management of radiotherapy-induced injury to brachiocephalic artery using covered stents. *Ann Vasc Surg* 2014; 28: 741.e15-18.
- Yoshikawa S, Asano T, Watanabe M, et al. Rupture of hepatic pseudoaneurysm formed nine years after carbon ion radiotherapy for hepatocellular carcinoma. *Intern Med* 2019; 58: 2639–2643.
- Lam JWK, Chan JYW, Lui WM, et al. Management of pseudoaneurysms of the internal carotid artery in postirradiated nasopharyngeal carcinoma patients. *Laryngoscope* 2014; 124: 2292–2296.
- Okubo K, Isobe J, Kitamura J, et al. Mediastinitis and pseudoaneurysm of brachiocephalic artery long after the resection of invasive thymoma and postoperative irradiation. *J Thorac Cardiovasc Surg* 2005; 130: 918–919.
- Furlough CL, Jain AK, Ho KJ, et al. Peripheral artery reconstructions using cryopreserved arterial allografts in infected fields. *J Vasc Surg* 2019; 70: 562–568.

12. Huang TL, Liang HL, Huang JS, et al. Ultrasound-guided compression repair of peripheral artery pseudoaneurysm: 8 years' experience of a single institute. *J Chin Med Assoc* 2012; 75: 468–473.
13. Gandhi SJ, Minn AJ, Vonderheide RH, et al. Awakening the immune system with radiation: optimal dose and fractionation. *Cancer Lett* 2015; 368: 185–190.
14. Li SH, Hsu SW, Wang SL, et al. Pseudoaneurysm of the external carotid artery branch following radiotherapy for nasopharyngeal carcinoma. *Jpn J Clin Oncol* 2007; 37: 310–313.
15. Chen CS, Park S, Shin JH, et al. Endovascular treatment for the control of active vaginal bleeding from uterine cervical cancer treated with radiotherapy. *Acta Radiol* 2018; 59: 1336–1342.
16. Murono S, Nakanishi Y, Inoue D, et al. Pseudoaneurysm of the lingual artery after concurrent intra-arterial chemotherapy with radiotherapy for advanced tongue cancer. *Head Neck* 2011; 33: 1230–1232.
17. Golarz SR and Gable D. Use of a Viabahn stent for repair of a common carotid artery pseudoaneurysm and dissection. *Ann Vasc Surg* 2010; 24: 550.e11–550.e13.
18. Watarida S, Shiraishi S, Katsuyama K, et al. Combined catheter embolization and femoro-femoral bypass for pseudoaneurysm of the right external iliac artery. *Surg Today* 1999; 29: 83–85.
19. Schneider JR, Patel NH, Hashemi F, et al. Infected Viabahn stent graft in the superficial femoral artery. *Eur J Vasc Endovasc Surg* 2011; 42: 699–703.
20. Krol E, Ongstad S, Gensler TW, et al. Delayed superficial femoral artery covered stent infection: report of two cases and review of literature. *Ann Vasc Surg* 2018; 52: 312.e1–312.e5.