

# Retrospective Study of the Results of Surgical Treatment of 31 Giant Cell Tumors of the Tendon Sheath in the Hand\*

## *Estudo retrospectivo dos resultados do tratamento cirúrgico de 31 tumores de células gigantes da bainha do tendão da mão*

José Antonio Galbiatti<sup>1</sup> Gabriel Rodrigues dos Santos Milhomens<sup>1</sup> Luís Felipe Haber Figueiredo e Silva<sup>1</sup>  
Diego dos Santos Santiago<sup>2</sup> José Cassimiro da Silva Neto<sup>2</sup> Sérgio de Oliveira Bruno Belluci<sup>2</sup>

<sup>1</sup>Faculdade de Medicina de Marília, Marília, SP, Brazil

<sup>2</sup>Irmandade da Santa Casa de Misericórdia de Marília, Marília, SP, Brazil

Rev Bras Ortop 2019;54:26–32.

Address for correspondence Gabriel Rodrigues dos Santos

Milhomens, Faculdade de Medicina de Marília, Marília, SP, Brazil

(e-mail: gmilhomens5@hotmail.com).

### Abstract

**Objective** To evaluate the results of the treatment of 31 giant-cell tumors of the tendon sheath of the hand cared for between 2006 and 2015.

**Methods** A group of patients for the present retrospective evaluation was defined, covering the period between February 2006 and November 2015, in which 31 records of patients who underwent surgery due to cell tumor of the tendon sheath of the fingers were studied and evaluated. The recommended treatment was complete excision of the tumor with preservation of the adjacent structures. The diagnosis was confirmed by pathological examination. The progress of the treatment after surgery was evaluated, especially regarding the rate of tumor recurrence.

**Results** Taking all 31 patients into consideration, there was a predominance of the female gender and white ethnicity. Most of these patients were aged between 30 and 50 years. The most affected side was the left one, and most tumors were in the flexor face. There was a predominance of the radial fingers, along with their distal end. A total of 27 patients are being followed up at regular intervals at an outpatient clinic, and three cases of tumor recurrence have been identified.

**Conclusion** An appropriate surgical technique is essential in order to prevent GCTTS recurrences. The results obtained in this research are in agreement with the literature.

### Keywords

- ▶ neoplasms
- ▶ hands
- ▶ giant-cell tumors

### Resumo

**Objetivo** Avaliar os resultados do tratamento de 31 tumores de células gigantes da bainha do tendão da mão encontrados entre 2006 e 2015.

**Métodos** Entre fevereiro de 2006 e novembro de 2015, um grupo de pacientes foi selecionado para avaliação retrospectiva, na qual foram estudados e avaliados 31 prontuários de pacientes submetidos a procedimento cirúrgico devido a tumor de células gigantes

\* Work developed at the Department of Orthopedics and Traumatology, Irmandade da Santa Casa de Misericórdia de Marília, Marília, SP, Brazil.

Gabriel Rodrigues dos Santos Milhomens's ORCID is <https://orcid.org/0000-0001-6805-5460>



**Palavras-chave**

- ▶ neoplasias
- ▶ mãos
- ▶ tumores de células gigantes

da bainha do tendão dos dedos da mão. O tratamento preconizado foi a excisão completa do tumor com a preservação das estruturas adjacentes. A confirmação diagnóstica foi feita pelo exame anatomopatológico. Foi avaliada a evolução do tratamento após a cirurgia, principalmente no tocante ao índice de recidivas dos tumores.

**Resultados** Dos 31 pacientes da amostra, houve predomínio do sexo feminino e da etnia branca. O tumor acometeu principalmente indivíduos entre 30 e 50 anos. O lado mais acometido foi o esquerdo, e a maioria dos tumores estava na face flexora. Houve predominância dos dedos radiais, juntamente com sua extremidade distal. Esses pacientes têm sido acompanhados em intervalos regulares em ambulatório. Dos 27 pacientes reavaliados, foram identificados 3 casos de recidiva tumoral.

**Conclusão** Uma técnica cirúrgica adequada é essencial para a prevenção de recidivas do TCGBT. Os resultados obtidos na pesquisa estão em concordância com a literatura atual.

**Introduction**

Giant-cell tumor of the tendon sheath (GCTTS), which is generically called giant-cell tumor of soft parts (GCTSP), is a benign neoplasm originating at the tendinous, peritendinous or articular synovial tissue. It is also called fibrous histiocytoma of the tendon sheath, xanthogranuloma, fibroxanthoma, tendinous sheath myeloma, pigmented villonodular tenosynovitis, benign synovioma, giant-cell fibrous hemangioma, hemosiderotic sarcoma, xanthomatous histiocytic granuloma, sclerosing hemangioma, myeloxanthoma and villous arthritis. It was first described by Chassaignac,<sup>1</sup> who considered it a malignant neoplasm of the digital tendon sheath.<sup>2-8</sup> Moser<sup>9</sup> described the first example, the diffuse type, and, in 1912, Dowd (apud Weiss et al)<sup>2</sup> questioned if these lesions were truly malignant. Jaffe et al<sup>10</sup> introduced the term pigmented villonodular tenosynovitis, which was considered a synonym of GCTTS for some time due to the histological similarities; currently, however, they are recognized as distinctive diseases: the former is characterized as diffuse, and the latter is nodular or localized.<sup>2,8,11,12</sup>

Giant-cell tumor of the tendon sheath is considered the most frequent hand tumor, and it results from a benign proliferation of histiocytes from the joints and peritendinous synovial tissues developing around the tendon sheaths, joint ligaments and joint synovium.<sup>4,12-16</sup> Although there is still some divergence among the researchers, the most accepted etiology is reactive or regenerative hyperplasia associated with inflammation.<sup>5,17</sup>

Giant-cell tumor of the tendon sheath is more common between the ages of 30 and 50 years, with a female predominance in a ratio of approximately 3:2.<sup>2,3,8,13,14,17,18</sup> It mostly occurs as tumor growths in the hands, mainly in the radial fingers, frequently close to the distal interphalangeal joint.<sup>3,7,8,14,18,19</sup> The tumor favors the flexor aspect of the hand, although the extensor aspect can also be affected. Occasionally, the tumor can be lateral or circumferential.<sup>18,20</sup> Other sites may be affected with less intensity, such as the foot, the ankle, the knee and the hip.<sup>2,3,14,16</sup>

These tumors develop for a long time and often maintain the same size for many years. The affected patients present normal cholesterol levels.<sup>2</sup> Percutaneous transillumination can help the differential diagnosis with a ganglion (synovial cyst).

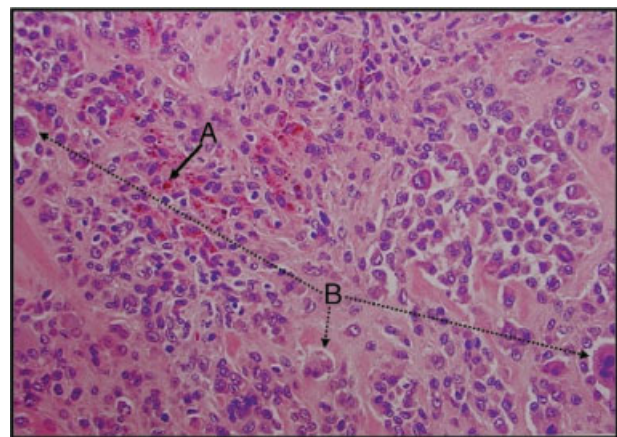
Radiographically, it is a circumscribed soft tissue mass in half of the patients, and rarely causes deformation, rarefaction and lytic lesions in the bones.<sup>3,8,12</sup>

Ultrasound can help define the dimensions of the tumor, identify satellite lesions, and differentiate ganglions or lipomas, the most common neoplasms of the hand.<sup>8</sup> Other diagnostic hypothesis of soft-part tumors must be considered, and only an anatomopathological examination can confirm them.<sup>7</sup>

Magnetic resonance imaging (MRI) is the most accurate test to define the lesion and the diagnostic suspicion.<sup>3</sup>

Giant-cell tumor of the tendon sheath can present itself as a slow-growing, well-circumscribed, firm, and lobulated mass partially or totally covered by a fibrous capsule and with no alterations in the overlying skin; it generally measures between 0.5 and 4.0 cm in diameter.<sup>2,3,7,18,20</sup> Lesions located in the foot are bigger and more irregular than those in the hand.<sup>2</sup> On the cross-sectional sections, the lesion is grayish-pink in color, with yellow or brown speckles, depending on the content of lipids, collagen, hemosiderin and histiocytes.<sup>2,3,12,19</sup>

Diagnosis confirmation is solely based on the anatomopathological examination of the specimen, which often varies histologically according to the proportion of mononuclear cells, giant cells, xanthomatous cells and the degree of



**Fig. 1** Slide photography showing the histological feature of the giant-cell tumor of the tendon sheath and evidence of hemosiderin granules (A) and giant cells (B). Magnification: 400x.

collagenization. The tumor is mostly composed of polygonal cells mixed with mildly-elongated hypocellular collagenated zones. Fused spaces are occasionally present, mainly next to the joints. Xanthomatous cells are frequently found in such tumors, and they can contain hemosiderin granules (► Fig. 1).<sup>18</sup> Bone and cartilaginous metaplasia are rarely observed.<sup>2,5,20,21</sup>

The differential diagnosis includes granulomatous lesions, tendinous xanthomas, tendinous fibromas and epithelioid sarcomas. This tumor is reportedly associated with rheumatoid arthritis, Paget disease of the bone, and degenerative osteoarthritis.<sup>2,5,12</sup>

The treatment of choice is total excision of the tumor, also known as excisional biopsy. This procedure attempts to spare the joint, tendinous, arterial and neural structures.<sup>3,6,12,15</sup> Its recurrence ranges from 5 to 50%, and it is related mainly to tumor resection failure and highly mitotic lesions.<sup>20</sup> A malignant GCTTS variant is rare and difficult to diagnose.<sup>7</sup> There are no reports of spontaneous regression.<sup>15</sup>

The goal of the present work is to evaluate the surgical outcomes of 31 giant-cell tumors of the tendon sheath of the hand treated over a period of 10 years (2006-2015) at the Orthopedics and Traumatology Department of Irmandade da Santa Casa de Misericórdia, in the city of Marília, Brazil. In addition, the study intends to relate the findings with the information found in the literature, and to highlight the importance of an adequate surgical technique to prevent recurrences.

## Material and Methods

A group of patients treated between February 2006 and November 2015 was selected for a retrospective evaluation; from this group, 31 medical records of patients submitted to a surgical procedure due to a GCTTS in the fingers were studied and analyzed. The patients were treated by two orthopedists specialized in hand surgery. From the total sample of 31 patients, 4 were not located for reevaluation. The study was approved by the Ethics in Research Committee of our institution under CAAE number 57226916.6.0000.5413.

The inclusion criteria consisted of hand tumor surgeries performed at the Orthopedics Service of our institution during the predefined period, presenting diagnostic confirmation of GCTTS by anatomopathological gross and microscopic examinations (► Fig. 1).

A serial number was chronologically assigned to each patient based on the date of the surgical treatment by the orthopedists of the Residence Service.

Regarding gender, 7 (22.59%) patients were male, and 24 (77.41%) were female.

The age of the patients ranged from 6 to 74 years, with an average of 43.64 years. Among the female patients, the age ranged from 15 to 74 years (average: 47.64 years), while among male patients, the age ranged from 6 to 56 years (average: 27 years).

A total of 25 (80.64%) patients were Caucasian, and only 6 (19.36%) were not.

► **Table 1** shows data regarding serial numbers, initials, gender, age and surgery date of the patients.

**Table 1** Serial number, initials, gender, age, and surgery date of the patients

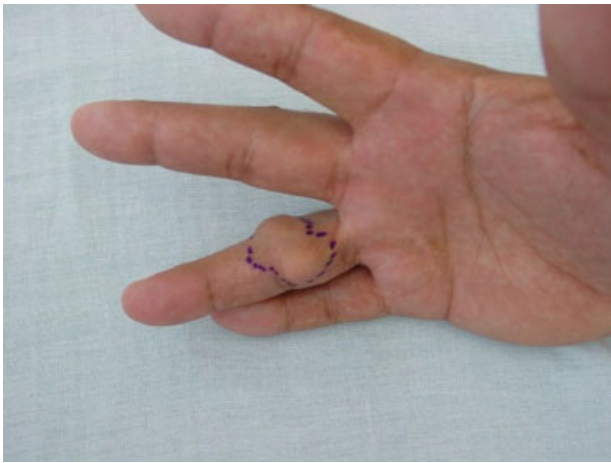
Serial number	Initials	Gender	Age	Surgery date
1	EII	F	46	March-06
2	EOM	F	38	February-08
3	CLBMP	F	47	May-08
4	MAFPE	F	45	May-08
5	EVB	F	60	June-08
6	SRS	F	44	December-08
7	ALNT	F	24	December-10
8	MHVT	F	68	April-11
9	VLTV	F	43	July-11
10	TCFS	M	25	April-12
11	MBBO	F	28	August-12
12	MLN	F	68	August-12
13	SASN	F	47	October-12
14	GAAC	M	13	November-12
15	COF	M	56	April-13
16	ASD	F	15	July-13
17	DGM	M	6	October-13
18	CMS	F	40	January-14
19	ASG	M	28	January-14
20	AAAS	M	34	June-14
21	MRB	F	47	August-14
22	MAPA	F	52	August-14
23	FOB	F	27	September-14
24	EAP	F	32	November-14
25	RUN	F	70	January-15
26	FRN	F	54	January-15
27	AMSB	F	66	February-15
28	MHPT	F	72	March-15
29	MLSD	F	74	May-15
30	RCRA	F	59	September-15
31	GSS	F	25	November-15

The surgical treatment consisted of complete tumor excision along with a detailed review of all subjacent areas to look for small residual nodules, the main cause of recurrence. All patients received locoregional anesthesia, which enabled the installation of a pneumatic tourniquet on the upper limb after active exsanguination with an Esmarche bandage. This technique provides an optimal site with no bleeding for the procedure and improves the surgical technique.

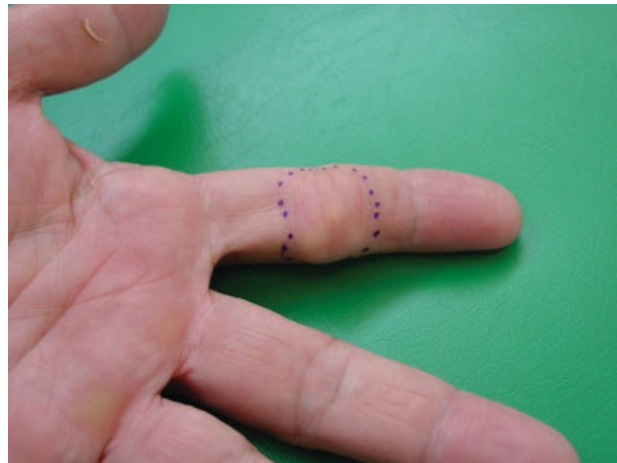Information regarding recurrences was collected.

In the surgical descriptions, we highlight the access route planning, and took into consideration the anatomical region containing the tumor. The lateral route was used in the

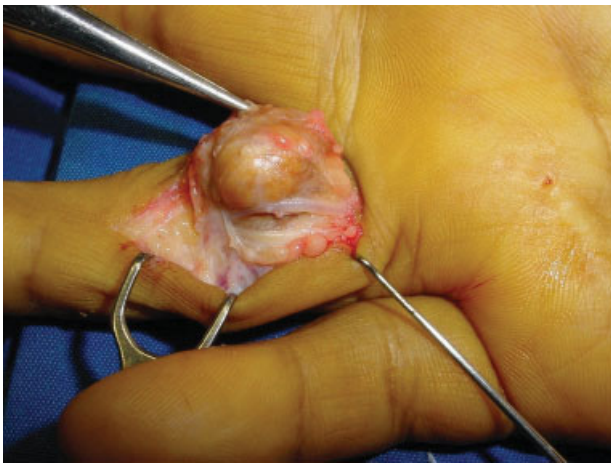




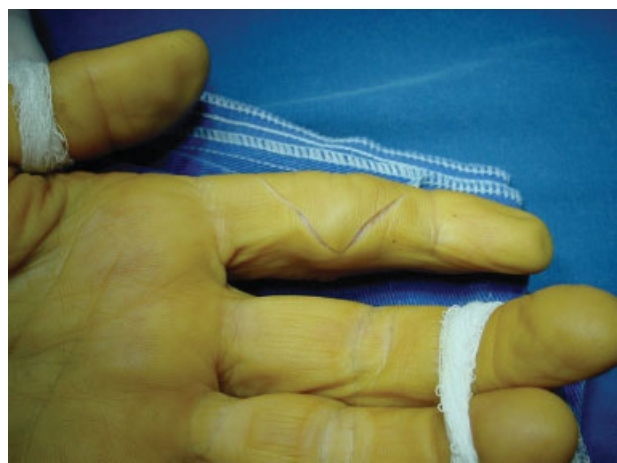**Fig. 2** Swelling appearance on the fourth digit of the right hand, partially affecting the dorsum, the radial aspect and the volar base of the proximal phalanx (patient number 6).



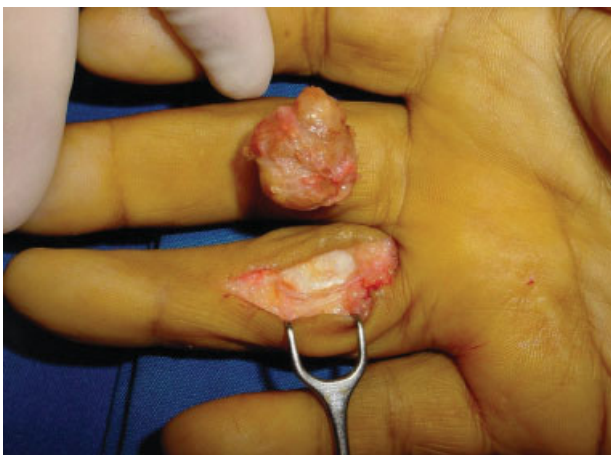**Fig. 5** Outline of the area of the tumor, predominantly in the volar region of the medial phalanx of the second digit of the left hand (patient number 10).



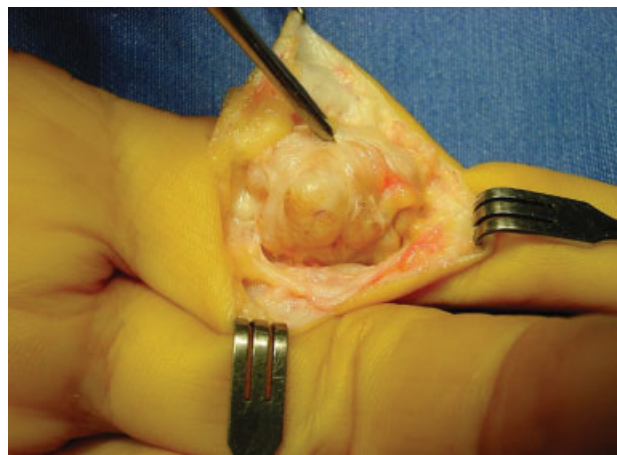
**Fig. 3** The lateral route enables the evaluation and dissection of the anterior vascular and nervous structures (patient number 6).



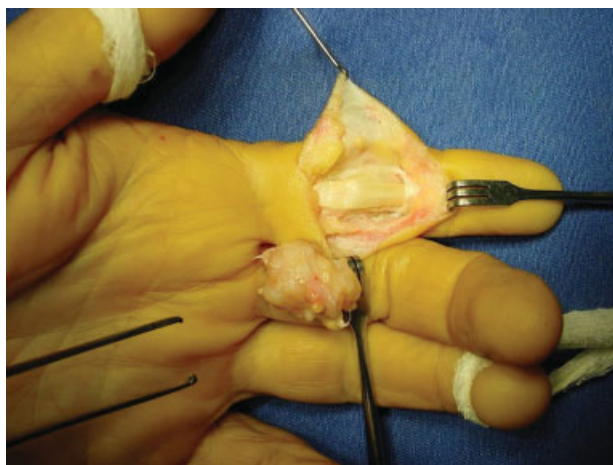
**Fig. 6** Perioperative picture showing the zigzag incision at the volar aspect of the second digit (patient number 10).



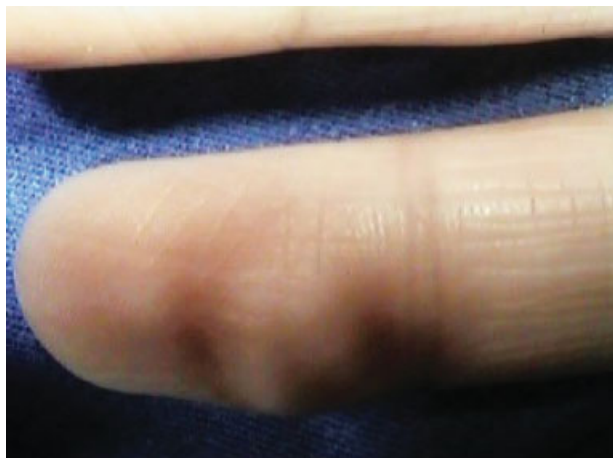**Fig. 4** At the end of surgery, the surgical site must be minutely searched for small tumors. Next to it, tumoral lesion with pseudo-capsule and brownish-yellow aspect of the giant-cell tumor of the tendon sheath (patient number 6).



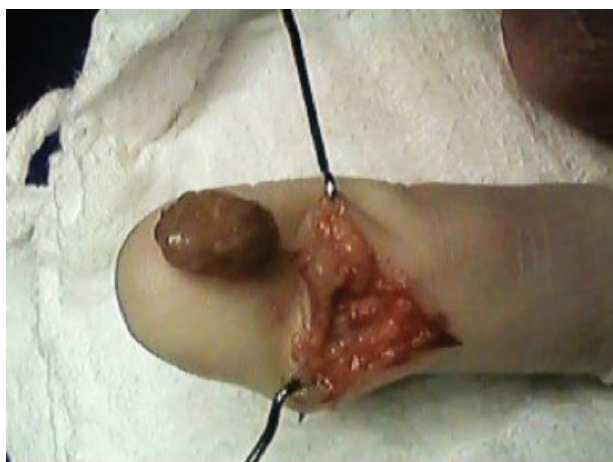**Fig. 7** Image of the partial dissection of the tumor showing the integrity of the vascular and nervous structures, which were ulnarly dissected and reflected (patient number 10).



**Fig. 8** Surgical site after tumor resection that, in this case, forced the removal of the annular pulley A3 along with the tumoral mass. Next to it, over the third digit, gross tumor specimen (patient number 10).



**Fig. 9** Volar swelling on the distal phalanx of the second digit of the right hand (patient number 16).



**Fig. 10** Surgical site of the tumor bed and, next to it, the brownish aspect of the giant-cell tumor of the tendon sheath (patient number 16).

digit when the tumor affected the volar and dorsal regions (►Figs. 2–4); a zigzag approach was performed for anterior lesions (►Figs. 5–8); oblique, straight incisions were performed for small tumors (►Figs. 9 and 10); and long, arch-like incisions were performed for dorsal tumors.

During the performance of the surgical technique, the tumor was dissected and removed, sparing its pseudocapsule; then, the open area and the tumoral bed were systematically searched for possible tumor fragments; if present, suspicious tissues must be removed to prevent recurrences.

During the postoperative period, a gutter cast was kept for seven days. The stitches were removed between 7 to 14 days postoperatively.

Then, home rehabilitation began with active and passive movements after the removal of the gutter cast.

The postoperative follow-up evaluations and reevaluations occurred in intervals ranging from 5 to 122 months.

## Results

The left side of the hand was affected in 17 (54.83%) cases, and the right side, in 14 (45.17%).

Regarding the fingers affected by the tumor, 4 (12.9%) lesions were located in the thumb, 12 (38.7%) in the second digit, 7 (22.5%) in the third digit, 4 (12.9%) in the fourth digit, and 4 (12.9%) in the fifth digit.

Considering the affected phalanx, distal phalanx lesions were found in 16 (51.6%) patients, followed by medial phalanx lesions in 9 (29.0%) patients, and proximal phalanx lesions in 6 (19.4%) patients.

Regarding the anatomical region predominantly affected by the tumor, the volar aspect was compromised in 19 (61.3%) occasions, and the dorsal aspect, in 12 (38.7%).

The arithmetic mean of the 3 dimensions of the tumor was calculated based on the macroscopic analysis, yielding a value of  $1.50 \times 1.06 \times 0.79$  cm.

►Table 2 shows data referring to the serial numbers and affected hand, digit and phalanx of the patients, in addition to the anatomical region predominantly occupied by the tumor and its dimensions.

Considering the 31 patients from the sample, there was a predominance of Caucasian females. The mean age of the patients was 43.64 years. The most affected side was the left one; most tumors were in the flexor aspect and involved mainly the radial fingers, along with their distal extremity.

In all patients, the diagnostic confirmation was based on the anatomopathological examination performed at the Pathology Service. The microscopy of GCTTS is exemplified in ►Fig. 1.

No skin necrosis or infection was observed in any of the cases.

Out of the 31 patients, 27 were reevaluated, and they have been followed up at regular intervals at the clinic. A total of four patients were lost during the reevaluation period. Until now, 3 cases of tumoral recurrence were verified, in patients identified by the serial numbers 12, 21 and 28.



**Table 2** Serial number and affected hand, digit and phalanx, anatomical region predominantly occupied by the tumor and lesion dimensions of the patients

Serial number	Hand	Digit	Phalanx	Anatomical region	Dimensions (in centimeters)
1	Left	1st	Distal	Volar	1.1 × 0.7 × 0.4
2	Left	2nd	Distal	Volar	2.0 × 1.1 × 0.7
3	Left	2nd	Proximal	Volar	1.9 × 0.8 × 0.8
4	Right	3rd	Distal	Volar	1.9 × 1.4 × 0.9
5	Right	3rd	Medial	Dorsal	1.4 × 1.0 × 0.6
6	Right	4th	Proximal	Volar	1.2 × 0.5 × 0.5
7	Right	2nd	Distal	Dorsal	1.5 × 1.3 × 0.7
8	Right	2nd	Distal	Dorsal	0.6 × 0.4 × 0.3
9	Right	3rd	Distal	Dorsal	0.7 × 0.5 × 0.4
10	Left	2nd	Medial	Volar	0.6 × 0.4 × 0.3
11	Left	3rd	Medial	Dorsal	1.6 × 1.2 × 0.8
12	Right	4th	Proximal	Volar	2.5 × 1.4 × 1.2
13	Right	2nd	Distal	Dorsal	1.2 × 1.0 × 0.8
14	Left	1st	Proximal	Dorsal	1.5 × 1.3 × 0.7
15	Left	5th	Medial	Volar	2.0 × 2.0 × 2.1
16	Right	2nd	Distal	Volar	3.2 × 2.5 × 2.8
17	Left	2nd	Medial	Volar	1.1 × 0.8 × 0.7
18	Left	5th	Distal	Dorsal	1.7 × 1.5 × 1.0
19	Right	5th	Medial	Dorsal	1.4 × 1.0 × 0.7
20	Left	3rd	Distal	Volar	0.7 × 0.7 × 0.5
21	Left	5th	Proximal	Dorsal	0.9 × 0.7 × 0.4
22	Right	1st	Distal	Volar	1.5 × 0.8 × 0.5
23	Right	2nd	Medial	Dorsal	2.5 × 2.0 × 1.5
24	Left	4th	Distal	Volar	1.2 × 0.8 × 0.6
25	Left	4th	Proximal	Volar	1.8 × 1.0 × 1.0
26	Left	3rd	Distal	Volar	3.2 × 1.5 × 1.5
27	Left	1st	Medial	Volar	2.0 × 2.0 × 0.1
28	Right	2nd	Distal	Dorsal	1.4 × 0.9 × 0.6
29	Left	3rd	Distal	Volar	1.8 × 1.0 × 0.8
30	Right	2nd	Medial	Volar	0.3 × 0.3 × 0.3
31	Left	2nd	Distal	Volar	0.6 × 0.5 × 0.3

## Discussion

When treating any soft-part tumor, it is important to evaluate benign and malign characteristics. After this evaluation, a biopsy or complete excision of the tumor must be proposed. Fortunately, malignant hand tumors are relatively rare and, in general, if not too big, it is possible to excise them at the first surgical time.

Giant-cell tumor of the tendon sheath, which is also called giant-cell tumor of soft parts, is found mainly in the hand and, in a lower proportion, it can also involve the foot, the ankle, the knee and the hip.

This tumor type rarely causes pain, and the most frequent clinical presentation is swelling.<sup>8,17-19</sup> Due to the slow growing nature of the tumor, the symptoms take six months to two and a half years to appear.<sup>3</sup>

The recommended treatment is complete tumoral excision sparing adjacent structures.

Retrospective studies always have some drawbacks, since the lack of well-defined criteria to fill out the records can hinder the collection of the required data from all patients. The present work tried to develop a protocol that could be used in all cases and could make the information more homogenous.

The present study required a reevaluation of the patients, and the higher the retroactive time, the higher the chance of losing the patient during follow-up; as such, four patients were lost. This is an acceptable figure, which represents nearly 13% of the sample. The authors believe that this number is small because the patients belong to a relatively stable community regarding migrations; in addition, medical records always have more than one contact address for the patients.

Regarding gender, the present work is consistent with the literature, with a predominance of female patients (77.41%).<sup>2,3,7,13,14,17,18</sup>

Concerning age epidemiology, the sample was consistent with the data reported by most studies, between the third and the fifth decades of life, although the tumor can affect children and elderly patients; the mean age of our sample was 43.64 years, ranging from 6 to 74 years.<sup>12-14,17,18</sup>

Considering the anatomical region predominantly affected by the tumor, the findings of the present work are similar to those of the literature: it is more frequent in the volar region, which was affected in 19 (61.3%) digits in our sample compared to the dorsal region, which was affected in 12 (38.7%) digits.<sup>22</sup> The lesion was volar in almost 70% of the cases.<sup>19,20</sup>

The index and medium fingers at the distal interphalangeal joint are the preferred sites for GCTTS. Some literature data refer to a non-significant predominance in the radial fingers.<sup>3,7,8,14,18,19</sup> The present work yielded data consistent with the literature, since the GCTTS affected the thumb in 4 (12.9%) cases, followed by the second digit in 12 (38.7%) cases, and the third digit in 7 (22.5%) cases, totaling 23 (74.2%) cases.

Loréa et al<sup>23</sup> reviewed circumferential tumors and discussed the technical difficulty and the two distinct tumor types defined in the immunohistochemistry. Other authors discussed the cellularity and mitotic activity of this tumor type, which still has not been fully clarified in the literature, but it is possibly related to recurrences.<sup>24</sup>

The literature data is quite diverse regarding tumor recurrence. The recurrence index ranges from 5 to 50%, showing a major discrepancy, frequently related to procedures performed by general surgeons, dermatologists and other physicians, sometimes in outpatient facilities and without a tourniquet or adequate anesthesia.<sup>20</sup>

Although the diagnosis may be clinically suspicious, it is confirmed by the anatomopathological examination. Total surgical excision is the definitive treatment.<sup>3,6,12,15</sup>

Age, gender and tumoral size appear not to influence the recurrence rate.<sup>5</sup> Although there is no literary consensus, some authors believe that the bone erosion, localization,

cellularity and mitotic activity of the neoplasm represent a higher risk of recurrence. Reilly et al<sup>5</sup> observed that GCTS recurrence is higher in the thumb interphalangeal joint and in the distal interphalangeal joints due to the inherent difficulty of performing complete tumor excision because of the proximity of neurovascular structures. However, recurrence is mainly related to the surgical procedures during tumor removal.<sup>3,14,19</sup>

## Conclusion

In general, the data obtained in the study and follow-up of these 31 patients are in line with the current literature. Out of the 27 reassessed patients, there were 3 (11.1%) recurrences.

### Conflicts of Interest

The authors have none to declare.

## References

- Chassaignac M. Cancer de la gaine des tendons. *Gaz Hosp Civ Milit* 1852;47:185–6
- Weiss SW, Goldblum JR, Folpe AL. *Enzinger and Weiss's soft tissue tumors*. 6th ed. Philadelphia: Saunders; 2014
- Adams EL, Yoder EM, Kasdan ML. Giant cell tumor of the tendon sheath: experience with 65 cases. *Eplasty* 2012;12:e50
- Lancigu R, Rabarin F, Jeudy J, Saint Cast Y, Cesari B, Fouque PA, et al. Giant cell tumors of the tendon sheaths in the hand: review of 96 patients with an average follow-up of 12 years. *Orthop Traumatol Surg Res* 2013;99(4, Suppl):S251–4
- Reilly KE, Stern PJ, Dale JA. Recurrent giant cell tumors of the tendon sheath. *J Hand Surg Am* 1999;24(6):1298–302
- Williams J, Hodari A, Janevski P, Siddiqui A. Recurrence of giant cell tumors in the hand: a prospective study. *J Hand Surg Am* 2010;35(3):451–6
- Valentini JD, Aguiar DF, Ferdinando MPL, Wagner M, Silva JB. Tumores da mão parte I: tumores de partes moles da mão. *Rev AMRIGS* 2015;59(3):237–42
- Lautenbach M, Kim S, Millrose M, Eisenschenk A. Nodular giant cell tumour of the tendon sheath of the hand: analysis of eighty-four cases: diagnostic decisions and outcome. *Int Orthop* 2013;37(11):2211–5
- Moser E. Primares sarkom der fussgelenklapsel Extirpation. Dauerheilung. *Dtsch Z Chir* 1909;98:306–10
- Jaffe H, Lichtenstein L, Sutro CJ. Pigmented villonodular synovitis, bursitis and tenosynovitis. *Arch Pathol (Chic)* 1941;31:731–65
- Botez P, Sirbu PD, Grierosu C, Mihailescu D, Savin L, Scarlat MM. Adult multifocal pigmented villonodular synovitis—clinical review. *Int Orthop* 2013;37(4):729–33
- Glowacki KA. Giant cell tumors of tendon sheath. *J Hand Surg Am* 2003;3(2):100–7
- Di Grazia S, Succi G, Fragetta F, Perrotta RE. Giant cell tumor of tendon sheath: study of 64 cases and review of literature. *G Chir* 2013;34(5-6):149–52
- Hwang JS, Fitzhugh VA, Gibson PD, Didesch J, Ahmed I. Multiple giant cell tumors of tendon sheath found within a single digit of a 9-year-old. *Case Rep Orthop* 2016;2016:1834740
- Silva JB, Calcagnotto GN, Scolari J, Fridman M. Tumor de células gigantes da bainha tendinosa ao nível dos dedos: exérese através da incisão circunferencial. *Rev Bras Ortop* 2002;37(4):129–32
- Pedrinelli A, Camargo OP, Barreto RB, Moldenhauer D, Pedrinelli R. Tumor de células gigantes de bainha de tendão no LCA. *Acta Ortop Bras* 2007;15(3):171–3
- Fotiadis E, Papadopoulos A, Svarnas T, Akritopoulos P, Sachinis NP, Chalidis BE. Giant cell tumour of tendon sheath of the digits. A systematic review. *Hand (N Y)* 2011;6(3):244–9
- Alves MPT. Excision of giant cell tumor of tendon sheath with bone involvement by means of double access approach: case report. *Rev Bras Ortop* 2015;46(1):101–6
- Osman W, Alaya Z, Haggui A, Rejeb MB, Jemni S, Naouar N, et al. Les tumeurs à cellules géantes des gaines synoviales de la main: à propos de 50 cas. *Pan Afr Med J* 2017;26(128):8p
- Green DP, Hotchkiss RN, Pederson WC. *Green's operative hand surgery*. 6th ed. New York: Churchill Livingstone; 2010
- Al-Qattan MM. Giant cell tumours of tendon sheath: classification and recurrence rate. *J Hand Surg [Br]* 2001;26(1):72–5
- Yamaguchi T, Dorfman HD. Giant cell reparative granuloma: a comparative clinicopathologic study of lesions in gnathic and extragnathic sites. *Int J Surg Pathol* 2001;9(3):189–200
- Loréa P, Medina J, Navarro R, Foucher G. Récidive des tumeurs à cellules géantes des gaines tendineuses digitales après exérese par une voie d'abord dite des "dents de la mer". A propos de 25 cas. *Ann Chir Plast Esthet* 2001;46(6):607–10
- Hosaka M, Hatori M, Smith RA, Kokubun S. A cell line with multinucleated giant cell formation established from a human giant cell tumor of tendon sheath—preliminary report. *J Orthop Sci* 2001;6(5):414–8