



Contents lists available at ScienceDirect

International Journal of Surgery Case Reports

journal homepage: www.casereports.com

Remote medulla oblongata ventral acute subarachnoid hemorrhage following cervical spinal surgery: A case report

Lu Feng, Yanwu Han, Yanjuan Wang, Guanglin Li, Guangming Wang*

Department of Neurosurgery, The First Hospital of Jilin University, Changchun, Jilin, 130021, PR China

ARTICLE INFO

Article history:

Received 12 January 2021

Received in revised form 11 February 2021

Accepted 13 February 2021

Available online 22 February 2021

Keywords:

Remote intracranial hemorrhage

Cerebrospinal fluid leakage

Spinal surgery

Case report

ABSTRACT

INTRODUCTION: The incidence of remote intracranial hemorrhage (RICH) in patients during spinal surgery is rare and the detailed mechanism remains unclear.

PRESENTATION OF CASE: A 55-year-old man had undergone cervical discectomy and fusion at C5–6 and C6–7 due to herniated disc and secondary spinal canal stenosis. He had severe headache 20 h postoperatively and his drain output increased from 100 to 350 mL in the second 10 h after surgery. Computed tomography (CT) and magnetic resonance imaging (MRI) were performed and he was diagnosed with acute subarachnoid hemorrhage in the ventral medulla oblongata. The drainage tube was quickly removed. Infusion of hypertonic saline was used to reduce intracranial pressure and nimodipine prevented vasospasm around the brainstem. The patient made a gradual, satisfactory recovery with conservative treatment.

DISCUSSION: The most likely pathomechanism leading to RICH is venous bleeding due to rapid leak of a large amount of cerebral spinal fluid (CSF) after spinal surgery. If the patient has a headache or neurological complaints after spinal surgery, immediate imaging is recommended to confirm the diagnosis. Treatment depends on the amount and location of intracranial hemorrhage.

CONCLUSION: RICH is a serious but rare complication of spinal surgery and cerebellar hemorrhage is the most common. The most important pathomechanism leading to RICH after spinal surgery is venous bleeding due to rapid leak of a large amount of CSF. Timely CT is necessary to exclude RICH. Treatment of RICH depends on the size of the intracranial hematoma and the patient's symptoms.

© 2021 The Author(s). Published by Elsevier Ltd on behalf of IJS Publishing Group Ltd. This is an open access article under the CC BY-NC-ND license (<http://creativecommons.org/licenses/by-nc-nd/4.0/>).

1. Introduction

RICH after spinal surgery is rare but it can occur at various sites; for example, cerebellar [1], intraventricular [2], epidural [3], subarachnoid, basal ganglia [4], subdural [5], or even intraparenchymal [6] hemorrhage. RICH has been observed after any type of spinal surgery, including cervical [5], thoracic [3] and lumbar [7] spinal surgery, and even lumbar puncture.

The exact pathophysiology and etiology of this exceedingly rare complication is still unclear, but evidence suggests that it is caused by excessive CSF loss during or after surgery, which results in cerebral displacement causing stretching and eventual tearing of the bridging veins [8]. However, some cases have also been reported with no durotomy or CSF leakage. We encountered a patient with medulla oblongata ventral subarachnoid hemorrhage owing to cervical spinal surgery, who presented with severe headache 20 h

postoperatively. We summarize possible mechanisms, and draw attention to the early identification and treatment of this complication to avoid or minimize permanent neurological injury. This study has been reported in line with the SCARE checklist [9].

2. Presentation of the case

A 55-year-old, previously healthy man was admitted with progressive numbness and immobility of both upper limbs. There was no history of hypertension or hematological diseases, no family history of the same condition was documented, and he was not on any medication. He was not a smoker. At admission, upon physical examination, the patient showed clear consciousness and could answer common questions. The pupils and relevant reflexes were normal. The power in the both upper limbs according to Medical Research Council grading was 4/5 [10]. The laboratory results of the patient were normal. Cervical MRI showed disc herniation and secondary spinal canal stenosis at C5–6 and C6–7 (Fig. 1B) and CT showed that the area of the medulla oblongata was normal (Fig. 1A).

The patient underwent cervical discectomy and fusion; performed by a spinal surgery consultant with 20 years' experience. The operation went well and no durotomy or CSF leakage was

Abbreviations: CSF, cerebrospinal fluid; CT, computed tomography; MRI, magnetic resonance image; RICH, remote intracranial hemorrhage.

* Corresponding author at: Department of Neurosurgery, The First Hospital of Jilin University, 1 Xinmin Avenue, Changchun, Jilin, 130021, PR China.

E-mail address: itisgmwang@jlu.edu.cn (G. Wang).

<https://doi.org/10.1016/j.ijscr.2021.105675>

2210-2612/© 2021 The Author(s). Published by Elsevier Ltd on behalf of IJS Publishing Group Ltd. This is an open access article under the CC BY-NC-ND license (<http://creativecommons.org/licenses/by-nc-nd/4.0/>).

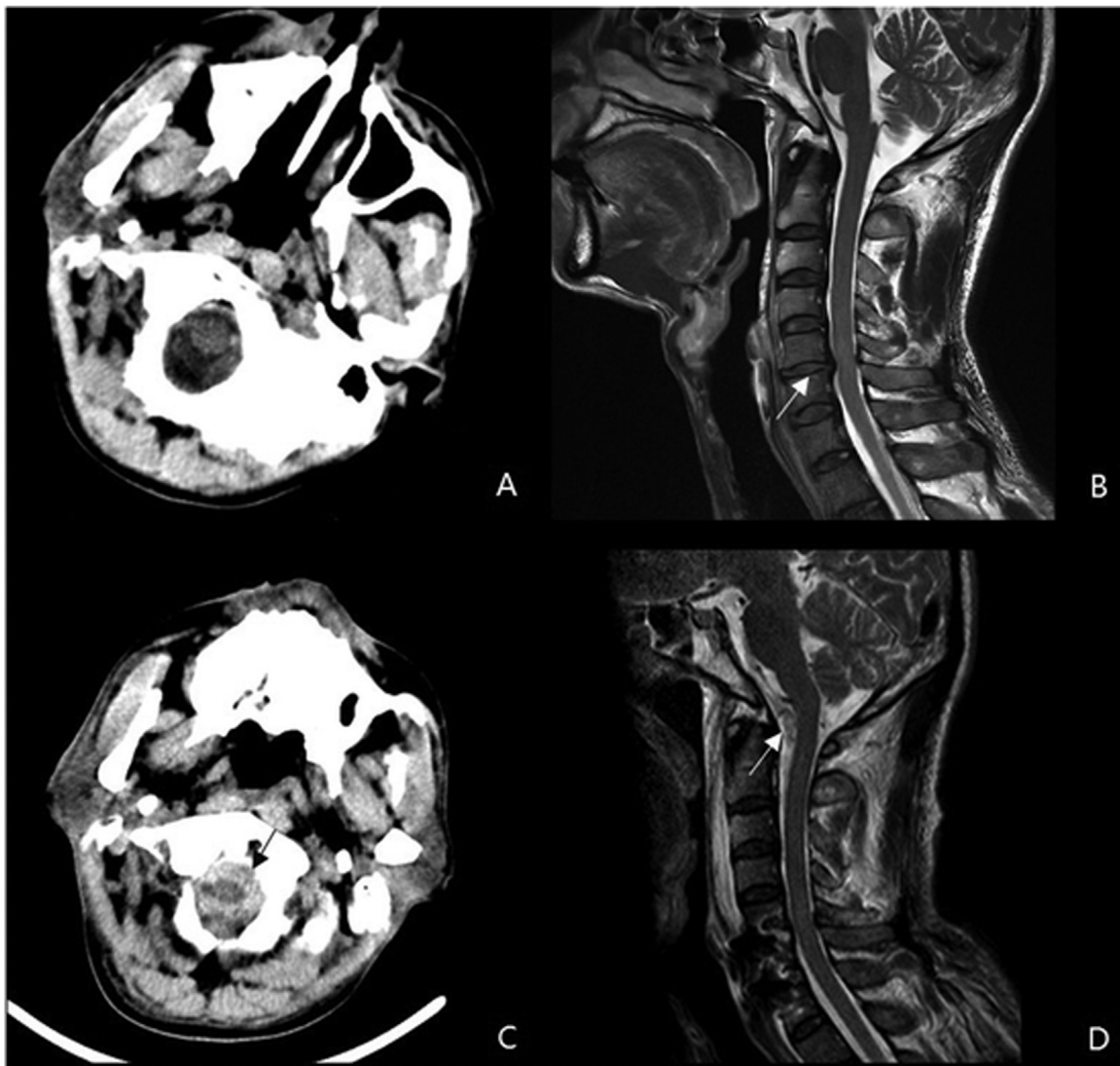


Fig. 1. Preoperative magnetic resonance imaging (MRI) and computed tomography (CT) (A, B). Axial brain CT (A) showing normal area of medulla oblongata. Sagittal T1-weighted MRI of the cervical spine (B) demonstrating an extruded C5–6 and C6–7 intervertebral disc and spinal canal stenosis (arrow). Postoperative MRI and CT at 22 h after spinal surgery (C, D). Axial brain CT (C) and sagittal T1-weighted MRI of the cervical spine (D) demonstrating medulla oblongata ventral acute subarachnoid hemorrhage (arrows).

encountered. Prior to closure, a hemovac drain was placed in the epidural space. After the operation, the patient had good consciousness, stable vital signs, obvious sense of limb release, and no decrease in muscle strength and sensation. Twenty hours later, he suffered acute-onset severe headache and his drain output increased from 100 to 350 mL in the second 10 h after surgery. CT and MRI showed ventral medullary subarachnoid hemorrhage and no obvious bleeding at the operation site (Fig. 1C, D). The drain was immediately removed. Infusion of hypertonic saline was used to reduce intracranial pressure and nimodipine prevented vasospasm around the brainstem. The headache gradually relieved within 1 week and the patient was transferred to the rehabilitation department in the next 2 weeks. During a follow-up period of 16 months, the patient's recovery was satisfactory.

3. Discussion

RICH is a rare poorly understood complication of spinal surgery, especially cervical spinal surgery, and can lead to significant morbidity and mortality [1]. After spinal surgery, intracranial hem-

orrhage remote from the area of surgery may develop [11]. The reported incidence of remote hemorrhage after spinal surgery is 0.08% [12], and the bleeding site is usually located in the cerebellum [13]. The exact pathophysiological mechanism of RICH after spinal surgery is unclear. Deniz et al. conducted a literature review and found no correlations between RICH and age, sex, pathology, or type of intervention performed [14]. Evidence suggests that the cranial bleeding has a venous origin [15]. One hypothesis is that excessive CSF loss results from incidental or intentional durotomy, or drain placement causes caudal prolapse in the cerebellum. This sudden shift of the brain may cause traction at the arachnoid matter and venous structures of the brain, leading to secondary venous tearing or occlusion and hemorrhage in cases in which reperfusion reoccurs or venous pressure increases [16]. However, there are also other reports of cases in which no durotomy or CSF leakage is encountered [1], as in the present case. CSF leakage or dural tear was not noted by the surgical team during the operation. However, there was a marked postoperative increase in drainage of about 250 mL at second 10 h, which may have been caused by rupture of the dural matter, and CSF leakage may not be obvious during surgery.

After surgery, the negative pressure caused by drainage can lead to massive loss of CSF, resulting in hemorrhage. So, while no CSF leakage was noted during surgery in our case, it is possible there was some leakage [4]. In view of the above findings and our previous report [17], we assumed that the tentorium of the cerebellum and foramen magnum are the boundary, and the central nervous system is divided into three chambers, supratentorial, infratentorial and spinal canal. No matter which chamber it is, the rapid loss of CSF and rapid perioperative parenchymal shift may result in hemorrhage at remote locations. There are some other risk factors that have been associated with spontaneous RICH, including dyslipidemia, smoking, diabetes mellitus, hypertension, amyloid angiopathy, vascular malformations, use of anticoagulants, tumors, trauma, and infection [18,19]. To the best of our knowledge, this kind of hemorrhage is not considered to be of arterial origin. Therefore, we did not perform a head CT angiography to rule out an aneurysm.

Usually, a headache is the most common symptom of RICH, but corresponding neurological symptoms are also found. If the patient has a headache or neurological complaints after spinal surgery, immediate imaging is recommended to confirm the diagnosis of RICH and early diagnosis and treatment can reduce mortality. In our case, the patient presented with only headache and no other symptoms 20 h after surgery. So, we speculate that there are many asymptomatic cases of RICH that are undetected after spinal cord surgery, because cranial CT is not routinely performed, and the incidence of RICH may exceed that which is reported [2,8,16]. Continued and worsening neurological symptoms after spinal surgery may warrant cranial imaging to rule out RICH, usually within the first 24 h after surgery [8].

To minimize the incidence of RICH, neurosurgeons and spinal surgeons should be aware of this rare complication, and care must be taken to prevent dural injury during spinal surgery or try to minimize CSF loss during durotomy by head-down position and immediate closure [7]. Patients should stay in bed for a period of time after the operation, to avoid postoperative hemorrhage caused by gravity-induced displacement of brain tissue [20]. When a tentative diagnosis of RICH is made, the suction drain should be removed promptly [21] and CT is needed. Generally, conservative medical treatment is sufficient for RICHs, and the long-term prognosis is good. However, in some cases, large hematomas that cause a significant mass effect or an acute hydrocephalus may need craniotomy and external ventricular drainage [22].

4. Conclusion

RICH is a serious but rare complication of spinal surgery, which can occur in any location in the skull, and cerebellar hemorrhage is the most common. The most important pathomechanism leading to RICH after spinal surgery is venous bleeding due to rapid leakage of a large amount of CSF. Most cases happen several hours after surgery, and once headache, vomiting or nervous system symptoms appear, timely CT is necessary to exclude RICH. Treatment of RICH depends on the size of the intracranial hematoma and the patient's symptoms. Spinal surgeons should be aware of this rare but serious complication. Dural repair and minimizing CSF loss after intraoperative dural tearing would be helpful to prevent postoperative RICH.

Declaration of Competing Interest

The authors report no declarations of interest.

Funding

No source of funding.

Ethical approval

Being a Case Report, with written consent our institution doesn't require formal Ethical Approval. Consent written informed consent was obtained from the patient for publication of this case report.

Consent

Written informed consent was obtained from the patient for publication of this case report and accompanying images. A copy of the written consent is available for review by the Editor-in-Chief of this journal on request.

Author contribution

Lu Feng and Yanwu Han: collected data and involved in the management of the case.

Guanglin Li and Yanjuan Wang: drafted the case report.

Guangming Wang: supervised study, provided resources and writing the final draft.

All authors proof read and approved the report for publication.

Lu Feng, Yanwu Han, Yanjuan Wang and Guanglin Li contributed equally to this work.

Registration of research studies

Not applicable.

Guarantor

Guangming Wang.

Provenance and peer review

Not commissioned, externally peer-reviewed.

References

- [1] R.C. Hoffer, M.P. Wemhoff, S.J. Johans, et al., Cerebellar hemorrhage following an uncomplicated lumbar spine surgery: case report, *J. Stroke Cerebrovasc. Dis.* 28 (7) (2019) e104–e105, <http://dx.doi.org/10.1016/j.jstrokecerebrovasdis.2018.12.001> [published Online First: Epub Date].
- [2] L.A. Tan, M.K. Kasliwal, H.S. An, et al., Obstructive hydrocephalus due to intraventricular hemorrhage after incidental durotomy during lumbar spine surgery, *Spine* 43 (5) (2018) E316–E319, <http://dx.doi.org/10.1097/BRS.0000000000001074> [published Online First: Epub Date].
- [3] S. Surash, D. Bhargava, A. Tyagi, Bilateral extradural hematoma formation following excision of a thoracic intradural lesion, *J. Neurosurg. Pediatr.* 3 (2) (2009) 137–140, <http://dx.doi.org/10.3171/2008.10.PEDS0860> [published Online First: Epub Date].
- [4] B. Berry, M. Ghannam, C. Bell, et al., Basal ganglia hemorrhage in a case report following spinal surgery, *BMC Neurol.* 18 (1) (2018) 204, <http://dx.doi.org/10.1186/s12883-018-1218-x> [published Online First: Epub Date].
- [5] T. Morimoto, M. Shiraki, K. Otani, et al., Supratentorial subdural hemorrhage of a previous head injury and cerebellar hemorrhage after cervical spinal surgery: a case report and review of the literature, *Spine* 39 (12) (2014) E743–747, <http://dx.doi.org/10.1097/BRS.0000000000000323> [published Online First: Epub Date].
- [6] G. Thomas, H. Jayaram, S. Cudlip, et al., Supratentorial and infratentorial intraparenchymal hemorrhage secondary to intracranial CSF hypotension following spinal surgery, *Spine* 27 (18) (2002) E410–412, <http://dx.doi.org/10.1097/00007632-200209150-00023> [published Online First: Epub Date].
- [7] T.K. Nam, S.W. Park, B.K. Min, et al., Remote cerebellar hemorrhage after lumbar spinal surgery, *J. Korean Neurosurg. Soc.* 46 (5) (2009) 501–504, <http://dx.doi.org/10.3340/jkns.2009.46.5.501> [published Online First: Epub Date].
- [8] P.E. Kaloostian, J.E. Kim, A. Bydon, et al., Intracranial hemorrhage after spine surgery, *J. Neurosurg. Spine* 19 (3) (2013) 370–380, <http://dx.doi.org/10.3171/2013.6.SPINE12863> [published Online First: Epub Date].
- [9] R.A. Agha, T. Franchi, C. Sohrabi, et al., The SCARE 2020 guideline: updating consensus Surgical CAse REport (SCARE) guidelines, *Int. J. Surg.* (84) (2020) 226–230, <http://dx.doi.org/10.1016/j.ijsu.2020.10.034> [published Online First: Epub Date].

- [10] M.A. James, Use of the Medical Research Council muscle strength grading system in the upper extremity, *J. Hand Surg.* 32 (2) (2007) 154–156, <http://dx.doi.org/10.1016/j.jhsa.2006.11.008> [published Online First: Epub Date].
- [11] H.M. Sen, M. Guven, A.B. Aras, et al., Remote cerebellar hemorrhage presenting with cerebellar mutism after spinal surgery: an unusual case report, *J. Korean Neurosurg. Soc.* 60 (3) (2017) 367–370, <http://dx.doi.org/10.3340/jkns.2014.0709.001> [published Online First: Epub Date].
- [12] B. Cevik, I. Kirbas, B. Cakir, et al., Remote cerebellar hemorrhage after lumbar spinal surgery, *Eur. J. Radiol.* 70 (1) (2009) 7–9, <http://dx.doi.org/10.1016/j.ejrad.2008.01.004> [published Online First: Epub Date].
- [13] F. Yang, J. Zhao, H. Xu, Characteristics of hemorrhagic stroke following spine and joint surgeries, *Biomed. Res. Int.* 2017 (2017), 5390839, <http://dx.doi.org/10.1155/2017/5390839> [published Online First: Epub Date].
- [14] D. Konya, S. Ozgen, M.N. Pamir, Cerebellar hemorrhage after spinal surgery: case report and review of the literature, *Eur. Spine J.* 15 (1) (2006) 95–99, <http://dx.doi.org/10.1007/s00586-005-0987-2> [published Online First: Epub Date].
- [15] A. Dincer, U. Ozcan, D. Kaya, et al., Asymptomatic remote cerebellar hemorrhage: CT and MRI findings, *Cerebellum* 11 (4) (2012) 880–886, <http://dx.doi.org/10.1007/s12311-011-0351-5> [published Online First: Epub Date].
- [16] J.A. Friedman, R.D. Ecker, D.G. Piepgras, et al., Cerebellar hemorrhage after spinal surgery: report of two cases and literature review, *Neurosurgery* 50 (6) (2002) 1361–1363, <http://dx.doi.org/10.1097/00006123-200206000-00030>, discussion 63–64, [published Online First: Epub Date].
- [17] G. Wang, J. Yu, Remote acute subarachnoid hemorrhage after drainage of chronic subdural hematoma: a case report and review of the literature, *Int. J. Surg. Case Rep.* 44 (2018) 202–206, <http://dx.doi.org/10.1016/j.ijscr.2018.02.044> [published Online First: Epub Date].
- [18] J.A. Caceres, J.N. Goldstein, Intracranial hemorrhage, *Emerg. Med. Clin. North Am.* 30 (3) (2012) 771–794, <http://dx.doi.org/10.1016/j.emc.2012.06.003> [published Online First: Epub Date].
- [19] Y. Guo, X.J. Yue, H.H. Li, et al., Overweight and obesity in young adulthood and the risk of stroke: a meta-analysis, *J. Stroke Cerebrovasc. Dis.* 25 (12) (2016) 2995–3004, <http://dx.doi.org/10.1016/j.jstrokecerebrovasdis.2016.08.018> [published Online First: Epub Date].
- [20] M.R. Khalatbari, I. Khalatbari, Y. Moharamzad, Intracranial hemorrhage following lumbar spine surgery, *Eur. Spine J.* 21 (10) (2012) 2091–2096, <http://dx.doi.org/10.1007/s00586-012-2187-1> [published Online First: Epub Date].
- [21] D. Numaguchi, K. Wada, M. Yui, et al., Incidence of remote cerebellar hemorrhage in patients with a dural tear during spinal surgery: a retrospective observational analysis, *Spine Surg. Relat. Res.* 3 (2) (2019) 141–145, <http://dx.doi.org/10.22603/ssrr.2018-0019> [published Online First: Epub Date].
- [22] H. Hashidate, M. Kamimura, H. Nakagawa, et al., Cerebellar hemorrhage after spine surgery, *J. Orthop. Sci.* 13 (2) (2008) 150–154, <http://dx.doi.org/10.1007/s00776-007-1199-x> [published Online First: Epub Date].

Open Access

This article is published Open Access at [sciencedirect.com](https://www.sciencedirect.com). It is distributed under the [IJSCR Supplemental terms and conditions](#), which permits unrestricted non commercial use, distribution, and reproduction in any medium, provided the original authors and source are credited.