



## Case report

# Hepatoduodenal fistula closure diagnosed and characterized Ecoendoscopically (EUS) and managed by OTSC CLIP OVESCO: A case report

Jairo Mendoza<sup>\*</sup>, Germán Tovar, Rubén Álvarez

<sup>a</sup> Division of Gastroenterology and digestive surgery, FOSCAL Clinic, Floridablanca, Santander, Colombia

## ARTICLE INFO

## Keywords:

Hepatoduodenal fistula  
Endoscopic ultrasonography  
OTSC clip OVESCO  
Case report

## ABSTRACT

**Introduction:** Gastrointestinal (GI) tract perforations are a significant source of morbidity in clinical practice; therefore, an early diagnosis is fundamental for early management. In management, surgery is the definitive therapy; however, there is evidence of a strong response to conservative measurements.

**Presentation of case:** A 53-year-old man known for a laparoscopic cholecystectomy with difficult access and postoperative complications was admitted to our emergency department due to a five-day clinical history comprising acute abdominal pain and feverish peaks up to 38.4 °C. Diagnosis methods CT and NMR were performed but did not lead to a clear diagnosis. Therefore, a EUS was performed observing an anechoic path that communicates the duodenal wall with a right subhepatic collection that was in contact with the proximal bile duct, thickening its walls. A 5 mm fistulous orifice was found. The hepatoduodenal fistula was close endoscopically with the over-the-scope-clip OVESCO OTSC. Post endoscopic closure course was uneventful.

**Discussion:** Duodenal fistulae are considered one of the most serious complications in gastrointestinal surgery, when conventional diagnosis methods do not permit the clinicians to get either a medical diagnosis or the management; the EUS can. Advances in interventional endoscopic techniques offer an alternative management for the closure of GI fistulae.

**Conclusion:** Whenever the presence of an organized fistula is clinically suspected, EUS can be considered a useful tool that allows not only the characterization of the fistulous path and but also the definition of the minimally invasive endoscopic treatment.

## 1. Introduction

Gastrointestinal (GI) tract perforations are a significant source of morbidity in clinical practice [1]. Early diagnosis is fundamental for early management [2]. When traditional diagnostic methods fail to provide a clear diagnosis, EUS (endoscopic ultrasonography) can be used accurately to identify abscesses and fistulae. In the management of gastrointestinal (GI) fistulae, surgical therapy has been the mainstay. However, advances in interventional endoscopic techniques offer an additional option before considering surgery [3].

This work has been reported in line with the SCARE criteria [4].

## 2. Case report

This report is a case of a 53-year-old male who was admitted to the

emergency department in a fourth level clinic (October 2020), due to a five-day clinical history comprising acute abdominal pain in the right upper quadrant 8/10 with feverish peaks up to 38.4 °C, no other related symptoms. There were no relevant physical findings. His past medical history included a laparoscopic cholecystectomy with difficult access in March 2020; thickened gallbladder with plastron, with friable greater omentum, friable easy bleeding liver, with a postoperative complication: liver abscess in the gallbladder bed; which required percutaneous drainage and broad-spectrum antimicrobial regimen. Ex-smoking, there was no other family history or any relevant genetic information of medical relevance.

Laboratory tests showed mild transaminitis and marked a rise of acute phase reactants. Laboratory test results: Alanine aminotransferase: 61 U/L, amylase: 48 U/L, aspartate aminotransferase 47 U/L, total bilirubin: 0.72 mg/dL, direct bilirubin 0.32 mg/dL, indirect bilirubin

<sup>\*</sup> Corresponding author.

E-mail address: [jairoemendoza.saavedra@hotmail.com](mailto:jairoemendoza.saavedra@hotmail.com) (J. Mendoza).

<https://doi.org/10.1016/j.ijscr.2021.106093>

Received 23 April 2021; Received in revised form 17 May 2021; Accepted 5 June 2021

Available online 8 June 2021

2210-2612/© 2021 The Authors. Published by Elsevier Ltd on behalf of IJS Publishing Group Ltd. This is an open access article under the CC BY-NC-ND license

(<http://creativecommons.org/licenses/by-nc-nd/4.0/>).

0.4 mg/dL, creatinine 0.85 mg/dL, blood urea nitrogen: 13.2 mg/dL, alkaline phosphatase: 96 IU/L, prothrombin time: 10.2 s, partial thromboplastin time: 27.9 s.

A double-contrast computerized axial tomography of abdomen was performed showing the thickening of the wall of the first duodenal portion that is in relation to the surgical bed. For a better diagnosis, a simple abdominal nuclear magnetic resonance was also performed evidencing small collections associated with an alteration in the signal intensity of the hepatic hilum and a thickening of the uppermost border of the first portion of the duodenum.

No clear diagnosis yet and due to the inflammatory process at the duodenum level related to the surgical bed, an esophagogastroduodenoscopy (EGD) was requested.

The EGD found a considerable deformity in the upper duodenal knee with significant edema of the mucosa, through which a serous-looking fluid drained. With suspicion of a duodenal fistula an EUS was carried out on the 22nd of October 2020 using a radial echoendoscope Pentax-Noblus.

On endoscopic view, there was a deformity and edema in the upper duodenal knee. On ultrasound view, a thickening of the entire wall at the level of the superior duodenal knee was found. Towards the front face, an anechoic path was observed which communicated the duodenal wall with a right subhepatic collection that was in contact with the proximal bile duct, thickening its walls. A 5 mm fistulous orifice was found (Figs. 1, 2). A percutaneous drain (pigtail) was placed by an interventional radiologist and nothing was done to the bile duct.

Both the EGD and EUS were performed by an experienced endoscopist and gastrointestinal surgeon.

It was concluded that the patient has a chronic hepatoduodenal fistula (Fig. 3) due to the former cholecystectomy. The endoscopic closure was managed using the over the clip OVESCO OTSC 11/6a – (165 cm) (Ovesco Endoscopy AG, Tübingen, Germany) (Fig. 4). The patient agreed with the treatment.

The postoperative course was uneventful and the follow-up course went smoothly.

### 3. Discussion

Duodenal fistula (DF) is considered one of the most serious complications in gastrointestinal surgery, which is concerned for its critical status, difficulty in treatment, and high mortality [5]. Therefore, early diagnosis is vital. Jian-an and Ren, Jie-Shou Li, stated that fistulography and abdominal CT scan are important early diagnostic methods [2]. In the management of duodenal fistulae, surgery is the definitive therapy; however, a strong response to conservative measurements has also been described in the literature.

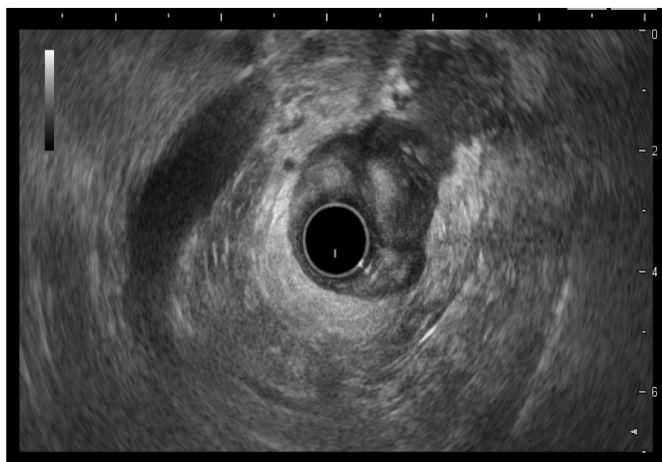

Fig. 1. Fistulous path (no marker was used).

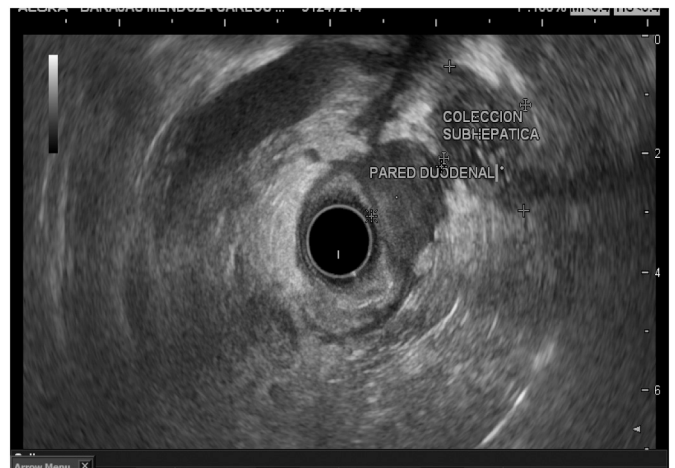

Fig. 2. Subhepatic collection, duodenal wall.

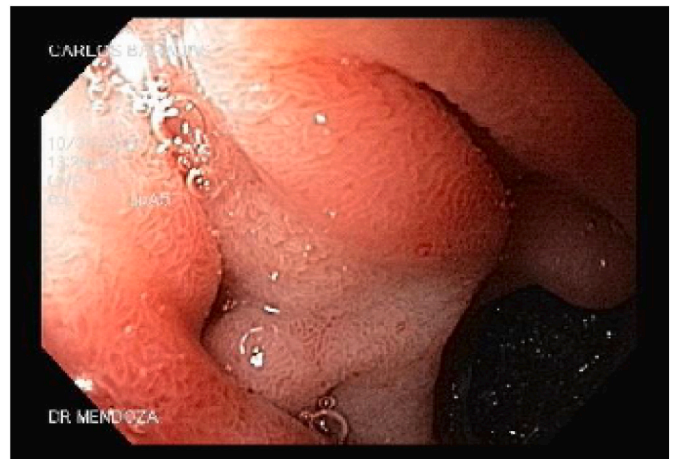


Fig. 3. Duodenal fistulous orifice.

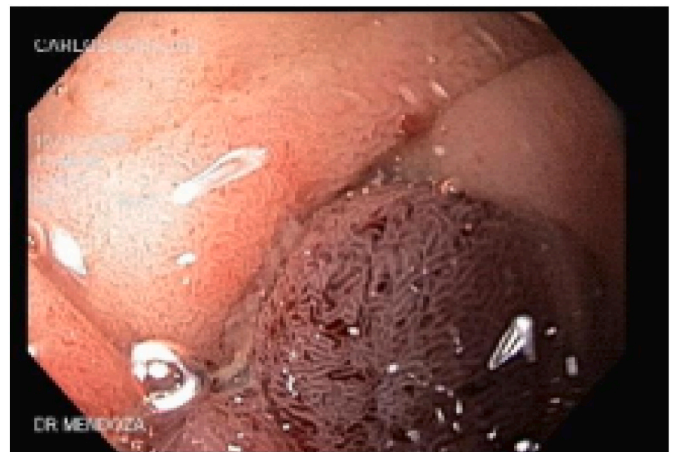

Fig. 4. Duodenal closure with over the clip OTSC 11/6a – (165 cm) (Ovesco Endoscopy AG, Tübingen, Germany).

Kumar R et al. reported the case of amebic liver abscesses (ALA) rupturing into the duodenum, forming a fistulous tract. Rupture into the duodenum is extremely rare. The diagnosis was made by ultrasonography (USG) and CT scan. The HDF closure method was conservative using metronidazole, diloxanide furoate or paromomycin after the patient

refused the surgical approach [6].

Pandey, Damodar reported the case of a hepatic abscess which was in continuation with the duodenum. As a diagnosis method, they used endoscopy, CT scan, and duodenal biopsy. In this case, the HDF was managed with endoscopic drainage and antibiotics [7].

Thomas De Somer et al. and Koji Imoto, et al. reported the cases HDF developed under the treatment with sorafenib for hepatocellular carcinoma (HCC). The diagnosis methods were the same as the aforementioned. In both cases, conservatives methods were used for the closure; immunotherapy with nivolumab and supportive enteral nutrition, and injection of argon plasma coagulation [8,9]. Another case of an HDF due to HCC was reported. In this case, the HDF occurred after repeated transcatheter arterial chemoembolization and radiotherapy. CT scan revealed a liver abscess with a duodenal fistula, which was successfully treated with endoscopic Histoacryl injection into the fistula [10].

In the cases discussed the HDF was diagnosed with traditional diagnosis methods. All of them used conservative treatments to manage the fistula and were successful. There was no information about the fistula size.

Najiha Farooqi and Faiz Tuma mention that imaging with GI contrast and small bowel follow-through imaging, or contrast enema can provide the confirmation of fistula. CT is often done first and MRI may be needed in subtle or difficult-to-diagnose fistulae [11].

In our case CT scan, MRI, EGD failed to provide a clear diagnosis, being the EUS the only method capable to help in clinical decision-making. Regarding the management of the fistula neither medical nor surgical management were suitable, because of his re-entry, high bleeding risk, duodenal fistula, and bile duct injury. Therefore, the minimally invasive method was the best treatment and out of the existing Clips, the OTSC system (Ovesco Endoscopy AG, Tübingen, Germany); was the interventional endoscopic technique selected. The OTSC system is a novel procedure that allows the sealing of GI defects such as fistulae, perforations, and leaks, and may also control severe bleeding [12]. This clip offers advantages over traditional TTSCs regarding the depth of tissue and size of lesion grasped, ease of application, and closure power [12,13].

To our best knowledge, this is the first case where an HDF is diagnosed by EUS and managed using the OTSC clip OVESCO.

#### 4. Conclusion

The present case draws attention because required a high degree of suspicion for its diagnosis and traditional diagnosis methods failed. Whenever the presence of an organized fistula is clinically suspected in the esophagus, stomach, duodenum, rectum, or rectum sigmoid, EUS can be considered a useful tool that allows characterizing the fistulous path defining the minimally invasive endoscopic treatment. This case offers an alternative diagnosis method EUS when traditional ones fail to provide an accurate diagnosis. Also contributes to reporting the use of the OTSC clip OVESCO in the endoscopic management of HDF.

#### Provenance and peer-reviewed

Not commissioned, externally peer-reviewed.

#### Funding

None.

#### Guarantor

Jairo Enrique Mendoza Saavedra.

#### Ethical approval

N/a.

#### Consent

Written informed consent was obtained from the patient for publication of this case report and accompanying images. A copy of the written consent is available for review by the Editor-in-Chief of this journal on request.

#### Research registration

N/a.

#### CRedit authorship contribution statement

All authors contributed in the same way: study concept, design, data analysis, writing the paper.

Gloria Liliana Mendoza Valbuena: data analysis, writing assistance, proof-reading the article.

#### Declaration of competing interest

None.

#### References

- [1] F. Junquera, E. Martínez-Bauer, M. Miquel, M. Fort, M. Gallach, E. Brullet, et al., OVESCO: a promising system for endoscopic closure of gastrointestinal tract perforations, *Gastroenterol. Hepatol.* 34 (8) (2011) 568–572.
- [2] J.A. Ren, J.S. Li, Early diagnosis and rapid treatments of gastrointestinal fistula, *Zhonghua Wei Chang Wai Ke Za Zhi* 9 (4) (2006 Jul) 279–280 (Chinese. PMID: 16886101).
- [3] J. Cho, A.B. Sahakian, Endoscopic closure of gastrointestinal fistulae and leaks, *Gastrointest. Endosc. Clin. N. Am.* 28 (2) (2018) 233–249.
- [4] R.A. Agha, T. Franchi, C. Sohrabi, G. Mathew, for the SCARE Group, The SCARE 2020 guideline: updating consensus surgical CASE REport (SCARE) guidelines, *Int. J. Surg.* 84 (2020) 226–230.
- [5] K. Gong, S. Guo, K. Wang, Diagnosis and treatment of duodenal injury and fistula, *Zhonghua Wei Chang Wai Ke Za Zhi Chin. J. Gastrointest. Surg.* 20 (3) (2017) 266–269.
- [6] R. Kumar, P. Kumar, K.N. Saxena, M. Dwivedi, Hepatoduodenal fistula: a rare complication of liver abscess, *J. Dig. Endosc.* 07 (04) (2016) 150–152.
- [7] D. Pandey, D. Uzunaslan, K. Zahid, N. Kiyici, A rare case of hepatoduodenal abscess with fistula: 923, *Off. J. Am. Coll. Gastroenterol. ACG 110* (2015) S397.
- [8] T. De Somer, E. Vanderstraeten, V. Bouderez, E. Monsaert, C. Van Steenkiste, Resolution of a hepatoduodenal fistula after nivolumab treatment in a patient with hepatocellular carcinoma: challenges in immunotherapy, *Acta Clin. Belg.* (2020) 1–5.
- [9] K. Imoto, M. Kohjima, T. Kurashige, T. Mutsuki, S. Tashiro, H. Suzuki, et al., Successful endoscopic treatment of hepatoduodenal fistula formed during sorafenib treatment for hepatocellular carcinoma with duodenal invasion, *Acta Hepatol. Jpn.* 60 (3) (2019) 91–98.
- [10] J. Jeon, J. Ahn, H. Yoo, T.K. Park, D. Je, H. Jeong, et al., Hepatoduodenal fistula formation following transcatheter arterial chemoembolization and radiotherapy for hepatocellular carcinoma: treatment with endoscopic Histoacryl injection, *Korean J. Intern. Med.* 29 (1) (2014) 101–105.
- [11] N. Farooqi, F. Tuma, Intestinal Fistula. En: StatPearls [Internet], StatPearls Publishing, Treasure Island (FL), 2020 [citado 23 de diciembre de 2020].
- [12] A. Kirschniak, T. Kratt, D. Stüker, A. Braun, M.-O. Schurr, A. Königsrainer, A new endoscopic over-the-scope clip system for treatment of lesions and bleeding in the GI tract: first clinical experiences, *Gastrointest. Endosc.* 66 (1) (2007) 162–167.
- [13] A. Repici, A. Arezzo, G. De Caro, M. Morino, N. Pagano, G. Rando, et al., Clinical experience with a new endoscopic over-the-scope clip system for use in the GI tract, *Dig. Liver Dis. Off. J. Ital. Soc. Gastroenterol. Ital. Assoc. Study Liver* 41 (6) (2009) 406–410.