

Hidradenitis Suppurativa (Hurley I/II): Serial Excisions with Primary Wound Closure Under Local Anesthesia As Most Adequate Treatment Approach!

Georgi Tchernev^{1,2}, Ivanka Temelkova^{1,2*}

¹Medical Institute of Ministry of Interior (MVR), Department of Dermatology, Venereology and Dermatologic surgery, General Skobelev 79, 1606 Sofia; ²Onkoderma - Clinic for Dermatology, Venereology and Dermatologic Surgery, General Skobelev 26, 1606 Sofia

Abstract

Citation: Tchernev G, Temelkova I. Hidradenitis Suppurativa (Hurley I/II): Serial Excisions with Primary Wound Closure Under Local Anesthesia As Most Adequate Treatment Approach!. Open Access Maced J Med Sci. 2019 Feb 15; 7(3):400-402. <https://doi.org/10.3889/oamjms.2019.148>

Keywords: Hidradenitis suppurativa; Acne inversa; Treatment; Serial excisions; Local anaesthesia; Recurrence

***Correspondence:** Ivanka Temelkova. Medical Institute of Ministry of Interior (MVR), Department of Dermatology, Venereology and Dermatologic surgery, General Skobelev 79, 1606 Sofia; Onkoderma - Clinic for Dermatology, Venereology and Dermatologic Surgery, General Skobelev 26, 1606 Sofia. E-mail: vanz2991@gmail.com

Received: 15-Jan-2018; **Revised:** 05-Feb-2019; **Accepted:** 06-Feb-2019; **Online first:** 11-Feb-2019

Copyright: © 2019 Georgi Tchernev, Ivanka Temelkova. This is an open-access article distributed under the terms of the Creative Commons Attribution-NonCommercial 4.0 International License (CC BY-NC 4.0)

Funding: This research did not receive any financial support

Competing Interests: The authors have declared that no competing interests exist

BACKGROUND: Acne inversa as a chronic inflammatory disorder can be divided into three stages according to Hurley's classification. It affects the axillary and anogenital region predominantly, and its chronic course of development is associated with a major negative impact on quality of life, especially in young patients. We discuss the different types of treatment in patients with acne inversa and the benefits of two-stage surgical treatment by serial excisions with primary wound closure under local anaesthesia.

CASE REPORT: We present a 28-year-old man with hidradenitis suppurativa stage I in the right axillary region and also in the pubic area. The patient is an active smoker. The patient was treated with Rifampicin 2x 300mg / day without any particular effect and preoperatively, systemic therapy with Clindamycin 4x 600mg / day was performed, combined with daily dressings with jodasept ointment for 7 days. The patient was treated through two surgical sessions under local anaesthesia with elliptical excision of the lesions located in the right axillary and the pubic area. Both of the two surgical defects were initially closed with single interrupted sutures. Histological examination of both lesions revealed the presence of suppurative folliculitis.

CONCLUSION: The literature describes various methods for treating acne inversa which include both systemic and local approaches. However, it is considered that drug therapy achieves only a temporary improvement in patients with hidradenitis suppurativa. For this reason, the surgical treatment of acne inversa is indicated as the only curative treatment, especially for recurrent lesions and serial excisions under local anaesthesia, followed by primary wound closure is a valuable treatment for patients with mild to moderate HS (Hurley stage I & II).

Introduction

Acne inversa (AI) (Hidradenitis suppurativa (HS)) is a chronic inflammatory disorder of the apocrine glands, which usually affects the axillary and anogenital region [1]. The main problem with this disease is the chronic course of development with a major negative impact on quality of life and significant co-morbidity in the cases of severe acne inversa (secondary lymphedema, hypertension, diabetes mellitus type II, obesity, metabolic syndrome and others) [1].

According to Hurley's classification, hidradenitis suppurativa can be divided into three clinical stages: Stage I: abscess formation, single or multiple without sinus tracts and scarring; Stage II: recurrent abscesses with sinus tracts and scarring; single or multiple widely separated lesions; Stage III:

diffuse or almost diffuse involvement or multiple interconnected tracts and abscesses [2].

Case Report

We present a 28-year-old man in good overall condition. The patient is an active smoker for 14 years (1 box per day). For several years, an acne inversa has been diagnosed. The patient was hospitalized for the surgical treatment of hidradenitis suppurativa within two surgical sessions. During the dermatological examination in the right axillary region and the pubic area the presence of erythema nodules filled with purulent content, clinically defined as hidradenitis suppurativa stage I, was established (Figure 1a, 1b, and 2a). In the right axillary region,

post-inflammatory hyperpigmentations and a scar of surgical intervention performed in the past were observed (Figure 1a, and 1b).

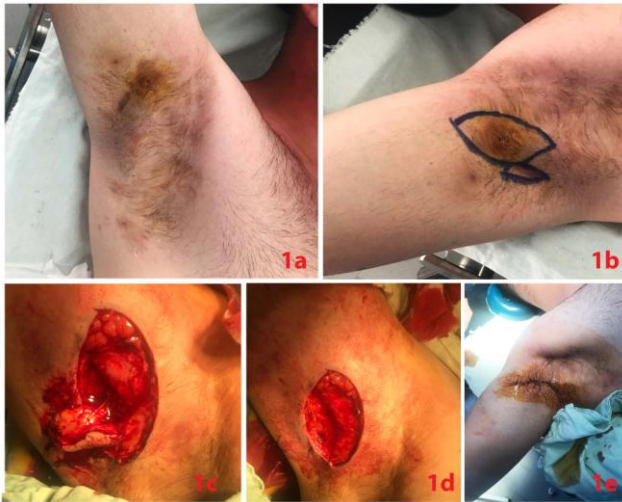


Figure 1: a) Clinical view of acne inversa: erythema nodules in the right axillary region; b) Preoperative finding: outlining the surgical margins; d) Intraoperative view: elliptical excision of the lesion in the right axillary region; e) Postoperative finding: surgical defect closed by single interrupted sutures

Post-inflammatory hyperpigmentations were also observed in the pubic area (Figure 2a). The patient was treated with Rifampicin 2 x 300 mg/day without any particular effect. Preoperatively, systemic therapy with Clindamycin 4 x 600 mg/day was performed, and dressings with jodasept ointment were applied topically for 7 days. In the first operative session, an elliptical excision was performed under local anaesthesia of the lesion located in the right axillary region (Figure 1b, and 1d). The surgical defect was primarily closed with single interrupted sutures (Figure 1e). A sterile bandage with jodasept ointment was made. The subsequent histological examination revealed the presence of suppurative folliculitis. In the second stage, an elliptical excision of erythema nodule in the pubic area was performed again under local anaesthesia with lidocaine (Figure 2b, and 2c). The occurred surgical defect was initially closed with single interrupted sutures (Figure 2d). Histological data was again about hidradenitis suppurativa. A smooth postoperative period was observed without complications and perfect cosmetic results.

Discussion

Treatment of acne inversa includes several basic options-topical options, systemic options and surgical methods, including laser therapy [1], [3]. About drug therapy, long-term antibiotics (clindamycin, rifampicin) or acitretin monotherapy, antiandrogens, tumour necrosis- α inhibitors (TNF α)

may be used, which may lead to improvement in milder cases of AI, but they are not curative [1], [3], [4].

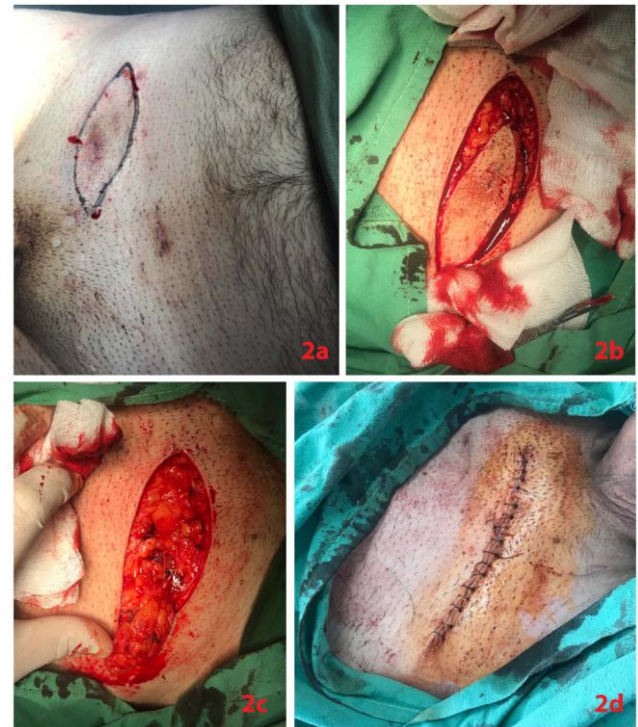

Figure 2: a) Clinical view of acne inversa: erythema nodules in the pubic area; b) and c) Intraoperative view: elliptical excision of the lesion in the pubic area; d) Postoperative finding: surgical defect closed by single interrupted sutures

It is believed that treatment with antibiotics or anti-inflammatory drugs such as prednisone or TNF- α -inhibitors usually achieves only temporary improvement and patients with advanced AI treated by combinations of antibiotics need up to 12 months before some of them achieve a temporary remission [1], [4]. As HS has a follicular pathogenesis Lasers and intense pulsed light (IPL) treatment have been found useful by reducing the numbers of hairs in areas with HS [5]. However, according to some authors, as we think, surgery should be introduced earlier in the management of acne inversa [6]. Furthermore, according to the literature, surgical intervention is considered as the only curative treatment for recurrent lesions, and for patients with mild to moderate HS (Hurley stage I & II), local excision followed by primary closure is a valuable treatment with low morbidity and a high patient satisfaction rate [4]. The risk of long-term signs of recurrence, most often near the surgical field, should be noted in surgical excisions under local anaesthesia (mainly wide excisions for Hurley Stages II to III) [7].

In conclusion, based on the results of our patient, we support the thesis that, for mild to moderate cases of hidradenitis suppurativa, serial excisions under local anaesthesia should be considered as first-line therapy.

References

1. Wollina U, Koch A, Heinig B, Kittner T, Nowak A. Acne inversa (Hidradenitis suppurativa): A review with a focus on pathogenesis and treatment. *Indian Dermatol Online J.* 2013; 4(1): 2–11. <https://doi.org/10.4103/2229-5178.105454> PMID:23439959 PMCID:PMC3573446
2. Collier F, Smith R, Morton C. Diagnosis and management of hidradenitis suppurativa. *BMJ.* 2013; 346:f2121. <https://doi.org/10.1136/bmj.f2121> PMID:23613539
3. Alikhan A, Lynch P, Eisen D. Hidradenitis suppurativa: a comprehensive review. *J Am Acad Dermatol.* 2009; 60(4):539-61. <https://doi.org/10.1016/j.jaad.2008.11.911> PMID:19293006
4. van Rappard D, Mooij J, Mekkes J. Mild to moderate hidradenitis suppurativa treated with local excision and primary closure. *J Eur Acad Dermatol Venereol.* 2012; 26(7):898-902. <https://doi.org/10.1111/j.1468-3083.2011.04203.x> PMID:21812838
5. Saunte D, Lapins J. Lasers and Intense Pulsed Light Hidradenitis Suppurativa. *Dermatol Clin.* 2016; 34(1):111-9. <https://doi.org/10.1016/j.det.2015.08.001> PMID:26617364
6. Vellaichamy G, Braunberger T, Nahhas A, Hamzavi I. Surgical procedures for hidradenitis suppurativa. *Cutis.* 2018; 102(1):13-16. PMID:30138502
7. Walter A, Meissner M, Kaufmann R, Valesky E, Pinter A. Hidradenitis Suppurativa After Radical Surgery-Long-Term Follow-up for Recurrences and Associated Factors. *Dermatol Surg.* 2018; 44(10):1323-1331. <https://doi.org/10.1097/DSS.0000000000001668> PMID:30204742