



## A computed tomography analysis of three-dimensional glenoid orientation modified by glenoid torsion

Noboru Matsumura, MD\*, Satoshi Oki, MD, Taku Suzuki, MD, Takuji Iwamoto, MD, Kazuki Sato, MD, Masaya Nakamura, MD, Morio Matsumoto, MD, Takeo Nagura, MD

Department of Orthopedic Surgery, Keio University School of Medicine, Tokyo, Japan

### ARTICLE INFO

#### Keywords:

Glenoid morphology  
glenoid version  
glenoid retroversion  
glenoid inclination  
glenoid torsion  
shoulder arthroplasty

Level of Evidence: Anatomy Study, Imaging

### ABSTRACT

**Background:** The longitudinal axis of the glenoid is not always parallel to the scapular body, and glenoid torsion could affect the values of glenoid orientation. The purpose of this study was to evaluate 3-dimensional glenoid version and inclination modified by glenoid torsion and to clarify the differences between the values of conventional and of modified glenoid orientations.

**Methods:** Computed tomography scans of 30 shoulders without shoulder pathology, 30 shoulders with primary osteoarthritis, and 30 shoulders with a massive rotator cuff tear or cuff tear arthropathy were retrospectively evaluated. After determining the glenoid axis and the scapular planes and calculating conventional glenoid version and inclination, modified glenoid version and inclination, and glenoid torsion, the values of conventional glenoid orientation and those of modified glenoid orientation were compared statistically.

**Results:** All shoulders showed anterior torsion of the glenoid with an average of  $16^\circ \pm 5^\circ$ . The values of modified glenoid retroversion were significantly smaller than those of conventional glenoid retroversion in all groups ( $P < .033$ ), and the values of the modified glenoid inferior inclination were significantly larger than those of conventional glenoid inferior inclination in all groups ( $P < .001$ ).

**Conclusions:** The present study showed that the glenoid twists with respect to the scapular body and that modification by glenoid torsion could affect the values of glenoid orientation. These results indicated that glenoid orientation with respect to the glenoid longitudinal axis will help surgeons determine proper placement of the glenoid component during shoulder arthroplasty.

© 2018 The Author(s). Published by Elsevier Inc. on behalf of American Shoulder and Elbow Surgeons. This is an open access article under the CC BY-NC-ND license. (<http://creativecommons.org/licenses/by-nc-nd/4.0/>)

Glenoid orientation is associated with several kinds of shoulder pathologies<sup>1,3,33,36</sup> and has often been assessed when planning shoulder operations.<sup>9,12,15</sup> Some arthritic glenoids have retroversion with a posterior bone defect,<sup>6,12,17,30</sup> and excessive retroversion is related to poor outcomes after arthroplasty.<sup>9,10,36</sup> As well as glenoid version, glenoid inclination is an important parameter for shoulder arthroplasty. Superior inclination of the glenoid is associated with cuff deficiency<sup>1,11</sup> and is reported to be a risk factor for poor outcomes after reverse shoulder arthroplasty.<sup>32</sup> Inferior inclination of the glenoid component can improve clinical outcomes of anatomic and reverse shoulder arthroplasties.<sup>20,26,27</sup>

In measuring glenoid orientation, 2-dimensional analyses with axial computed tomography (CT)<sup>12,25,36</sup> and plain radiographs<sup>3,23,27</sup>

have commonly been used. Because the scapula inclines on the thorax and scapular rotation could change the values of glenoid orientation, some 2-dimensional studies have measured glenoid orientation on a 3-dimensionally corrected slice, including the scapular body, to exclude the effect of scapular inclination to the thorax.<sup>1,4,5,15</sup> Recent studies evaluated 3-dimensional glenoid orientation with respect to the scapular body.<sup>8,21,22</sup> Because the glenoid longitudinal axis is not always parallel to the scapular body, however, the measured values of glenoid orientation might not provide useful information for shoulder surgery. Although numerous studies have analyzed glenoid version and inclination, glenoid torsion between the scapular body and the glenoid has not been considered.

We hypothesized that the glenoid twists with respect to the scapular body and that the values of glenoid orientation differ with and without modification by glenoid torsion. The purpose of this study was to evaluate 3-dimensional glenoid orientation modified by glenoid torsion and to clarify the differences between the values of the conventional and modified orientations of the glenoid surface using CT scans.

The Keio University School of Medicine Institutional Review Board approved this study (Reference study number 20130147).

\* Corresponding author: Noboru Matsumura, MD, Department of Orthopedic Surgery, Keio University School of Medicine, 35 Shinanomachi, Shinjuku-ku, Tokyo 160-8582, Japan.

E-mail address: [noboru18@gmail.com](mailto:noboru18@gmail.com) (N. Matsumura).

<https://doi.org/10.1016/j.jses.2018.07.002>

2468-6026/© 2018 The Author(s). Published by Elsevier Inc. on behalf of American Shoulder and Elbow Surgeons. This is an open access article under the CC BY-NC-ND license. (<http://creativecommons.org/licenses/by-nc-nd/4.0/>)

## Materials and methods

This study retrospectively evaluated CT scans of 30 shoulders with primary osteoarthritis (OA), which were taken in our institution between March 2014 and October 2017 (OA group: mean age,  $75 \pm 7$  years; range, 61–86 years; 25 women and 5 men; 16 right, 14 left), and 30 shoulders with a massive rotator cuff tear or cuff tear arthropathy (CTA) between September 2014 and October 2017 (CTA group: mean age,  $75 \pm 6$  years; range, 64–86 years; 21 women and 9 men; 18 right and 12 left). According to the Walch classification scheme,<sup>36</sup> 3 shoulders in the OA group were classified as type A1, 15 as type A2, 2 as type B1, and 9 as type B2. The 30 shoulders in the CTA group showed a rotator cuff tear involving 2 or more tendons on magnetic resonance imaging.<sup>13</sup> According to the Sirveaux classification scheme<sup>32</sup>, 18 shoulders were classified as type E0, 4 as type E1, 6 as type E2, and 2 as type E3 on plain radiographs. For comparison, pre-operative bilateral CT scans of 30 shoulders with unilateral glenohumeral instability were enrolled (control group: mean age,  $26 \pm 9$  years; range, 16–49 years; 15 women and 15 men; 15 right and 15 left). The contralateral shoulders of patients with glenohumeral instability without any pathology in the shoulder girdle were evaluated and did not show any evidence of glenohumeral bone loss or arthritis on CT scans. Thus, the study reviewed a total of 90 shoulders.

Axial CT scans, including the entire scapula from its medial border and from its inferior angle to the glenohumeral joint, were taken with a resolution of 0.98 mm per pixel and reconstructed with 1-mm-thick slices (Toshiba Aquilion ONE; Toshiba Medical Systems, Tochigi, Japan). The image data were extracted in the obtained Digital Imaging and Communication in Medicine (DICOM) data format (National Electrical Manufacturers Association, Rosslyn, VA, USA).

The bony landmarks on the scapula were determined from the obtained DICOM data. To assess 3-dimensional glenoid orientation, the subchondral bone of the glenoid articular surface was plotted with 2-mm intervals from the anterior glenoid rim and posterior rim in all slices including the glenoid using OsiriX MD 8.5.2 software (Pixmeo, Geneva, Switzerland). The glenoid plane was defined as the best fitting plane, which was reconstructed from all of the plotted points of the glenoid surface.<sup>24</sup> A line perpendicular to the glenoid plane was defined as the glenoid axis (Fig. 1, A).

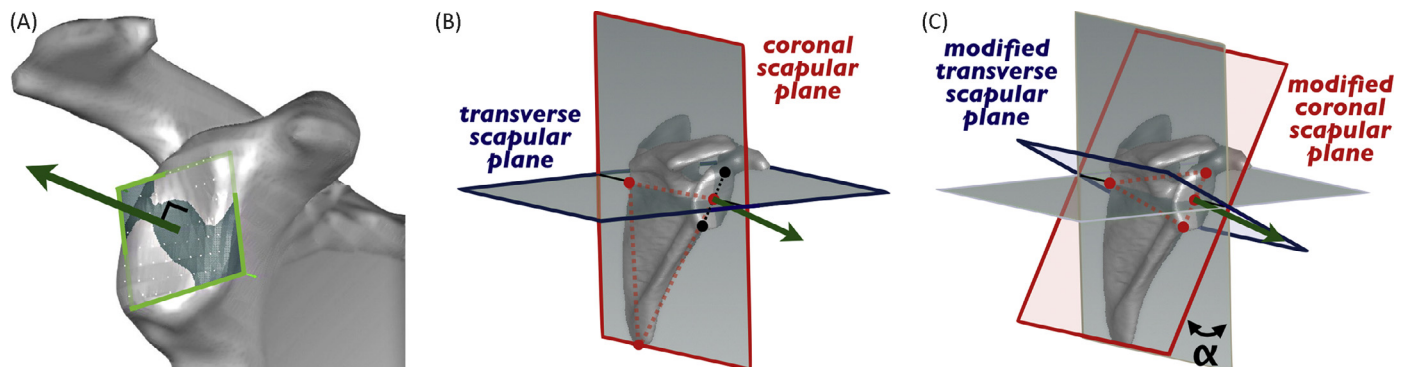
A 3-dimensional scapular model was reconstructed in AVIZO 6.2 software (Maxnet, Tokyo, Japan), and the root of the scapular spine, inferior angle of the scapular body, and superior and inferior poles of the glenoid were plotted on the models using MeshLab 1.3.3 software

(ISTI, Pisa, Italy). The root of the scapular spine was determined as the most medial point of the scapular spine, where the spine curves inferiorly and combines with the scapular body. The inferior angle was defined as the most inferior point of the scapular body. The superior pole of the glenoid was set as the supraglenoid tubercle of the ovoid glenoid surface, where the long head of the biceps tendon is thought to originate,<sup>31</sup> and the inferior pole was set as the furthest point from the superior pole on the glenoid surface.<sup>1,2,15,29</sup> The midpoint between the superior pole and the inferior pole of the glenoid was set as the glenoid center.<sup>15</sup>

The scapular anatomic planes were defined based on scapular landmarks.<sup>4-7,14,18,30</sup> The coronal scapular plane was defined as the plane passing through 3 landmarks of the root of the scapular spine, the inferior angle of the scapular body, and the glenoid center, and the transverse scapular plane was perpendicular to the coronal scapular plane and included the root of the spine and the glenoid center (Fig. 1, B). The modified transverse scapular plane was defined as the plane including the root of the scapular spine and the superior and inferior poles of the glenoid, and the modified transverse plane was perpendicular to the modified coronal plane and included the root of the spine and the glenoid center. Glenoid torsion was evaluated as the angle between the coronal scapular plane and the modified coronal scapular plane (Fig. 1, C).

Three-dimensional glenoid orientation was determined with the glenoid axis and the scapular planes. Conventional glenoid version, which was defined as the angle between the glenoid axis and the coronal scapular plane, and conventional glenoid inclination, which was the angle between the glenoid axis and the transverse scapular plane, were evaluated. Modified glenoid version was defined as the angle between the glenoid axis and the modified coronal scapular plane, and modified glenoid inclination was the angle between the glenoid axis and the modified transverse scapular plane. All shoulders were independently reviewed twice with a minimum of a 1-month interval between measurements by 2 evaluators.

For the statistical analyses, IBM SPSS Statistics 23.0.0.2 software (IBM, Armonk, NY, USA) was used. Intraclass correlation coefficients (ICCs) were used to evaluate intra-rater and inter-rater reliabilities for modified glenoid version, modified glenoid inclination, and glenoid torsion. Repeated measurements by 2 observers with a 1-month interval (ICC model 1,1) and blinded measurements by 2 observers (ICC model 2,1) were performed. After reliabilities were determined, the values of glenoid version, inclination, and torsion were averaged across the 2 observers and their 2 measurements.



**Figure 1** (A) The glenoid plane (surrounded by green lines) is defined as the best fitting plane, which is reconstructed from all of the plotted points of the glenoid surface. A line perpendicular to the glenoid plane is defined as the glenoid axis (green line with arrow). (B) The coronal scapular plane (surrounded by red lines) is defined as the plane passing through 3 landmarks of the root of the scapular spine, the inferior angle of the scapular body, and the glenoid center. The transverse scapular plane (surrounded by blue lines) is perpendicular to the coronal scapular plane and includes the root of the spine and the glenoid center. Conventional glenoid orientation is determined with the angle between the glenoid axis (green line with arrow) and the scapular planes. The longitudinal axis of the glenoid (black dotted line) is not parallel to the scapular body. (C) The modified transverse scapular plane (surrounded by red lines) is defined as the plane including the root of the scapular spine, the superior pole of the glenoid, and the inferior pole of the glenoid. The modified transverse plane (surrounded by blue lines) is perpendicular to the modified coronal plane and includes the root of the spine and the glenoid center. Modified glenoid orientation is determined with the angle between the glenoid axis (green line with arrow) and the modified scapular planes. Glenoid torsion ( $\alpha$ ) is calculated as the angle between the coronal scapular plane and the modified coronal scapular plane.

**Table 1**  
The values of glenoid orientation and differences by etiology

Variable	Control group (N=30) (°)	OA group (N=30) (°)	CTA group (N=30) (°)	P value
Modified retroversion	2 ± 3 (-5 to 8)	7 ± 9 (-9 to 21)	3 ± 5 (-9 to 12)	.002*
Modified inferior inclination	7 ± 3 (1-12)	11 ± 6 (-3 to 24)	1 ± 6 (-15 to 11)	<.001**
Anterior torsion	19 ± 4 (13-29)	17 ± 5 (8-26)	12 ± 5 (2-22)	<.001**

OA, osteoarthritis; CTA, cuff tear arthropathy.

Data are presented as the mean ± standard deviation (range).

\* Statistically significant ( $P < .01$ ).

\*\* Statistically significant ( $P < .001$ ).

To examine the differences by etiology, differences in modified glenoid version, modified glenoid inclination, and glenoid torsion were compared among the control group, OA group, and CTA group using 1-way analysis of variance. With significant effects, post hoc Mann-Whitney  $U$  tests with the Bonferroni correction were performed to identify the differences between the groups. Paired  $t$  tests were used to compare the values of conventional glenoid orientation (retroversion and inferior inclination) to those of modified glenoid orientation. The values of the differences between conventional and modified retroversion and between conventional and modified inferior inclination were also computed by subtraction of the conventional values from the modified values. The correlation between the values of modified glenoid orientation and the difference in glenoid orientation was analyzed using Spearman rank correlation tests. The significance level was set at .05 for all analyses.

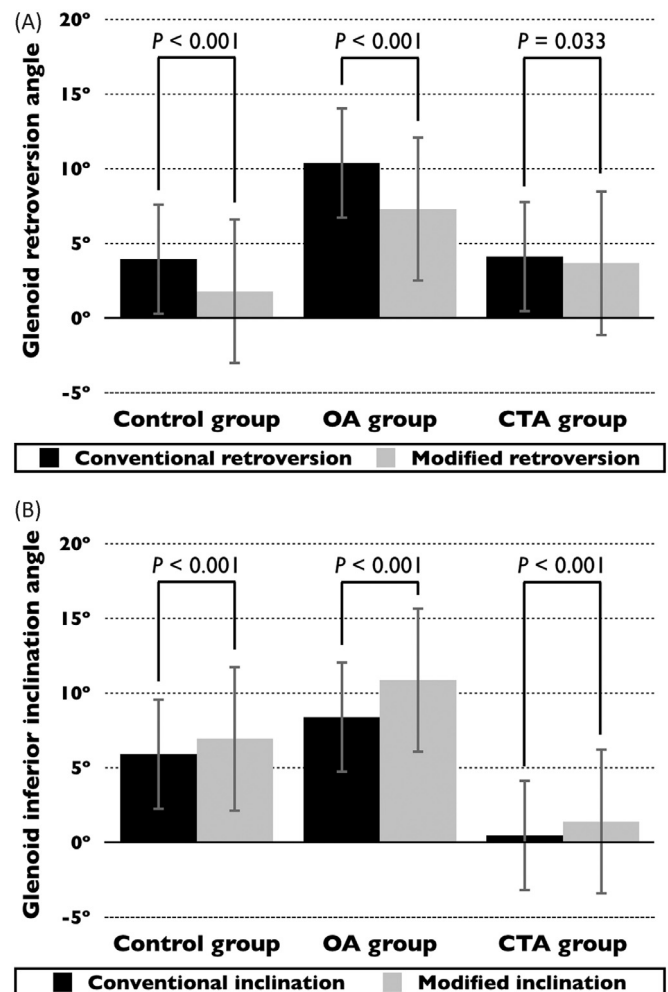
## Results

Intra-rater reliability was 0.908 (95% confidence interval [CI], 0.786-0.962) for modified glenoid version, 0.848 (95% CI, 0.662-0.937) for modified glenoid inclination, and 0.928 (95% CI, 0.828-0.971) for glenoid torsion. Inter-rater reliability was 0.872 (95% CI, 0.707-0.947) for modified glenoid version, 0.821 (95% CI, 0.518-0.931) for modified glenoid inclination, and 0.910 (95% CI, 0.788-0.882) for glenoid torsion. Intra-rater and inter-rater reliabilities exceeded 0.8 for glenoid orientation measurement and were regarded as good to excellent.

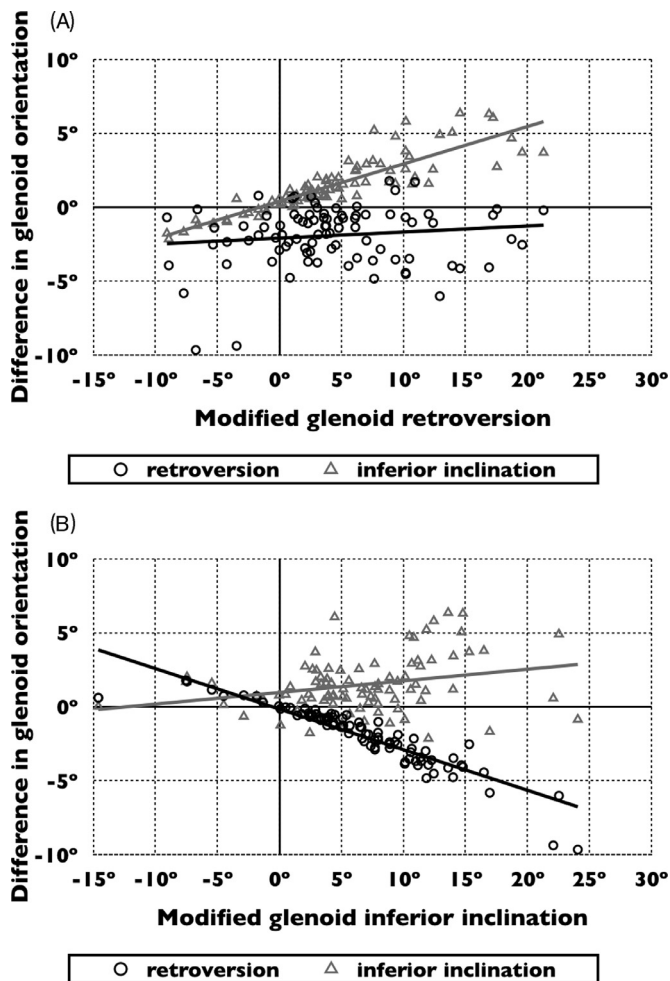
In this study, a positive number means retroversion, inferior inclination, and anterior torsion, and a negative number means anteversion, superior inclination, and posterior torsion of the glenoid. The glenoid had an average modified retroversion of  $4^\circ \pm 6^\circ$  (range,  $-9^\circ$  to  $21^\circ$ ) and modified inferior inclination of  $6^\circ \pm 7^\circ$  (range,  $-15^\circ$  to  $24^\circ$ ). All glenoids showed anterior torsion with respect to the scapular body, with an average of  $16^\circ \pm 5^\circ$  (range,  $2^\circ$ - $29^\circ$ ). The values of glenoid orientation varied by etiology (Table 1). The values of modified glenoid retroversion were significantly larger in the OA group than in the control group ( $P = .021$ ). The values of modified glenoid inferior inclination were significantly larger in the OA group than in the other 2 groups ( $P = .012$  in the control group and  $P < .001$  in CTA group), and the values were significantly smaller in the CTA group than in the control group ( $P < .001$ ). The values of glenoid anterior torsion were significantly larger in the control group than in the OA group ( $P < .001$ ) and CTA group ( $P = .003$ ).

The values of modified glenoid retroversion were significantly smaller than those of conventional glenoid retroversion in all groups ( $P < .001$  in the control and OA groups and  $P = 0.033$  in CTA group; Fig. 2, A). The values of modified glenoid inferior inclination were significantly larger than those of conventional glenoid inferior inclination in all groups ( $P < .001$  in all groups; Fig. 2, B). The value of modified glenoid retroversion had a strong positive correlation with

the difference between conventional inferior inclination and modified inferior inclination of the glenoid ( $R = 0.919$  and  $P < .001$ ), but no correlation was found with the difference between conventional retroversion and modified retroversion ( $R = 0.502$  and  $P < .001$ ; Fig. 3, A). The value of modified glenoid inferior inclination had a strong negative correlation with the difference between conventional



**Figure 2** (A) Conventional and modified glenoid retroversion of the 3 groups. The values of modified glenoid retroversion are significantly smaller than those of conventional glenoid retroversion in all 3 groups. (B) Conventional and modified glenoid inferior inclination of the 3 groups. The values of modified glenoid inferior inclination are significantly larger than those of conventional glenoid inferior inclination in all 3 groups. Mean data are presented with standard deviation (range bars). OA, osteoarthritis; CTA, cuff tear arthropathy.



**Figure 3** (A) Correlation between the values of modified glenoid retroversion and the differences between conventional glenoid orientation and modified glenoid orientation. The value of modified glenoid retroversion has a strong positive correlation with the difference in glenoid inferior inclination ( $R=0.919$  and  $P<.001$ ). (B) Correlation between the value of modified glenoid inferior inclination and the difference between conventional glenoid orientation and modified glenoid orientation. The values of modified glenoid inferior inclination have a strong negative correlation with the differences in glenoid retroversion ( $R=-0.961$  and  $P<.001$ ) and a weak positive correlation with the difference in glenoid inferior inclination ( $R=0.265$  and  $P=.012$ ). OA, osteoarthritis; CTA, cuff tear arthropathy.

retroversion and modified retroversion of the glenoid ( $R=-0.961$  and  $P<.001$ ) and a weak positive correlation with the difference between conventional inferior inclination and modified inferior inclination of the glenoid ( $R=0.265$  and  $P=.012$ ; Fig. 3, B). On one hand, the absolute difference between conventional and modified glenoid version exceeded  $3^\circ$  in 24.4% and  $5^\circ$  in 4.4% of all shoulders. On the other hand, the absolute difference between conventional and modified glenoid inclination exceeded  $3^\circ$  in 16.7% and  $5^\circ$  in 6.7% of all 90 shoulders.

## Discussion

Scapular morphology appears to be modular.<sup>19</sup> The glenoid can rotate medially or laterally, superiorly or inferiorly, and anteriorly or posteriorly in relation to the scapular body. Although glenoid version and inclination have been recognized as important parameters for shoulder pathologies, glenoid torsion has rarely been considered. This study showed that the glenoid usually has anterior torsion with respect to the scapular body and that modification by glenoid torsion could affect the values of glenoid orientation.

Although glenoid version and inclination is reported to be associated with several kinds of shoulder pathologies,<sup>1,3,33,36</sup> glenoid torsion between the scapular body and the glenoid has not been evaluated. The present study found the glenoid rotates anteriorly, and our control glenoid had an average anterior torsion of  $19^\circ$ . The values of glenoid anterior torsion were significantly larger in the control group than in the OA and CTA groups. In our shoulders with central migration of the glenoid, the glenoid longitudinal axis was likely to approach to the scapular body plane. The present results indicated that glenoid central migration might decrease the values of glenoid anterior torsion.

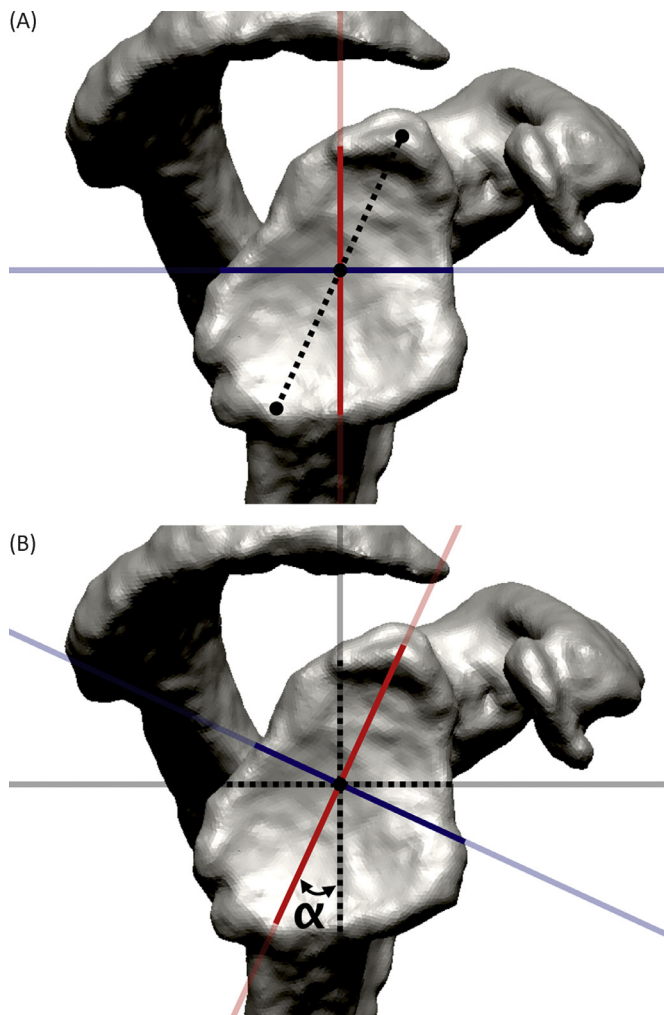
The direction of the glenoid surface can be interpreted with glenoid version and inclination with respect to the scapula. The glenoid surface is the only index of the scapula during glenoid implantation and is compared to a clock face to assess bone wear in cases with shoulder instability<sup>29</sup> or glenohumeral arthritis.<sup>15</sup> Unfortunately, however, the glenoid longitudinal axis, which connects the superior and inferior poles of the glenoid, is not parallel to the scapular body because it usually twists anteriorly with respect to the scapular body. Because the values of glenoid version and inclination change with modification by glenoid torsion, conventional glenoid orientation might not provide useful information for shoulder surgery. Bouchaib et al<sup>2</sup> evaluated 2-dimensional glenoid version on the reconstructed axial plane perpendicular to the longitudinal axis of the glenoid surface. During shoulder arthroplasty, it is important to recognize the respective glenoid orientation for proper placement of the glenoid component within the glenoid vault.<sup>15,16,28,34</sup> Unless the preoperatively measured values represent proper glenoid orientation, the glenoid would be reconstructed inadequately. We expect that glenoid orientation with respect to the glenoid longitudinal axis will help surgeons with operative management.

The glenoids in the OA group showed larger retroversion and larger inferior inclination than in the other groups, and biconcave glenoids are reported to have posteroinferior bone defects of the glenoid.<sup>17</sup> When glenoid orientation is assessed with respect to the scapular body, overestimation of glenoid retroversion is likely to increase in cases with large inferior inclination, and underestimation of glenoid inferior inclination increases in cases with large retroversion of the glenoid (Fig. 4). If the glenoid orientation is not restored during anatomic shoulder arthroplasty, the shear force to the glenoid component might increase.<sup>16</sup> The present results indicate that glenoid orientation should be assessed with respect to the glenoid longitudinal axis in the operative management of asymmetric posteroinferior bone loss of arthritic glenoids.

This study evaluated conventional and modified glenoid orientations in the same shoulders without redefinition of the scapular bony landmarks. The present study had several limitations. The number of shoulders was relatively small, and the OA group and the CTA group included various types of glenoids. Thus, differences in glenoid orientation among shoulder pathologies remained unclear.

Clinical significance would be another possible limitation. This study showed that the conventional measuring method referring to the scapular body overestimates glenoid retroversion and underestimates glenoid inferior inclination. Modification by glenoid torsion could change the values of glenoid orientation up to  $10^\circ$ , but whether the differences would affect the clinical outcomes of shoulder arthroplasty remains unclear.

The third limitation was the position of the glenoid center. To assess the effect of glenoid torsion, this study defined the glenoid center as the midpoint between the superior pole and the inferior pole of the glenoid, and conventional and modified scapular planes were both defined to include the root of the scapular spine and the glenoid center. However, the position of the glenoid center changes with the reference systems<sup>35</sup> and can affect the values of glenoid orientation. Furthermore, the longitudinal axis of the glenoid surface was defined on CT data in this study, but this axis might differ from the intraoperative superiorinferior axis that is determined during arthroplasty.



**Figure 4** (A) A 68-year-old woman with primary osteoarthritis. The biconcave glenoid has retroversion of  $6^\circ$  with respect to the conventional coronal scapular plane (red solid line) and inferior inclination of  $22^\circ$  with respect to the conventional transverse scapular plane (blue solid line). (B) The glenoid has anterior torsion of  $25^\circ$  ( $\alpha$ ) with respect to the scapular body. With modification by glenoid torsion, the glenoid shows anteversion of  $3^\circ$  with respect to the modified coronal scapular plane (red solid line) and inferior inclination of  $22^\circ$  with respect to the modified coronal scapular plane (blue solid line).

Finally, the control group consisted of contralateral shoulders of patients with unilateral glenohumeral instability. Although these shoulders did not have any shoulder pathology and appeared to be normal, glenohumeral instability might affect the morphology of the contralateral shoulders.

## Conclusions

Three-dimensional glenoid orientation was evaluated with modification by glenoid torsion. The present study showed that the glenoid twists with respect to the scapular body and that modification by glenoid torsion could affect the values of glenoid orientation. The values of modified glenoid retroversion were significantly smaller than those of conventional glenoid retroversion, and the values of modified glenoid inferior inclination were significantly larger than those of conventional glenoid inferior inclination. These results indicate that glenoid orientation with respect to the glenoid longitudinal axis will help surgeons determine proper placement of the glenoid component during shoulder arthroplasty.

## Disclaimer

This work was supported by Japan Society for the Promotion of Science (JSPS) Grant-in-Aid for Scientific Research (KAKENHI) Grant Number JP17K16703.

The authors, their immediate families, and any research foundations with which they are affiliated have not received any financial payments or other benefits from any commercial entity related to the subject of this article.

## References

- Bishop JL, Kline SK, Alderink KJ, Zuel R, Bey MJ. Glenoid inclination: in vivo measures in rotator cuff tear patients and associations with superior glenohumeral joint translation. *J Shoulder Elbow Surg* 2009;18:231-6. <http://dx.doi.org/10.1016/j.jse.2008.08.002>
- Bouchaib J, Clavert P, Kempf JF, Kahn JL. Morphological analysis of the glenoid version in the axial plane according to age. *Surg Radiol Anat* 2014;36:579-85. <http://dx.doi.org/10.1007/s00276-013-1238-6>
- Brewer BJ, Wubben RC, Carrera GF. Excessive retroversion of the glenoid cavity. A cause of non-traumatic posterior instability of the shoulder. *J Bone Joint Surg Am* 1986;68:724-31.
- Bryce CD, Davison AC, Lewis GS, Wang L, Flemming DJ, Armstrong AD. Two-dimensional glenoid version measurements vary with coronal and sagittal scapular rotation. *J Bone Joint Surg Am* 2010;92:692-9. <http://dx.doi.org/10.2106/JBJS.L.00177>
- Budge MD, Lewis GS, Schaefer E, Coquia S, Flemming DJ, Armstrong AD. Comparison of standard two-dimensional and three-dimensional corrected glenoid version measurements. *J Shoulder Elbow Surg* 2011;20:577-83. <http://dx.doi.org/10.1016/j.jse.2010.11.003>
- Chalmers PN, Salazar D, Chamberlain A, Keener JD. Radiographic characterization of the B2 glenoid: the effect of computed tomographic axis orientation. *J Shoulder Elbow Surg* 2017;26:258-64. <http://dx.doi.org/10.1016/j.jse.2016.07.021>
- Churchill RS, Brems JJ, Kotschi H. Glenoid size, inclination, and version: an anatomic study. *J Shoulder Elbow Surg* 2001;10:327-32.
- De Wilde LF, Verstraeten T, Speeckaert W, Karelse A. Reliability of the glenoid plane. *J Shoulder Elbow Surg* 2010;19:414-22. <http://dx.doi.org/10.1016/j.jse.2009.10.005>
- Denard PJ, Walch G. Current concepts in the surgical management of primary glenohumeral arthritis with a biconcave glenoid. *J Shoulder Elbow Surg* 2013;22:1589-98. <http://dx.doi.org/10.1016/j.jse.2013.06.017>
- Farron A, Terrier A, Büchler P. Risks of loosening of a prosthetic glenoid implanted in retroversion. *J Shoulder Elbow Surg* 2006;15:521-6. <http://dx.doi.org/10.1016/j.jse.2005.10.003>
- Flieg NG, Gatti CJ, Doro LC, Langenderfer JE, Carpenter JE, Hughes RE. A stochastic analysis of glenoid inclination angle and superior migration of the humeral head. *Clin Biomech (Bristol, Avon)* 2008;23:554-61. <http://dx.doi.org/10.1016/j.clinbiomech.2008.01.001>
- Friedman RJ, Hawthorne KB, Genes BM. The use of computerized tomography in the measurement of glenoid version. *J Bone Joint Surg Am* 1992;74:1032-7.
- Gerber C, Fuchs B, Hodler J. The results of repair of massive tears of the rotator cuff. *J Bone Joint Surg Am* 2000;82:505-15.
- Ghafurian S, Galdi B, Bastian S, Tan V, Li K. Computerized 3D morphological analysis of glenoid orientation. *J Orthop Res* 2016;34:692-8. <http://dx.doi.org/10.1002/jor.23053>
- Hoenecke HR Jr, Hermida JC, Flores-Hernandez C, D'Lima DD. Accuracy of CT-based measurements of glenoid version for total shoulder arthroplasty. *J Shoulder Elbow Surg* 2010;19:166-71. <http://dx.doi.org/10.1016/j.jse.2009.08.009>
- Karelse A, Van Tongel A, Verstraeten T, Poncet D, De Wilde LF. Rocking-horse phenomenon of the glenoid component: the importance of inclination. *J Shoulder Elbow Surg* 2015;24:1142-8. <http://dx.doi.org/10.1016/j.jse.2014.12.017>
- Knowles NK, Keener JD, Ferreira LM, Athwal GS. Quantification of the position, orientation, and surface area of bone loss in type B2 glenoids. *J Shoulder Elbow Surg* 2015;24:503-10. <http://dx.doi.org/10.1016/j.jse.2014.08.021>
- Kwon YW, Powell KA, Yum JK, Brems JJ, Iannotti JP. Use of three-dimensional computed tomography for the analysis of the glenoid anatomy. *J Shoulder Elbow Surg* 2005;14:85-90. <http://dx.doi.org/10.1016/j.jse.2004.04.011>
- Landau JP, Hoenecke HR. Genetic and biomechanical determinants of glenoid version: implications for glenoid implant placement in shoulder arthroplasty. *J Shoulder Elbow Surg* 2009;18:661-7. <http://dx.doi.org/10.1016/j.jse.2008.11.012>
- Laver L, Garrigues GE. Avoiding superior tilt in reverse shoulder arthroplasty: a review of the literature and technical recommendations. *J Shoulder Elbow Surg* 2014;23:1582-90. <http://dx.doi.org/10.1016/j.jse.2014.06.029>
- Lewis GS, Armstrong AD. Glenoid spherical orientation and version. *J Shoulder Elbow Surg* 2011;20:3-11. <http://dx.doi.org/10.1016/j.jse.2010.05.012>
- Matsumura N, Oki S, Ogawa K, Iwamoto T, Ochi K, Sato K, et al. Three-dimensional anthropometric analysis of the glenohumeral joint in a normal Japanese population. *J Shoulder Elbow Surg* 2016;25:493-501. <http://dx.doi.org/10.1016/j.jse.2015.08.003>
- Maurer A, Fucentese SF, Pfirrmann CW, Wirth SH, Djahangiri A, Jost B, et al. Assessment of glenoid inclination on routine clinical radiographs and computed tomography examinations of the shoulder. *J Shoulder Elbow Surg* 2012;21:1096-103. <http://dx.doi.org/10.1016/j.jse.2011.07.010>

24. Moineau G, Levigne C, Boileau P, Young A, Walch G. French Society for Shoulder and Elbow (SOFEC). Three-dimensional measurement method of arthritic glenoid cavity morphology: feasibility and reproducibility. *Orthop Traumatol Surg Res* 2012;98:S139-45. <http://dx.doi.org/10.1016/j.otsr.2012.06.007>
25. Mullaji AB, Beddow FH, Lamb GH. CT measurement of glenoid erosion in arthritis. *J Bone Joint Surg Br* 1994;76:384-8.
26. Oosterom R, Rozing PM, Bersee HE. Effect of glenoid component inclination on its fixation and humeral head subluxation in total shoulder arthroplasty. *Clin Biomech (Bristol, Avon)* 2004;19:1000-8. <http://dx.doi.org/10.1016/j.clinbiomech.2004.07.001>
27. Randelli P, Randelli F, Arrigoni P, Ragone V, D'Ambrosi R, Masuzzo P, et al. Optimal glenoid component inclination in reverse shoulder arthroplasty. How to improve implant stability. *Musculoskelet Surg* 2014;98(Suppl. 1):15-8. <http://dx.doi.org/10.1007/s12306-014-0324-1>
28. Rispoli DM, Sperling JW, Athwal GS, Wenger DE, Cofield RH. Projection of the glenoid center point within the glenoid vault. *Clin Orthop Relat Res* 2008;466:573-8. <http://dx.doi.org/10.1007/s11999-007-0087-1>
29. Rouleau DM, Garant-Saine L, Canet F, Sandman E, Ménard J, Clément J. Measurement of combined glenoid and Hill-Sachs lesions in anterior shoulder instability. *Shoulder Elbow* 2017;9:160-8. <http://dx.doi.org/10.1177/1758573216681208>
30. Scalise JJ, Bryan J, Polster J, Brems JJ, Iannotti JP. Quantitative analysis of glenoid bone loss in osteoarthritis using three-dimensional computed tomography scans. *J Shoulder Elbow Surg* 2008;17:328-35. <http://dx.doi.org/10.1016/j.jse.2007.07.013>
31. Sethi N, Wright R, Yamaguchi K. Disorders of the long head of the biceps tendon. *J Shoulder Elbow Surg* 1999;8:644-54.
32. Sirveaux F, Favard L, Oudet D, Huquet D, Walch G, Mole D. Grammont inverted total shoulder arthroplasty in the treatment of glenohumeral osteoarthritis with massive rupture of the cuff. Results of a multicentre study of 80 shoulders. *J Bone Joint Surg Br* 2004;86:388-95.
33. Tétreault P, Krueger A, Zurakowski D, Gerber C. Glenoid version and rotator cuff tears. *J Orthop Res* 2004;22:202-7. [http://dx.doi.org/10.1016/S0736-0266\(03\)00116-5](http://dx.doi.org/10.1016/S0736-0266(03)00116-5)
34. Ting FS, Poon PC. Perforation tolerance of glenoid implants to abnormal glenoid retroversion, anteversion, and medialization. *J Shoulder Elbow Surg* 2013;22:188-96. <http://dx.doi.org/10.1016/j.jse.2011.12.009>
35. Verstraeten TR, Deschepper E, Jaxsens M, Walravens S, De Coninck B, Pouliart N, et al. Determination of a reference system for the three-dimensional study of the glenohumeral relationship. *Skeletal Radiol* 2013;42:1061-71. <http://dx.doi.org/10.1007/s00256-013-1572-0>
36. Walch G, Badet R, Boulahia A, Khoury A. Morphologic study of the glenoid in primary glenohumeral osteoarthritis. *J Arthroplasty* 1999;14:756-60.