

# Magnetic resonance imaging features of complications following hip replacement: A pictorial review

Khushboo Pilania, Bhavin Jankharia

Department of Radiodiagnosis, Jankharia Imaging Center, Mumbai, Maharashtra, India

**Correspondence:** Dr. Khushboo Pilania, Jankharia Imaging Centre, 383 S V P Road, Bhaveshwar Vihar, Mumbai - 400 004, Maharashtra, India. E-mail: pilania.khushboo@gmail.com

## Abstract

Hip replacement surgery helps millions of people worldwide walk painlessly each year. With increasing life spans and decreased clinical threshold for surgery, this number will continue to rise. With the increase in the number of surgeries and the longevity of implants, the need for early and prompt diagnosis of complications is also rising. This essay underlines the fact that magnetic resonance imaging on a 1.5T scanner with specialized metal artefact reduction sequences is a viable technique to image the post-arthroplasty hip and has vast potential in the prompt and early diagnosis of complications in these patients.

**Key words:** Arthroplasty hip; artifacts; complications; magnetic resonance imaging; musculoskeletal abnormalities

## Introduction

Total hip arthroplasty (THR) involves either total replacement of the femoral head as well as neck and the acetabulum by separate prostheses [Figure 1] or a surface replacement or a “double cup” resurfacing arthroplasty [Figure 2] where only resurfacing of the femoral and the acetabular articular surfaces with metal cups is done.

The type of replacement is further classified on the basis of the material of the prosthesis (e.g., metal vs. ceramic), articulating surfaces (metal on polythelene vs. metal on metal vs. ceramic on polythelene), and the technique used for fixation (cement vs cementless).

The various complications following arthroplasty include aseptic loosening, particle disease (osteolysis), infection,

component wear, dislocation, fracture, heterotopic ossification, metal-induced reactive mass, abductor muscle tear, iliopsoas impingement and muscle atrophy.

The first investigation in evaluating a post-arthroplasty hip is usually plain radiographs, and although they are helpful in picking up fractures, dislocations, and heterotopic ossification, soft tissue pathologies are often overlooked. Nuclear imaging techniques including triple phase bone scans and gallium scans also have an important role in evaluating painful hip arthroplasties, especially because of the lack of artefacts; however, they have limitations due to the lack of anatomic delineation of the pathology.<sup>[1]</sup>

Cross-sectional imaging in post-arthroplasty hips has always been a challenge because of the susceptibility

### Access this article online

#### Quick Response Code:



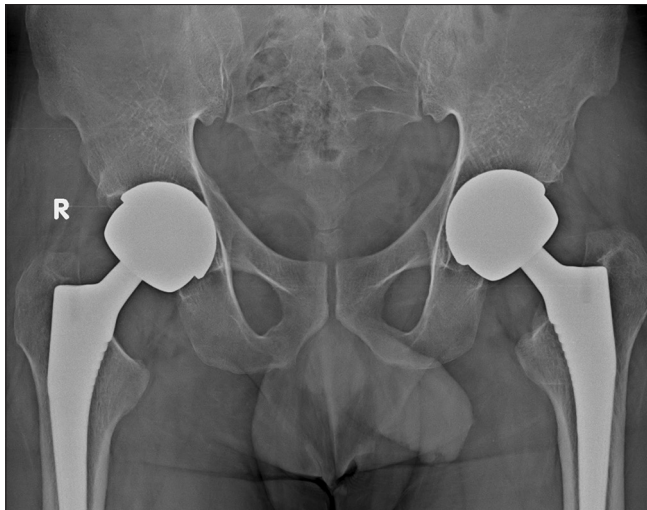
**Website:**  
www.ijri.org

**DOI:**  
10.4103/0971-3026.184414

This is an open access article distributed under the terms of the Creative Commons Attribution-NonCommercial-ShareAlike 3.0 License, which allows others to remix, tweak, and build upon the work non-commercially, as long as the author is credited and the new creations are licensed under the identical terms.

**For reprints contact:** reprints@medknow.com

**Cite this article as:** Pilania K, Jankharia B. Magnetic resonance imaging features of complications following hip replacement: A pictorial review. Indian J Radiol Imaging 2016;26:271-8.



**Figure 1:** Frontal radiograph shows bilateral total hip replacement

artefacts on magnetic resonance imaging (MRI) [Figure 3] and beam hardening on computed tomography (CT) and positron emission tomography (PET)/CT scan, which prevents accurate evaluation of regions of interest near the implants.<sup>[2,3]</sup> Although PET/CT scan provides both functional and anatomic details and can diagnose a problem with high sensitivity,<sup>[1]</sup> it lacks specificity in differentiating periprosthetic infection from loosening or inflammation. Dual energy CT scanners with metal artefact reduction sequences (MARS) protocols reduce artefact considerably and in the future may likely be a viable alternative to MRI.

Lately, with the advent of MARS and newer instrumentation, the challenge of susceptibility artefacts due to metal implants has largely been overcome.<sup>[4,5]</sup> [Figure 4]. Through this article, we intend to provide an insight into the MRI features of various associated complications.

#### Learning objectives

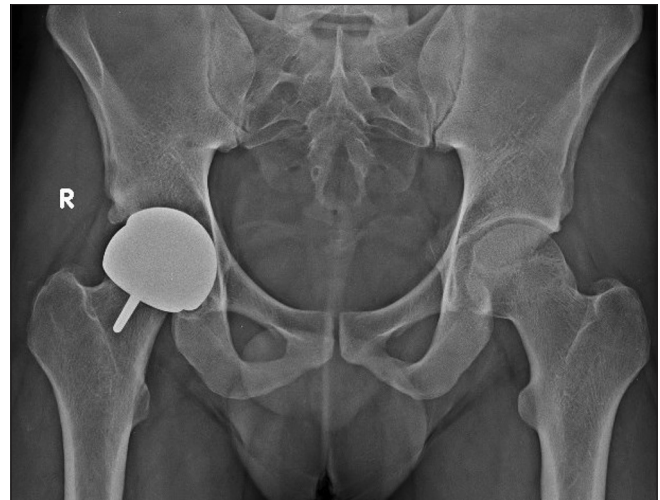1. To review the imaging appearances of the common complications post-hip replacement with emphasis on MRI features
2. To differentiate complications from normal post-arthroplasty appearances
3. To understand the parameter modifications required in overcoming susceptibility artefacts on MRI.

#### Magnetic resonance evaluation of post-arthroplasty hips

This essay is based on the review of MRI findings of 136 patients with 181 replaced hips. The duration of replacement ranged from 6 months to 5.5 years. Of the 181 hips, 110 had total hip replacement (THR) and 71 had resurfacing.

All MRI studies were performed on a 1.5T scanner (Sonata, Siemens, Germany).

Our standard protocol is as follows:



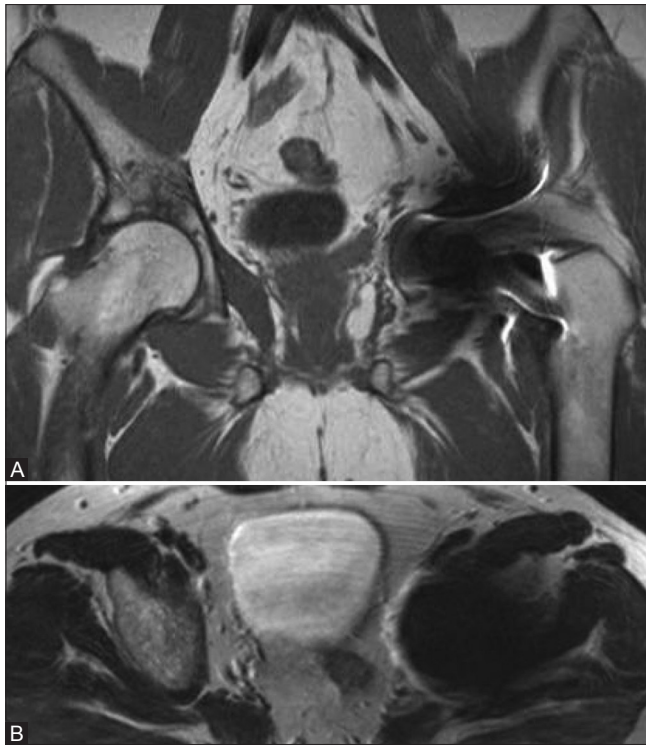**Figure 2:** Frontal radiograph shows resurfacing arthroplasty of the right hip

- Both hips are scanned together in a six-channel body coil
- All subjects undergo MRI using standard clinical protocols optimized to minimize metallic susceptibility artefact
- The protocol includes short TI inversion recovery-echo planar, T1-weighted (T1W) and T2-weighted (T2W) coronal, T1W and T2W axial, and T2W sagittal sequences
- Fast spin-echo T1W and T2W images are obtained in the coronal, axial, and sagittal planes with the frequency encoding direction oriented away from the tissues of interest
- The parameters are as follows: TR range, 400–4000 ms; TE range, 8–102 ms; bandwidth 600–751; FOV, 300–400 mm; number of signals acquired, 2; acquisition matrix, 256–320 (frequency) × 75–80 (phase); and slice thickness, 4 mm. A fast inversion recovery sequence was performed in the coronal plane using the following parameters: TR/TE, 4480/49; inversion time, 130 ms; bandwidth, 407; FOV, 300–350 mm; number of signals acquired, 2; acquisition matrix, 256 (frequency) × 100 (phase); and slice thickness, 4 mm
- The average acquisition time is 2–4 min for each imaging plane with a total acquisition time of approximately 25–30 min.

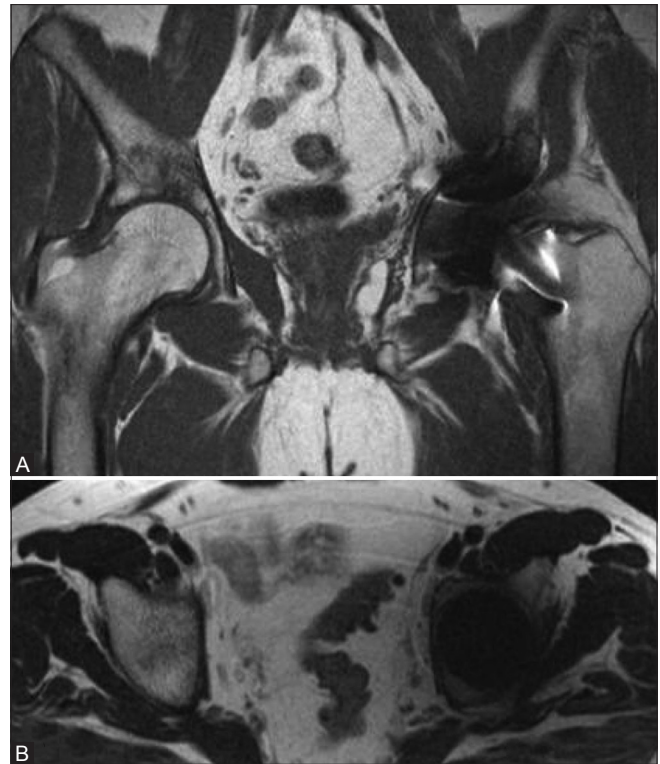The following abnormalities are seen: Periprosthetic osteolysis (18), loosening (3), periprosthetic soft tissue mass (80), muscle atrophy — gluteal maximus (10), gluteal minimus and medius (25), piriformis (41) iliopsoas (39), muscle edema (1), muscle/tendon tear (2), lymphadenopathy (12).

#### Imaging Appearance of Various Complications

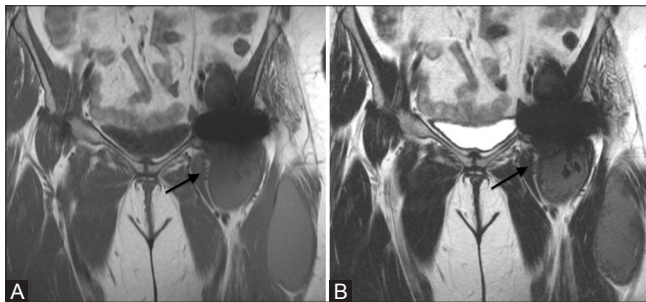
Periprosthetic soft tissue [Figure 5] is defined as abnormal fluid/intermediate-to-low signal intensity



**Figure 3 (A and B):** Conventional coronal T1W (A) and axial T2W (B) images in a patient with left hip resurfacing show extensive artefacts, obliterating soft tissue details



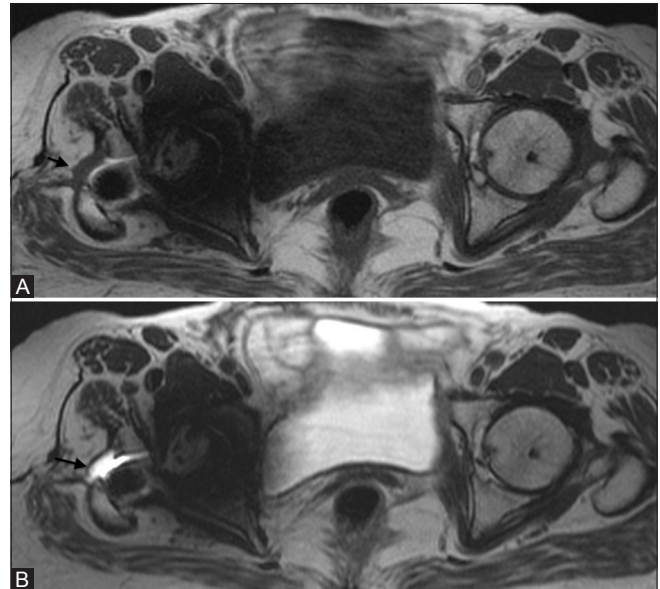
**Figure 4 (A and B):** Images corresponding to Figure 3 after the application of the MARS sequences show significant reduction in the metal artifact and better visualisation of the soft tissue details



**Figure 5 (A and B):** Coronal T1W (A) and T2W (B) MARS images show a large multiloculated, low T2 signal intensity periprosthetic soft tissue mass (arrow) on the left

lesion adjacent to the prosthesis on T1W and T2W images. The low signal on T2-weighted images reflects metal deposition<sup>[6,7]</sup> [Figure 5]. This was found in 80 hips. These are reactive masses also known as pseudotumors<sup>[6,7]</sup> and have been labelled histologically “aseptic lymphocyte-dominated vascular-associated lesions.”<sup>[6]</sup> The proposed pathophysiology behind formation of these masses/fluid collections include elements of delayed hypersensitivity reactions as well as direct toxic effects of metal ions.

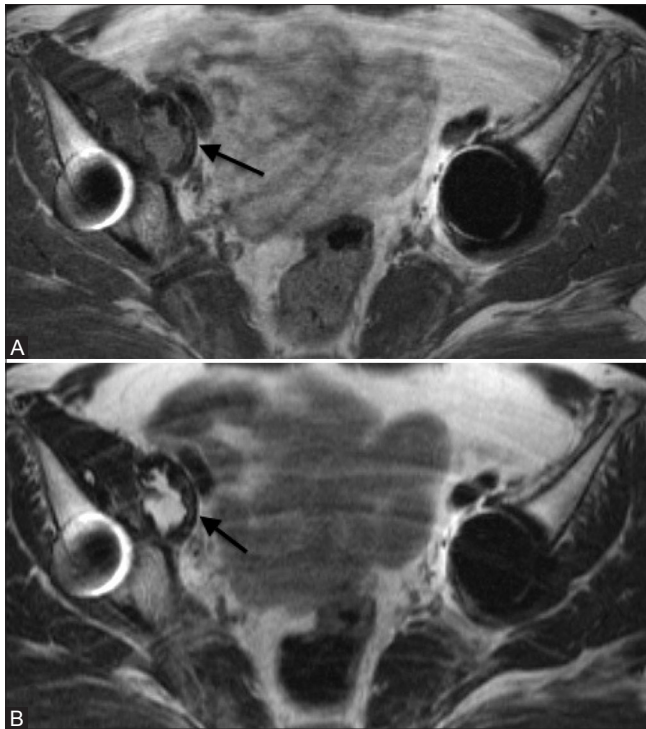
Female sex, small prosthetic cup size, and poor positioning of the components are factors that possibly increase the risk of developing these reactive masses.<sup>[8-10]</sup>



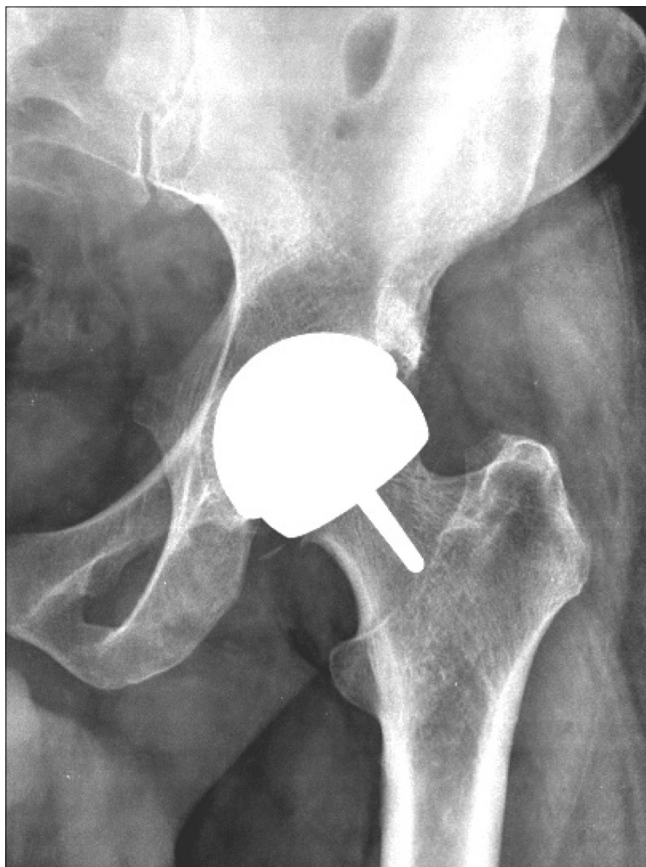**Figure 6 (A and B):** Axial T1W (A) and T2W (B) MARS images show a thin-walled type 1 collection (arrow) anterior to greater trochanter on the right

Sometimes high T1 signal intensity is also seen and this may also reflect metal deposition,<sup>[6,7]</sup> even though hemorrhage may also present similarly. A peripheral T1 hyperintense rim may be indicative of infection.<sup>[11,12]</sup> Sometimes, there is

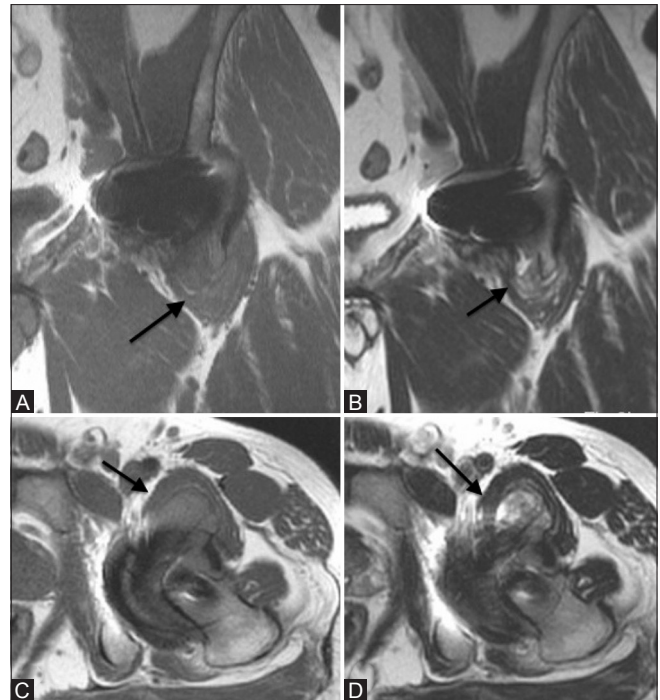




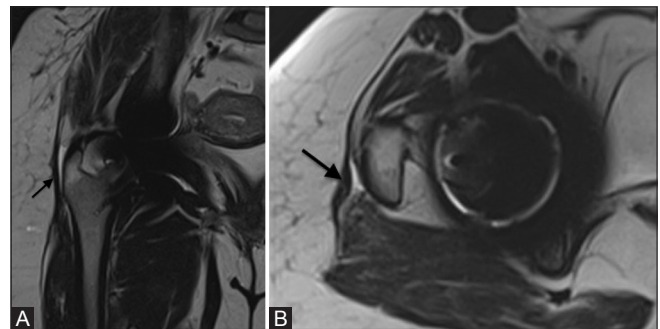
**Figure 7 (A and B):** Axial T1W (A) and T2W (B) MARS images show a thick-walled type 2 collection (arrow) within the right iliopsoas muscle



**Figure 9:** Frontal radiograph of the same patient shown in Figure 8 showed no abnormality



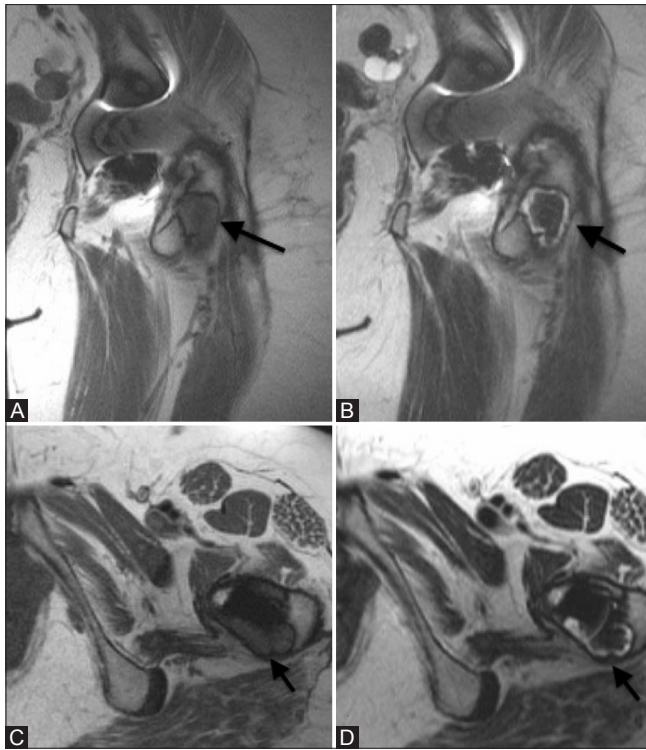
**Figure 8 (A-D):** Coronal T1W (A), T2W (B) and axial T1W (C) and T2W (D) images show a heterogenous thick-walled periprosthetic soft tissue (arrow) in the left iliopsoas bursa



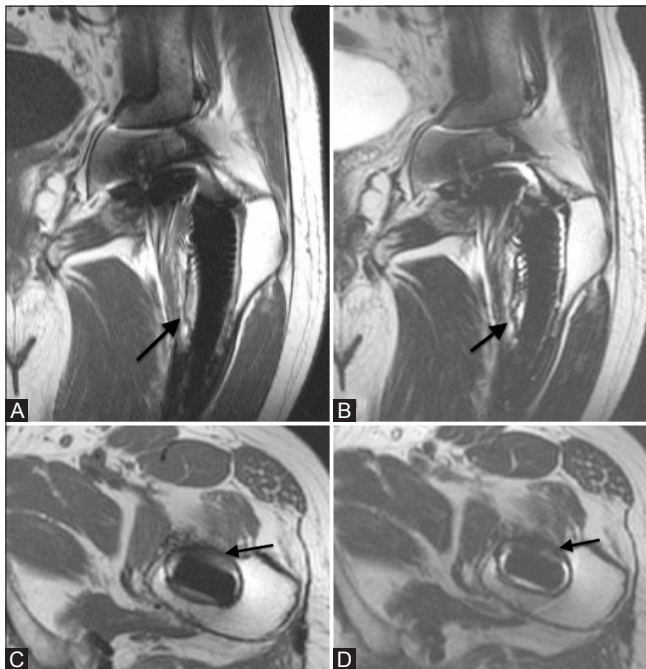
**Figure 10 (A and B):** Coronal (A) and axial (B) T2W images show fluid in the right trochanteric bursa not communicating with the joint space (black arrow)

a dilemma in distinguishing juxtaarticular abscesses from reactive masses, especially in symptomatic patients, and diagnostic confidence can be achieved only by biopsy/aspiration and analysis of the material.

The periprosthetic soft tissues are classified into three types based on MRI findings: Type 1 [Figure 6], cystic masses with wall <3 mm; type 2 [Figure 7], cystic masses with wall >3 mm but less than the diameter of the cystic component; and type 3 [Figures 8 and 9], predominantly solid masses.<sup>[13]</sup> The size of the mass and its relationship to surrounding structures is meticulously defined. Careful inspection for communication of collection with joint is done to avoid erroneously labelling a thickened non-communicating trochanteric bursa as a “reactive mass.” [Figure 10].<sup>[6]</sup>

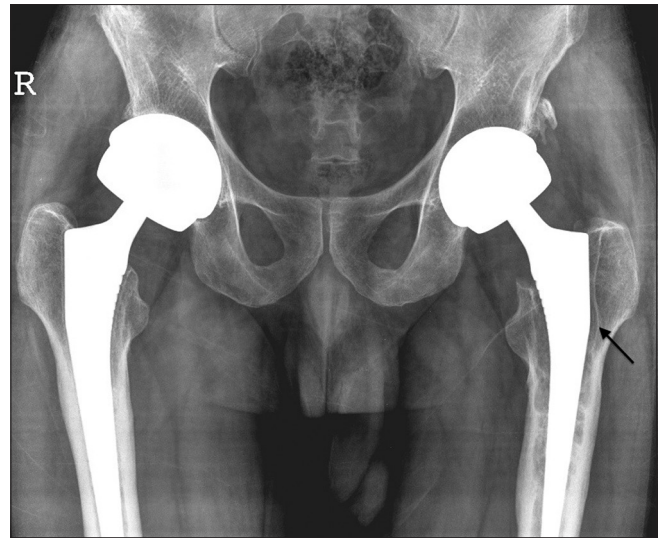


**Figure 11 (A-D):** Focal particle disease. Coronal T1W (A) and T2W (B) and axial T1W (C) and T2W (D) images show a well defined focal areas of osteolysis with low T2 signal soft tissue (arrow), at the proximal bone prosthesis interface posteriorly

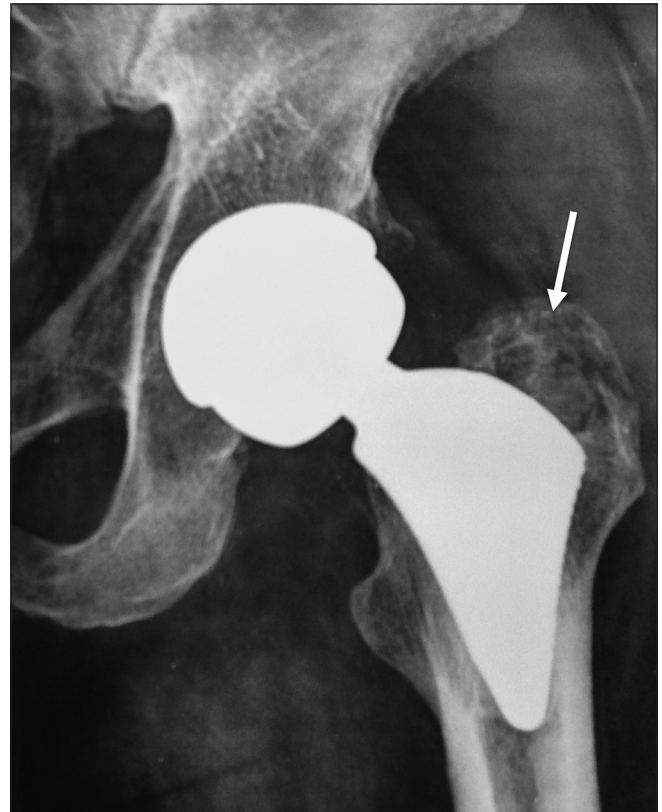

**Figure 13 (A-D):** Loosening. Coronal T1W (A), T2W (B) and axial T1W (C) and T2W (D) images of the same patient with bilateral THR show linear fluid signal (arrow) tracking along the bone prosthesis interface on the left. Obvious marrow edema is not seen

These periprosthetic masses have been recognized as a major cause of revision, which is required in patients



**Figure 12:** Frontal radiograph of the pelvis shows linear lucency (arrow) along the bone prosthesis interface on the left

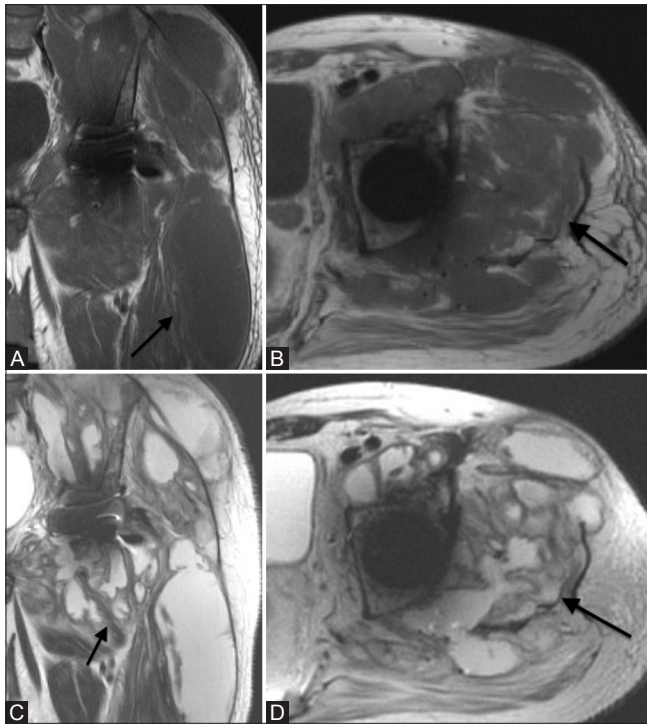


**Figure 14:** Osteomyelitis. Plain radiograph of a patient with left THR and swelling of the left thigh, shows an ill-defined osteolytic area with possible sequestrum (arrow) in the left greater trochanter region

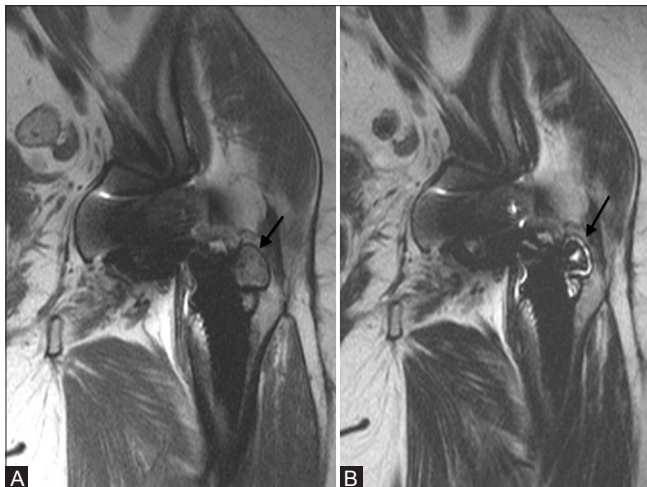
with troublesome symptoms or larger lesions. Correct management of patients with smaller lesions and minor symptoms is still uncertain because it is not known whether these lesions are likely to progress.<sup>[6]</sup>

Osteolysis is denoted as intermediate-signal-intensity marrow replacement of the hyperintense fatty marrow





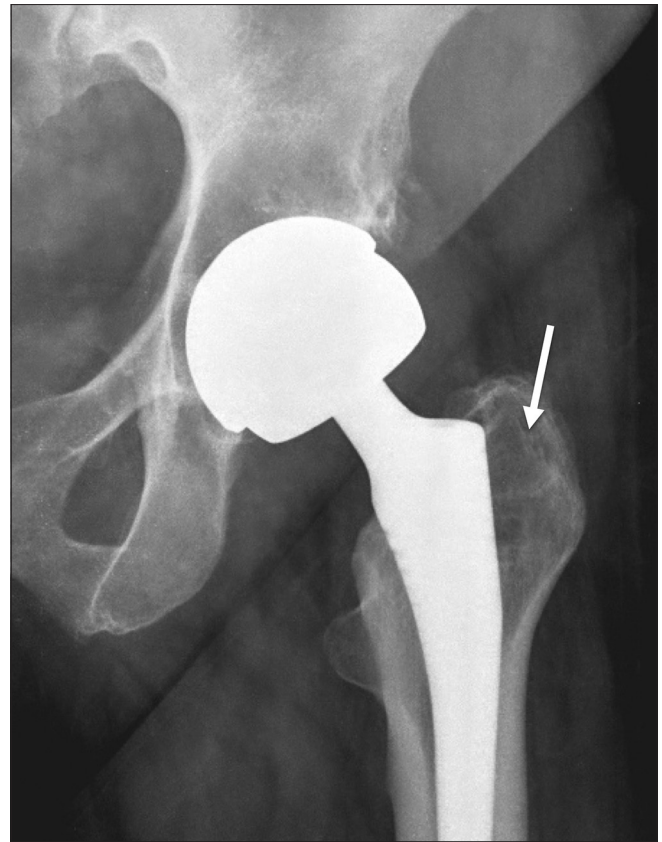**Figure 15 (A-D):** Coronal and axial T1W (A,B) and T2W (C,D) images of the same patient show associated large multiloculated abscesses (arrow)



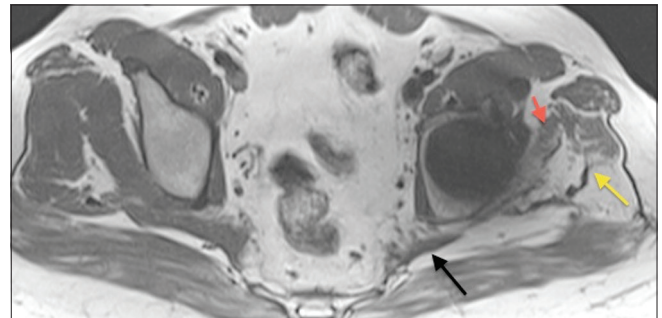
**Figure 17 (A and B):** Coronal T1W (A) and T2W (B) images of the same patient shown in Figure 16, show a well defined focal area of osteolysis (arrow) at the bone prosthesis interface laterally, confirming the radiographic lucency to be focal particle disease

[Figure 11]. The presence, location (acetabular, femur or both), as well as size are recorded. The pathophysiology behind this periprosthetic osteolysis is essentially the same as that described for the reactive masses.

A focal well-defined area of osteolysis without the surrounding edema is usually labelled as focal particle disease [Figure 11]. Linear, long segment, fluid signal-intensity marrow replacement of >2 mm width,



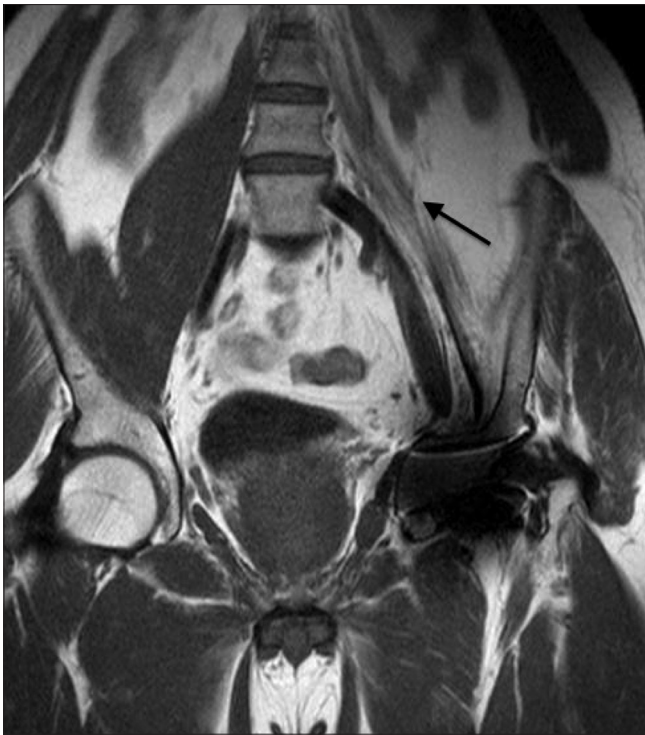**Figure 16:** Frontal radiograph of a patient with left THR shows periprosthetic lucency (arrow) in the left greater trochanter. It is difficult to confidently differentiate periprosthetic osteopenia due to stress shielding from osteolysis due to particle disease



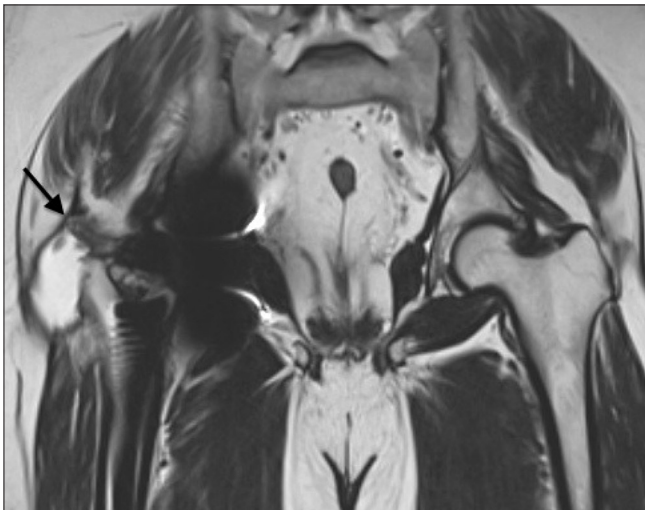
**Figure 18:** Axial T1W image shows severe atrophy of the left gluteus minimus (red arrow) and medius (yellow arrow) with fatty infiltration. Moderate atrophy of the left piriformis (black arrow) is also seen

along the bone prosthesis interface, without significant marrow edema, is suggestive of aseptic loosening of the prosthesis [Figures 12 and 13]. An irregular ill-defined area of osteolysis with marrow edema is usually seen in cases of infection [Figures 14 and 15]. Presence of enlarged lymph nodes adds to the level of confidence.

The differentiation is important as it dictates management because large sized focal particle disease and loosening usually require revision whereas smaller sized particle



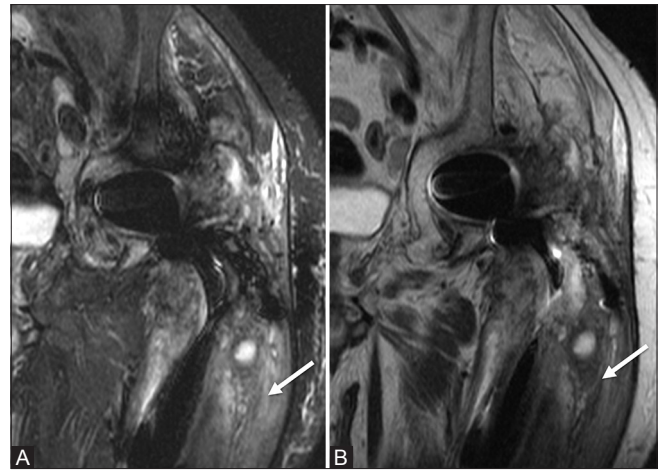
**Figure 19:** Coronal T1W image shows severe atrophy (arrow) of the left iliopsoas muscle



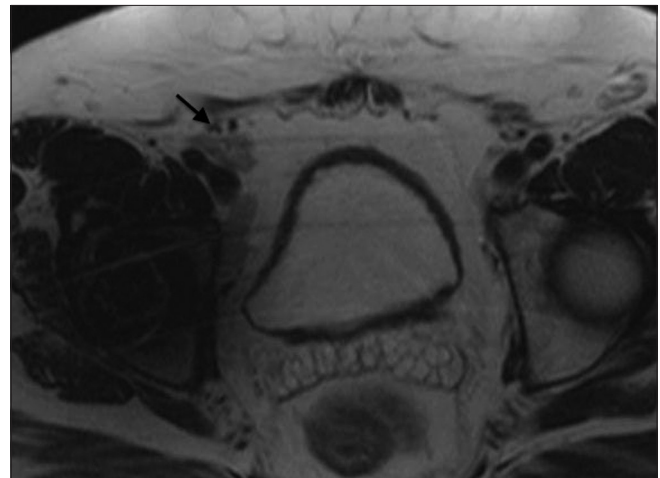**Figure 21:** Coronal T1W image shows a tear of the tendinous insertion of the right gluteus medius from its insertion on the greater trochanter (arrow)

diseases may sometimes be followed-up without any need for immediate revision. Periprosthetic infections may be treated with antibiotics, especially if associated complications such as loosening are not present.

Three patients in whom radiographs were suggestive of periprosthetic osteolysis involving the greater trochanter, were found to have no osteolysis on MR, and thus MR helped in differentiating normal periprosthetic osteopenia that occurs in areas of stress shielding from particle disease



**Figure 20 (A and B):** Coronal STIR (A) and T2W (B) images show edema (arrow) of the muscles of the left thigh



**Figure 22:** Axial T2W image shows an enlarged right external iliac lymph node (arrow)

[Figures 16 and 17]. Calcar resorption is also sometimes mistaken as pathological osteolysis and absence of marrow edema on MR adds to the diagnostic confidence of this being a normal post-arthroplasty appearance. Stress loading distally may result in cortical thickening and bridging sclerosis at the tip of the prosthesis (called pedestal). Understanding of these normal post-arthroplasty appearances has become important with the increasing use of bone ingrowth prosthesis, which results in more reactive changes in the native bone due to the altered stress distribution.

Lucent zones at the metal-bone interface are also seen in stable noncemented hip arthroplasties because fixation in these cases is usually due to a combination of both bone and fibrous tissue ingrowth and the fibrous tissue may present as a lucent zone at the interface on radiographs, which again can be distinguished on MR by the low signal tissue in cases of fibrous ingrowth vs. high signal soft tissue within the lucent zones in cases of loosening. Stability over



time, however, still remains the most important factor differentiating between the two. The gluteus, piriformis, and iliopsoas muscles are assessed for the presence of atrophy [Figures 18 and 19], defined as loss of volume and the presence of fatty replacement, as well as for the presence of muscle edema [Figure 20], defined as the presence of high signal intensity on inversion recovery images. Gluteal maximus atrophy—moderate-to-severe was appreciated in 10 hips, gluteus medius, and minimus atrophy was seen in 25 hips. 39 of 179 hips had iliopsoas atrophy and 41 had atrophy of the piriformis.

The presence or absence of a tear [Figure 21] is graded as follows: 1, no tear; 2, partial-thickness tear; or 3, full-thickness tear.

The pelvic region is assessed for enlarged lymph nodes [Figure 22] with enlargement being defined as >1 cm in short axis diameter. Lymphadenopathy was reported in 12 patients. Abductor tendon tear was seen in 3 and muscle edema in one hip.

## Conclusion

With the ever-increasing number of hip replacements worldwide, the demand for prompt and early diagnosis of post arthroplasty complications has increased as well. Radiographs and nuclear imaging, earlier the mainstays for the evaluation of post arthroplasty hips, have vast limitations especially with respect to the evaluation of soft tissue details, which account for the symptoms in a significant number of patients. MARS MRI is proving to be of immense help in detailed evaluation of these soft tissue complications. Periprosthetic reactive soft tissues, the most common cause of revision and usually not detected on radiographs, are picked up with relatively high sensitivity on MRI even in early stages. The differentiation of periprosthetic osteolysis from osteopenia related to stress shielding is quite straightforward with MRI. MRI also allows early diagnosis of infection way before changes are evident on radiographs and thus allows prompt and early treatment. This essay shows the potential of MARS MRI on a 1.5T scanner in the post-arthroplasty hip.

## Financial support and sponsorship

Nil.

## Conflicts of interest

There are no conflicts of interest.

## References

1. Jansen JA, Smit F. The role of nuclear medicine techniques in differentiation between septic and aseptic loosening of total hip and knee arthroplasty. *Tijdschr Nucl Geneesk* 2012;34:988-94.
2. Lee MJ, Kim S, Lee SA, Song HT, Huh YM, Kim DH, *et al.* Overcoming artifacts from metallic orthopedic implants at high-field-strength MR imaging and multidetector CT. *RadioGraphics* 2007;27:791-803.
3. White LM, Buckwalter KA. Technical considerations: CT and MR imaging in the postoperative orthopedic patient. *Semin Musculoskelet Radiol* 2002;6:5-17.
4. Guermazi A, Miaux Y, Zaim S, Peterfy CG, White D, Genant HK. Metallic artefacts in MR imaging: Effects of main field orientation and strength. *Clin Radiol* 2003;58:322-8.
5. Mitchell DG, Cohen MS. Transverse magnetization and T2 contrast. In: Mitchell DG, Cohen MS, eds. *MRI principles*. 2<sup>nd</sup> ed. New York, NY: Springer-Verlag; 2000. p. 35-47.
6. Ostlere S. How to image Metal-on-Metal prostheses and their complications. *AJR Am J Roentgenol* 2011;197:558-67.
7. Davies AP, Willert HG, Campbell PA, Learmonth ID, Case CP. An unusual lymphocytic perivascular infiltration in tissues around contemporary metal-on-metal joint replacements. *J Bone Joint Surg Am* 2005;87:18-27.
8. Grammatopoulos G, Pandit H, Oxford Hip and Knee Group, Murray DW, Gill HS. The relationship between head-neck ratio and pseudotumour formation in metal-on-metal resurfacing arthroplasty of the hip. *J Bone Joint Surg Br* 2010;92:1527-34.
9. De Haan R, Campbell PA, Su EP, De Smet KA. Revision of metal-on-metal resurfacing arthroplasty of the hip: The influence of malpositioning of the components. *J Bone Joint Surg Br* 2008;90:1158-63.
10. Glyn-Jones S, Pandit H, Kwon YM, Doll H, Gill HS, Murray DW. Risk factors for inflammatory pseudotumour formation following hip resurfacing. *J Bone Joint Surg Br* 2009;91:1566-74.
11. Soler R, Rodríguez E, Remuiñán C, Santos M. MRI of musculoskeletal extraspinal tuberculosis. *J Comput Assist Tomogr* 2001 25 (2):177-83.
12. Sharma P. MR features of tuberculous osteomyelitis. *Skeletal Radiol* 2003;32:279-85.
13. Hauptfleisch J, Pandit H, Grammatopoulos G, Gill HS, Murray DW, Ostlere S. A MRI classification of periprosthetic soft tissue masses (pseudotumours) associated with metal-on-metal resurfacing hip arthroplasty. *Skeletal Radiol* 2012;41:149-55.